

# JOURNAL of FORENSIC ODONTO- STOMATOLOGY

## VOLUME 34 Number 2 December 2016

### SECTION IDENTIFICATION

## Multiple deaths caused by a fire in a factory: identification and investigative issues

Vilma Pinchi<sup>1</sup>, Viola Bartolini<sup>1</sup>, Elisabetta Bertol<sup>2</sup>, Martina Focardi<sup>1</sup>, Francesco Mari<sup>2</sup>, Ugo Ricci<sup>3</sup>, Stefano Vanin<sup>4</sup>,  
Gian-Aristide Norelli<sup>1</sup>

<sup>1</sup>Department of Health Sciences, Section of Medical Forensic Sciences, University of Florence, Florence, Italy

<sup>2</sup> Department of Health Sciences, Forensic Toxicology Division, University of Florence, Florence, Italy

<sup>3</sup>Diagnostic Genetics Unit, Azienda Ospedaliero-Universitaria Careggi, Florence, Italy <sup>4</sup>Department of Biological Sciences, School of Applied Sciences, University of Huddersfield, UK

Corresponding author: [vilma.pinchi@unifi.it](mailto:vilma.pinchi@unifi.it)

The authors declare that they have no conflict of interest.

### ABSTRACT

*The article presents a case of multiple casualties following a textile factory fire. The incident required a full DVI team similar to large mass-disaster because of the specific operational aspects and identification difficulties. The autopsy results were consistent with death by fire and the toxicological investigations revealed carbon monoxide poisoning in four cases (HbCO% ranging between 88,05 and 95,77), two deaths by cyanide intoxication (with concentrations between 5,17 and 8,85 mcg/ml), and in one case there was a synergistic effect of the two substances (carbon monoxide and cyanide). The identification, carried out in accordance with INTERPOL protocols, encountered serious difficulties in the AM phase primarily due to a language barrier and the lack of any dental or medical information relating to the victims. Secondary identifiers proved to be very useful in corroborating possible identities. As a result of the combined efforts of a team of experts the identity of each victim was determined and in all cases at least one primary identifier was used in the identification process. The deployment of DVI teams composed of forensic experts from different fields of expertise and well acquainted with DVI procedures, is essential in events involving multiple casualties that may also include foreign victims. The DVI team should intervene not only in PM examinations but also in the collection of AM data for those individuals not accounted for and by helping police in contacting families of missing people.*

**KEYWORDS:** carbonization; body identification; charred bodies; DVI teams; fire multicasualties; tongue protrusion.

JFOS. July 2016, Vol.33, No.2 Pag 47-59  
ISSN :2219-6749

## INTRODUCTION

A mass-disaster is defined as *an event which generates more victims at one time than locally available resources can manage using routine procedures. It requires exceptional emergency arrangements and additional or extraordinary assistance.*<sup>1</sup>

In Italy, Magistrates have the responsibility to implement investigations for the identification of victims in cases of mass disaster. They commission case-by-case teams of forensic experts from the police and other Institutions, such as Universities. DVI teams with specifically qualified and trained professionals are not yet available in Italy despite the establishment of DVI section from 2006<sup>2</sup> by the National State Police. The legal framework on DVI activity and organization is, however, evolving thanks to a new proposal of law that is actually under discussion at Italian Parliament. This law will ultimately implement procedures from Interpol's DVI recommendations and, if implemented, will form the basis for the recruitment and the composition of DVI teams in Italy for the future.

The recovery of burned corpses invariably raises specific forensic issues requiring appropriate intervention in order to both establish the cause of death and the identification of the victims. The forensic pathologist must determine if the victim was exposed to fire before or after death and report possible evidence of homicide, suicide or accidental death. Therefore, a careful examination of the corpse is essential to detect not only vital signs but also to detect any possible injuries contributing to, or causing death.<sup>3,4</sup>

Fires in a closed environment generally cause severe destruction of the bodies of the victims. Due to the lasting high temperature<sup>5</sup> in these cases visual recognition is not usually appropriate and a scientific identification process through the

comparison and reconciliation of primary and secondary identifiers according to DVI Interpol procedures is required.<sup>6,7</sup>

Any forensic activity, therefore, must be performed with the utmost care, paying very close attention to every aspect of evidence collection at the disaster or crime scene. In cases of advanced carbonization, small or tiny fragments such as teeth may become detached and disregarded as important evidence by personnel not trained in forensics. There is also the ever present risk that certain personal items or body parts could be damaged, misplaced or even lost during victim recovery and transportation to the mortuary. Specific techniques such as fixing sprays or glues can be applied to the body parts prior to removal of the body.<sup>8</sup> During this phase of recovery, the participation of forensic experts is essential in order to obtain a general description of the state of the victims and to record accurately the number of victims and detached body parts. Such methods allow for proper documentation of all personal effects including their positions and locations at the disaster scene. Later these details could provide invaluable information in the identification process. Not only can this information help to identify the victims, but may also lead to an understanding of the possible causation of the deaths and injuries as well as the circumstances of the disaster itself.<sup>9,10</sup>

This paper reports a case of multiple deaths in a textile factory that required the full participation of a DVI team composed of two Forensic pathologists, a Forensic Toxicologist, two Forensic Odontologists and a Forensic DNA expert. Because of specific operational and identification difficulties the DVI team was similar to that deployed for mass-disasters.

In addition, the case was conducted against the background of a serious crime

investigation that included the violation of labour and safety laws, building regulations and immigration laws. There were also diplomatic issues, since all of the victims were of Chinese nationality. As a result the case required an extensive police investigation with lasting public and media attention. Hence, forensic experts were not only under pressure to provide prompt and effective identification of the charred bodies, but also to provide relevant data that could prove useful for the Police criminal investigations.

The case highlights the crucial role of the timely deployment of a forensic team, made up of experts as suggested by the DVI Interpol procedures and appropriate to the specific identification and investigative issues of the case. Additionally, this report discusses the reliability of some specific findings used in identifying victims in a closed disaster and complications encountered in PM and AM data collection.

### **MATERIALS AND METHODS**

In September of 2013, a large fire broke out in a textile factory in Prato (central Italy), where a number of illegal Chinese workers were employed.

From the beginning, the case aroused the interest of the public and politicians. The town of Prato, close to Florence, has a long history in textile, a thriving industry. Over the last few decades the town has undergone an economic crisis. It has also seen a rise in Chinese immigration and a number of industries belonging to Chinese entrepreneurs. Typically, these industries employ many illegal immigrants working in sweatshop-like conditions. These employees not only work in the factories but frequently live, eat, and sleep inside them.

The report states the fire night caused by a malfunction of the heating system. It

happened at night when many of the occupants were most likely asleep. Some workers near the building's main entrance survived. After the fire was extinguished, firefighters recovered the charred remains of seven bodies, supposedly workers at the same factory.

The Criminal Court of Prato appointed a single Forensic Pathologist who intervened directly at the disaster site. The following day a DVI team was called upon to determine the cause of death and identify the victims. Later a second Forensic Odontologist was called on for quality control as required by Interpol 600's forms.

The factory, with an area of 500 square meters, was made up of a large single space with front access. To the right, there were two rooms; a bathroom and a dormitory. These two rooms were covered by plasterboard. There was a wooden loft, which partially collapsed in the fire along with the roof. In addition to manufacturing equipment the facility housed combustible textile material which fueled the fire. The absence of any sort of accelerant or other suggestive evidence or circumstantial data excluded the possibility of arson.

Figure 1 shows the inside of the building and the position of the victims at recovery. Five of the seven bodies (corresponding to PM 2,3,5,6,7) were found partially buried in the rubble close together at the back of the shed on the right hand side, corresponding to the section of loft that collapsed. Another victim, (PM4) found with a cell phone in the left hand, was on the same side but separated from the others. The last victim, in nightclothes, (PM1), was found in the anterior portion of the loft which was still standing. The victim was near a window covered by a grating with one arm poking through the broken glass of the window.

Because conditions at the factory were dangerous as a result of the fire, the DVI team was not allowed on site. Against this background there was no possibility to identify and recover any remaining body parts that may have been either neglected or overlooked during removal of the bodies.

All forensic activities (AM and PM) for body examination and identification were carried out in the Department of Health Sciences, section of Medical Forensic Sciences at the University of Florence.

Forensic pathologists, odontologists and geneticists collected ante-mortem (AM) data obtained from relatives and acquaintances of the victims. Interviews were conducted with the help of an official Chinese interpreter. During AM sessions, saliva samples were taken from close relatives of the victims and AM data of the missing were registered on AM INTERPOL forms.<sup>11</sup> The postmortem examination started with photographic documentation and full-x-rays of all of the victims or human remains using a portable X-ray machine Corsix Italray®. External examination and full autopsies were then performed according to standard post-mortem forensic procedures as much as was possible given the state of the seriously carbonized remains.<sup>6</sup>

Forensic odontologists conducted dental examinations, including oral photography and intra-oral digital radiography using a Dental Portable X-ray machine Rextar-X® (Posdion Co., Ltd) and Intraoral Digital Dental X-Ray Sensor Sirona Xios®.

Postmortem data were registered on INTERPOL's pink PM DVI forms.

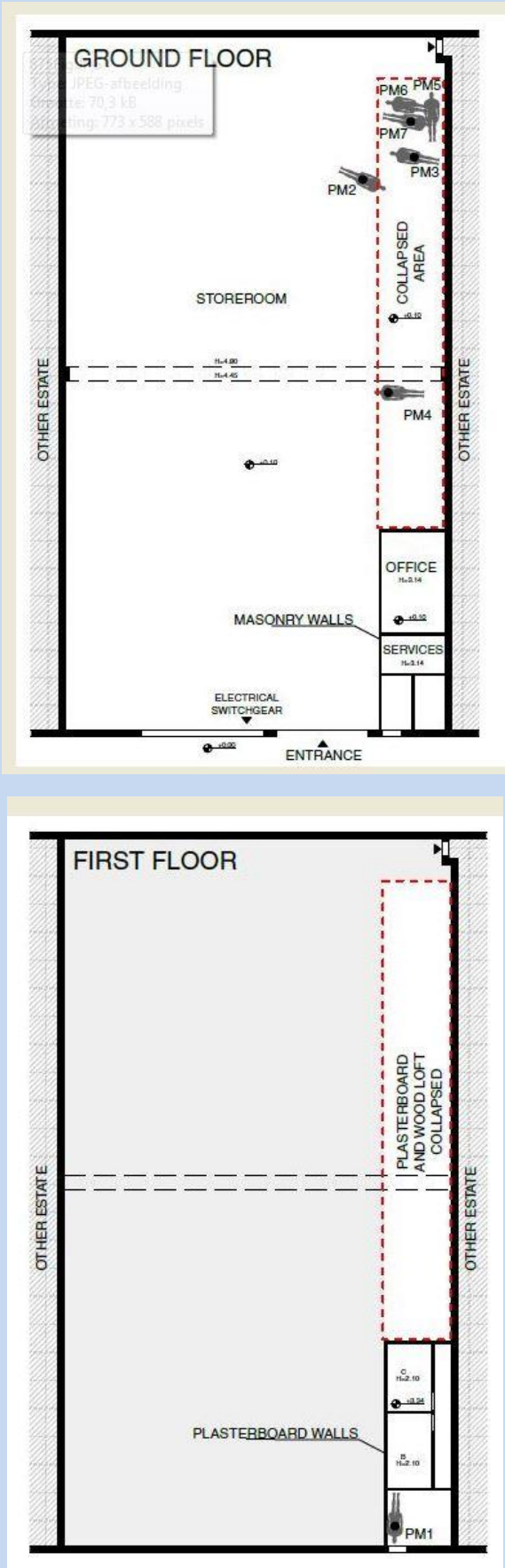
The identification was carried out in accordance with Interpol protocols,<sup>6,7</sup>

through a careful reconciliation of AM and PM data.

Toxicological investigations were performed on blood samples by gas chromatography-mass spectrometry to investigate amounts of ethanol, psychotropic, hypnotic, toxic or any pharmacologically active substances. In order to assess the cause of death and the status of vitality at the time of the fire, levels of carboxyhemoglobin and cyanide were measured by spectrophotometry.

Genetic investigations were done according to the recommendations of the International Society of Forensic Genetics (ISFG),<sup>12</sup> and of ENFSI (European Network of Forensic Science Institutes)<sup>13</sup>. According to the INTERPOL recommendation<sup>6</sup> samples of muscles and oral mucosa were taken from each victim from anatomical sites that were least damaged by the fire. In cases of severely burned victims one tooth was collected as a possible source of DNA. DNA, extracted through manual and automated procedures<sup>14, 15</sup> from tissue samples, was quantified by Nanodrop method. Genetic profiles were obtained through AmpFISTR® NGM™ PCR Amplification Kit (Life Technology, USA) and PowerPlex® Y23 System (Promega, USA). Profile comparison was performed using the software Familias®.<sup>16</sup>

Fig.1: GRAPHIC PRINTOUT OF BODY'S POSITION



## **RESULTS**

### **1. Identification**

#### **1.1. P.M. data**

Numbering and labeling the bodies (from PM1 to PM7) presented the first major obstacle since each body had two sets of labels and numbers. The first set was done by firefighters at the disaster scene and the second set by mortuary personnel. Complete photo sets taken by the police and the forensic pathologist inside the factory facilitated reconciliation of the two different sets of labels and numbers enabling the original position of the victims to be determined.

Most of the bodies were incomplete and the degree of carbonization was so thorough that facial recognition was possible for only one victim.

Table 1 shows the PM data related to primary identifiers (dental records, fingerprints and DNA) and other autopsy findings as well as relevant circumstantial, autopsy and toxicological findings necessary to ascertain the cause of death.

Amputations and/or charring of the limbs prevented the collection of fingerprints in five of the seven victims. Interpol 600 PM forms were completed with dental data for six of the seven victims despite the high degree of carbonization. Dental data was unavailable for one victim where the splanchnocranium had been completely destroyed. Complete sets of intra-oral X-rays were also taken where possible.

Determining the genetic profile was possible in all cases using soft tissue samples.<sup>17</sup>

Prior to autopsy, full X-rays of the victims were captured; no significant findings were detected.

#### **1.2. A.M. data**

Language barriers caused major difficulties during AM interviews. Despite having lived in Italy for several years, many of the Chinese interviewed spoke little or no Italian. The official interpreter was unable to understand all of the various Chinese languages and dialects. In some cases, where verbal communication was unhelpful, odontologists were reduced to asking relatives to sketch rather than describe dental features. Additionally, some of the victims had entered Italy illegally and had no official I.D. making even gathering of basic information difficult. The lack of medical and dental records proved increasingly problematic. Most of the victims seemed to have had dental work done in China but none of the relatives knew whether the missing victims had ever sought treatment in Italy from a physician, hospital or dentist or whether their medical needs had been taken care of within the Chinese community.

No medical or dental records were provided to the Italian authorities by the relatives in China. However, using important information and data (Table 2) gathered from the in-depth interviews with relatives, sufficient material was collected to enable the reconciliation phase. A relative for each of the unidentified victims was available to provide a saliva sample: two brothers, two sisters, one daughter, one son and a mother.

#### **1.3. Reconciliation**

The results of the identification activity are summarized in Table 2, which shows the primary identifiers and the secondary means of identification for each victim.

The genetic link between the victim and relatives was assessed in all cases. When the profile of a relative in direct line was provided (three victims), the identification was obtained and expressed in terms of full

compatibility; in the other cases a statistical analysis was performed and the results expressed in terms of likelihood ratio. In all cases, a positive association was made confirming, with various degrees of likelihood, and all of the victims were identified (Table 2).

Fingerprints were obtainable in two cases. A positive match was found with two of the missing whose fingerprints had been registered in the AFIS (Automated Fingerprints Identification System). Dental data recounted by relatives suggested possible or probable identification in four cases. For example, PM 2 showed a pin in tooth 22, compatible with a gold crown on an upper incisor, reported by relatives (Table 2); the diastema and the lack of a tooth observed in PM1 matched the anamnestic data provided by AM3.

In four cases the identification was by secondary means of identification, primarily related to anatomical features, such as in the case of PM6, where the absence of the uterus uncovered during the autopsy phase was congruent with a previous hysterectomy reported by relatives.

Carbonization of PM5 was so advanced as to prevent the collecting of any dental data or fingerprints. However, a decorated gold necklace around the victim's neck was identical to the gold necklace in photographs of one of the missing.

The malformation of a nail phalanx on the index finger of the left hand observed in PM1 was initially considered potentially relevant because such malformation is so rare in the general population. Yet it is a typical deformity in sewing machine operators. In fact the malformation was reported by relatives for five of victims and therefore it proved to be inconclusive.

## **2. Cause of death**

As shown in table 1, the toxicological analysis revealed high levels of carboxyhemoglobin (HbCO), ranging between 48.68% and 95.77%, with variable concentrations of cyanides (between 0.29 and 8.85 mcg/ml). In two cases, the death was due to acute cyanide poisoning. Four subjects died of carbon monoxide poisoning. In one case the concentrations of the two substances, although high, were at sub-lethal levels, leading to the hypothesis of a combined synergic effect from the two substances as cause of death.

The levels of ethanol, between 0.15 and 0.71 g/l), were not relevant to death. Nor were any exogenous substances or drugs potentially relevant as a cause of death.

As shown in table 1, in all cases (with the exception of the most severely carbonised body) the autopsy revealed soot in the airway and with variable degrees of soot in the oesophagus. In two cases oedema and redness of the larynx or of the lower airways was observed as a consequence of inhalation of hot gases. Fractures of the skull, together with the presence of blood in the extra-dural spaces observed in the most of the charred bodies found beneath the rubble, can be ascribed to post-mortem events. Similarly, the retraction of the dura and of the brain that was observed is compatible with post-mortem events. The examination disclosed protrusion of the tongue between the teeth in three of the seven victims; in the other four cases this phenomenon could not be determined because of the degree of carbonization of the lower part of the face or of the tongue itself.

## **DISCUSSION**

### **Identification**

The identity of all the bodies was accurately established through primary and secondary identifiers. The forensic experts,

however, faced several difficulties arising at different stages of the investigation. Given the severe carbonization of most bodies, fingerprints were retrievable in only two cases, and in one case dental information was missing as a consequence of destruction of the splanchnocranium. Moreover the victims recovered were allocated two different sets of labels and numbers, initially by firefighters at the disaster site and secondarily by mortuary personnel receiving the victims. These problems were caused by the delay in commissioning assistance from a team qualified and familiar with DVI procedures prior to body recovery and labelling.

The case highlights the lack of specific legal guidance currently in force to establish procedures for response, recruitment and operation of DVI teams for both mass disasters and incidents involving multiple casualties. Moreover there is an impelling need to both determine and quantify the qualifications and numbers of experts comprising a DVI team in cases of the necessity of an urgent response.

The impending consideration of a new law concerning mass-disasters and incidents involving multiple casualties currently under examination by the Italian Parliament may result in the appropriate legal implementation of DVI Interpol procedures in Italy. Until a ruling from the Italian Parliament has been granted the current status of an “ad hoc” response initiated by the local Magistrate that encompasses Police and “civilian” specialists (from Universities, hospitals, etc) will be likely to prevail.

Soft tissues for genetic examination resulted adequate for DNA testing from all of the victims, so there was no need for DNA extractions from dental structures. A direct comparison of the DNA from the victims was not possible because there

were no biological AM samples available. However DNA from

relatives in direct line to the victims was obtainable in some cases. Against this background genetic evaluation was carried out in terms of likelihood. However, amongst the victims, there were neither siblings nor blood relatives available for sampling, so an adequate level of certainty,<sup>18</sup> as stipulated by the ISFG (International Society for Forensic Genetics) was secured.

Of particular significance it is important to state that other identifiers, both primary (dental and fingerprints) and secondary, were used in confirming the genetic results, underlining the importance of a multidisciplinary approach between forensic specialists.<sup>19</sup>

Dental structures are extremely resistant to high temperatures,<sup>20</sup> but in this case three of the victims were so severely carbonized to an extent that the teeth were of no evidential value for purposes of identification. In one case there was complete destruction of the splanchnocranium. The careful collection of teeth and dental fragments and their subsequent insertion into empty sockets enabled high quality digital intra-oral radiographs to be captured for possible comparison with AM dental X-rays.<sup>21, 22, 23,24</sup> Regardless of the lack of AM dental records or X-rays, relatives were able to provide precise dental information that proved most useful in distinguishing one victim from another as in case PM3 (Table 2).

Despite the help of an interpreter, the linguistic barrier hindered interviews of relatives and each interview required in excess two hours. These lengthy interviews involved the entire forensic team and interfered with collecting essential forensic



information. It is significant that information gathered from these interviews for example, anatomical features confirmed during autopsy, proved less

relevant for purposes of identification than had been predicted.

### Ascertainment of the cause of death

Many types of irritating or poisonous gases can result as products of fire combustions in industrial and domestic settings. Among these substances, carbon monoxide (CO) and cyanide (CN) prevail for chemical-toxicological importance,<sup>25</sup> and the literature clearly provides data about the concentrations of these substances in victims of fire.<sup>26,27</sup>

In the present case, the vast quantity of synthetic textile material, partially recovered in the building, and responsible for the extremely high temperatures reached during the fire, caused at the high amount of hydrogen cyanide and inorganic acids released, typical of the combustion of synthetic polymer.<sup>28</sup>

Toxicological analysis found values compatible with a lethal acute poisoning by carbon monoxide or cyanides, or by a combined action of the two substances.

All of the victims presented at least one sign of vital signs included in the literature in similar cases of death by fire.<sup>29,3</sup>

Protrusion of the tongue between the teeth, observed in charred corpses, is currently being discussed as a sign of vital burning. The exact physiological mechanism involved is still unknown and under discussion. Bernitz<sup>30</sup> attributed it to a reflex laryngospasm induced by air temperatures of  $>150^{\circ}\text{C}$  and hyperventilation or the heat-related shrinkage of the soft tissue of the neck.<sup>31</sup>

This latter mechanism seems to also be responsible for the intramuscular bleeding of the tongue found in victims of fire and especially associated with low levels of COHb,<sup>32</sup> which other authors have attributed, instead, to a possible acute hemodynamic disturbance in the head

including the brain (cranial congestion) during the process of dying by fire.<sup>33</sup> Some authors<sup>34, 3</sup> reported evidence supporting the value of this sign as an additional indicator of vitality; others criticize this assertion,<sup>35, 36</sup> highlighting the absence of a physio-pathological explanation thus supporting it as a "vitality sign".<sup>37</sup> A recent article<sup>38</sup> reported the finding of tongue protrusion in two bodies burnt after death and the protrusion of the tongue is described as a possible result of the genioglossus retraction due to heat.

All of the victims showed evident signs of vital burning and protrusion of the tongue between the teeth was detected in all the victims except for those whose skull was largely destroyed. However the evidence of tongue protrusion as a vital sign in this report is inconclusive.

The presence of blood in the extradural space, the retraction of the dura and brain of reduced dimensions was observed at autopsy in more than one victim. These findings are described in the literature as possible post-mortal phenomena in the case of exposure to prolonged heat affecting the head. Moreover the increased brittleness of the charred bone and the steam pressure within the skull can also be the cause of the fractures to the cranium<sup>39</sup> observed in two of the victims (PM3 and PM6). These features were observed in those victims with severe burning found together under the rubble of combustible material and consequently more exposed to prolonged higher temperatures. The two

victims found near the loft that was used as the dormitory area located in the right posterior area of the building demonstrated the maximum degree of burning and incineration. This area would correspond to the area where the fire broke out, most likely while the victims were asleep.

The autopsy and circumstantial findings suggested that the victims with the least

damage (PM1 and PM4), presumably realized the presence of fire, but could not escape. It was hypothesized that the security exits and the stairs for reaching the ground floor and the main door were obstructed by either material or by fire itself. Firefighters confirmed that the stairs were made of wood and located in the right posterior area of the building where the fire started. Data concerning the position of the bodies and the circumstantial details confirm the importance of accurate post mortem investigations for evidence-based reconstruction of fire scene and casualties<sup>40</sup>. It is significant that this evidence resulted useful during Court proceedings in establishing criminal and civil liability for both the factory owner and the employer of the victims, both parties being responsible for worker security and the surveillance of building security.

## **CONCLUSION**

The report is a typical multi-casualty case that implies procedures and deployment of DVI personnel similar to mass-disasters due to specific forensic issues and the judicial demands for timely and effective reports on the cause of death and the identification of victims. The disaster occurred inside the largest Chinese community in Italy and some specific difficulties affected the AM data collection and body recovery at the site of the fire.

Thanks to the deployment of a DVI team composed of specialists from different fields of expertise, certain procedural mishaps were avoided. This case provides some important and meaningful lessons:

**Site of disaster.** The intervention of non-forensic personnel including a forensic pathologist not qualified in DVI procedures produced mislabeling and cross-numbering of victims that resulted in a time-

consuming specific reconciliation process. It is probable that tiny but relevant body parts were not recovered or collected at the disaster site.

**Autopsy findings and toxicology analysis** support the conclusion that the death of the victims was caused by carbon monoxide and/or cyanides intoxication. Our data supports the conclusion that tongue protrusion co-exists with clear signs of vital burning, yet there is no compelling evidence to exclude tongue protrusion is a post-mortal phenomenon.

The collection of AM data from ethnic communities or from developing countries is challenging because of significant language barriers and the lack of AM data. Nonetheless, despite the bare minimum AM data available in this case, a systematic collection of PM data offered meaningful reconciliation of primary and secondary identifiers for all of the victims.

The activities at the scene of the fire as well as the findings from the PM examinations of the victims made a significant contribution to reconstruction of the circumstances of

the disaster and to the investigation by the public prosecutor.

This case supports the conclusion that the establishment of DVI teams, guidelines and regulations for recruitment/deployment of forensic experts who are acquainted with procedures, codes, forms and issues connected with DVI activity are an urgent necessity for Italy.

Table 1: Autopsy findings and primary identifiers for bodies; relevant circumstantial, autopsy and toxicological findings to ascertain cause of death.

BODY	POSITION ON THE DISASTER SITE	SEX (Morphological)	Sex (DNA)	EXTERNAL EXAMINATION: STATE OF THE BODY	AUTOPSY FINDINGS	TONGUE THRUST OUT/CLAMPED BETWEEN THE TEETH	DNA (sample)	FINGERPRINTS	ALCOHOL g/l	OTHER TOXIC SUBSTANCES or DRUGS	HbCO %	CYANIDES mcg/ml	CAUSE OF DEATH
PM 1	Anterior portion of the loft (not collapsed) near a window, closed by a gratin	Male	Male	complete, not charred; injury to head, vital injury to right hand	deformity of the distal phalanx of the second finger of the right hand; soot and food material into the trachea and larynx	Yes	Psoas muscle/buccal mucosa	Yes	0,46	no	48,68	8,85	acute cyanide poisoning
PM 2	right rear side of the shed, partially buried under the rubble of a collapsed loft	Male	Male	advanced carbonization, lower limbs missing	soot in the airway and esophagus, pulmonary edema, extradural blood	impossible to assess	Psoas muscle, blood/buccal mucosa	No	0,15	no	61,63	5,17	acute cyanide poisoning
PM 3	right rear side of the shed, partially buried under the rubble of a collapsed loft	Male	Male	advanced carbonization, incomplete, missing: upper right limb, left hand, lower right limb, left foot	soot in the airway, fracture of the skull, extradural blood, shrunk dura, reduced brain volume, pulmonary edema	impossible to assess	Blood, muscle/buccal mucosa	No	0,54	no	81,23	3,63	acute cyanide and carbon monoxide poisoning
PM 4	Right rear side of the shed, far from the others	Male	Male	advanced carbonization, complete	abundant soot in the airways, edema and redness of the larynx, pulmonary edema	Yes	Psoas muscle, blood/buccal mucosa	Yes	0,33	no	95,77	1,25	acute carbon monoxide poisoning
PM 5	right rear side of the shed, partially buried under the rubble of a collapsed loft	Female	Female	advanced carbonization, missing: upper and lower limbs, maxillary bones, teeth, splanchnocranium	absence of organs of the neck, presence of uterus	impossible to assess	Gluteal muscle, blood	No	0,71	no	94,4	0,93	acute carbon monoxide poisoning
PM 6	right rear side of the shed, partially buried under the rubble of a collapsed loft	Impossible to assess	Female	advanced carbonization: missing upper and lower limbs	soot in the airway and esophagus, fracture of the skull, exposure of the abdominal organs	Yes	Muscle, blood, costal bone/buccal mucosa	No	0,18	no	94,89	2,59	acute carbon monoxide poisoning
PM 7	right rear side of the shed, partially buried under the rubble of a collapsed loft	Male	Male	advanced carbonization: missing upper and lower limbs	soot in the airway and in the esophagus, extradural blood, shrunk dura, reduced brain volume	Impossible to assess	Psoas muscle and blood/buccal mucosa	No	0,42	no	88,05	0,29	acute carbon monoxide poisoning

Table 2: Identification sheet reporting comparison of AM and PM data

REPORT	DNA	FINGERPRINTS	DENTAL RECORDS (MATCH AM-PM)	SECONDARY MEANS OF IDENTIFICATION (MATCH AM-PM)	ID SUMMARY
PM1- AM3	Direct line relative	Yes	diastema of 0.5 mm between 13 and 14, and a missing tooth in the right upper jaw, both reported by relatives	deformity of the distal phalanx of the second finger of the right hand	DNA FINGERPRINTS DENTAL Secondary identifiers
PM2- AM7	1: 4,6 x E <sup>+12</sup>	-	finding of a pin in the tooth 22 in accordance with reported presence of gold crown in the left upper jaw	No inconsistencies, nothing relevant	DNA DENTAL
PM3- AM1	1: 9,8 x e <sup>+5</sup>	-	periapical bone loss – fistula involving 36 and 16, in agreement with recent reported intake of antibiotics for “teeth”. Endodontic therapy and metal-ceramic crown on central incisor (11), with pulp chamber compatible with a dental trauma occurred in child/adolescence.	No inconsistencies	DNA DENTAL
PM4- AM2	1:2,8 x e <sup>+6</sup>	Yes	lack of all third molar and cross bite of 22 with 32-33, compatible with reported retro position of upper incisor.	presence of dorsal nevus, reported by a relative	DNA FINGERPRINTS DENTAL Secondary identifiers
PM5- AM4	Direct line relative	-	Not possible because of the lack of PM dental data	gold necklace recognized by husband	DNA Secondary identifiers
PM6- AM6	Direct line relative	-	Not possible because of the absence of AM dental data	absence of the uterus, consistent with prior hysterectomy (reported by relatives)	DNA Secondary identifiers
PM7- AM5	1:7629	-	Not possible because of the absence of AM dental data	No inconsistencies	DNA

## REFERENCES

- 1 World Health Organization Health Action in Crises Injury and Violence Prevention Geneva 2007. Available from [http://www.who.int/hac/techguidance/tools/mcm\\_guidelines\\_en.pdf](http://www.who.int/hac/techguidance/tools/mcm_guidelines_en.pdf) access [cited 26 October 2015].
- 2 Police Decree of 6 April 2006, establishing the group of Mission DVI (Disaster Victim Identification)
- 3 Bohnert M, Werner CR, Pollak S. *Problems associated with the diagnosis of vitality in burned bodies. Forensic Sci Int* 2003 Aug 27;135(3):197-205. Available from: [http://dx.doi.org/10.1016/S0379-0738\(03\)00214-7](http://dx.doi.org/10.1016/S0379-0738(03)00214-7) [cited 1 September 2016]
- 4 Tümer AR, Akçan R, Karacaoğlu E, Balseven-Odabaşı A, Keten A, Kanburoğlu C, Unal M, Dinç AH. *Postmortem burning of the corpses following homicide. J Forensic Leg Med* 2012;19(4):223-8. Available from: <http://dx.doi.org/10.1016/j.jflm.2012.01.001> [cited 1 September 2016]
- 5 Lain R, Taylor J, Croker S, Craig P, Graham J. *Comparative dental anatomy in Disaster Victim Identification: Lessons from the 2009 Victorian Bushfires. Forensic Sci Int* 2011 25;205(1-3):36-9. Available from: <http://dx.doi.org/10.1016/j.forsciint.2010.06.008> [cited 1 September 2016]
- 6 Disaster victim identification guide: INTERPOL 2009.
- 7 Sweet D. *INTERPOL DVI best-practice standards--An overview. Forensic Sci Int* 2010 10;201(1-3):18-21. Available from: <http://dx.doi.org/10.1016/j.forsciint.2010.02.031> [cited 1 September 2016]
- 8 Hill AJ, Lain R, Hewson I. *Preservation of dental evidence following exposure to high temperatures. Forensic Sci Int* 2011 25;205(1-3):40-3. Available from: <http://dx.doi.org/10.1016/j.forsciint.2010.08.011> [cited 1 September 2016]
- 9 Focardi M, Gualco B, Norelli GA. *Accidental death in autoerotic maneuvers. Am J Forensic Med Pathol* 2008;29(1):64-8. Available from: DOI: 10.1097/PAF.0b013e3181651b79 [cited 1 September 2016]
- 10 Focardi M, Pinchi V, Defraia B, Norelli GA. *An unusual case of incaprettamento. Am J Forensic Med Pathol* 2014 Jun;35(2):83-5. doi: 10.1097/PAF.0000000000000074.
- 11 <http://www.interpol.int/INTERPOL-expertise/Forensics/DVI-Pages/Forms>
- 12 [www.isfg.org](http://www.isfg.org) [cited 24 July 2016]
- 13 ENFSI-ENFSI document on DNA-database management 2011.
- 14 Pinchi V, Torricelli F, Nutini AL, Conti M, Iozzi S, Norelli GA. *Techniques of dental DNA extraction: Some operative experiences. Forensic Sci Int* 2011 Jan 30;204(1-3):111-4. Available from: <http://dx.doi.org/10.1016/j.forsciint.2010.05.010> [cited 1 September 2016]
- 15 Pinchi V, Focardi M, Martinelli D, Norelli GA, Carboni I, Gozzini A, Romolini C, Torricelli F, Ricci U. *DNA extraction method from teeth using QIACube. Forensic Sci Int. Genetic supplement series* 2013 4;1:276-277. Available from: <http://dx.doi.org/10.1016/j.fsigss.2013.10.141> [cited 1 September 2016]
- 16 Egeland, Thore; Mostad, Petter: "Statistical Genetics and Genetical Statistics: a Forensic Perspective". *Scand Journal of Statistics*, 2002 Vol. 29. Available from: <http://www.jstor.org/stable/4616716> [cited 1 September 2016]
- 17 Ricci U, Carboni I, Iozzi S, Nutini AL, Contini E, Torricelli F, Focardi M, Pinchi V, Mari F, Norelli GA. *Genetic identification of burned corpses as a part of disaster victim identification effort, Forensic Sci Int. Genetic Supplement* Available from: doi:10.1016/j.fsigss.2015.09.177 [cited 1 September 2016]
- 18 Gjertson DW, Brenner CH, Baur MP, Carracedo A, Guidet F, Luque JA, Lessig R, Mayr WR, Pascali VL, Prinz M, Schneider PM, Morling N. 'ISFG: Recommendations on biostatistics in paternity testing', *Forensic Sci Int Genetics* 2007 1(3), 223-231. Available from: <http://dx.doi.org/10.1016/j.fsigen.2007.06.006> [cited 1 September 2016]
- 19 Bassed R. *Identification of Severely Incinerated Human Remains: The need for a cooperative approach between forensic specialities. Med Sci Law* October 2003;43,4:356-361. Available from: doi: 10.1258/rsmmmsl.43.4.356 [cited 1 September 2016]
- 20 Valenzuela A, Martin-de las Heras S, Marques T, Exposito N, Bohoyo JM. *The application of dental methods of identification to human burn victims in a mass disaster. Int J Legal Med* 2000;113(4):236-9. Available from: <http://hera.ugr.es/doi/15017072.pdf> [cited 1 September 2016]
- 21 Pinchi V, Norelli GA, Caputi F, Fassina G, Pradella F, Vincenti C. *Dental identification by comparison of antemortem and postmortem dental radiographs: influence of operator qualifications and cognitive bias. Forensic Sci Int* 2012 Oct 10;222(1-3):252-5. Available from: <http://dx.doi.org/10.1016/j.forsciint.2012.06.015> [cited 1 September 2016]
- 22 Pinchi V, Zei G. *Two positive identifications assessed with occasional dental findings on non-dental x-rays. J Forensic Odontostomatol* 2008 Dec 1;26(2):34-8. Available from: <http://www.iofos.eu/Journals/JFOS%20Dec08/PINCHI%20FINAL.pdf> [cited 1 September 2016]
- 23 Pinchi V, Forestieri AL, Calvitti M. *Thickness of the dental (radicular) cementum: a parameter for estimating age. J Forensic Odontostomatol*. 2007 Jun;25(1):1-6. Available from: <http://www.iofos.eu/Journals/JFOS%20Jun07/Pinchi%20et%20al%20article.pdf> [cited 1 September 2016]
- 24 Pinchi V, Pradella F, Buti J, Baldinotti C, Focardi M, Norelli GA. *A new age estimation procedure based on the 3D CBCT study of the pulp cavity and hard tissues of the teeth for forensic purposes: A pilot study. J Forensic Leg Med*. 2015 Nov;36:150-7. doi: 10.1016/j.jflm.2015.09.015. Epub 2015 Sep 30.
- 25 Yeoh MJ, Braitberg G. *Carbon monoxide and cyanide poisoning in fire related deaths in Victoria, Australia. J Toxicol Clin Toxicol* 2004;42(6):855-63. Available from: <http://dx.doi.org/10.1081/CLT-200035211> [cited 1 September 2016]
- 26 Teige B. et al. *Carboxyhemoglobin concentrations in fire victims and in cases of fatal carbon monoxide poisoning Z.Rechtsmedizin* 1977; 80:17-21.
- 27 Anderson RA et al. *Fire deaths in the Glasgow area: II the role of carbon monoxide Med. Sci. Law* 1981;21: 288-294.. Available from: doi: 10.1177/002580248102100407 [cited 1 September 2016]
- 28 Alarie Y. *Toxicity of fire smoke Crit Rev Toxicol* 2002 Jul;32(4):259-89. Available from: <http://dx.doi.org/10.1080/20024091064246> [cited 1 September 2016]
- 29 Gerling I, Meissner C, Reiter A, Oehmichen M. *Death from thermal effects and burns. Forensic Sci Int* 2001 Jan 1;115(1-2):33-41. Available from: [http://dx.doi.org/10.1016/S0379-0738\(00\)00302-9](http://dx.doi.org/10.1016/S0379-0738(00)00302-9) [cited 1 September 2016]

**Multiple deaths caused by a fire in a factory: identification and investigative issues.** *Pinchi et al.*

- 30 Bernitz H, Vann Staden PJ, Cronjé CM, Sutherland R. *Tongue protrusion as an indicator of vital burning* *Int J Legal Med* 2014;128:309–312. Available from: DOI: [10.1007/s00414-013-0861-4](https://doi.org/10.1007/s00414-013-0861-4) [cited 1 September 2016]
- 31 Bohnert M. *Injury: burns, scalds, and chemical*. *Wiley encyclopaedia of forensic science*. Chichester: John Wiley & Sons; 2009. Available from: DOI: [10.1002/9780470061589.fsa048](https://doi.org/10.1002/9780470061589.fsa048) [cited 1 September 2016]
- 32 Hashimoto Y, Moriya F, Nakanishi A. *Intramuscular bleeding of the tongue in the victims of house fire*. *Leg Med (Tokyo)* 2003 Mar;5 Suppl 1:328-331. Available from: [http://dx.doi.org/10.1016/S1344-6223\(02\)00163-3](http://dx.doi.org/10.1016/S1344-6223(02)00163-3) [cited 1 September 2016]
- 33 Quan L, Zhu BL, Ishida K, Oritani S, Taniguchi M, Kamikodai Y, Tsuda K, Fujita MQ, Maeda H. *Hemorrhages in the root of the tongue in fire fatalities: the incidence and diagnostic value*. *Leg Med (Tokyo)* 2003 Mar;5 Suppl 1:332-334. Available from: [http://dx.doi.org/10.1016/S1344-6223\(02\)00164-5](http://dx.doi.org/10.1016/S1344-6223(02)00164-5) [cited 1 September 2016]
- 34 Hejna P, Janík M. *Comments on Tongue protrusion as an indicator of vital burning*. *Int J Legal Med* 2014 Mar;128(2):321-2. Available from: DOI: [10.1007/s00414-013-0931-7](https://doi.org/10.1007/s00414-013-0931-7) [cited 1 September 2016]
- 35 Madea B, Doberentz E. *Protrusion of the tongue in burned bodies as a vital sign? Letter to the editor concerning the paper "Tongue protrusion as an indicator of vital burning" by Bernitz et al.* *Int J Legal Med* 2015 Mar;129(2):313-4. Available from: DOI: [10.1007/s00414-014-1019-8](https://doi.org/10.1007/s00414-014-1019-8) [cited 1 September 2016]
- 36 Nikolić S, Živković V. *Regarding the tongue protrusion as an indicator of vital burning. Much ado about nothing*. *Int J Legal Med*. 2015 Mar;129(2):315-6. doi: [10.1007/s00414-014-1062-5](https://doi.org/10.1007/s00414-014-1062-5). Epub 2014 Aug 19. Available from: DOI: [10.1007/s00414-014-1062-5](https://doi.org/10.1007/s00414-014-1062-5) [cited 1 September 2016]
- 37 Bohnert M. *Protrusion of the tongue in burned bodies as a vital sign?* *Int J Legal Med* 2014;128:317. Available from: DOI: [10.1007/s00414-014-1019-8](https://doi.org/10.1007/s00414-014-1019-8) [cited 1 September 2016]
- 38 Nikolić S, Živković V. *Protrusion of the tongue in bodies burned after death: Two cases of arson to cover homicide*. *Med Sci Law* 2015 Oct;55(4):300-3. doi: [10.1177/0025802414542260](https://doi.org/10.1177/0025802414542260). Available from: doi: [10.1177/0025802414542260](https://doi.org/10.1177/0025802414542260) [cited 1 September 2016]
- 39 Bohnert M, Rost T, Faller-Marquardt M, Ropohl D, Pollak S. *Fractures of the base of the skull in charred bodies--post-mortem heat injuries or signs of mechanical traumatization?* *Forensic Sci Int* 1997 May 23;87(1):55-62. Available from: [http://dx.doi.org/10.1016/S0379-0738\(97\)02136-1](http://dx.doi.org/10.1016/S0379-0738(97)02136-1) [cited 1 September 2016]
- 40 Michiue T, Ishikawa T, Oritani S, Maeda H. *Contribution of forensic autopsy to scene reconstruction in mass fire casualties: a case of alleged arson on a floor consisting of small compartments in a building*. *Leg Med (Tokyo)* 2015 Jan;17(1):43-7. Available from: <http://dx.doi.org/10.1016/j.legalmed.2014.09.004> [cited 1 September 2016]

\*\*\*\*\*