

Correlation between ultrasonic features and expression levels of C-erbB-2, VEGF and nm23 in breast cancer

MIN NIE^{1,2}, YONGCHUN QIN², JIAFENG ZHU², YANZHI LI³ and ZHIBIN WANG¹

¹Department of Medical Imaging, The Affiliated Hospital of Qingdao University, Qingdao, Shandong 266001;

²Department of Medical Imaging, People's Hospital of Rizhao, Rizhao, Shandong 276800;

³ICU, People's Hospital of Zhangqiu, Jinan, Shandong 250000, P.R. China

Received October 30, 2017; Accepted May 9, 2018

DOI: 10.3892/ol.2018.8777

Abstract. Breast cancer is one of the most common female malignancies in clinical practice, which ranks number one in terms of its high incidence. We investigated the relevance of ultrasonic features of breast cancer and expression levels of C-erbB-2, vascular endothelial growth factor (VEGF) and nm23 and its clinical significance. A total of 76 patients with breast cancer were recruited who were admitted to The Affiliated Hospital of Qingdao University from January, 2016 to August, 2017. All patients underwent color Doppler ultrasonic imaging, and expression levels of C-erbB-2, VEGF and nm23 in their tumor tissues were measured by immunohistochemistry. The ultrasonic features were evaluated and compared with the expression levels of C-erbB-2, VEGF and nm23 for each patient. Ultrasonography showed a tumor mass with spiculated margins, abnormal vasculature, and a diameter no less than 3 cm, as well as lymph node metastasis. The above signs were associated with high expression of C-erbB-2, VEGF and nm23 ($p < 0.05$), but calcification was not associated with high expression of these biomarkers ($p > 0.05$). For patients with highly expressed C-erbB-2 and VEGF, the time to peak (TTP) of the time-intensity curve obtained by contrast enhanced ultrasound was shorter, while the peak intensity (PI) was higher. On the contrary, for patients with highly expressed nm23, the TTP was apparently longer, while the PI was lower ($p < 0.05$). The ultrasonic features of breast cancer were relevant to the expression levels of C-erbB-2, VEGF and nm23. Thus, the expression levels of C-erbB-2, VEGF and nm23 were predictable indirectly according to the ultrasonic features of the patient, which can be used as a reference for breast cancer treatment and prognosis prediction.

Introduction

Breast cancer is one of the most common female malignancies in clinical practice, which ranks number one in terms of its high incidence (1). The clinical symptoms of breast cancer mainly include non-gestational nipple discharge, nipple and/or areola abnormalities, breast lumps, enlarged axillary lymph nodes, and skin changes (2). At present, ultrasound is a major tool for diagnosing breast cancer, and has been widely used in clinic (3). Clinical treatments of breast cancer include surgery, chemotherapy, radiation, targeted and traditional Chinese medicine adjuvant therapy. Surgery is the most commonly used treatment, and a radical mastectomy is the preferred type of surgery (4). The C-erbB-2 protein is a member of the epidermal growth factor receptor family, which is closely associated with onset and progression of breast cancer (5). Vascular endothelial growth factor (VEGF) is a growth factor of vascular endothelial cells that promotes the growth of new blood vessels, and it plays a major role in invasion and metastasis of breast cancer (6). The nm23 gene is a tumor suppressor gene, and is associated with inhibition of metastasis in many tumors, such as hepatocellular carcinoma, melanoma, breast cancer and gastric cancer. Patients with breast cancer who were diagnosed early and underwent effective treatments usually have a good prognosis, but those with advanced breast cancer still have a poor prognosis. So, early screening of breast cancer is of great clinical significance (7). In this study, ultrasonography was performed for patients with breast cancer, and the expression levels of C-erbB-2, VEGF and nm23 were measured, in order to explore the relevance of ultrasonic features of breast cancer to expression levels of C-erbB-2, VEGF and nm23. The results may serve as a reference for diagnosis and treatment of breast cancer.

Materials and methods

Subjects. A total of 76 patients with breast cancer were enrolled in this study who were admitted to The Affiliated Hospital of Qingdao University (Qingdao, China) from January, 2016 to August, 2017. Inclusion criteria included patients meeting the diagnostic criteria (female patients, Han ethnicity) for breast cancer (8), undergoing ultrasound examination, without mental disorders, and were not previously treated with surgery,

Correspondence to: Dr Zhibin Wang, Department of Medical Imaging, The Affiliated Hospital of Qingdao University, 16 Jiangsu Road, Qingdao, Shandong 266001, P.R. China
E-mail: wibaxa81@163.com

Key words: vascular endothelial growth factor, nm23, ultrasound, breast cancer, C-erbB-2

radiotherapy and chemotherapy. Exclusion criteria excluded patients during pregnancy, with moderate to severe anemia, during menstrual cycle or with unexplained vaginal bleeding, and previously treated with drugs and surgery.

This study was approved by the Ethics Committee of the Affiliated Hospital of Qingdao University and informed consents were signed by the patients or guardians.

Ultrasonography. All patients underwent ultrasound examination of the whole breasts and the axilla area with a Philips iU22 Color Doppler Ultrasound System (The Philips Foundation, Amsterdam, The Netherlands) at a probe frequency of 7.5-12.0 MHz. Patients lay down in a supine position with the hands up. The probe scanned an area with the nipple, the lower edge of the breast, and the axilla on the boundary. The cancer lesion was checked for its morphology, size, margins, echogenicity, presence of calcification, and blood flow signal. Axillary lymph nodes were also checked for accompanied enlargement. SonoVue was used as the contrast agent (registration no. H20080059; Bracco SpA, Milan, Italy). The ultrasound probe was positioned on the region of interest, followed by injection of the contrast agent through the peripheral vein. Time was recorded from the point of injection. When the contrast agent passed the imaging window, a sector scan was performed slowly on the lesion, and the contrast-enhanced ultrasound images were stored continuously for about 3 min (Table I).

Measurement of expression levels of C-erbB-2, VEGF and nm23. The expression levels of C-erbB-2, VEGF and nm23 in tumor tissues were measured by immunohistochemistry (IHC). Rabbit anti-human VEGF polyclonal antibody was purchased from Beijing Bioss Biotechnology Co., Ltd. (Beijing, China). Rabbit anti-human C-erbB-2 polyclonal antibody and mouse anti-human nm23 monoclonal antibody were all purchased from Fuzhou Maixin Biotechnology Co., Ltd. (Fuzhou, China). The paraffin-embedded tumor tissue was cut into 4 μ m sections using a microtome (Leica Microsystems GmbH, Wetzlar, Germany). The slides with paraffin sections were baked overnight in an incubator (Shanghai Medical Instrument Co., Ltd., Shanghai, China) at 60°C. With xylene dewaxed, the slides were put in ethanol of 100, 95, 80, and 75% in this order for 10 min each, followed by a soak in distilled water for 5 min. Endogenous peroxidases were inactivated by adding 3% hydrogen peroxide solution 50 μ l and incubation at 20°C for 10 min. After washing with PBS 3 times (5 min each), the primary antibody 50 μ l was added, followed by incubation at 4°C overnight. The secondary antibody was added, incubation at 20°C for 10 min, followed by DAB staining (DAB kit was purchased from Beijing Zhongshan Golden Bridge Biotechnology Co., Ltd., Beijing, China). The staining progress was monitored under a microscope (Olympus Corporation, Tokyo, Japan). After staining, the slides were washed with distilled water to terminate staining. After counterstaining with hematoxylin for 2 min, the slides were mounted with natural balsam.

Evaluation indicators. Two senior ultrasound specialists performed the double-blind diagnostic imaging examinations. Based on the ultrasonic features, patients were divided into the following groups: Group with tumor diameter \geq 3 cm and

Table I. General information.

Items	Subjects (n=76)
Age range (years)	25-65
Average age (years)	43.72 \pm 5.73
BMI (kg/m ³)	21.67 \pm 1.31
Mean tumor diameter (cm)	3.06 \pm 1.73
The average diameter	
Clinical stage (n,%)	
I	12 (15.79)
IIA	19 (6.32)
Beyond IIA	45 (59.21)
Category (n,%)	
Familial	9 (11.84)
Sporadic	67 (88.16)
Ultrasound signs (n,%)	
Burr	49 (64.47)
Abnormal vascular	48 (63.16)
Lymphatic metastasis	32 (42.11)
Calcification	33 (43.42)
BMI, body mass index.	

group with tumor diameter <3 cm; group with spiculated tumor mass and group with non-spiculated tumor mass; group with abnormal tumor vascularity and group without abnormal tumor vascularity; group with lymph node metastasis and group without lymph node metastasis; group with calcification and group without calcification. The ultrasonography time-intensity curve (TIC) was recorded. Relevant parameters include the time to peak (TTP) and the peak intensity (PI). TTP is the time between start of contrast signal and PI on the region of interest. PI is the maximum signal intensity on region of interest.

The expression levels of C-erbB-2, VEGF and nm23 in breast cancer tissues were measured by IHC. Five fields of view of high magnification, x400 were randomly selected from each slide. Brownish yellow cells were regarded as positive expression of C-erbB-2 and VEGF. The percentage of positive cells was calculated and a score (PP) was given according to the percentage. A PP score of 0, 1, 2 and 3 points was given if the percentage of positive cells was 0, <5, >5 but \leq 20 and >20%, respectively. Apart from the PP scores, the intensity of staining was scored as well (SI). An SI score of 0, 1, 2 and 3 points were given if the nuclei color was colorless, light yellow, brown and dark brown, respectively. An immunoreactivity score (IRS) was calculated by the product of the percentage of positive cells (PP score) and the intensity of staining (SI score): IRS=PP x SI. IRS >4 was defined as high expression, whereas IRS \leq 4 was defined as low expression (9). Expression of nm23 was observed in cytoplasm, according to SI score: \geq 2 represented high expression, while <2 represented low expression.

Statistical analysis. Data were processed using SPSS 19.0 software (SPSS, Inc., Chicago, IL, USA). Measurement data are expressed as mean \pm standard deviation (SD) using t-test.

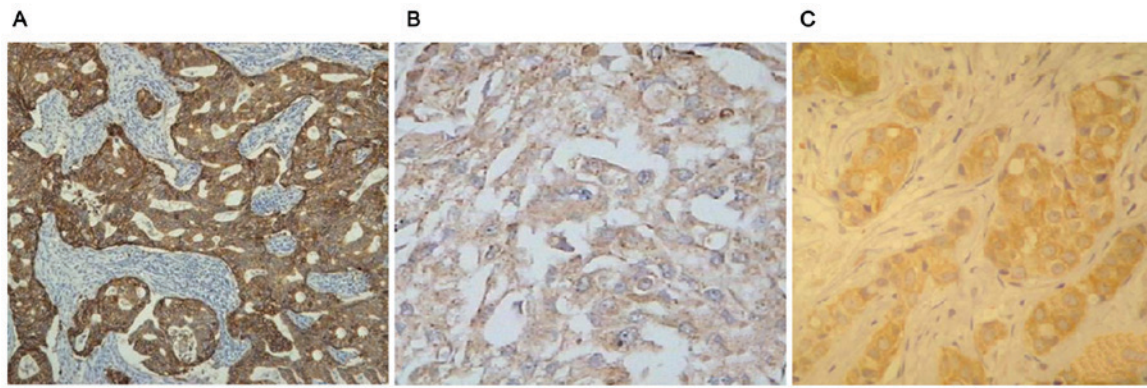


Figure 1. IHC images of breast cancer. (A) C-erbB-2 positive in breast cancer tissues (x400). (B) VEGF positive in breast cancer tissues (x400). (C) nm23 positive in breast cancer tissues (x400). IHC, immunohistochemistry; VEGF, vascular endothelial growth factor.

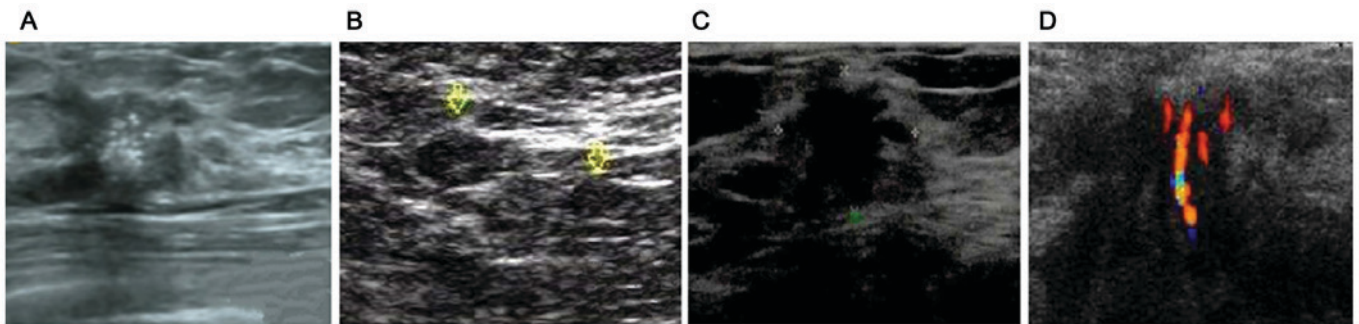


Figure 2. Typical ultrasound image in breast cancer. (A) Calcification sign. (B) Lymphatic metastasis sign. (C) Burr sign. (D) Abnormal vascular sign.

Table II. Comparison of accuracy of ultrasonic examinations and pathological examinations in the diagnosis of breast cancer (n, %).

Methods	Diagnosis (%)	Misdiagnosis (%)	Error diagnosis (%)	Accuracy (%)
Pathological examinations	76 (100.00)	0 (0.00)	0 (0.00)	76 (100.00)
Enhanced CT	72 (94.47)	2 (2.63)	2 (2.63)	72 (94.47)
χ^2				2.311
p-value				0.129

CT, computed tomography.

Enumeration data are expressed as a number or percentage (%) using χ^2 test. Pearson's analysis was used for correlation of C-erbB-2, VEGF and nm23 expression. Difference was statistically significant at $p < 0.05$.

Results

Positive expression of C-erbB-2, VEGF and nm23 was observed in patients with breast cancer (Fig. 1A-C). Ultrasound examination showed different signs of breast cancer, including burr sign, abnormal vascular sign, lymphatic metastasis sign and calcification sign (Fig. 2A-D).

Analysis of accuracy of ultrasonic examinations in the diagnosis of breast cancer. There was no significant differences

in the accuracy of diagnosis of breast cancer between the two methods ($p > 0.05$) (Table II).

Relevance of tumor characteristics of ultrasonic signs to expression levels of C-erbB-2, VEGF and nm23. Apparently, the high expression rates of C-erbB-2 and VEGF in the group with tumor diameter ≥ 3 cm were higher than those in the group with tumor diameter < 3 cm, whereas the high expression rate of nm23 was higher in the group with tumor diameter < 3 cm. ($p < 0.05$) (Table III).

The high expression rates of C-erbB-2 and VEGF were higher in the group with spiculated tumor margins than those in the group with non-spiculated tumor margins, whereas the high expression rate of nm23 was higher in the group with non-spiculated tumor margins ($p < 0.05$) (Table IV). The high

Table III. Correlation between tumor diameter and high expression rates of C-erbB-2, VEGF and nm23 (n, %).

Groups	Cases	C-erbB-2 high expression	VEGF high expression	nm23 high expression
Tumor diameter ≥ 3 cm	41	40 (97.56)	39 (97.56)	22 (53.66)
Tumor diameter < 3 cm	35	19 (54.29)	19 (54.29)	34 (97.14)
χ^2		17.947	15.234	16.238
p-value		< 0.001	< 0.001	< 0.001

VEGF, vascular endothelial growth factor.

Table IV. Correlation between spiculated tumor margins and high expression rates of C-erbB-2, VEGF and nm23 (n, %).

Groups	Cases	C-erbB-2 high expression	VEGF high expression	nm23 high expression
Spiculated tumor margins	49	43 (87.76)	42 (85.71)	21 (42.86)
Non-spiculated tumor margins	27	16 (59.25)	16 (59.25)	25 (92.59)
χ^2		6.582	5.356	16.001
p-value		0.010	0.021	< 0.001

Table V. Correlation between abnormal tumor vascularity and high expression rates of C-erbB-2, VEGF and nm23 (n, %).

Groups	Cases	C-erbB-2 high expression	VEGF high expression	nm23 high expression
Abnormal tumor vascularity	48	43 (89.58)	42 (87.50)	22 (45.83)
Without abnormal tumor vascularity	28	16 (57.14)	16 (57.14)	24 (85.71)
χ^2		8.931	7.451	10.162
p-value		0.003	0.007	0.001

Table VI. Correlation between lymph node metastasis and high expression rates of C-erbB-2, VEGF and nm23 (n, %).

Groups	Cases	C-erbB-2 high expression	VEGF high expression	nm23 high expression
Lymph node metastasis	30	30 (100.00)	30 (100.00)	11 (34.38)
Without lymph node metastasis	46	37 (80.43)	26 (56.52)	45 (97.83)
χ^2		15.304	16.500	35.664
p-value		< 0.001	< 0.001	< 0.001

VEGF, vascular endothelial growth factor.

expression rates of C-erbB-2 and VEGF were higher in the group with abnormal tumor vascularity than those in the group without abnormal tumor vascularity, whereas the high expression rate of nm23 was higher in the group without abnormal tumor vascularity ($p < 0.05$) (Table V).

The high expression rates of C-erbB-2 and VEGF were higher in the group with lymph node metastasis than those in the group without lymph node metastasis, whereas the high expression rate of nm23 was higher in the group without

lymph node metastasis ($p < 0.05$) (Table VI). There was no significant difference in the high expression rates of C-erbB-2, VEGF and nm23 between the group with calcification and the group without calcification ($p > 0.05$) (Table VII).

Comparison of TIC parameters in different expression levels of C-erbB-2, VEGF and nm23. The TTP was shorter in patients with high C-erbB-2, high VEGF and low nm23 expression, the corresponding PI was higher ($p < 0.05$) (Tables VIII, IX and X).

Table VII. Correlation between calcification and high expression rates of C-erbB-2, VEGF and nm23 (n, %).

Groups	Cases	C-erbB-2 high expression	VEGF high expression	nm23 high expression
Calcification	31	21 (63.64)	21 (63.64)	23 (69.70)
Without calcification	45	38 (84.44)	37 (82.22)	33 (73.33)
χ^2		3.416	2.543	0.009
p-value		0.064	0.111	0.922

VEGF, vascular endothelial growth factor.

Table VIII. Correlation between TIC parameters and expression level of C-erbB-2.

Groups	Cases	TTP (sec)	PI (dB)
C-erbB-2 high expression	59	6.25±2.04	3.57±0.75
C-erbB-2 low expression	17	9.56±2.52	1.69±0.46
t-value		5.585	9.790
p-value		<0.001	<0.001

TTP, time to peak; PI, peak intensity; TIC, time-intensity curve.

Table IX. Correlation between TIC parameters and expression level of VEGF.

Group	Cases	TTP (sec)	PI (dB)
VEGF high expression	58	6.23±2.03	3.57±0.73
VEGF low expression	18	9.54±2.54	1.64±0.47
t-value		5.685	10.533
p-value		<0.001	<0.001

VEGF, vascular endothelial growth factor; TTP, time to peak; PI, peak intensity; TIC, time-intensity curve.

Correlation analysis of C-erbB-2, VEGF and nm23 expression. Pearson's correlation analysis showed that there was a positive correlation between C-erbB-2 and VEGF, VEGF and nm23, nm23 and C-erbB-2 ($r=0.463, 0.452, 0.478, P<0.05$) (Fig. 3).

Discussion

Breast cancer is the most common cancer among women, which affects women's physical health as well as their psychological well-being in a negative way. According to statistical analysis, breast cancer incidence can be as high as 25%. The current incidence in China is still low, but with the development of China's society, it has been increasing at a higher rate than in developed countries (10). Breast cancer ranks the highest in incidence of cancers diagnosed among Chinese women. The incidence varies between urban and rural areas in China, which is higher in urban areas than that in rural areas. The pathogenesis of breast cancer is currently still under debate. There is consensus that onset and progression of breast cancer

Table X. Correlation between TIC parameters and expression level of nm23.

Groups	Cases	TTP (sec)	PI (dB)
nm23 high expression	56	9.57±2.52	1.97±0.32
nm23 low expression	20	6.26±2.04	2.79±0.58
t-value		5.281	6.005
p-value		<0.001	<0.001

TIC, time-intensity curve.

results from multi-step synergies of various factors, involving mutation and proliferation of tumor cells, infiltration of the basement membrane, inactivation of tumor suppressor genes, and imbalance of protease secretion (11). High risk factors of breast cancer may include: Age, family history, unmarried late pregnancy, early menarche, late menopause, frequent chest X-rays, excessive drinking, long-term use of contraceptives, abortion and inhibition of breastfeeding (12). Early breast cancer symptoms are invisible and not noticeable without a professional screening, thus the disease is easily overlooked and missed. It can slow down deterioration of breast cancer to a certain extent and reduce mortality if early screening is performed and patients receive comprehensive treatments (13).

With continuous improvement of ultrasound technology, color Doppler ultrasound has become one of the most important diagnostic methods for breast cancer. The morphology, size and blood flow of tumor mass can be clearly viewed, thus it provides a reliable way to effectively distinguish benign and malignant tumors (14). The C-erbB-2 is an oncogene that indicates tumor prognosis (15). VEGF is one of the most potent and specific angiogenic factors, and it belongs to the family of platelet-derived growth factors, including VEGF-A (namely VEGF), VEGF-B, VEGF-C and VEGF-D. VEGF-A stimulates the vascular endothelial cells, promoting its division and proliferation, and ultimately forming new blood vessels. VEGF-B can promote vascular endothelial growth and migration, tumor growth and metastasis. VEGF-C and VEGF-D can promote lymphangiogenesis and thus promote lymphatic metastasis of tumors. VEGF is highly expressed in many kinds of tumor tissues (16,17). The nm23 gene is a tumor suppressor gene. It was first found in an animal experiment that the nm23 gene can inhibit tumor growth and metastasis (18). The results in this study showed that tumor diameter ≥ 3 cm, spiculated tumor

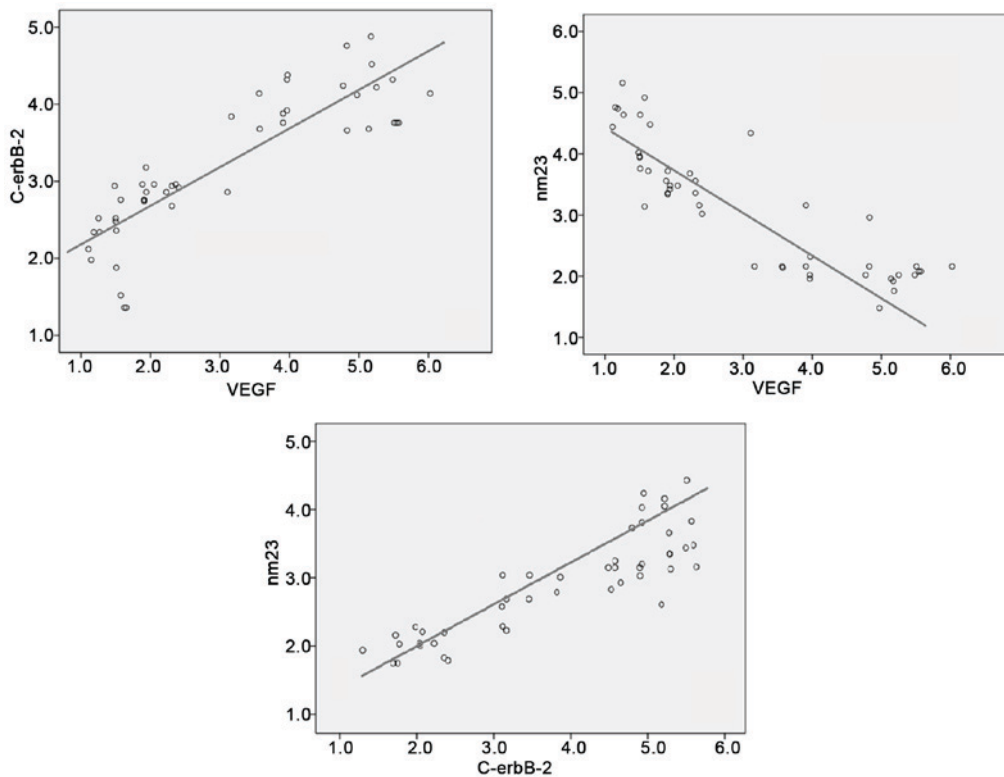


Figure 3. Correlation analysis of C-erbB-2, VEGF and nm23 expression. VEGF, vascular endothelial growth factor.

margin, lymph node metastasis and abnormal tumor vascularity were all associated with higher expression of C-erbB-2 and VEGF and lower expression of nm23 ($p < 0.05$). There were no significant differences in expression of C-erbB-2, VEGF and nm23 between tumor with calcification and tumor without calcification ($p > 0.05$). Thus, bigger tumor size, spiculated tumor margins, lymph node metastasis and abnormal tumor vascularity were specific ultrasonic features of breast cancer. Under pathological conditions, activation of C-erbB-2 led to expression of VEGF activity. The balance between angiogenic factors and inhibitory factors was broken, which promoted microvascular formation, leading to uncontrollable vascular endothelial cell proliferation. As indicators, expression levels of C-erbB-2 and VEGF measured by IHC were high. As tumor advanced and grew bigger, expression of nm23 was hindered. Especially in the lymph nodes metastasis, the expression level of nm23 was significantly low.

Tumor onset, progression and metastasis all rely on microvascular formation. Recently, there have been continual advances in ultrasound technology. Currently ultrasound imaging is widely used in clinical diagnosis of various cancers due to merits such as convenience, no radiation exposure and good reproducibility in evaluation of tumor microvascular network. Ultrasound is especially highly sensitive in assessing tumor blood flow. Tumor blood flow pattern can be quantified by analyzing TTP and PI from the TIC, which may help improve cancer diagnosis (19). The results in this study showed that the TTP of patients with high expression of C-erbB-2 and VEGF was shorter than that of patients with low expression of C-erbB-2 and VEGF, and the corresponding PI was higher. On the contrary, the TTP of patients with high expression of nm23 was longer than that of patients with low expression of nm23,

and the corresponding PI was lower ($p < 0.05$). Tumor was in continual progression when expression levels of C-erbB-2 and VEGF were high. At this stage, cancer cell proliferation was fast, and the tumor mass became larger, leading to lymphatic and hematogenous metastasis. In tumor tissue, blood supply was abundant, and blood flow was fast as well, thus the average blood volume was large, leading to high PI in the contrast-enhanced ultrasound imaging. When nm23 expression level was high, tumor cells were well differentiated, and were less likely to spread to lymph nodes. At this stage, the tumor blood flow was slow, leading to low PI in the contrast-enhanced ultrasound imaging. When nm23 expression level became low, suppression of tumor metastasis was compromised, which promoted onset and progression of breast cancer (20).

In summary, ultrasound can show morphological changes in breast cancer. The ultrasound features and blood flow parameters were closely associated with expression levels of C-erbB-2, VEGF and nm23. Their correlations can serve as a reference for diagnosis and prognosis of breast cancer.

Acknowledgements

Not applicable.

Funding

No funding was received.

Availability of data and materials

The datasets used and/or analyzed during the current study are available from the corresponding author on reasonable request.

Authors' contributions

MN analyzed and interpreted the patient data, and was a major contributor in writing the manuscript. YQ participated in the analysis and discussion of the data. JZ is responsible for the collection of the data and the follow-up management of the patients. YL participated in the experiment and data collection. ZW was a major contributor in designing the methods. All authors read and approved the final manuscript.

Ethics approval and consent to participate

This study was approved by the Ethics Committee of The Affiliated Hospital of Qingdao University (Qingdao, China). Signed informed consents were obtained from the patients or guardians.

Consent for publication

Not applicable.

Competing interests

The authors declare that they have no competing interests.

References

- Shenouda MN, Sadek BT, Goldberg SI, Keruakous AR, Croft BJ, Abi Raad RF and Taghian AG: Clinical outcome of isolated locoregional recurrence in patients with breast cancer according to their primary local treatment. *Clin Breast Cancer* 14: 198-204, 2014.
- Akahane K, Tsunoda N, Murata T, Fujii M, Fuwa Y, Wada K, Oda K and Nagino M: An awareness survey of surgeons involved in breast cancer treatment regarding their patients returning to work. *Nagoya J Med Sci* 76: 315-322, 2014.
- Barnard ME, Boeke CE and Tamimi RM: Established breast cancer risk factors and risk of intrinsic tumor subtypes. *Biochim Biophys Acta* 1856: 73-85, 2015.
- Acil H and Cavdar I: Comparison of quality of life of Turkish breast cancer patients receiving breast conserving surgery or modified radical mastectomy. *Asian Pac J Cancer Prev* 15: 5377-5381, 2014.
- Singleton TP, Perrone T, Oakley G, Niehans GA, Carson L, Cha SS and Strickler JG: Activation of c-erbB-2 and prognosis in ovarian carcinoma. Comparison with histologic type, grade, and stage. *Cancer* 73: 1460-1466, 1994.
- Zhao D, Pan C, Sun J, Gilbert C, Drews-Elger K, Azzam DJ, Picon-Ruiz M, Kim M, Ullmer W, El-Ashry D, *et al*: VEGF drives cancer-initiating stem cells through VEGFR-2/Stat3 signaling to upregulate Myc and Sox2. *Oncogene* 34: 3107-3119, 2015.
- Sauer T, Furu I, Beraki K, Jebsen PW, Ormerod E and Naess O: nm23 protein expression in fine-needle aspirates from breast carcinoma: Inverse correlation with cytologic grading, lymph node status, and ploidy. *Cancer* 84: 109-114, 1998.
- Bao L, Cardiff RD, Steinbach P, Messer KS and Ellies LG: Multipotent luminal mammary cancer stem cells model tumor heterogeneity. *Breast Cancer Res* 17: 137, 2015.
- Jagadish N, Parashar D, Gupta N, Agarwal S, Sharma A, Fatima R, Suri V, Kumar R, Gupta A, Lohiya NK, *et al*: A novel cancer testis antigen target A-kinase anchor protein (AKAP4) for the early diagnosis and immunotherapy of colon cancer. *OncoImmunology* 5: e1078965, 2016.
- Youlden DR, Cramb SM, Dunn NA, Muller JM, Pyke CM and Baade PD: The descriptive epidemiology of female breast cancer: An international comparison of screening, incidence, survival and mortality. *Cancer Epidemiol* 36: 237-248, 2012.
- Khan MA: Effect of preoperative intravenous steroids on seroma formation after modified radical mastectomy. *J Ayub Med Coll Abbottabad* 29: 207-210, 2017.
- Memmi EM, Sanarico AG, Giacobbe A, Peschiaroli A, Frezza V, Cicalese A, Pisati F, Tosoni D, Zhou H, Tonon G, *et al*: p63 sustains self-renewal of mammary cancer stem cells through regulation of Sonic Hedgehog signaling. *Proc Natl Acad Sci USA* 112: 3499-3504, 2015.
- Thorsen LB, Offersen BV, Danø H, Berg M, Jensen I, Pedersen AN, Zimmermann SJ, Brodersen HJ, Overgaard M and Overgaard J: DBCG-IMN: A population-based cohort study on the effect of internal mammary node irradiation in early node-positive breast cancer. *J Clin Oncol* 34: 314-320, 2016.
- Faustino-Rocha AI, Gama A, Oliveira PA, Alvarado A, Fidalgo-Gonçalves L, Ferreira R and Ginja M: Ultrasonography as the gold standard for in vivo volumetric determination of chemically-induced mammary tumors. *In Vivo* 30: 465-472, 2016.
- Farabegoli F, Ceccarelli C, Santini D, Baldini N, Taffurelli M, Marrano D, Treré D and Derenzini M: c-erbB-2 over-expression in amplified and non-amplified breast carcinoma samples. *Int J Cancer* 84: 273-277, 1999.
- Hamnvik OP, Choueiri TK, Turchin A, McKay RR, Goyal L, Davis M, Kaymakcalan MD and Williams JS: Clinical risk factors for the development of hypertension in patients treated with inhibitors of the VEGF signaling pathway. *Cancer* 121: 311-319, 2015.
- Ciamporcero E, Miles KM, Adelaiye R, Ramakrishnan S, Shen L, Ku S, Pizzimenti S, Sennino B, Barrera G and Pili R: Combination strategy targeting VEGF and HGF/c-met in human renal cell carcinoma models. *Mol Cancer Ther* 14: 101-110, 2015.
- Lin CH, Dammai V, Adryan B and Hsu T: Interaction between Nm23 and the tumor suppressor VHL. *Naunyn Schmiedebergs Arch Pharmacol* 388: 143-152, 2015.
- Ahmed M: Image-guided tumor ablation: Standardization of terminology and reporting criteria - a 10-year update: Supplement to the consensus document. *J Vasc Interv Radiol* 25: 1706-1708, 2014.
- Simpson JF, O'Malley F, Dupont WD and Page DL: Heterogeneous expression of nm23 gene product in noninvasive breast carcinoma. *Cancer* 73: 2352-2358, 1994.



This work is licensed under a Creative Commons Attribution-NonCommercial-NoDerivatives 4.0 International (CC BY-NC-ND 4.0) License.