

Available online at www.sciencedirect.com

ScienceDirect

journal homepage: www.elsevier.com/locate/radcr

Case Report

Pseudoprogression of CNS metastatic disease of alveolar soft part sarcoma during anti-PDL1 treatment^{☆☆☆}

Thomas A. Vander Jagt^{a,*}, Lara E. Davis^{b,c}, Meghna Das Thakur^c, Carl Franz^d, Jeffery M. Pollock^a

^a Department of Radiology, Oregon Health Science University, Portland, OR, USA

^b Department of Pediatric Hematology and Oncology; Knight Cancer Institute Division of Hematology and Medical Oncology, Oregon Health Science University, Portland, OR, USA

^c Division of Oncology Biomarker Development, Genetech, South San Francisco, CA, USA

^d Division of Chemistry and Biology, Lake Tahoe Community College, South Lake Tahoe, CA, USA

ARTICLE INFO

Article history:

Received 9 April 2018

Revised 17 May 2018

Accepted 23 May 2018

Keywords:

Pseudoprogression

PDL1

Alveolar soft part sarcoma

ABSTRACT

Immune checkpoint inhibitors are increasingly used in treatment of metastatic renal cell carcinoma, melanoma, and nonsmall cell lung cancer, as well as in clinical trials for novel targets. We present a pediatric patient with metastatic alveolar soft part sarcoma who was treated with MPDL3280 (Atezolizumab), a monoclonal anti-programmed death ligand-1 antibody. Imaging results for the patient suggested disease progression of multiple brain metastases with stable systemic disease. The patient met response evaluation criteria in solid tumors (RECIST) criteria of progression of disease and was removed from treatment with MPDL3280. Subsequent surgical resection of the brain lesions revealed nonviable tumor with extensive lymphocytic infiltrates consistent with pseudoprogression. This case report adds to a growing number of reports that question reliance on RECIST criteria and suggest need for further refinement of RECIST or irRECIST during immune checkpoint inhibitor treatment for central nervous system metastatic lesions.

© 2018 The Authors. Published by Elsevier Inc. on behalf of University of Washington.

This is an open access article under the CC BY-NC-ND license.

(<http://creativecommons.org/licenses/by-nc-nd/4.0/>)

Case report

A 13-year-old female initially presented with symptoms of headaches. Subsequent findings included a left parietal mass,

numerous pulmonary nodules, and a soft tissue lesion in her right thigh. A lung biopsy confirmed the diagnosis of alveolar soft part sarcoma. The patient underwent total resection of the brain metastasis with subsequent enrollment in clinical trial of cediranib. Treatment was discontinued after 5 months due to central nervous system (CNS) disease progression. The patient then underwent resection of the largest brain metastasis and a large mediastinal metastasis. This was followed by stereotactic radiosurgery of three brain lesions with palliative surgical resection of the primary thigh mass. The pa-

* Acknowledgment: The authors would like to thank Cleopatra Kozłowski.

☆☆ Competing Interests: The authors have declared that no competing interests exist.

* Corresponding author.

E-mail address: vanderja@ohsu.edu (T.A. Vander Jagt).

<https://doi.org/10.1016/j.radcr.2018.05.013>

1930-0433/© 2018 The Authors. Published by Elsevier Inc. on behalf of University of Washington. This is an open access article under the CC BY-NC-ND license. (<http://creativecommons.org/licenses/by-nc-nd/4.0/>)

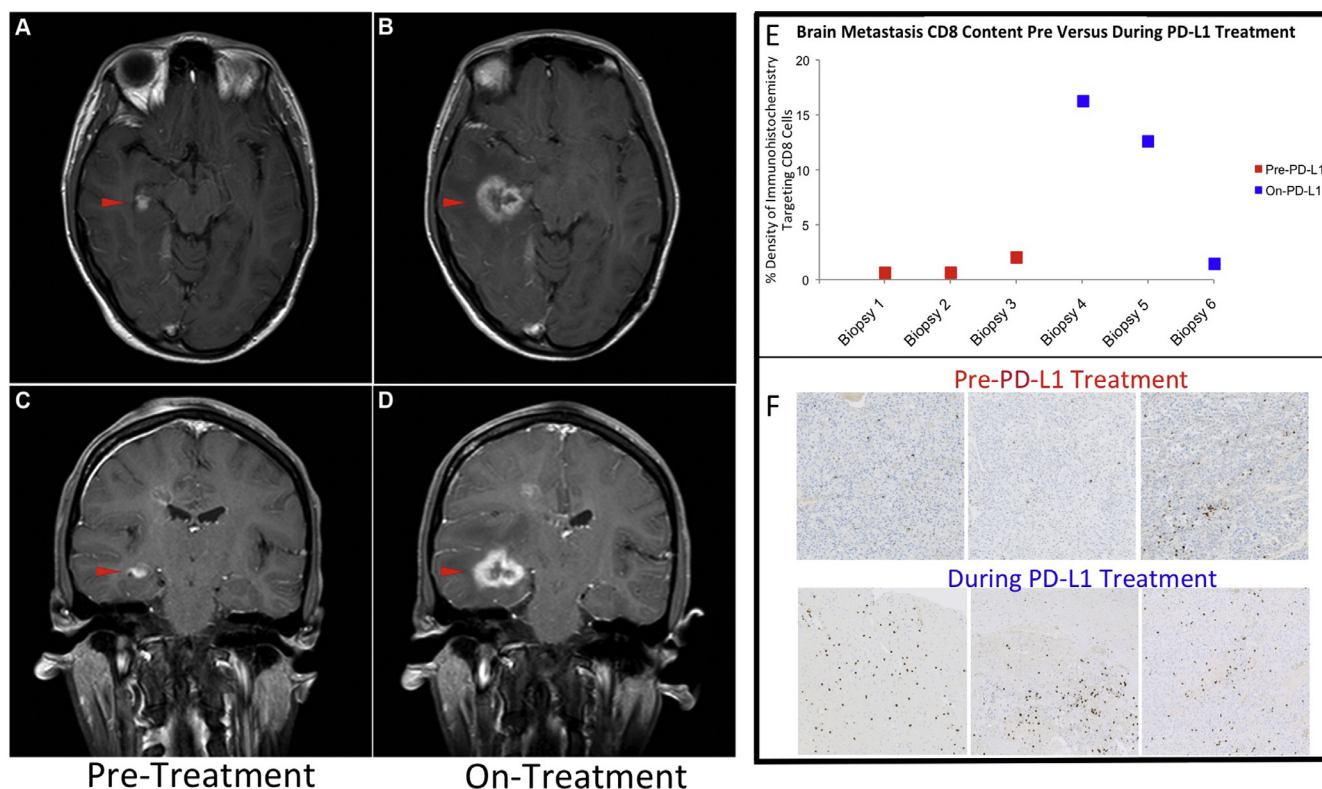


Fig. 1 – Thirteen-year-old female with alveolar soft part sarcoma brain metastasis demonstrating pseudoprogression during anti-PD-1 (Programmed cell death-1 protein) inhibitor therapy proven by postresection pathology. Axial (A and B) and coronal (C and D) images T1-weighted postcontrast (Omniscan, 3-T magnet) of right temporal lobe metastatic deposit demonstrating pseudoprogression with increased enhancement and diameter during therapy of MPDL3280 (Atezolizumab) (B and D) compared to pretreatment (A and C). (E) CD8 density quantification was done by pathologist designated regions of interest of invasive margin, periphery, core and whole area of section slides. Slides were then scanned on a Hamamatsu Nanozoomer 2.0HT at 20x. HRP (horseradish peroxidase) stain was detected by computing mean area divided by nuclear counterstain area for mean cell HRP positive nuclei density/total cells. (F) Representative examples of 4- μ m thickness, formalin-fixed, paraffin-embedded tissue section of temporal lobe resections from initial stereotactic right temporal resection (pre PD-L1) compared to during MPDL3280 (PD-L1) therapy. Slides were glass mounted and cover slipped and subsequently stained for CD8 (clone SP16, AbCam) detected by OmniMap antirabbit HRP detection kit followed by ChromoMap.

patient also required urgent surgery for ileocolic intussusception secondary to a small bowel metastatic burden. Patient was treated with cabozantinib (off-label) but demonstrated continued disease progression. This required palliative radiation to brain, soft tissue, bone, pancreas, and renal masses, as well as a repeat small bowel resection for enlarging metastases. After 12 months of treatment with cabozantinib, the patient had turned 15-years-old and therefore became eligible for enrollment in an expanded access program for trabectedin. She had new brain metastases identified after 6 weeks, and therefore trabectedin was discontinued.

Subsequently, the institutional review board at Oregon Health and Science University, Genentech, and the Federal Drug Administration, approved an individual investigational new drug protocol for the patient to receive MPDL3280 (Atezolizumab), a monoclonal anti-programmed death ligand-1 (anti-PDL1) antibody. Informed consent was obtained from the

patient and her parents. MPDL3280 was administered at a dose of 15 mg/kg IV every 21 days. Treatment was complicated by repeated hospital admissions for partial small bowel obstructions that were successfully managed without surgical intervention. Magnetic resonance imaging (MRI) of the brain and CT of the chest, abdomen, and pelvis after 8 weeks of treatment demonstrated a mixed response but overall stable disease by Response Evaluation Criteria in Solid Tumors (RECIST). After six doses, she began to experience worsening headaches. Brain MRI confirmed enlargement of multiple brain metastases, most notably in the right temporal lobe (Fig. 1A-D) and right cerebellum, with extensive surrounding edema and 5-mm midline shift. Nineteen months prior, the temporal lobe lesion had been treated to 30 Gy and 5 months prior, to 20 Gy. The cerebellar lesion had been treated 13 months prior to 20 Gy. The patient then underwent complicated diagnostic and therapeutic right temporal and cere-

Target Lesion	16 weeks prior	Baseline	8 weeks	14 weeks	26 weeks	8 months	10 months
			MPDL3280A x3	MPDL3280A x5	MPDL3280A x9	MPDL3280A x12	MPDL3280A x15
Left lower lobe	5.6	7.4	6.3	7.5	7.7	8.0	8.0
Spleen	4.9	6.5	7.3	9.2	8.0	5.9	4.8
Pancreatic head	1.4	1.5	1.1	1.5	1.7	1.2	1.4
New lesions.	No	No	No	No	No	No	Yes

Fig. 2 – Systemic response evaluation criteria in solid tumors lesions imaged with contrasted computed tomography during Anti-PD-1 MPDL3280A treatment (15 mg/kg IV every 21 days). Measures demonstrate stable or reduction of lesion size of systemic disease during treatment. Weeks of total treatment with programmed death ligand-1 inhibitor denoted in top row. Response Evaluation Criteria in Solid Tumors measurements are represented in cm.

bellar craniotomies for resection of these two lesions with 3 days of corticosteroids administered perioperatively. Upon pathologic review, no viable tumor was identified. The surgical specimens contained primarily necrotic tissue with extensive lymphocytic infiltrate as denoted by histology results of increase CD8 staining post-treatment with MPDL3280 (Figs. 1 E and F). Concurrent RECIST stable systemic metastatic disease was demonstrated in lesions in lung, spleen, and pancreas during treatment (Fig. 2).

Discussion

PDL-1 release by tumor cells has been shown to inhibit immune response to the tumor. Ligand modulation therapy can enhance lymphocyte activation and engagement of the immune response toward tumor tissue [1]. Flair inflammatory response and pseudoprogression during immune therapy targeting PD-1 and PDL-1 has been reported in nonsmall cell lung cancer as well as CNS metastatic melanoma treatment [2–4]. These studies have also questioned the standard RESIST 1.1 criteria for clinical decision making for disease progression during use of immune therapy. Developing new strategies when CNS pseudoprogression may be present during mixed systemic response is essential for therapeutic decisions. The case presented here demonstrates pseudoprogression similar to previous reports describing treatment of melanoma with ipilimumab, a monoclonal antibody against cytotoxic T-lymphocyte-associated antigen-4, with initial increased size of systemic tumor lesions that were subsequently confirmed by biopsy as inflammatory cell infiltrates and necrosis [5]. Results for treatment with the PD-1 inhibitor pembrolizumab have also shown disease progression by MRI, in which subsequent histopathology demonstrated inflammatory response to treatment [4]. Currently, rates of CNS metastatic disease pseudoprogression in the context of systemic stable or regressing lesions, as determined by RESIST, are unknown [2]. This is due in part to limited clinical trials that included

CNS metastatic disease. In addition, there are suggestions of variable responses likely related to bioavailability of agents or T-cells in CNS lesion microenvironments [6,7]. To our knowledge, there are no previously published case reports of pseudoprogression involving alveolar soft part sarcoma CNS metastasis treated with MPDL3280 (Atezolizumab). The current literature provides limited data to better delineate expected occurrence rates of mixed systemic response to therapy in the context of CNS pseudoprogression of metastatic disease.

Immune checkpoint inhibitors are utilized in an increasing number of clinical trials for a variety of metastatic disease targets including newly Food and Drug Administration approved targets. Furthermore, there are a growing number of case reports of CNS metastases associated with melanoma and lung cancer, in which CNS pseudoprogression was confirmed by histopathology. These cases involved use of several immune check point inhibitors, such as PD-1 and PDL-1 and T-cell mediated immune therapy CTLA4 antibodies. Currently, newly revised RECIST 1.1 and irRECIST (immune related response RECIST) criteria for validating timeline windows for expected pseudoprogression in metastatic CNS lesions, as well as expected rates of overall occurrence, are not well developed [2,8]. The CNS lesion microenvironment is thought to have an unknown component for predicted response and response time during immune therapy. CNS bioavailability of PD-1 and PDL-1 is still unknown. This may be related in part to varying levels of blood brain barrier disruption for each metastatic disease type [7,9]. Largely, pseudoprogression diagnosis has been reliant on retrospective histopathology in most case reports, limiting its value collectively for use in treatment decisions.

To our knowledge, the present case is the only case involving PDL-1 treatment of pediatric metastatic alveolar soft part sarcoma demonstrating CNS pseudoprogression with stable or regression of diffuse systemic disease (Fig. 1 and Fig. 2). It revisits an ongoing question for use of contrast MRI-based imaging to determine treatment response in trial immune therapies. Use of contrast-enhanced MRI and diffusion-based imaging in disease progression with other therapies such as

resection, chemotherapy, and radiotherapy remains a challenge for identifying post-treatment inflammatory reactions for continuation of treatment decisions [10]. There is utility of diffusion-weighted imaging for delineating disease progression vs inflammatory reaction for gliomas [11]. However, varying cell types in metastatic disease and heterogeneous lesion environments would make generalization of these principles inappropriate until specific data exist for each type of metastatic disease [12]. The current RECIST 1.1 and irRECIST mainly rely on imaging demonstrating lesion size progression beyond recommended time frames as it pertains to data from chemoradiative paradigms to evaluate the possibility of pseudoprogression.

Currently, application of RECIST criteria remains difficult with the growing utilization of immune therapy agents, due to lack of data from controlled studies for determining what a reliable response window should be to suggest pseudoprogression. Perhaps, in the near future, perfusion MRI (rCBV) (relative cerebral blood volume) and dynamic susceptibility contrast perfusion can play a larger role in criteria for determining metastatic CNS disease progression, along with PET (positron emission tomography) imaging using neutral amino acid transport metabolism, to help delineate inflammatory response from disease progression [13,14].

REFERENCES

- [1] Pardoll DM. The blockade of immune checkpoints in cancer immunotherapy. *Nat Rev Cancer* 2012;12(4):252–64.
- [2] Chiou VL, Burotto M. Pseudoprogression and immune-related response in solid tumors. *J Clin Oncol* 2015;33(31):3541–3.
- [3] Sarfaty M, Moore A, Dudnik E, Peled N. Not only for melanoma. Subcutaneous pseudoprogression in lung squamous-cell carcinoma treated with nivolumab: a case report. *Medicine (Baltimore)* 2017;96(4):e5951.
- [4] Cohen JV, Alomari AK, Vortmeyer AO, Jilaneanu LB, Goldberg SB, Mahajan A, Chiang VL, Kluger HM. Melanoma brain metastasis pseudoprogression after pembrolizumab treatment. *Cancer Immunol Res*, 2016;4(3):179–82.
- [5] Hodi FS, Oble DA, Drappatz J, Velazquez EF, Ramaiya N, Ramakrishna N, Day AL, Mac Rae S, Hoos A, Mihm M. CTLA-4 blockade with ipilimumab induces significant clinical benefit in a female with melanoma metastases to the CNS. *Nat Clin Pract Oncol* 2008;5(9):557–61.
- [6] Wilson EH, Weninger W, Hunter CA. Trafficking of immune cells in the central nervous system. *J Clin Invest*, 2010;120(5):1368–79.
- [7] Cohen JV, Kluger HM. Systemic immunotherapy for the treatment of brain metastases. *Front Oncol* 2016;6:49.
- [8] Seymour L, Bogaerts J, Perrone A, Ford R, Schwartz LH, Mandrekar S, Lin NU, Litieue S, Dancey J, Chen A, Hodi FS, Therasse P, Hoekstra OS, Shankar LK, Wolchok JD, Ballinger M, Caramella C, de Vries EG. irRECIST: guidelines for response criteria for use in trials testing immunotherapeutics. *Lancet Oncol* 2017;18(3):e143–52.
- [9] Di Giacomo AM, Margolin K. Immune checkpoint blockade in patients with melanoma metastatic to the brain. *Semin Oncol* 2015;42(3):459–65.
- [10] Ellingson BM, Chung C, Pope WB, Boxerman JL, Kaufmann TJ. Pseudoprogression, radionecrosis, inflammation or true tumor progression? Challenges associated with glioblastoma response assessment in an evolving therapeutic landscape. *J Neurooncol* 2017;134(3):495–504.
- [11] Wang S, Martinez-Lage M, Sakai Y, Chawla S, Kim SG, Alonso-Basanta M, et al. Differentiating tumor progression from pseudoprogression in patients with glioblastomas using diffusion tensor imaging and dynamic susceptibility contrast MRI. *AJNR Am J Neuroradiol* 2016;Jan 37(1):28–36.
- [12] Villanueva-Meyer JE, Mabray MC, Cha S. Current clinical brain tumor imaging. *Neurosurgery* 2017;81(3):397–415.
- [13] Galldiks N, Langen KJ. Amino acid PET—an imaging option to identify treatment response, post therapeutic effects, and tumor recurrence. *Front Neurol* 2016;7:120.
- [14] Song YS, Choi Sh, Park CK, Yi KS, Lee WJ, Yun TJ, Kim TM, Lee SH, Kim JH, Sohn CH, Park SH, Kim IH, Jahng GH, Chang KH. True progression versus pseudoprogression in the treatment of glioblastomas: a comparison study of normalized cerebral blood volume and apparent diffusion coefficient by histogram analysis. *Korean J Radiol* 2013;14(4):662–72.