


REVIEW

Open Access



# Differences and similarities between disseminated intravascular coagulation and thrombotic microangiopathy

Hideo Wada<sup>1\*</sup> , Takeshi Matsumoto<sup>2</sup>, Kei Suzuki<sup>3</sup>, Hiroshi Imai<sup>3</sup>, Naoyuki Katayama<sup>4</sup>, Toshiaki Iba<sup>5</sup> and Masanori Matsumoto<sup>6</sup>

## Abstract

**Introduction:** Both disseminated intravascular coagulation (DIC) and thrombotic microangiopathy (TMA) cause microvascular thrombosis associated with thrombocytopenia, bleeding tendency and organ failure.

**Reports and discussion:** The frequency of DIC is higher than that of thrombotic thrombocytopenic purpura (TTP). Many patients with TMA are diagnosed with DIC, but only about 15% of DIC patients are diagnosed with TMA. Hyperfibrinolysis is observed in most patients with DIC, and microangiopathic hemolytic anemia is observed in most patients with TMA. Markedly decreased ADAMTS13 activity, the presence of Shiga-toxin-producing *Escherichia coli* (STEC) and abnormality of the complement system are useful for the diagnosis of TTP, STEC-hemolytic uremic syndrome (HUS) and atypical HUS, respectively. However, there are no specific biomarkers for the diagnosis of DIC.

**Conclusion:** Although DIC and TMA are similar appearances, all coagulation, fibrinolysis and platelet systems are activated in DIC, and only platelets are markedly activated in TMA.

**Keywords:** DIC, TMA, Microvascular thrombosis, Hyperfibrinolysis, Organ failure, Microangiopathic hemolytic anemia

## Background

Disseminated intravascular coagulation (DIC) [1, 2] is a serious disease that causes microvascular thrombosis associated with thrombocytopenia, a bleeding tendency and organ failure. These symptoms and laboratory data are similar to those of thrombotic microangiopathy (TMA) [3] which includes thrombotic thrombocytopenic purpura (TTP) [4, 5], Shiga-toxin-producing *Escherichia coli* (STEC) - hemolytic uremic syndrome (HUS) [6, 7], complement-mediated TMA (also called atypical HUS; aHUS) [7, 8] and secondary TMA [3, 9]. DIC also has several clinical subtypes, including asymptomatic type, marked bleeding type, organ failure type and complication types such as TTP or heparin-induced thrombocytopenia [10]. As the treatment of DIC [11] differs from that of TMA [4, 12], it is important to perform a differential diagnosis of DIC and TMA. The

differences and similarities between DIC and TMA are reviewed in this study.

## Differences in the definition and concept of DIC and TMA

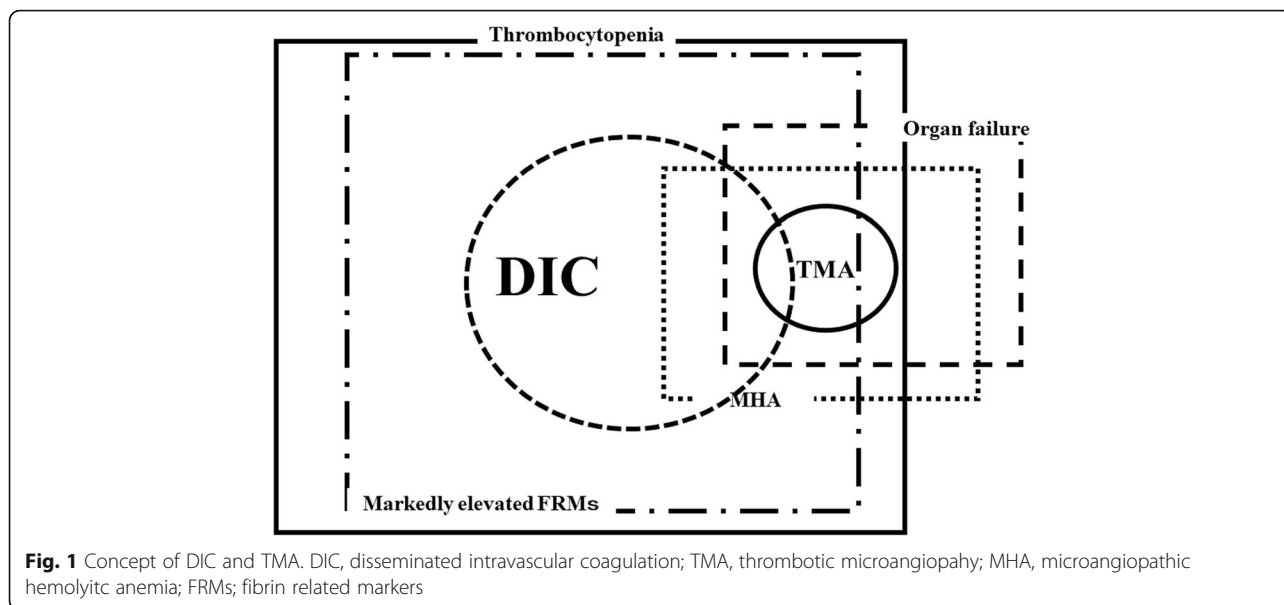
The frequency of pneumonia associated DIC was reported to be about 10,000 cases per year according to the Japanese Diagnosis Procedure Combination (DPC) database [13], suggesting that DIC due to pneumonia occurs in about 70/10<sup>6</sup> populations. With the addition of other types of DIC, the frequency of all DIC is about 300/10<sup>6</sup> populations. In contrast, the frequency of TTP was reported to be 2.0/10<sup>6</sup> populations [3]. These reports suggest that the frequency of DIC in Japan is 150-fold higher than that of TTP (Fig. 1). According to the International Society of Thrombosis and Haemostasis (ISTH), DIC is an acquired syndrome characterized by the intravascular activation of coagulation with the loss of localization arising from different causes. It can originate from and cause damage to the microvasculature, which if sufficiently severe, can produce organ dysfunction. DIC is characterized by the generation of fibrin

\* Correspondence: [wadahide@clin.medic.mie-u.ac.jp](mailto:wadahide@clin.medic.mie-u.ac.jp)

<sup>1</sup>Department of Molecular and Laboratory Medicine, Mie University Graduate School of Medicine, Tsu, Mie 514-8507, Japan

Full list of author information is available at the end of the article



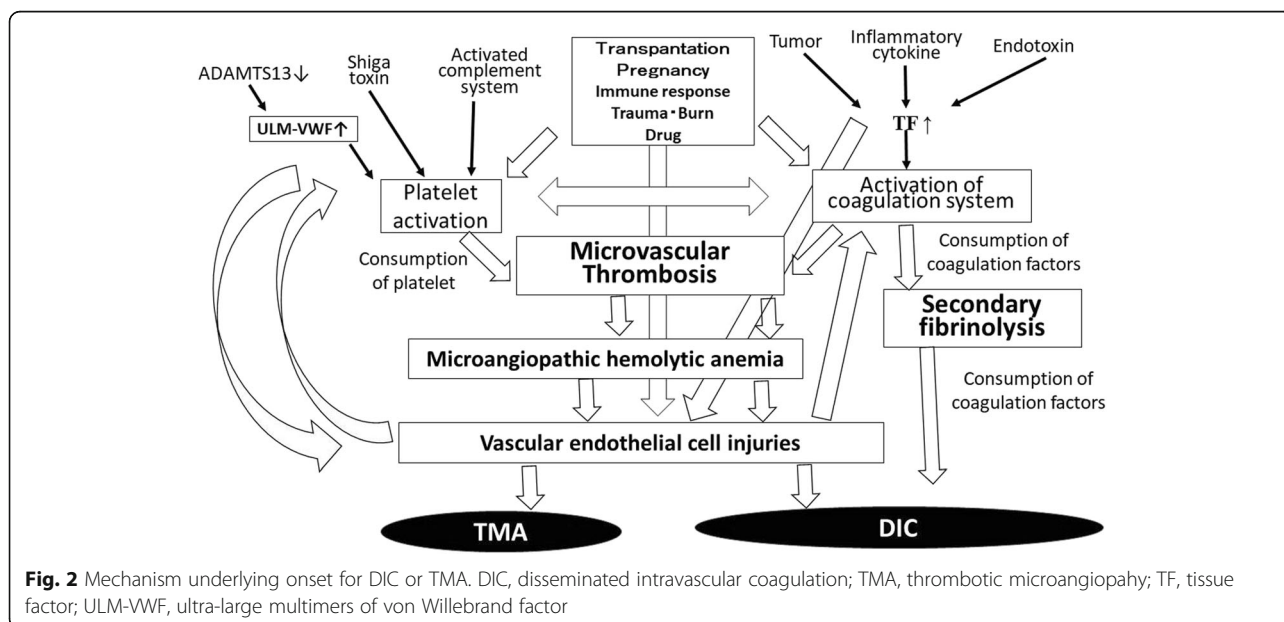


related markers (FRMs; soluble fibrin monomers, fibrinogen and fibrin degradation products [FDPs], D-dimers, etc.) and reflects an acquired (inflammatory) or non-inflammatory disorder of the microvasculature [1]. Regarding the definition of TMA, TMA presents with microangiopathic hemolytic anemia (MHA), including hemolytic anemia, thrombocytopenia and organ failure in the kidney, central nervous system, and other organs [3, 4]. These findings suggest that marked elevation of FRMs is required in DIC while MHA is required in TMA; the diagnosis of TTP among TMA requires a markedly decreased ADAMTS13 level [14], that of STEC-HUS requires the detection of a STEC infection

[15] and that of aHUS requires the detection of abnormalities in the complement system [16].

However, DIC has no specific marker for its diagnosis and is instead diagnosed by a scoring system using global coagulation tests. Furthermore, DIC is often associated with TMA, and TMA is often associated with DIC [17], suggesting that a differential diagnosis between DIC and TMA may be difficult.

DIC associated with TMA was observed in patients with bone marrow metastasis of solid cancer as gastric cancer, those with liver failure and those with group A streptococcal infection. In patients with DIC, bone marrow metastasis mainly causes MHA, liver failure mainly causes an



**Table 1** Diagnostic criteria for infectious DIC

	ISTH	P	JSTH	P	JMHLW	P	JAAM	P
PLT ( $\times 10^3/\mu\text{l}$ )	$100 \geq > 50$	1	$120 \geq > 80$	1	$120 \geq > 80$	1	$120 \geq > 8.0$	1
	$50 \geq$	2	$80 \geq > 50$	2	$80 \geq > 50$	2		
			$50 \geq$	3	$50 \geq$	3	$80 \geq$	3
Reduction of PLT			30%	1*			30%	1*
							50%	3*
Prothrombin time ratio or Prolongation (s)	$3 \leq < 6.0$	1	$1.25 \leq < 1.67$	1	$1.25 \leq < 1.67$	1	$1.2 \leq$	1
	$6 \leq$	2	$1.67 \leq$	2	$1.67 \leq$	2		
Fibrinogen (g/L)	$1.0 \geq$	1			$1.5 \geq > 1.0$	1		
					$1.0 \geq$	2		
Fibrin related markers, FDP ( $\mu\text{g/ml}$ )			$10 \leq < 20$	1	$10 \leq < 20$	1	$10 \leq < 25$	1
	Increase	2	$20 \leq < 40$	2	$20 \leq < 40$	2		
	Markedly increase	3	$40 \leq$	3	$40 \leq$	3	$25 \leq$	3
Antithrombin			$< 70\%$	1				
TAT or SF			2 fold higher of NR					
Underlying diseases					Positive	1		
Bleeding					Positive	1		
OF due to thrombosis					Positive	1		
SIRS							Positive	1
DIC		$5 \leq$		$5 \leq$		$7 \leq$		$4 \leq$

ISTH International Society of Thrombosis and Haemostasis, JSTH Japanese Society of Thrombosis and Hemostasis, JMHLW Japanese Ministry of Health, Labor and Welfare, JAAM Japanese Association for Acute Medicine, PLT platelet count, FDP fibrinogen and fibrin degradation products, TAT thrombin antithrombin complex, SF soluble fibrin, SIRS systemic inflammatory response syndrome, DIC disseminated intravascular coagulation

\*PLT and reduction of PLT points should be within 3 points

increase in the von Willebrand factor/ADAMTS13 ratio, and group A streptococcal infection mainly cause massive hemolysis. However, it would be much more important to find TMA associated with DIC.

#### Differences and similarities in the mechanism of onset for DIC and TMA

The basic mechanism of onset for DIC is the marked activation and consumption of coagulation system followed by the activation of secondary fibrinolysis [18]. In contrast, the basic mechanism of onset for TMA is the marked activation and consumption of platelets due to several factors followed by the activation and injury of vascular endothelial cells [19, 20] (Fig. 2). Triggers of the activation of coagulation system are reported to include tissue factor (TF) [21, 22], inflammatory cytokines [23, 24] and lipopolysaccharide (LPS) [25], the activation leukocytes [26] and abnormal delivery among others. Trigger of platelet and vascular endothelial cells activation are reported to be a marked decrease in the ADAMTS13 levels in TTP [27], the detection of STEC in STEC-HUS [15] and the detection of abnormalities in the complement system in aHUS [16], along with other factors, such as transplantation, pregnancy, drugs and immune diseases, in secondary TMA [28]. Particularly marked decreases in the ADAMTS13 level result in an inability to cleave ultra-large

multimers of von Willebrand factor [29, 30], thereby causing platelet aggregation. Markedly fibrinolysis is frequently observed in most patients with DIC, except for some septic DIC cases [31], while markedly fibrinolysis is not observed in patients with TMA.

Both DIC and TMA cause microvascular thrombosis, which is caused mainly by the activation of the coagulation system in DIC and by the activation of platelets and vascular endothelial cells in TMA. Several cases of TMA have been reported to be complicated with hemophilia patients treated with activated prothrombin complex concentrates (APCCs) in the clinical trial for Emicizumab [32]. As APCCs usually causes DIC but not TMA, the differential diagnosis is important in these cases [33]. Although DIC is an acquired disease, Upshaw-Schulman syndrome as familial TTP [34] and many patients with aHUS are examples of congenital TMA.

#### Difference in the diagnosis between DIC and TMA

As there is no gold standard for diagnosing DIC and no specific biomarker that clearly diagnoses DIC, the differential diagnosis between DIC and TMA is difficult. Four diagnostic criteria for DIC has been established by the Japanese Ministry of Health, Labor and Welfare [35], ISTH [1], Japanese Association for Acute Medicine [36] and the Japanese Society on Thrombosis and Hemostasis

**Table 2** Diagnostic criteria for TMA [4, 35, 36]

	STEC-HUS	aHUS	TTP	TMA
Hemoglobin (g/dl)	10.0 $\geq$	10.0 $\geq$	Hemolysis	10.0 $\geq$
Platelet ( $\times 10^4/\mu\text{l}$ )	15.0 $\geq$	15.0 $\geq$	Thrombocytopenia	15.0 $\geq$
Ogan failure	Renal failure Creatinine $\geq 1.5$ folds of the standard	Renal failure Creatinine $\geq 1.5$ folds of the standard	Neurological symptoms	?
Laboratory finding	Detection of STEC	Genetic abnormality in the complement system	ADAMTS13 < 10%	?

TMA thrombotic microangiopathy, aHUS atypical hemolytic uremic syndrome, TTP thrombotic thrombocytopenic purpura, STEC Shiga toxin-producing *Escherichia coli*

(JSTH) [37, 38]. These diagnostic criteria use a similar scoring system based on global coagulation tests (GLTs) such as the platelet count, prothrombin time (PT), FRMs (Table 1). Therefore, there are no significant differences in the usefulness among various diagnostic criteria for DIC [39]. The diagnosis of TMA is based on the presence of hemolytic anemia (hemoglobin < 10 g/dl), thrombocytopenia ( $12 \times 10^9/\text{ml}$ ) and organ failure. TMA patients with ADAMTS13 < 10%, those with STEC and those with abnormalities in the complement system can be easily diagnosed with TTP, STEC-HUS and aHUS, respectively (Table 2) [4, 40, 41]. However, markedly decreased ADAMTS13 levels have been reported in severe sepsis patients without TTP [42, 43], suggesting that platelet activation due to decreased ADAMTS13 might be observed in DIC patients with severe sepsis. The diagnosis of other TMA aside from DIC with

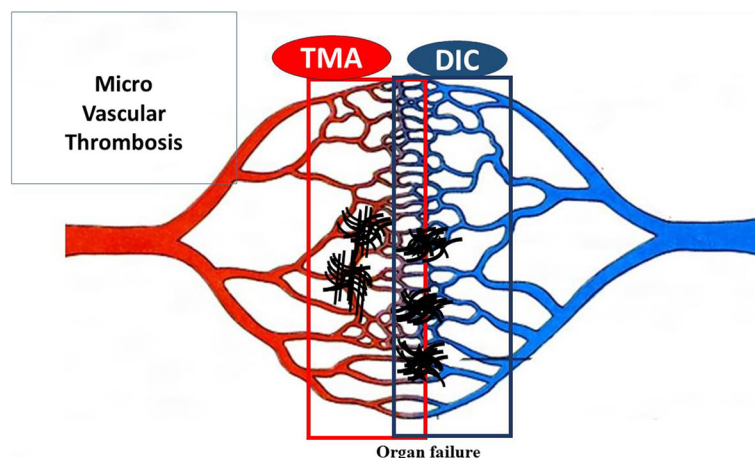
hemolysis is difficult. Most patients with TMA can be diagnosed using several DIC diagnostic criteria to have DIC, but only 10%–15% of DIC patients can be diagnosed to have TMA (Fig. 2).

#### Differences and similarities between DIC and TMA

The differences and similarities between DIC and TMA are described in Table 3. Among clinical symptoms, bleeding and organ failure are frequently observed in patients with DIC as well as those with TMA, but lung or cardiovascular failures is more frequently observed only in patients with DIC [44], while renal or central nervous system failure is more frequently observed in patients with TMA [3]. Hypotension as organ failure is observed in many patients with DIC, while hypertension tend to be observed in patients with TMA [45]. Hypertension may be caused by acute kidney injury or arterial occlusion.

**Table 3** Differences and similarities between TMA and DIC

		Severe DIC	Severe TMA
Symptoms	Organ failure	Often (Lung, Kidney, Shock)	Usually (Kidney, CNS)
	Bleeding and bleeding tendency	Frequent	Frequent
	Blood pressure	Low	High
	Hematuria	Sometimes	Frequent
	Anemia	Often	Usually
Laboratory data	Platelet count	Low	Low
	Hemoglobin	Often low	Low
	Fibrin related markers	Markedly high	Slightly high
	Prothrombin time	Often prolong	Normal
	Antithrombin	Often low	Normal
	Albumin	Often low	Normal
	Creatinine	Often high	High
	Total bilirubin, LDH	Often high	High
Treatments	Supportive therapy	Recommended	Recommended
	Blood transfusion (RBC, FFP)	Recommended	Recommended,
	Blood transfusion (PC)	Recommended	Not recommended
	Anticoagulant	Recommended (Japan)	Not mentioned
	PE/FFP	Not mentioned	Recommended
	Special treatment	AT, rhTM (Japan)	Hemodialysis (HUS), Eculizumab (aHUS), Rituximab (TTP)



**Fig. 3** Microvascular thrombosis in DIC and TMA. DIC, disseminated intravascular coagulation; TMA, thrombotic microangiopathy

Anemia is also more frequently observed in patients with TMA [20, 46] than in those with DIC. Red blood cell fragmentation may be caused by microvascular thrombosis on the arterial side which has a high blood pressure, but not on the venous side (Fig. 3). Among laboratory data, thrombocytopenia is observed in both DIC and TMA. A decreased hemoglobin level and increased levels of creatinine, total bilirubin and LDH are observed in most patients with TMA, but these abnormalities are observed in only 15% of patients with DIC. A prolonged PT and decreased AT and albumin levels are frequently (but not always) observed in patients with DIC. Markedly elevated FRMs are observed in most patients with DIC. As markedly fibrinolysis may dissolve microthromboses in patients with DIC but not in those with TMA, thrombosis of DIC is not usually detected on autopsy. Therefore, elevated FRMs and decreased platelet counts are the most useful markers for DIC [1].

In Japan, regarding the treatment of DIC and TMA, platelet transfusion is contraindicated for TMA [4], while anticoagulant therapy for DIC, but not for TMA, is recommended [10, 11]. Anti-fibrinolytic therapy is recommended for DIC patients with hyperfibrinolysis. Plasma exchange is recommended in most some cases of TMA such as TTP [47], but not for DIC. Antithrombin concentrate [48] and recombinant thrombomodulin [49] for DIC are frequently used in Japan, while eculizumab [50] has proven effective for complement mediated TMA, such as aHUS, and rituximab [51] is effective for TTP in patients with a high titer of inhibitor for ADAMTS13.

### Conclusion

DIC and TMA are similar appearances, however, all coagulation, fibrinolysis and platelet systems are activated

in DIC, and only platelets are markedly activated in TMA. As treatment is different between DIC and TMA, differential diagnosis between DIC and TMA is important.

### Abbreviations

aHUS: atypical HUS; DIC: Disseminated intravascular coagulation; DPC: Diagnosis Procedure Combination; FDP: fibrinogen and fibrin degradation products; FRMs: fibrin related markers; GLTs: global coagulation tests; HUS: Hemolytic uremic syndrome; ISTH: International Society of Thrombosis and Haemostasis; JSTH: Japanese Society on Thrombosis and Hemostasis; MHA: microangiopathic hemolytic anemia; PT: prothrombin time; STEC: Shiga-toxin-producing *Escherichia coli*; TMA: thrombotic microangiopathy; TTP: thrombotic thrombocytopenic purpura

### Acknowledgements

None

### Funding

This work was supported in part by a Grant-in-Aid from the Ministry of Health, Labour and Welfare of Japan and the Ministry of Education, Culture, Sports, Science and Technology of Japan.

### Availability of data and materials

None

### Authors' contributions

WH fully wrote this manuscript. MT, SK and IH reviewed these references. KN, IT, and MM discussed and gave the suggestions for this manuscript. All authors read and approved the final manuscript.

### Ethics approval and consent to participate

The study protocol was approved by the Human Ethics Review Committee of the Mie University School of Medicine, and a signed consent form was obtained from each subject. This study was faithfully carried out in accordance with the principles of the Declaration of Helsinki.

### Consent for publication

A signed consent form was obtained from each subject.

### Competing interests

The authors declare that they have no competing interests.

## Publisher's Note

Springer Nature remains neutral with regard to jurisdictional claims in published maps and institutional affiliations.

### Author details

<sup>1</sup>Department of Molecular and Laboratory Medicine, Mie University Graduate School of Medicine, Tsu, Mie 514-8507, Japan. <sup>2</sup>Division of Blood Transfusion Medicine and Cell Therapy, Mie University Graduate School of Medicine, Tsu, Japan. <sup>3</sup>Emergency Critical Care Center, Mie University Graduate School of Medicine, Tsu, Japan. <sup>4</sup>Department of Hematology and Oncology, Mie University Graduate School of Medicine, Tsu, Japan. <sup>5</sup>Department of Emergency and Disaster Medicine, Juntendo University Graduate School of Medicine, Tokyo, Japan. <sup>6</sup>Department of Blood Transfusion Medicine, Nara Medical University, Nara, Japan.

Received: 23 January 2018 Accepted: 21 March 2018

Published online: 11 July 2018

### References

- Taylor FB Jr, Toh CH, Hoots WK, Wada H, Levi M. Scientific subcommittee on disseminated intravascular coagulation (DIC) of the international society on thrombosis and Haemostasis (ISTH): towards definition, clinical and laboratory criteria, and a scoring system for disseminated intravascular coagulation. *Thromb Haemost.* 2001;86:1327–30.
- Wada H, Matsumoto T, Yamashita Y, Hatada T. Disseminated intravascular coagulation: testing and diagnosis. *Clin Chim Acta.* 2014;436C:130–4.
- Wada H, Matsumoto T, Yamashita Y. Natural history of thrombotic thrombocytopenic Purpura and hemolytic uremic syndrome. *Semin Thromb Hemost.* 2014;40:866–73.
- Matsumoto M, Fujimura Y, Wada H, Kokame K, Miyakawa Y, Ueda Y, Higasa S, Moriki T, Yagi H, Miyata T, Murata M. For TTP group of blood coagulation abnormalities research team, research on rare and intractable disease supported by health, labour, and welfare sciences research grants: Diagnostic and treatment guidelines for thrombotic thrombocytopenic purpura (TTP) 2017 in Japan. *Int J Hematol.* 2017;106:3–15.
- South K, Lane DA. ADAMTS-13 and von Willebrand factor: a dynamic duo. *J Thromb Haemost.* 2017; in press
- Mele C, Remuzzi G, Noris M. Hemolytic uremic syndrome. *Semin Immunopathol.* 2014;36:399–420.
- Jokiranta TS. HUS and atypical HUS. *Blood.* 2017;129:2847–56.
- Shen YM. Clinical evaluation of thrombotic microangiopathy: identification of patients with suspected atypical hemolytic uremic syndrome. *Thromb J.* 2016;14(Suppl 1):19.
- Epperla N, Hemauer K, Hamadani M, Friedman KD, Kreuziger LB. Impact of treatment and outcomes for patients with posttransplant drug-associated thrombotic microangiopathy. *Transfusion.* 2017;57:2775–81.
- Wada H, Asakura H, Okamoto K, Iba T, Uchiyama T, Kawasugi K, Koga S, Mayumi T, Koike K, Gando S, Kushimoto S, Seki Y, Madoiwa S, Maruyama I, Yoshioka A. Japanese Society of Thrombosis Hemostasis/DIC subcommittee: expert consensus for the treatment of disseminated intravascular coagulation in Japan. *Thromb Res.* 2010;125:6–11.
- Wada H, Thachil J, Di Nisio M, Mathew P, Kurosawa S, Gando S, Kim HK, Nielsen JD, Dempfle CE, Levi M, Toh CH. The scientific standardization committee on DIC of the international society on thrombosis Haemostasis: guidance for diagnosis and treatment of DIC from harmonization of the recommendations from three guidelines. *J Thromb Haemost.* 2013;11:761–7.
- Scully M, Hunt BJ, Benjamin S, Liesner R, Rose P, Peyvandi F, Cheung B, Machin SJ. British Committee for Standards in Haematology: guidelines on the diagnosis and management of thrombotic thrombocytopenic purpura and other thrombotic microangiopathies. *Br J Haematol.* 2012;158:323–35.
- Tagami T, Matsui H, Horiguchi H, Fushimi K, Yasunaga H. Antithrombin and mortality in severe pneumonia patients with sepsis-associated disseminated intravascular coagulation: an observational nationwide study. *J Thromb Haemost.* 2014;12:1470–9.
- Yoshii Y, Fujimura Y, Bennett CL, Isonishi A, Kurumatani N, Matsumoto M. Implementation of a rapid assay of ADAMTS13 activity was associated with improved 30-day survival rate in patients with acquired primary thrombotic thrombocytopenic purpura who received platelet transfusions. *Transfusion.* 2017;57:2045–53.
- Grisaru S, Xie J, Samuel S, Hartling L, Tarr PI, Schnadower D, Freedman SB, Alberta Provincial Pediatric Enteric Infection Team. Associations between hydration status, intravenous fluid administration, and outcomes of patients infected with Shiga toxin-producing *Escherichia coli*: a systematic review and meta-analysis. *JAMA Pediatr.* 2017;171:68–76.
- Berger BE. The alternative pathway of complement and the evolving clinical-pathophysiological Spectrum of atypical hemolytic uremic syndrome. *Am J Med Sci.* 2016;352:177–90.
- Schwameis M, Schörgenhofer C, Assinger A, Steiner MM, Jilma B. WVF excess and ADAMTS13 deficiency: a unifying pathomechanism linking inflammation to thrombosis in DIC, malaria, and TTP. *Thromb Haemost.* 2015;113:708–18.
- Wada H. Disseminated intravascular coagulation. *Clin Chim Acta.* 2004;344:13–21.
- Yamashita Y, Naitoh K, Wada H, Ikejiri M, Mastumoto T, Ohishi K, Hosaka Y, Nishikawa M, Katayama N. Elevated plasma levels of soluble platelet glycoprotein VI (GPVI) in patients with thrombotic microangiopathy. *Thromb Res.* 2014;133(3):440–4.
- Ito-Habe N, Wada H, Matsumoto T, Ohishi K, Toyoda H, Ishikawa E, Nomura S, Komada Y, Ito M, Nobori T, Katayama N. Elevated Von Willebrand factor propeptide for the diagnosis of thrombotic microangiopathy and for predicting a poor outcome. *Int J Hematol.* 2011;93:47–52.
- Sase T, Wada H, Nishioka J, Abe Y, Gabazza EC, Shiku H, Suzuki K, Nakamura S, Nobori T. Measurement of tissue factor messenger RNA levels in leukocytes from patients in hypercoagulable state caused by several underlying diseases. *Thromb Haemost.* 2003;89:660–5.
- Sase T, Wada H, Kamikura Y, Kaneko T, Abe Y, Nishioka J, Nobori T, Shiku H. Tissue factor messenger RNA levels in leukocytes compared with tissue factor antigens in plasma from patients in hypercoagulable state caused by various diseases. *Thromb Haemost.* 2004;92:132–9.
- Wada H, Tamaki S, Tanigawa M, Takagi M, Deguchi A, Mori Y, Katayama N, Yamamoto T, Deguchi K, Shirakawa S. Plasma level of IL-1 $\beta$  in disseminated intravascular coagulation. *Thrombo Haemost.* 1991;65:364–8.
- Wada H, Ohiwa M, Kaneko T, Tamaki S, Tanigawa M, Takagi M, Mori M, Shirakawa M. Plasma level of tumor necrosis factor in disseminated intravascular coagulation. *Am J Hematol.* 1991;37:147–51.
- Duburcq T, Tournays A, Gnemmi V, Hubert T, Gmyr V, Pattou F, Jourdain M. Impact of obesity on endotoxin-induced disseminated intravascular coagulation. *Shock.* 2015;44:341–7.
- Matsumoto T, Kaneko T, Wada H, Kobayashi T, Abe Y, Nobori T, Shiku H, Stearns-Kurosawa DJ, Kurosawa S. Proteinase 3 expression on neutrophil membranes from patients with infectious disease. *Shock.* 2006;26:128–33.
- Kobayashi T, Wada H, Nishioka J, Yamamoto M, Matsumoto T, Tamaru T, Nomura S, Masuya M, Mori Y, Nakatani K, Nishikawa M, Katayama N, Nobori T. ADAMTS13 related markers and Von Willebrand factor in plasma from patients with thrombotic Microangiopathy (TMA). *Thromb Res.* 2008;121:849–54.
- Franchini M, Montagnana M, Targher G, Lippi G. Reduced von Willebrand factor-cleaving protease levels in secondary thrombotic microangiopathies and other diseases. *Semin Thromb Hemost.* 2007;33:787–97.
- Ruggeri ZM, Zimmerman TS. The complex multimeric composition of factor VIII/von Willebrand factor. *Blood.* 1981;57:1140–3.
- Arya M, Anvari B, Romo GM, Cruz MA, Dong JF, McIntire LV, Moake JL, Lopez JA. Ultralarge multimers of von Willebrand factor form spontaneous high-strength bonds with the platelet glycoprotein Ib-IX complex: studies using optical tweezers. *Blood.* 2002;99:3971–7.
- Wada T, Gando S, Maekawa K, Katabami K, Sageshima H, Hayakawa M, Sawamura A. Disseminated intravascular coagulation with increased fibrinolysis during the early phase of isolated traumatic brain injury. *Crit Care.* 2017;21:219.
- Oldenburg J, Mahlangu JN, Kim B, Schmitt C, Callaghan MU, Young G, Santagostino E, Kruse-Jarres R, Negrier C, Kessler C, et al. Efficacy of emicizumab prophylaxis in hemophilia a with inhibitors. *N Engl J Med.* 2017;377:809–18.
- Wada H, Matsumoto T, Katayama N. Efficacy of emicizumab prophylaxis in hemophilia a with inhibitors. *N Engl J Med.* 2017;377:2193–4.
- Fujimura Y, Matsumoto M, Isonishi A, Yagi H, Kokame K, Soejima K, Murata M, Miyata T. Natural history of Upshaw-Schulman syndrome based on ADAMTS13 gene analysis in Japan. *J Thromb Haemost.* 2011;9:283–301.
- Kobayashi N, Maekawa T, Takada M, Tanaka H, Gonmori H. Criteria for diagnosis of DIC based on the analysis of clinical and laboratory findings in 345 DIC patients collected by the research committee on DIC in Japan. *Bibl Haematol.* 1983;49:265–75.
- Gando S, Saitoh D, Ogura H, Mayumi T, Koseki K, Ikeda T, et al. Japanese Association for Acute Medicine Disseminated Intravascular Coagulation (JAAM DIC) study group: natural history of disseminated intravascular coagulation diagnosed based on the newly established diagnostic criteria

- for critically ill patients: results of a multicenter, prospective survey. *Crit Care Med.* 2008;36:145–50.
37. Asakura H, Takahashi H, Uchiyama T, Eguchi Y, Okamoto K, Kawasugi K, Madoiwa S, Wada H. DIC subcommittee of the Japanese Society on Thrombosis and Hemostasis: Proposal for new diagnostic criteria for DIC from the Japanese Society on Thrombosis and Hemostasis. *Thromb J.* 2016;14:42.
  38. Wada H, Takahashi H, Uchiyama T, Eguchi Y, Okamoto K, Kawasugi K, Madoiwa S, Asakura H. DIC subcommittee of the Japanese Society on Thrombosis and Hemostasis: The approval of revised diagnostic criteria for DIC from the Japanese Society on Thrombosis and Hemostasis. *Thromb J.* 2017;15:17.
  39. Takemitsu T, Wada H, Hatada T, Ohmori Y, Ishikura K, Takeda T, Sugiyama T, Yamada N, Maruyama K, Katayama N, Isaji S, Shimpo H, Kusunoki M, Nobori T. Prospective evaluation of three different diagnostic criteria for disseminated intravascular coagulation. *Thromb Haemost.* 2011;105:40–4.
  40. Terano C, Ishikura K, Hamada R, Yoshida Y, Kubota W, Okuda Y, Shinozuka S, Harada R, Iyoda S, Fujimura Y, Hamasaki Y, Hataya H, Honda M. Practical issues in using eculizumab for children with atypical hemolytic uremic syndrome in the acute phase: a review of 4 patients. *Nephrology (Carlton).* 2017; in press
  41. Kato H, Nangaku M, Hataya H, Sawai T, Ashida A, Fujimaru R, Hidaka Y, Kaname S, Maruyama S, Yasuda T, Yoshida Y, Ito S, Hattori M, Miyakawa Y, Fujimura Y, Okada H, Kagami S. Joint Committee for the Revision of clinical guides of atypical hemolytic uremic syndrome in Japan: clinical guides for atypical hemolytic uremic syndrome in Japan. *Pediatr Int.* 2016;58:549–55.
  42. Ono T, Mimuro J, Madoiwa S, Soejima K, Kashiwakura Y, Ishiwata A, Takano K, Ohmori T, Sakata Y. Severe secondary deficiency of von Willebrand factor-cleaving protease (ADAMTS13) in patients with sepsis-induced disseminated intravascular coagulation: its correlation with development of renal failure. *Blood.* 2006;107:528–34.
  43. Habe K, Wada H, Ito-Habe N, Hatada T, Matsumoto T, Ohishi K, Maruyama K, Imai H, Mizutani H, Nobori T. Plasma ADAMTS13, von Willebrand factor (VWF) and VWF propeptide profiles in patients with DIC and related diseases. *Thromb Res.* 2012;129:598–602.
  44. Wada H, Matsumoto T, Hatada T. Diagnostic criteria and laboratory tests for disseminated intravascular coagulation. *Expert Rev Hematol.* 2012;5:643–52.
  45. Rafiq A, Tariq H, Abbas N, Shenoy R. Atypical hemolytic-uremic syndrome: a case report and literature review. *Am J Case Rep.* 2015;16:109–14.
  46. Ito N, Wada H, Matsumoto M, Fujimura Y, Murata M, Izuno T, Sugita M, Ikeda Y. National questionnaire survey of TMA. *Int J Hematol.* 2009;90:328–35.
  47. Rock GA, Shumak KH, Buskard NA, Blanchette VS, Kelton JG, Nair RC, Spasoff RA, Group CAS. Comparison of plasma exchange with plasma infusion in the treatment of thrombotic thrombocytopenic purpura. *N Engl J Med.* 1991;325:393–7.
  48. Iba T, Gando S, Saitoh D, Wada H, Di Nisio M, Thachil J. Antithrombin supplementation and risk of bleeding in patients with sepsis-associated disseminated intravascular coagulation. *Thromb Res.* 2016;145:46–50.
  49. Hayakawa M, Yamakawa K, Saito S, Uchino S, Kudo D, Iizuka Y, Sanui M, Takimoto K, Mayumi T, Ono K. Japan septic disseminated intravascular coagulation (JSEPTIC DIC) study group: recombinant human soluble thrombomodulin and mortality in sepsis-induced disseminated intravascular coagulation. A multicentre retrospective study. *Thromb Haemost.* 2016;115:1157–66.
  50. Legendre CM, Licht C, Muus P, Greenbaum LA, Babu S, Bedrosian C, Bingham C, Cohen DJ, Delmas Y, Douglas K, Eitner F, Feldkamp T, Fouque D, Furman RR, Gaber O, Herthelius M, Hourmant M, Karpman D, Lebranchu Y, Mariat C, Menne J, Moulin B, Nürnberger J, Ogawa M, Remuzzi G, Richard T, Sberro-Soussan R, Severino B, Sheerin NS, Trivelli A, Zimmerhackl LB, Goodship T, Loirat C. Terminal complement inhibitor eculizumab in atypical hemolytic-uremic syndrome. *N Engl J Med.* 2013 Jun 6;368:2169–81.
  51. George JN, Woodson RD, Kiss JE, Kojouri K, Vesely SK. Rituximab therapy for thrombotic thrombocytopenic purpura: a proposed study of the transfusion medicine/hemostasis clinical trials network with a systematic review of rituximab therapy for immune-mediated disorders. *J Clin Apheresis.* 2006;21:49–56.

Submit your next manuscript to BioMed Central and we will help you at every step:

- We accept pre-submission inquiries
- Our selector tool helps you to find the most relevant journal
- We provide round the clock customer support
- Convenient online submission
- Thorough peer review
- Inclusion in PubMed and all major indexing services
- Maximum visibility for your research

Submit your manuscript at  
[www.biomedcentral.com/submit](http://www.biomedcentral.com/submit)

