

Oncology

Investigation of a renal mass: Diagnosing renal paraganglioma

Lucy Elizabeth Hempenstall^{a,*,1}, Amila R. Siriwardana^b, Devang J. Desai^c^a Toowoomba Rural Clinical School University of Queensland, Urology Department Toowoomba Hospital, QLD, Australia^b Urology Department Princess Alexandra Hospital, Brisbane, QLD, Australia^c Toowoomba Hospital QLD, Toowoomba Urology, Senior Lecturer University of Queensland, Australia

ARTICLE INFO

Keywords:

Renal paraganglioma
MIBG scintigraphy

Introduction

Catecholamine-secreting tumours are rare, neuroendocrine tumours that arise from chromaffin cells in the adrenal medulla or sympathetic chain.^{1–3} They are divided into pheochromocytomas (intra-adrenal) and paragangliomas (extra-adrenal).¹ These lesions emit catecholamines into the circulation triggering hypertension, headaches, diaphoresis, palpitations and tremors.¹ Due to the variety of non-specific symptoms, the diagnosis of these lesions can be especially challenging.

Case report

A 77-year-old female was referred to our regional Urology Outpatient Department with an incidental finding of a presumed renal mass in the upper pole of the left kidney. It was initially identified on imaging as part of investigation for biliary colic.

The patient denied haematuria, flank pain or unintentional weight loss. There were no features to suggest any paraneoplastic syndrome. Her medical history included hypertension, chronic obstructive pulmonary disease and a 40-pack year smoking history.

Ultrasound imaging described a mass measuring 63 × 62 × 47mm in dimension interposed between the inferior pole of the spleen and the superior pole of the left kidney. It was suggestive of a possible adrenal lesion.

Subsequent contrast computed tomography (CT) abdomen and pelvis characterised the lesion as an exophytic upper pole cortical mass in the left kidney measuring 72 × 60 × 51mm (Fig. 1). It was heterogeneous in enhancement with solid and cystic components, and was reported as a likely renal cell carcinoma (RCC). Bilateral adrenal glands were reported normal. No lymphadenopathy or other solid organ

lesions were identified. In addition, the patient underwent a positron emission scan (PET) CT that showed only mild avidity in the left renal mass.

Renal function was stable with an estimated glomerular filtration rate (eGFR) was 62 (normal > 59) and creatinine measured 82 μmol/L (normal 45–90 μmol/L). Three urine cytology specimens were negative for urothelial malignancy. Due to the possibility of a primary adrenal mass given the tumour location, investigations were ordered to exclude a possible pheochromocytoma.

24-h urine normetadrenaline and metadrenaline were secreted at approximately 15 times the upper limit of normal. Normetadrenaline measured 36 μmol/24h (normal = < 2.3 μmol/24h) and metadrenaline measured 11 μmol/24h (normal = < 1.3 μmol/24h). These results were further confirmed on serology with plasma normetadrenaline measuring 22 000pmol/L (normal = < 900pmol/L) and plasma metadrenaline level measuring 3120pmol/L (normal < 500pmol/L); raising the possibility of a catecholamine-producing lesion.

In light of these positive results, whole body MIBG study using 233Mq 123I-MIBG was ordered. The intensity of the tracer activity corresponded to a large lesion arising in the superior aspect of the left kidney measuring 74 × 59 × 49 mm (Fig. 2). This lesion was separate from the left adrenal gland. No other MIBG avid masses were identified indicative of metastasis. This investigation thus supported the diagnosis of a paraganglioma located in the upper pole of the left kidney.

Discussion

Of all catecholamine-secreting tumours, 15% of are paragangliomas, 5–10% are multiple and 10% are malignant.² The majority of paragangliomas occur in the retroperitoneum (85%),² and

* Corresponding author. Toowoomba Hospital, Toowoomba, QLD, 4350, Australia.

E-mail address: lucy.hempenstall@health.qld.gov.au (L.E. Hempenstall).¹ The corresponding author is not the recipient of a research scholarship.

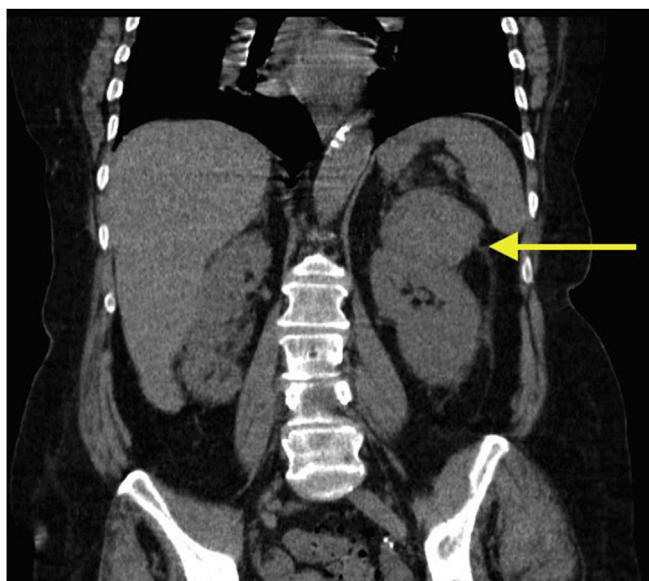


Fig. 1. Coronal section of a computed tomography (CT) abdomen and pelvis scan depicting a left kidney upper pole mass measuring $72 \times 60 \times 51$ mm (indicated by the yellow arrow). Appearances are suggestive of a possible renal cell carcinoma. (For interpretation of the references to colour in this figure legend, the reader is referred to the Web version of this article.)

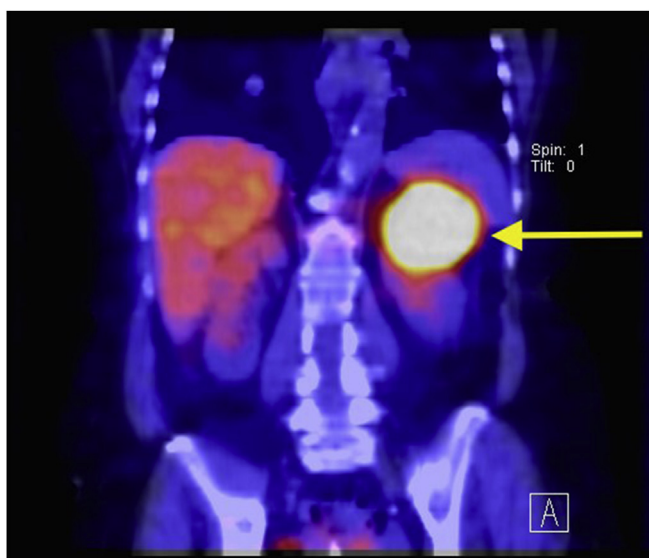

Fig. 2. $233\text{Mbc }^{123}\text{I-MIBG}$ SPECT CT coronal section of the abdomen scanned at 4 hours post MIBG injection illustrating high MIBG avidity of the left upper kidney lesion measuring $74 \times 59 \times 49$ mm (indicated by the yellow arrow). This lesion corresponds the lesion identified on CT scan and confirms a renal paraganglioma. (For interpretation of the references to colour in this figure legend, the reader is referred to the Web version of this article.)

paragangliomas are more likely to be malignant (40%) than pheochromocytomas (10%).³ Malignant paragangliomas are characterised by the presence of distant sites of metastasis.³ Sympathetic paragangliomas of the kidney are extremely rare and the mechanism by which they develop in the kidney is unknown.⁴ They may occur in the hilum (32%), upper pole (26%) or lower pole (42%) of the kidney.⁵

Functional studies using iodine labeled metaiodobenzylguanidine (123I-MIBG) are performed to localise catecholamine-secreting lesions.¹ 123I-MIBG is a noradrenaline analogue that is stored within intracellular storage granules of the presynaptic adrenergic neurons.⁶ In

this case, MIBG scintigraphy was highly avid in the left upper pole of the kidney (Fig. 2).

This patient's journey emphasizes the diagnostic challenge associated with diagnosing renal tumours. She was largely asymptomatic from this lesion, however in retrospect had difficulty to treat hypertensive disease and was prescribed multiple anti-hypertensive medications prior to diagnosis. Many features initially favoured the diagnosis of RCC including the patient's age, smoking status and RCC being the most common cause of malignant renal tumours. The CT scan appearance of the lesion was described as likely RCC, however there are currently no criteria to distinguish RCC from pheochromocytoma on CT imaging.⁶

The current mainstay of treatment for paragangliomas is complete resection, in this case a total left nephrectomy would be recommended. Careful perioperative management is required with preoperative treatment aimed at adrenergic blockage with alpha and beta blocking agents to avoid intraoperative complications such as lethal hypertensive crisis and arrhythmias with tumour handling.¹ Removing catecholamine-secreting tumours is an exceedingly high-risk procedure and should be performed at a centre with a specialized operating team.

This patient, however, declined operative treatment and planned for conservative management. She is currently prescribed phenoxylbenzamine 20–30mg daily under endocrine specialist guidance and has been referred to palliative care services.

Conclusion

This patient's renal mass was identified, characterised and diagnosed by different imaging modalities. Renal paraganglioma is a rare condition, and the patient may have been misdiagnosed with RCC had further investigation and MIBG scintigraphy not been performed. Thus, careful consideration is required when evaluating renal masses.

General urology

Declarations of interest

None.

Acknowledgments

This research did not receive any specific grant from funding agencies in the public, commercial, or not-for-profit sectors.

Appendix A. Supplementary data

Supplementary data related to this article can be found at <https://doi.org/10.1016/j.eucr.2018.08.001>.

References

- Carty SY W. Paragangliomas: epidemiology, clinical presentation, diagnosis, and histology: UpToDate. . [updated 15 August 2017. Available from: <https://www.uptodate.com/contents/paragangliomas-epidemiology-clinical-presentation-diagnosis-and-histology>; 2018.
- Disick GI, Palese MA. Extra-adrenal pheochromocytoma: diagnosis and management. *Curr Urol Rep.* 2007;8(1):83–88.
- Yehia ZA, Sayyid RK, Haydar AA. Renal hilar paraganglioma: a case report. *World J Radiol.* 2014;6(1):15–17.
- Alberti C. Urology pertinent neuroendocrine tumors: focusing on renal pelvis, bladder, prostate located sympathetic functional paragangliomas. *Geka Chiryo.* 2016;37(2):55–60.
- Hayes WS, Davidson AJ, Grimley PM, Hartman DS. Extraadrenal retroperitoneal paraganglioma: clinical, pathologic, and CT findings. *AJR Am J Roentgenol.* 1990;155(6):1247–1250.
- Wiseman GA, Pacak K, O'Dorisio MS, et al. Usefulness of 123I-MIBG scintigraphy in the evaluation of patients with known or suspected primary or metastatic pheochromocytoma or paraganglioma: results from a prospective multicenter trial. *J Nucl Med.* 2009;50(9):1448–1454.