

Case Report

# Traumatic thoracic spine spondyloptosis treated with spondylectomy and fusion

Arash Fattahi, Abdoulhadi Daneshi

Department of Neurosurgery, 7tir Hospital, Iran University of Medical Sciences, Tehran, Iran

E-mail: \*Arash Fattahi - arashmedicine@gmail.com; Abdoulhadi Daneshi - drmd\_daneshi@yahoo.com

\*Corresponding author

Received: 23 June 18    Accepted: 13 July 18    Published: 10 August 18


## Abstract

**Background:** There are multiple surgical treatment options for traumatic thoracic spine spondyloptosis, a three-column spinal injury typically attributed to high-energy trauma.

**Case Description:** A 20-year-old male presented with back deformity attributed to a fall. On neurological examination, he had complete spinal cord injury below the T6 level. Magnetic resonance and computed tomography imaging documented a T8 vertebral fracture and complete T7/T8 spondyloptosis. Six days following admission, he underwent a single posterior procedure consisting of a T8 spondylectomy and instrumented fusion from T5 to T11. The patient was mobilized in a wheelchair on the 3<sup>rd</sup> postoperative day and was discharged on the 11<sup>th</sup> day following admission. Three months later, the surgical construct was fused and the patient’s neurological status remained unchanged.

**Conclusion:** Here we present a patient who following a fall sustained a T7/T8 spondyloptosis resulting in paraplegia treated with a single posterior T8 spondylectomy with T5–T11 instrumented fusion.

**Key Words:** Complete cord injury, spondylectomy, spondyloptosis, thoracic spine, trauma

<b>Access this article online</b>
<b>Website:</b> <a href="http://www.surgicalneurologyint.com">www.surgicalneurologyint.com</a>
<b>DOI:</b> 10.4103/sni.sni_204_18
<b>Quick Response Code:</b>


## INTRODUCTION

Traumatic thoracic spine spondyloptosis (TTS) is a three-column spinal injury that typically results in paralysis.<sup>[1,4]</sup> Due to the thoracic rib cage and its connection with sternum, TTS is typically attributed to very high-energy trauma.<sup>[3]</sup> Surgery typically requires both reduction and fusion of the deformity. Different treatment options for TTS include intraoperative axilla-pelvic distraction and fusion, *in situ* fixation and fusion, or corpectomy with cage placement.<sup>[1,2,4,7]</sup> Here we present a case of T7/T8 TTS surgically treated with a total of T8 spondylectomy and T5–T11 posterior instrumented fusion.

## CASE REPORT

A 20-year-old male was admitted with paraplegia after a 9-m fall. He initially underwent emergent bilateral chest

This is an open access journal, and articles are distributed under the terms of the Creative Commons Attribution-NonCommercial-ShareAlike 4.0 License, which allows others to remix, tweak, and build upon the work non-commercially, as long as appropriate credit is given and the new creations are licensed under the identical terms.

**For reprints contact:** reprints@medknow.com

**How to cite this article:** Fattahi A, Daneshi A. Traumatic thoracic spine spondyloptosis treated with spondylectomy and fusion. *Surg Neurol Int* 2018;9:158. <http://surgicalneurologyint.com/Traumatic-thoracic-spine-spondyloptosis-treated-with-spondylectomy-and-fusion/>

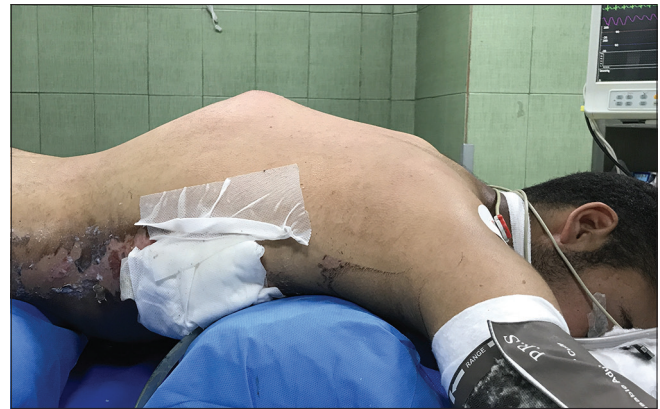tube placement for a hemothorax. As he was paraplegic with a T6 sensory level, computed tomography thoracic studies were performed. These revealed a T8 body fracture and T7/T8 spondyloptosis [Figures 1 and 2]. Six days later, he underwent reduction of the spondyloptotic T7/8 deformity, total T8 spondylectomy with discectomy of T7/T8 and T8/T9, and instrumented fusion and bilateral pedicular screw fixation from T5 to T11 [Figure 3]. The accompanying dura laceration was not repaired (circumferential rupture of the cord and dura were noted). A sub-fascial drain was placed and was removed on the third postoperative day; there was no secondary cerebrospinal fluid fistula. The patient was mobilized in a wheelchair on the 3<sup>rd</sup> postoperative day and discharged the 11<sup>th</sup> day following admission. Three months later, the fusion construct was intact, but the patient's neurological status remained unchanged (e.g., complete paraplegia).

## DISCUSSION

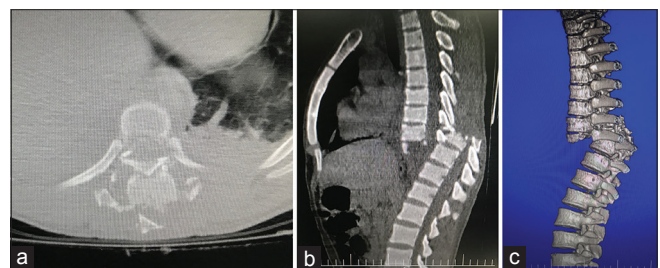
Surgical treatment of TTS is very complex problem and requires a multidisciplinary approach. Injury to great arteries of thoracic cage and other vital organs can complicate management. With complete cord disruption, as in the case presented, delayed surgery helps reduce perioperative surgical complications and life-threatening events (e.g., aortic or vena cava injuries).

Rahimizadeh and Rahimizadeh reported a patient with a retro-spondyloptosis of T2 requiring total spondylectomy, intraoperative distraction, and T1–T3 fusion.<sup>[5]</sup> Farooque *et al.* presented a patient with spondyloptosis at the T9/T10 level treated with *in situ* fixation/fusion.<sup>[1]</sup> Sandquist *et al.* presented a T12/L1 spondyloptosis treated with spondylectomy of L1 and T8 to L4 instrumented fusion.<sup>[6]</sup> Here in a patient with T7/T8 spondyloptosis, we performed a T8 spondylectomy and fused T5–T11 (e.g. relatively short fusion construct).

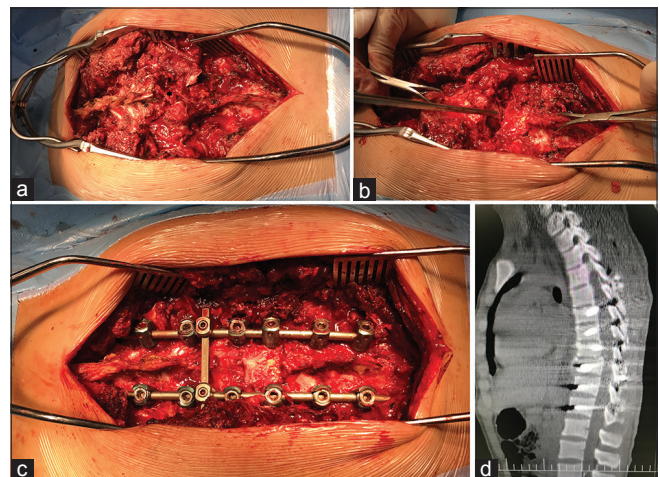
Goals of surgery for TTS in patients with complete spinal cord injuries include minimizing major displacement during the reduction of displaced vertebrae to avoid great thoracic vessel injuries. Although some authors report success using axilla-pelvic distraction for deformity reduction, these procedures increase risks/complications.<sup>[2]</sup> Where only one vertebra is removed (e.g., spondylectomy) and accompanied by pedicle/screw fixation/fusion, excessive traction and its complications are avoided. This procedure, also called “shortening of the spinal column,” can reduce the surgical time without impacting neurological outcomes (e.g., already a complete spinal cord injury). Furthermore, if the dura is lacerated and there is full cord transection, there is no need for dural repair.



**Figure 1: Photograph revealing severe stepping and deformity of back on the prone position**



**Figure 2: Preoperative axial (a), sagittal (b), and three-dimensional (c) reconstruction computed tomography revealing a T8 body fracture with spondyloptosis of T7 on T8 concomitant with severe deformity**



**Figure 3: Intraoperative illustrations before (a) and after (b) spondylectomy showing complete release of the spine after T8 removal and also cross section of the cord and dura (\*). Also we can see intraoperative illustration showing spinal curve after instrumentation (c). Postoperatively sagittal reconstructed (d) computed tomography revealing good realignment of the spine with instrumented fusion between T5, T6, T7, T9, T10, and T11**

## CONCLUSION

Here we presented a patient with a TTS attributed to T7/T8 spondyloptosis and a complete spinal cord injury

requiring T8 spondylectomy and T5–T11 pedicle screw instrumented fusion.

### Declaration of patient consent

The authors certify that they have obtained all appropriate patient consent forms. In the form the patient(s) has/have given his/her/their consent for his/her/their images and other clinical information to be reported in the journal. The patients understand that their names and initials will not be published and due efforts will be made to conceal their identity, but anonymity cannot be guaranteed.

### Financial support and sponsorship

Nil.

### Conflicts of interest

There are no conflicts of interest.

## REFERENCES

1. Farooque K, Khatri K, Gupta A. Missed traumatic thoracic spondyloptosis with no neurological deficit: A case report and literature review. *Trauma Mon* 2016;21:e19841.
2. Lee CW, Hwang SC, Im SB, Kim BT, Shin WH. Traumatic thoracic spondyloptosis: A case report. *J Korean Neurosurg Soc* 2004;35:624.
3. Meneghini RM, DeWald CJ. Traumatic posterior spondyloptosis at the lumbosacral junction. A case report. *J Bone Joint Surg Am* 2003;85-A: 346-50.
4. Mishra A, Agrawal D, Gupta D, Sinha S, Satyarthee GD, Singh PK, et al. Traumatic spondyloptosis: A series of 20 patients. *J Neurosurg Spine* 2015;22:647-52.
5. Rahimizadeh A, Rahimizadeh A. Management of traumatic double-level spondyloptosis of the thoracic spine with posterior spondylectomy: Case report. *J Neurosurg Spine* 2015;23:715-20.
6. Sandquist L, Paris A, Fahim DK. Definitive single-stage posterior surgical correction of complete traumatic spondyloptosis at the thoracolumbar junction. *J Neurosurg Spine* 2015;22:653-7.
7. Sekhon LH, Sears W, Lynch JJ. Surgical management of traumatic thoracic spondyloptosis: Review of 2 cases. *J Clin Neurosci* 2007;14:770-5.