

**CASE REPORT**

# New mutations in the *SLC7A7* gene of two chinese sisters with lysinuric protein intolerance

Guoqing Zhang | Ling Cao

The Children's Hospital affiliated to the Capital Institute of Pediatrics, Beijing, China

**Correspondence**

Ling Cao, The Children's Hospital affiliated to the Capital Institute of Pediatrics, Beijing, China.

Email: caoling9919@163.com

**Abstract**

Lysinuric protein intolerance (LPI) is an inherited aminoaciduria with an autosomal recessive mode of inheritance. The first two cases of sisters being diagnosed with LPI in China is contained within this report. In our cases, there were two heterozygous mutations in the *SLC7A7* gene of the two sisters: deletion of c.1387: del C and IVS4+1C>T. One patient was treated with inhaled rGM-CSF for 1.5 years at 5 µg/kg two times a day. Her condition is improving with no side effects.

**KEYWORDS**

gene mutation, GM-CSF, lysinuric protein intolerance (LPI)

## 1 | CASE ONE

A 6-year-old girl was admitted to our hospital with chronic dyspnea occurring over 5 years and increasing in severity within the proceeding 2 months. When she was 1 year old, she was suffered from fever followed by the onset of dyspnea. After treating with prednisone and antibiotics, Over the next 5 years, she was administrated prednisone 5 mg/d. Three to five times a year, she suffered from respiratory tract infection in addition to severe dyspnea. During these periods, prednisone dosage was increased to 30 mg/d. Her physical activity was gradually limited. She developed clubbed fingers. Two months before admission, she fractured her right arm. At the same time, she experienced high fever with respiratory distress and was treated with endotracheal intubation mechanical ventilation at a local hospital for 8 days. The patient was the younger of the two siblings. Her physical development was delayed. She suffered from occasional vomiting and poor appetite after age one. Her parents had no history of chronic diseases.

The patient's height was 103 cm, weight was 13.7 kg, BMI 12.9. Her height and weight were both below the 3rd percentile within her age group. Her oxygen saturation was 95% when using a nasal oxygen tube with an oxygen supplementation of 4 L/min. Physical examination revealed respiratory distress with tachypnea. Pulmonary auscultation

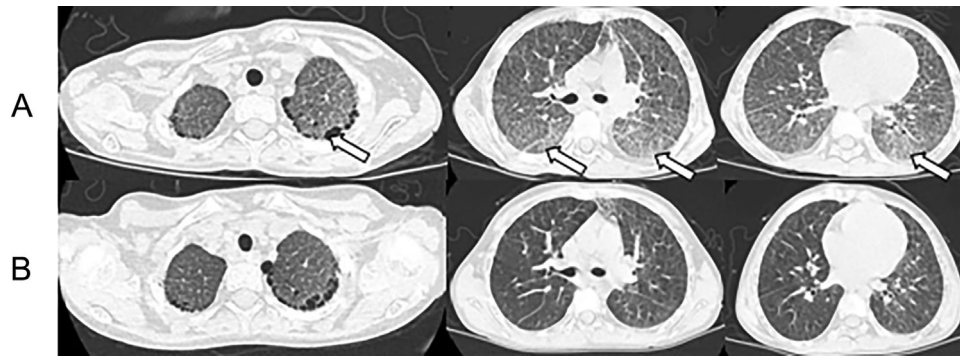
revealed no abnormalities. In her abdomen, the liver was palpable three finger-breadth below the right costal margin and the spleen with palpable three finger-breadth below the left costal margin. Clubbed fingers was present.

A chest HRCT revealed the presence of crazy paving patterns (Fig. 1A). Additionally a Periodic Acid-Schiff (PAS) stain of the bronchoalveolar lavage fluid was confirmed positive. Abdominal ultrasonography revealed diffuse enlargement of the liver and spleen. Blood ammonia was 51 µmol/L (11-40). Serum ferritin was 159.89 ng/mL (10-120). Metabolic disease screening by blood testing showed Citrulline was 199 µmol/L (2.7-38), Arginine was 15.98 µmol/L (0-50), and Citrulline/Arginine was 12.44 (<7). Urine tests showed increased Uracil. Both lower extremities and left wrist X ray showed osteoporosis. The mutation in the *SLC7A7* gene included C.1387 del C and IVS4+1C>T, which originated from the patient's father and mother, respectively. Thus, we diagnosed the patient as having lysinuric protein intolerance (LPI) associated pulmonary alveolar proteinosis (PAP).

After the patient was admitted, corticosteroid treatment was discontinued. The patient was treated with segmental lung lavage four times within 1 month of admission without noticeable improvement. At this time, we decided to treat with rGM-CSF at 5 µg/kg two times a day. The respiratory conditions improved slightly and the required

This is an open access article under the terms of the Creative Commons Attribution-NonCommercial License, which permits use, distribution and reproduction in any medium, provided the original work is properly cited and is not used for commercial purposes.

© 2017 The Authors. *Pediatric Pulmonology* Published by Wiley Periodicals.



**FIGURE 1** (A) At admission, multiple small cystic lucency in subpleural and crazy paving pattern. (B) 1.5 years later, areas of ground glass attenuation are no longer visible

oxygen supplementation at rest state gradually decreased to 1 L/min. After 3 months of rGM-CSF treatment the patient could breathe without inhaled oxygen. The result of her lung function tests showed FEV<sub>1</sub> at a level below detection limit, FVC at 85.5% of predicted. Six months later, she could walk 100-200 m; 18 months later, she could walk 1000-1500 m and climb up three floors of stairs. At this time, FVC was at 91.4% of predicted, FEV<sub>1</sub> was at 90.3% of predicted, FEV<sub>1</sub>/FVC was at 100.3%, DLCO was at 71.3% of predicted. Her chest HRCT showed significant improvements (Fig. 1B). Blood ammonia was 50 umol/L. Her complete blood count was normal during the period of inhaled rGM-CSF treatment.

## 2 | CASE TWO

The patient was a 9-year-old girl who was the elder sister of the patient in case one. At 2 years old, the patient suffered from cyanosis and dyspnea after physical activity. She had clubbed-finger. When the patient was 4 years old, her chest HRCT revealed crazy paving pattern (Fig. 2A). Using results of a lung biopsy, she was diagnosed with chronic interstitial pneumonia at a local hospital and was prescribed corticosteroid. At 8 years old, she stopped taking corticosteroid. Her physical activity is normal for her age group.

The patient's height was 142 cm, weight was 29 kg, BMI 14.4. Her height and weight were both below the 75th percentile within her age group. Her oxygen saturation was 98% without oxygen supplementation. Pulmonary auscultation revealed no abnormalities. Clubbed-finger was present but not as notably as in her younger sister.

We used lung tissue obtained from her previous biopsy to perform a PAS stain which had a positive result. Her chest HRCT showed patches and nodular opacities on the apicoposterior of the left lung lobe, multiple cystic lucency in subpleural of both upper lobes (Fig. 2B). Like her sister, the patient had a mutation in the *SLC7A7* gene including C.1387 del C and IVS4+1C>T. Her Lung function tests showed FVC at 69% of predicted, FEV<sub>1</sub> at 73% of predicted, FEV<sub>1</sub>/FVC at 110%, DLCO at 56% of predicted. Abdominal ultrasonography revealed diffuse enlargement of the liver and spleen. Blood ammonia was 60 umol/L (11-40). Serum ferritin was 568.98 ng/mL (10-120). Metabolic disease screening by blood testing showed Citrulline was

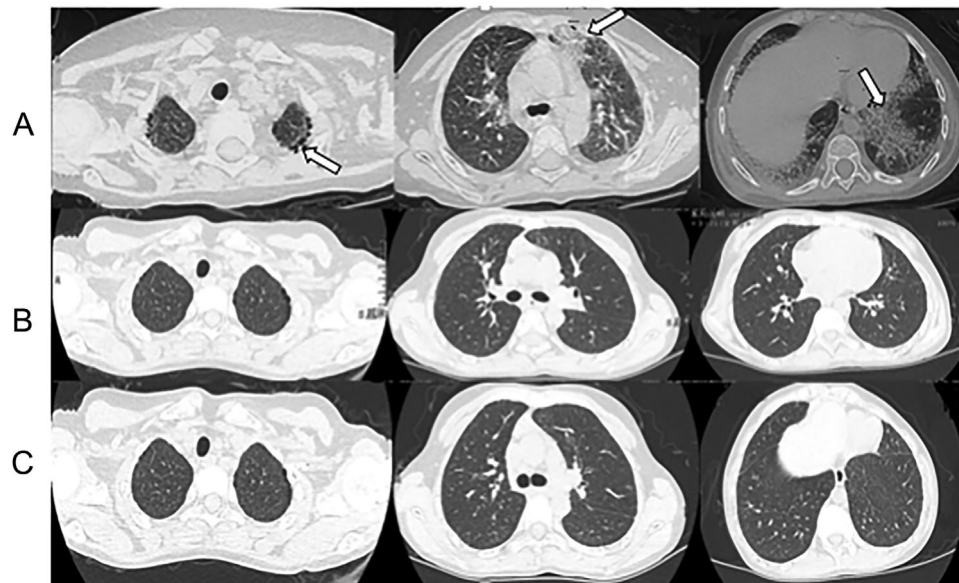
33.25 umol/L (2.7-38), Arginine was 1.87 umol/L (0-50), Citrulline/Arginine was 17.71 (<7). Increased lysine was shown through urine tests. The patient was also diagnosed LPI with PAP. We recommended she restrict protein intake then supplement with vitamins and calcium. She chosen not to inhale rGM-CSF due to economic reasons. Eighteen months later, her lung function test result showed FVC at 68.2% of predicted, FEV<sub>1</sub> at 74.9% of predicted, FEV<sub>1</sub>/FVC at 111.1%, DLCO at 64.5% of predicted. Her chest HRCT showed no improvement compared to her condition at admission (Fig. 2C). Blood ammonia was 40 umol/L (11-40).

## 3 | DISCUSSION

To our knowledge, LPI is mostly found in Finland and Japan. The incidence of LPI in Japan is about 1/57 000.<sup>1</sup> If we use this incidence rate, there should be about 1500 LPI patients born in China every year. Yet, there are no case reports of LPI in China.

LPI is a rare inherited metabolic disorder of dibasic amino acid transport. Renal tubular and intestinal transport is deficient, resulting in decreased circulating dibasic amino acid levels. The complications of the disease can be renal (tubulopathy, renal insufficiency), hematological (pancytopenia, macrophage activation syndrome), bone (osteoporosis), and gastrointestinal. However, the major and life-threatening complications involve the lung are manifested as PAP and fibrosis.<sup>1</sup> Only a few papers have been published about LPI specifically presenting as pulmonary symptoms.<sup>2</sup> Linkage analysis was used to locate the pathogenic gene of LPI as *SLC7A7* mutation which is the solution transport vector. At present, 51 kinds of *SLC7A7* gene mutations causing LPI have been found worldwide, including insert (C.1384-1385 ins ACTA), delete (C.1185-1188 del TTCT) and point mutations (P.R410X, P.Y457X, P.R 468X, P.L124p, etc).<sup>3-4</sup> In our cases, there were two heterozygous mutations in the *SLC7A7* gene of the two sisters: C.1387 del C and IVS4+1C>T, which has never been reported worldwide.

Although the exact pathogenesis of PAP in LPI is unclear, disturbances in the function and phagocytic activity of monocyte-derived macrophages has been demonstrated. According to Amelia Barilli study CD204 (Scavenger Receptor A, SR-A), a protein involved in



**FIGURE 2** (A) Five years before admission, multiple cystic lucency in subpleural and crazy paving pattern. (B) At admission, nodular opacities on the apicoposterior of the left lung lobe, multiple cystic lucency in subpleural of both upper lobes. (C) A 1.5 years after admission, no significant improvement compared to at admission

cholesterol uptake;<sup>5</sup> PPAR (Peroxisome Proliferator-Activated Receptor- $\gamma$ ), a key mediator of surfactant catabolism by alveolar macrophages (AM),<sup>6–7</sup> and PU.1, a transcription factor that promotes AM maturation, differentiation, and surfactant catabolism.<sup>8</sup> The treatment with rGM-CSF induced marked expression of all these markers, functioning alveolar macrophages.<sup>9</sup> This study also demonstrated that the presence of the mutated SLC7A7 does not interfere with the GM-CSF induced macrophage differentiation and indicate that mechanisms other than impaired GM-CSF signaling should be investigated to explain LPI-associated PAP. Alternatively, GM-CSF dependent increase of SLC7A7 mRNA may lead to an enhanced synthesis of  $\gamma$ -LAT1 protein that ameliorates macrophage function.<sup>9</sup> PAP inhaled granulocyte-macrophage colony-stimulating factor (GM-CSF) is used off-label in patients with idiopathic PAP with anti-GM-CSF antibodies to activate and attract monocyte-derived macrophages into the lungs. We hypothesize that increasing the activity and the number of alveolar macrophages in the alveolar fluid by recombinant human GM-CSF (rh-GMCSF) inhalation could promote the resolution of PAP also in LPI.

In a similar case, Barilli successfully treated a 21-year-old patient using rGM-CSF.<sup>9</sup> Tanner also reported two patients diagnosed LPI with PAP who were treated with inhaled rGM-CSF and achieved positive results.<sup>10</sup> Our patient from case one inhaled rGM-CSF for 1.5 years. Her exercise tolerance and lung function have improved significantly without noticeable side effects. From this, we conclude that inhaled rGM-CSF may be beneficial for patients with LPI associated PAP.

## REFERENCES

- Noguchi A, Shoji Y, Koizumi A, et al. SLC7A7 genomic structure and novel variants in three Japanese lysinuric protein intolerance families. *Hum Mutat.* 2000;15:367–372.
- Borsani G, Bassi MT, Sperandio MP, et al. SLC7A7, encoding a putative permease-related protein, is mutated in patients with lysinuric protein intolerance. *Nat Genet.* 1999;21:297–301.
- Font-Llitjós M, Rodríguez-Santiago B, Espino M, et al. Novel SLC7A7 large rearrangements in lysinuric protein intolerance patients involving the same AluY repeat. *Eur J Hum Genet.* 2009;17:71–79.
- Smaria P, Genneroso A, Gianfranco S. Lysinuric protein intolerance: update and extended mutation analysis of the SLC7A7 gene. *Hum Mutat.* 2008;29:14–21.
- Glass CK, Witztum JL. Atherosclerosis. the road ahead. *Cell.* 2001;104:503–516.
- Bonfield TL, Farver CF, Barna BP, et al. Peroxisome proliferator-activated receptor $\gamma$  is deficient in alveolar macrophages from patients with alveolar proteinosis. *Am J Respir Cell Mol Biol.* 2003;29:677–682.
- Thomassen MJ, Barna BP, Malur AG, et al. ABCG1 is deficient in alveolar macrophages of GM-CSF knockout mice and patients with pulmonary alveolar proteinosis. *J Lipid Res.* 2007;48:2762–2768.
- Bonfield TL, Raychaudhuri B, Malur A, et al. PU.1 regulation of human alveolar macrophage differentiation requires granulocyte-macrophage colony-stimulating factor. *Am J Physiol Lung Cell Mol Physiol.* 2003;285:L1132–L1136.
- Barilli A, Rotoli MB, Visigalli R, et al. In Lysinuric Protein Intolerance system  $\gamma$ -L activity is defective in monocytes and in GM-CSF-differentiated macrophages. *Orphanet J Rare Dis.* 2010;5:32.
- Tanner LM, Kurko J, Tringham M, et al. Inhaled sargramostim induces resolution of pulmonary alveolar proteinosis in lysinuric protein intolerance. *JIMD Rep.* 2017;34:97–104.

**How to cite this article:** Zhang G, Cao L. New mutations in the SLC7A7 gene of two chinese sisters with lysinuric protein intolerance. *Pediatric Pulmonology.* 2017;52:E94–E96. <https://doi.org/10.1002/ppul.23760>