

Extra-oral dental radiography for disaster victims using a flat panel X-ray detector and a hand-held X-ray generator

Maki Ohtani
Toru Oshima
Sohtaro Mimasaka

*Department of Forensic Sciences,
Akita University Graduate School
of Medicine, Japan*

Corresponding author:
mohtani@doc.med.akita-u.ac.jp

The authors declare that they have no conflict of interest.

ACKNOWLEDGMENT

This work was supported by JSPS KAKENHI Grant Number JP15K11443.

KEYWORDS

disaster victim identification, extra-oral plain dental radiography, flat panel X-ray detector, lateral oblique radiograph, mouth opening, scattered X-rays

J Forensic Odontostomatol 2017. Dec;
(35): 28-34
ISSN :2219-6749

ABSTRACT

Background: Forensic odontologists commonly incise the skin for post-mortem dental examinations when it is difficult to open the victim's mouth. However, it is prohibited by law to incise dead bodies without permission in Japan. Therefore, we attempted using extra-oral dental radiography, using a digital X-ray equipment with rechargeable batteries, to overcome this restriction.

Materials and methods: A phantom was placed in the prone position on a table, and three plain dental radiographs were used per case: "lateral oblique radiographs" for left and right posterior teeth and a "contact radiograph" for anterior teeth were taken using a flat panel X-ray detector and a hand-held X-ray generator. The resolving power of the images was measured by a resolution test chart, and the scattered X-ray dose was measured using an ionization chamber-type survey meter.

Results: The resolving power of the flat panel X-ray detector was 3.0 lp/mm, which was less than that of intra-oral dental methods, but the three extra-oral plain dental radiographs provided the overall dental information from outside of the mouth, and this approach was less time-consuming. In addition, the higher dose of scattered X-rays was laterally distributed, but the dose per case was much less than that of intra-oral dental radiographs.

Conclusion: Extra-oral plain dental radiography can be used for disaster victim identification by dental methods even when it is difficult to open the mouth. Portable and rechargeable devices, such as a flat panel X-ray detector and a hand-held X-ray generator, are convenient to bring and use anywhere, even at a disaster scene lacking electricity and water.

INTRODUCTION

Six years have passed since the Great East Japan Earthquake, and the identity of 69 victims remain unknown. ¹Kumagai² reported the post-mortem dental records of unknown disaster victims in Iwate prefecture three years after the Great East Japan Earthquake. Of these, 64.7% did not have post-mortem dental charts available, and 79.4% had neither oral photographs nor dental radiographs. She reported that one of the reasons for few and poor dental records was that many burnt bodies were included, which were fragile and where it was difficult to open the mouth.

Forensic odontologists commonly incise the skin when it is difficult to open the victim's mouth for post-mortem dental examinations.^{3,4} However, in Japan, it is prohibited by law to incise dead bodies without a permit, and it is difficult to obtain a permit from a court at a disaster site, because the permit requires that the same procedures as for forensic autopsy should be followed. Most dentists at sites lacking electricity and water could not record oral findings, take oral photographs, or take dental radiographs of the victims using intra-oral methods without a permit.

To record some dental information without the need for a permit, forensic odontologists have developed devices, such as cameras for obtaining oral photographs⁵⁻⁷ and mouth gags. After the earthquake, we attempted to perform dental radiography by extra-oral methods to overcome this restriction. We usually take panoramic radiographs under recumbence⁸ and multi-detector computer tomography (MDCT) images⁹⁻¹² as extra-oral methods in our institution. However, these radiographs require large appliances, and it is difficult to apply them outside of specialized institutions. Therefore, we attempted to take "lateral oblique radiographs" for posterior teeth and "contact radiographs" for anterior teeth (hereafter collectively termed "plain dental radiographs") using portable devices,^{13,14} i.e. analog film and an alternating-current(AC) powered hand-held X-ray generator. We found that all teeth could be covered by only three radiographs, which could be taken by a single examiner when the body is placed in the prone position. Additionally, these radiographs yielded clear images sufficient for comparison to the ante-mortem images, and lead to positive identification.¹⁵

In this study, we evaluated the use of extra-oral plain dental radiography by means of portable and rechargeable-type devices, i.e. a flat panel X-ray detector and a hand-held X-ray generator, with a view to using these in disaster sites, and examined the scattered X-rays to determine the safety of use.

MATERIALS AND METHODS

Materials for extra-oral plain dental radiographs

The extra-oral plain dental radiographs were taken with a hand-held X-ray generator:

NOMAD™ (Aribex, Charlotte, NC, USA), and a flat panel X-ray detector (FPD): FUJIFILM DR CALNEO C mini wireless SQ 24 x 30 cm (Fujifilm Medical, Tokyo, Japan). The NOMAD™ has rechargeable batteries and backscatter radiation shielding, and the anode voltage(60 kV) and anode current(2.3mA) were fixed. CALNEO C is an indirect conversion type X-ray detector, and the images were immediately sent to a laptop with wireless.

Methods for extra-oral plain dental radiographs

The FPD and ahead phantom for dental radiographic examinations (Kyoto Kagaku, Kyoto, Japan) were placed in the prone position. We used three plain dental radiographs per case; we used "lateral oblique radiographs" for posterior teeth on both sides and a "contact radiograph" for anterior teeth.¹⁴ For "lateral oblique radiographs", the FPD was placed against the cheek to cover the premolars and molars. The central X-ray was projected from between the ramus and the cervical spines of the contralateral side toward the posterior teeth (Figure 1A). For "contact radiographs", the FPD was placed against the lips to cover the incisors, and the central X-ray was projected from the posterior neck region toward the anterior teeth (Figure 1B). For anterior teeth, the cone position of the X-ray generator was placed closely against the neck skin to enlarge the cervical spine.

Measurements of the resolving powers

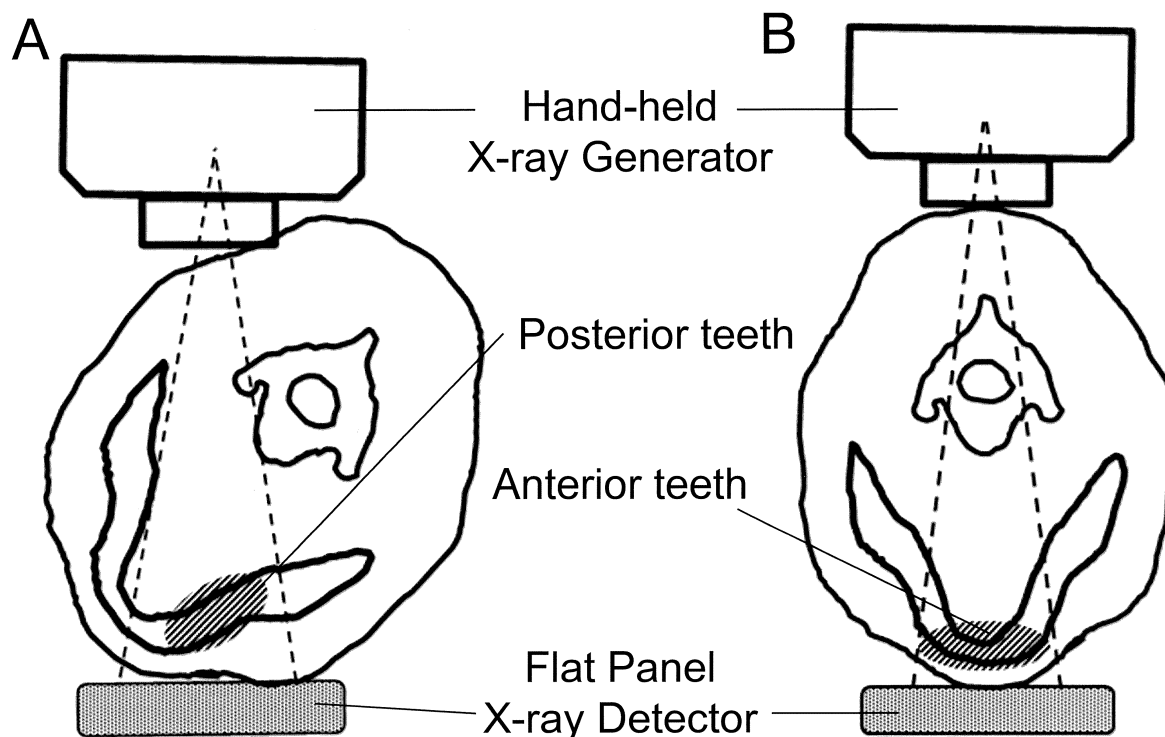
The resolving power of the images was measured using a resolution test chart type 1 (Moriyama X-ray Equipment, Tokyo, Japan), for paired use of the CALNEO C and NOMAD™. As a reference, we also measured the resolving power for paired use of a Compuray Ultimate Sensor Large (Yoshida, Tokyo, Japan), which is a Complementary Metal Oxide Semiconductor (CMOS) sensor for intra-oral radiography, and a NOMAD™.

Measurements of the dose of scatted X-rays

The FPD and the head phantom were placed in the prone position on a 70-cm high table. The X-ray generator was set in the positions for taking images of the left posterior teeth, anterior teeth, and right posterior teeth, and irradiation was performed 6 times for 0.5 second for each radiograph.

Fig.1: Extra-oral plain dental radiography.

- (A) The “lateral oblique radiograph” method for the posterior teeth.
 (B) The “contact radiograph” method for the anterior teeth.



An ionization chamber-type survey meter ICS-323C (Hitachi Aloca Medical, Tokyo, Japan) was placed on a 1 m high table, toward the cone of the X-ray generator. The scattered X-rays were measured^{16,17} at distances ranging from 0.5 m to 2.0 m, at 0.5 m intervals from the cone of the X-ray generator, and at angles ranging from 0° to 180°, at 45° intervals with respect to the phantom's body-axis line. We set 0° as the direction to the feet, 90° as the right side of the phantom, and 180° as the direction to the top of the head. A bone model with a 2.5 mm thickness lead-equivalent apron stood was placed at 0.5 m, 180°, to represent an examiner. Therefore, the 1 cm dose equivalent was measured at 19 measurement points and the examiner standing point after removing the bone model.

Calculation of the dose of scatted X-rays

The dose equivalents of scatted X-rays for one case were calculated. One case involved three dental radiographs: left posterior teeth, anterior teeth, and right posterior teeth, and the exposure

time for each radiograph was 0.10 s.

Furthermore, the average of the maximum number of cases of plain dental radiographs that could be taken in one day, while remaining within the individual dose limits,¹⁸ i.e. 20 mSv/year for occupational exposure and 1 mSv/year for public exposure, were calculated, with one year equal to 50 weeks and one week equal to five days.

RESULTS

We attempted to take plain dental radiographs of a head phantom using the FPD and the rechargeable hand-held X-ray generator by the same way as using the analog films and the AC powered hand-held X-ray generator. Teeth were comprehensively covered using only three radiographs (Figure 2). When the exposure time was over 0.06 s, the images were good quality automatically by the image processing software.

The resolving powers of the digital devices were measured. The resolving power using the CALNEO C and NOMAD™ was 3.0 line pairs/mm (lp/mm), and that by Compuray Ultimate

Fig.2: The three extra-oral plain dental radiographs of the head phantom. The three radiographs provided a broader coverage from outside of the mouth.

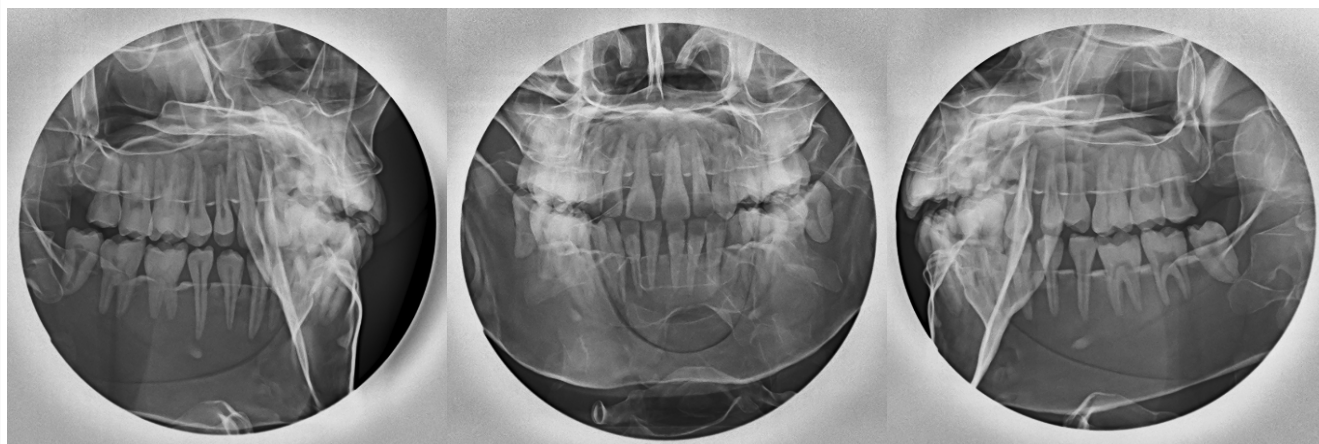
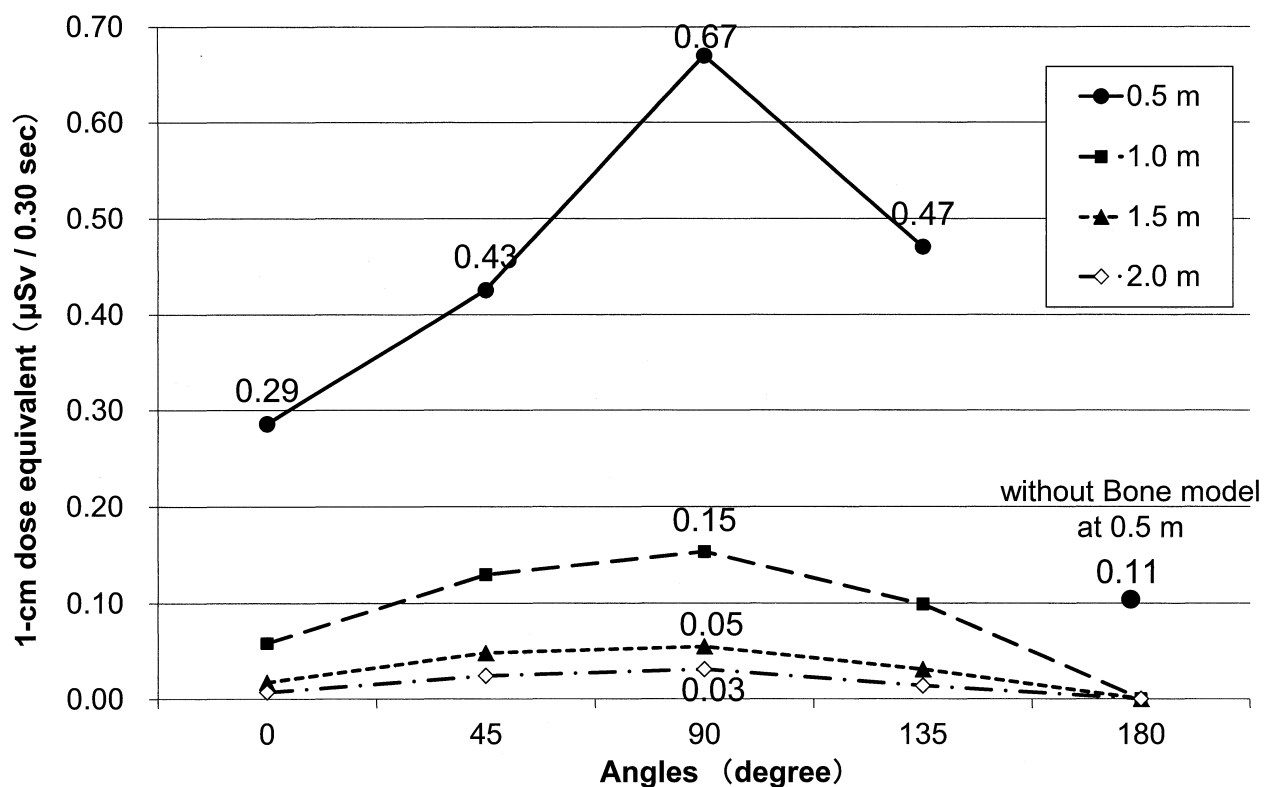


Fig.3: The 1 cm dose equivalents of scattered X-rays of one case, at various distances and angles. A higher dose was observed at 90° for each distance, and the dose decreased approximately with the square of the distance



Sensor Large and NOMAD™ was 6.0 lp/mm. The average dose of scatted X-rays for one case was measured and is shown in Figure 3. The highest dose was 0.67 µSv/case at 0.5 m, 90°. The higher dose of scattered X-rays was observed at

90° for each distance, and the dose decreased approximately with the square of the distance. The dose at the measurement points behind the bone model were less than 0.1 µSv for 3-s exposure. The dose at the examiner's standing

point was 0.11 $\mu\text{Sv}/\text{case}$.

The averages of the maximum number of cases of plain dental radiographs that could be taken in one day, while remaining within the individual dose limits, were calculated and are shown in Table 1. If examiners registered as radiation

workers, they could process up to 119 cases per day without the need for protective devices. However, in view of public exposure, they could take up to 5 cases at 0.5 m, up to 26 cases at 1.0 m, and up to 80 cases at 1.5 m.

Table 1: The average of the maximum number of cases of plain dental radiographs that could be taken in one day, while remaining within the individual dose limits.

Distances (at a 90° direction)	Dose of Scattered X-rays of 1 case	Average of maximum number of cases in one day	
		Occupational exposure < 20 mSv / year	Public exposure < 1 mSv / year
0.5 m	0.67 μSv	119 cases	5 cases
1.0 m	0.15 μSv	533 cases	26 cases
1.5 m	0.05 μSv	1,600 cases	80 cases
2.0 m	0.03 μSv	2,666 cases	133 cases

DISCUSSION

Plain dental radiographs obtained by extra-oral methods using the FPD and the rechargeable hand-held X-ray generator recorded post-mortem dental information objectively equivalent to those using analog films and the AC powered hand-held X-ray generator. As compared to radiography using films, the following points were the same. Three radiographs were sufficient to cover all teeth, and were obtained by one examiner when the dead body was in the prone position. The overall dental information, such as teeth, alveolar bone, and the structures in the maxilla and mandible, could be recorded from outside of the mouth using this approach. Radiopaque dental restorations, severe dental caries, and radiolucent or radiopaque lesions in the jaws are also likely to be observable, because those could be seen in the study using films. Moreover, radiography using the FPD has advantages, because the FPD is a digital device. We were able to assess the images obtained immediately, without the need for film development; no water is needed for such development, and the image could be retaken if the original image was not adequate. The range of

exposure time was not particularly rigorous, because we were able to use image-processing tools. No electricity is needed in mortuaries, because the equipment is rechargeable.

We measured the scattered X-rays when the plain dental radiographs were taken. Before taking measurements, we decided on the exposure time. The range of exposure time required for obtaining plain dental radiographs with the FPD is not narrower than that required for analog film. We were able to take one radiograph per 0.01 s of exposure time, but the image quality was low. In the preliminary test in practice, one radiograph with good quality could be obtained within 0.10 s for almost all cases, although the adequate exposure time depended on the condition of the dead body. We recorded the dose of the scattered X-ray per case as a 1-cm dose-equivalent for 0.10 s exposure time for each of three regions, totalling 0.30 s.

The highest dose of scattered X-rays was 0.67 $\mu\text{Sv}/\text{case}$ at the point of 0.5 m and 90°. Takahashi¹⁶ reported that the maximum dose of scattered X-rays was approximately 3 μSv , when 10 intra-oral radiographs were taken for all teeth. The dose for extra-oral plain dental radiographs

was markedly less than that for intra-oral dental radiographs, because the central X-ray was projected toward the floor. The dose of scattered X-rays decreased approximately with the square of the distance, and the dose was distributed higher at 90° and lower at 0° and 180°. This distribution was observed not only for the irradiation of the right molars, but also for the left molars, probably because the neck region was concave between the head and the body.

As the public are nervous about radiological protection after the nuclear accident at Fukushima, it is necessary to ensure the safety of radiography for various professionals working together at a disaster site. We attempted to calculate the maximum number of cases that could be processed in one day in terms of individual dose limits in the 90° direction. In the Great East Japan Earthquake, it was difficult to examine more than 30 cases per day, even if examiners only performed dental radiography. Using our approach, examiners could process up to 119 cases, even at 0.5 m, if they were registered as a radiation worker. Based on public exposure, they could process up to 26 cases at 1.0 m, and 80 cases at 1.5 m. Therefore, all individuals, other than radiation workers, should stay 1.5 m or more away from the X-ray generator, if they do not use any protection materials, such as screens and aprons. The guidelines of Japan's Ministry of Health and Welfare on the safe use of X-ray equipment for home-care service in 1998 stated that healthcare workers other than an operator and a support person, family members, and caregivers should stay 2 m or more away. Moreover, a similar guideline for first-aid stations at disaster sites in 2009 stated that healthcare workers other than an operator and a support person, should stay 2 m or more away for occupational protection, or 3 m or more away for public protection. If radiological examiners adhere to these guidelines, they can take extra-oral plain dental radiographs safely even at disaster sites.

Compared to other methods of dental radiography, the use of plain dental radiographs in this study had some advantages. As compared to the intra-oral method, we do not need to open the mouth; we could record the dental information from outside if the dead body had mouth opening difficulty because of burnt skin, dried skin, rigor mortis and fragile teeth and jaws. Even if teeth and jaws were fragile, we could place the dead body in the prone position by

using assistive devices. Additionally, three plain dental radiographs provided broader coverage than 10 intra-oral radiographs; the plain dental radiography would be less time-consuming than intra-oral radiography. Moreover, fewer radiographs and the prone position used in this method lead to a lower dose of scattered X-rays per case than the dose used in the intra-oral method, as previously mentioned. As compared to panoramic radiography, plain dental radiography could be used by adjusting the FPD position and the cone angle of the X-ray generator against the head, even if a head is bloated due to post-mortem changes, or is severely tilted upward by burnt muscles. In contrast, it is sometimes difficult to place maxillary and mandibular dental arches of a large sized head or a tilted head on the focal trough for panoramic radiography.¹⁹ As compared to MDCT, plain dental radiography is not affected by the metal artefacts that often make it difficult to observe the teeth.

Moreover, plain dental radiography has some limitations. The resolving power of the plain dental radiographs was 3.0 lp/mm, which was less than that of intra-oral radiographs; if the characteristic points were very small, a detailed comparison with ante-mortem radiographs would be difficult. In addition, lateral oblique radiography and contact radiography are classical methods, which have been used since before CT was developed; ante-mortem radiographs are commonly taken by different approaches. When comparing the radiographs taken using such different modalities, we were not able to superimpose the images, because of different distortions and magnifications. It is necessary to compare the characteristic points in both post-mortem and ante-mortem radiographs. Yet, the FPD remains an expensive device. If they became popular in first-aid centres and general hospitals, such devices would be more easily obtained in future.

CONCLUSION

Extra-oral plain dental radiography can be used for disaster victim identification by dental methods, even when it is difficult to open the mouths of dead bodies. Portable and rechargeable devices, i.e. an FPD and a hand-held X-ray generator, are convenient to bring to and use at any mortuaries, even at disaster scenes lacking electricity and water. In future, we will study

whether plain dental radiographs are sufficient to compare with ante-mortem radiographs in cases in actual practice.

REFERENCES

1. The list of unknown disaster victims of the Great East Japan Earthquake [Internet]. [updated 2017 Feb 8; cited 2017 May 19]; Available from: <http://www.tohoku.npa.go.jp/mimoto/ichiran.htm>. [Japanese]
2. Kumagai A. Factors associated with the difficulty of identifying some victims of the Great East Japan Earthquake. *Kanagawa Shigaku*. 2015; 50 suppl: 96-102. [Japanese]
3. Whittaker DK, MacDonald DG. *A Colour Atlas of Forensic Dentistry*. Ipswich, England. Wolfe Publishing; 1989. 22-5.
4. Silver WE, Souviron RR. *Dental Autopsy*. Boca Raton, Florida, USA. CRC press; 2009. 101-9.
5. Tsuzuki T, Ueno A, Kajiwara M, Hanaoka Y, Uchiyama H, Agawa Y, Takagi T, Sato Y. Evaluation of intraoral CCD camera for dental examination in forensic inspection. *Leg Med (Tokyo)*. 2002;4:40-6.
6. Yoshida M, Hanaoka Y, Tsuzuki T, Ueno A, Takagi T, Iwahara K, Yasuda M, Sato Y, Minaguchi K. Collection of intraoral findings in corpse with small-scale color dental scanner system. *Forensic Sci Int*. 2009;185:e25-9.
7. Hanaoka Y, Tsuzuki T, Yoshida M, Iwahara K, Suyama Y, Matsukubo T, Sato Y, Minaguchi K. New device for collecting intra-oral findings of unknown body. *Bull Tokyo Dent Coll*. 2011;52:149-53.
8. Yamaguchi T, Yamada Y, Yamamoto I, Ohira H, Watanabe A, Ohtani S. Usefulness of postmortem dental panoramic X-ray photographs taken using a portable radiography apparatus for dental identification. *Nihon Hoigaku Zasshi*. 2002;56:254-7. [Japanese]
9. Birngruber CG, Obert M, Ramsthaler F, Kreutz K, Verhoff MA. Comparative dental radiographic identification using flat panel CT. *Forensic Sci Int*. 2011;209:e31-4.
10. Bassed RB, Hill AJ. The use of computed tomography (CT) to estimate age in the 2009 Victorian bushfire victims: a case report. *Forensic Sci Int*. 2011;205:48-51.
11. Thali MJ, Markwalder T, Jackowski C, Sonnenschein M, Dirnhofer R. Dental CT imaging as a screening tool for dental profiling: Advantages and limitations. *J Forensic Sci*. 2006;51:113-9.
12. Kirchhoff S, Fischer F, Lindemaier G, Herzog P, Kirchhoff C, Becker C, Bark J, Reiser MF, Eisenmenger W. Is post-mortem CT of the dentition adequate for correct forensic identification? Comparison of dental computed tomography and visual dental record. *Int J Legal Med*. 2008;122:471-9.
13. Stephens RG, Reid JA. The extraoral lateral oblique radiograph: A radiation-efficient replacement for the pantomograph. *J Can Dent Assoc*. 1983;7:483-90.
14. Wood RE, Kogon SL. Dental radiology considerations in DVI incidents: A review. *Forensic Sci Int*. 2010;201:27-32.
15. Ohtani M, Oshima T, Mimasaka S. Application of extra-oral dental radiography using a hand-held X-ray generator for personal identification: case report. *Res Pract Forensic Med*. 2014;57:155-60. [Japanese]
16. Takahashi W. Study on the personal monitoring of dental workers in intra-oral radiographic examination – Investigation from the three dimensional dose distribution. *Ohu Univ Dent J*. 1991;18:26-45. [Japanese]
17. Kuroyanagi K, Hayakawa Y, Fujimori H, Sugiyama T. Distribution of scattered radiation during intraoral radiography with the patient in supine position. *Oral Surg Oral Med Oral Pathol*. 1998;85:736-41.
18. ICRP Publication 103. The 2007 recommendations of the international commission on radiological protection. *Ann ICRP*. 2007;37.
19. Ohtani M, Oshima T, Mimasaka S. Limitations of panoramic radiographs under recumbent position equipment in postmortem dental examination. *Forensic Dental Science* 2013;6:67. [Japanese]