



ORIGINAL ARTICLE

# Vedolizumab in the treatment of Crohn's disease of the pouch

Freeha Khan, Xian-Hua Gao, Amandeep Singh, Jessica R. Philpott and Bo Shen\*

Center for Inflammatory Bowel Disease, Digestive Disease and Surgery Institute, Cleveland Clinic, Cleveland, OH, USA

\*Corresponding author. The Center for Inflammatory Bowel Disease, Digestive Disease and Surgery Institute-A31, The Cleveland Clinic Foundation, 9500 Euclid Ave, Cleveland, OH 44195, USA. Tel: +1-216-444-9252; Fax: +1-216-444-6305; Email: shenb@ccf.org

## Abstract

**Background:** Our recent study showed the efficacy and safety of vedolizumab in the treatment of chronic antibiotic-refractory pouchitis. However, there are no published studies on its efficacy and safety in Crohn's disease (CD) of the pouch. The aim of this study was to assess the efficacy and safety of vedolizumab in those patients.

**Methods:** This case series included all eligible patients with CD of the pouch from our prospectively maintained, IRB-approved Pouchitis Registry from 2015 to 2017. Disease activity in pouch patients can be monitored using the modified Pouchitis Disease Activity Index (mPDAI). mPDAI is the 18-point pouchitis disease activity index consisting of three principal component scores: symptom (range, 0–6 points), endoscopy, (range 0–6 points), and histology (range, 2–6 points). Pre- and post- treatment (minimum 6 months) pouchoscopy and clinical visits were used to calculate mPDAI.

**Results:** A total of 12 patients were included in this study, who had restorative proctocolectomy with ileal pouch anal anastomosis for medically refractory ulcerative colitis (UC). The mean age at the time of pre-colectomy diagnosis of UC was  $25.0 \pm 11.5$  years. The mean current age was  $41.0 \pm 12.1$  years, nine (75.0%) were female, three (25.0%) had smoked and eight (66.7%) had used anti-tumor necrosis factor agents prior to vedolizumab use. The mean duration of vedolizumab use was  $1.0 \pm 6.4$  years. There was a significant reduction in mPDAI symptom subscores after vedolizumab therapy ( $3.50 \pm 1.93$  vs  $5.08 \pm 0.79$ ,  $P = 0.015$ ). The pre- and post-treatment mean endoscopy subscores were  $1.25 \pm 1.36$  and  $0.91 \pm 1.50$  in the afferent limb ( $P = 0.583$ );  $2.58 \pm 1.68$  and  $2.27 \pm 2.05$  ( $P = 0.701$ ) in the pouch body; and  $2.67 \pm 1.93$  and  $2.09 \pm 2.12$  ( $P = 0.511$ ) in the cuff, respectively. None of the patients experienced side effects throughout the vedolizumab therapy.

**Conclusion:** The findings of our study suggests that vedolizumab appears to be effective and safe in reducing the symptoms in patients with CD of the pouch.

**Key words:** Anti-tumor necrosis factor agent; Crohn's disease; ileal pouch; restorative proctocolectomy; vedolizumab

## Introduction

Restorative proctocolectomy with ileal pouch anal anastomosis (IPAA) is the treatment of choice for medically refractory ulcerative colitis (UC), colitis-associated dysplasia and familial adenomatous polyposis (FAP) [1]. Some patients who undergo IPAA for

UC may develop early-onset Crohn's disease (CD) of the pouch or *de novo* CD of the pouch (months to years after IPAA) [2]. A collaborative endoscopy evaluation, histology, radiographic imaging and examination under anesthesia are often required for an accurate diagnosis, disease classification, management and

Submitted: 30 January 2018; Accepted: 4 May 2018

© The Author(s) 2018. Published by Oxford University Press and Sixth Affiliated Hospital of Sun Yat-Sen University

This is an Open Access article distributed under the terms of the Creative Commons Attribution Non-Commercial License (<http://creativecommons.org/licenses/by-nc/4.0/>), which permits non-commercial re-use, distribution, and reproduction in any medium, provided the original work is properly cited. For commercial re-use, please contact [journals.permissions@oup.com](mailto:journals.permissions@oup.com)

prognosis [3]. Documented frequencies of CD of the pouch in patients who underwent IPAA for UC ranged from 2.7% to 13% [4]. Recurrent CD in the ileal pouch is a common cause for pouch failure, requiring pouch excision or permanent diversion [5–8].

Crohn's disease of the pouch has three phenotypes: inflammatory, fibrostenotic and fistulizing [4]. Each phenotype is associated with different risk factors and clinical presentations. The etiology and pathogenesis of CD of the pouch are not clear. Patients should be strongly encouraged to avoid smoking cigarettes and non-steroidal anti-inflammatory drug (NSAID) use. Medical treatment plays an important role in inflammatory and fistulizing CD of the pouch. Reported pharmaceutical agents for CD of the pouch include budesonide, infliximab and adalimumab [9,10].

Vedolizumab is a gut-specific monoclonal antibody, which acts on  $\alpha 4\beta 7$  isomer of integrin and blocks gut lymphocyte trafficking [11], which was approved by the Food and Drug Administration of US for the induction and maintenance of remission in moderate to severe CD and UC. Clinically we found that vedolizumab appeared to be safe and effective in the treatment of chronic antibiotic-refractory pouchitis. However, the efficacy and safety of vedolizumab in CD of the pouch have not been systemically evaluated. The aim of the study was to evaluate the efficacy and safety of vedolizumab in CD of the pouch by measuring the modified Pouchitis Disease Activity Index (mPDAI) symptom and endoscopy subscores pre and post treatment.

## Patients and methods

This case series study included all eligible patients with CD of the pouch from our prospectively maintained, Institutional Review Board (IRB)-approved Pouchitis Registry from June 2015 until June 2017. Demographics, comorbidities and pouch complications were extracted from a prospectively maintained pouch database. Office visit notes, follow-up notes, admission records, operation reports and other medical records were carefully reviewed.

### Inclusion and exclusion criteria

Inclusion criteria were patients with (i) an age older than 18 years, (ii) pelvic ileal pouch, (iii) diagnosis of CD of the pouch and (iv) being treated or with a history of treatment with vedolizumab. They were excluded if they had underlying FAP or CD with a diverting ileostomy.

### Clinical variables

A retrospective chart review was performed by one investigator (F.K.) to extract relevant data and demographic information, including age, gender, body mass index (BMI), smoking history, family history of inflammatory bowel disease (IBD), chronic medical issues, history of colon cancer and clinical symptoms including presence or absence of extra-intestinal manifestations. Pouch-related variables were also collected including indication of pouch surgery, duration of disease, type of pouch, history of pouchitis and past or current use of immunomodulators (azathioprine [AZA], 6-mercaptopurine [6-MP], methotrexate [MTX], anti-tumor necrosis factor [TNF] or anti-integrin agents). CD of the pouch was diagnosed by a combined assessment of endoscopic, histologic and radiographic features [12].

In addition, we recorded information regarding vedolizumab-related adverse events, exacerbation of extra-intestinal manifestations and pouch failure (defined by need for pouch revision or excision and permanent ileostomy). The diagnosis of CD of the pouch was made on the basis of a triad of compatible

symptoms and endoscopic and histologic findings. Pre- and post-treatment (minimum 6 months) pouchoscopy and clinical visits were used to calculate mPDAI symptom (range 0–6) and endoscopy (range 0–6) subscores.

### Outcome measurement

The primary outcomes were to assess the improvement or reduction in the mPDAI symptom and endoscopy subscores after 6 months of vedolizumab therapy for CD of the pouch. The mPDAI symptom index is the most commonly used diagnostic instrument. mPDAI is the 18-point pouchitis disease activity index consisting of three principal component scores: symptom (range, 0–6 points), endoscopy, (range 0–6 points), and histology (range, 2–6 points). Symptoms include stool frequency, rectal bleeding, fecal urgency/abdominal cramps, and fever. Endoscopic criteria include presence of edema, granularity, friability, loss of vascular pattern, mucus exudates and ulceration. Histology evaluation consists of polymorphic nuclear leukocyte infiltration and degree of ulceration. Pre- and post-treatment (minimum 6 months) pouchoscopy and clinical visits were used to calculate mPDAI. Endoscopy subscores are evaluated in the afferent limb, pouch body and cuff. The secondary outcome was adverse events related to the use of vedolizumab.

### Statistical analysis

Data are presented as mean  $\pm$  standard deviation, median (25th, 75th percentiles) or frequency (percentage). A Sign test was used to assess whether the difference between post- and pre-vedolizumab mPDAI scores was significantly different than 0. Univariable analysis was conducted to assess factors associated with changes in mPDAI. All analyses were performed using SAS (version 9.4, The SAS Institute, Cary, NC) and a  $P < 0.05$  was considered statistically significant.

## Results

A total of 12 patients who received vedolizumab for CD of the pouch were included in the analysis. Six (50.0%) had inflammatory phenotype of CD of the pouch and six (50.0%) had fibrostenotic phenotype of CD of the pouch. They were followed for treatment response and adverse events at 6 months post therapy.

### Demographic and clinical variables

The mean age at the time of diagnosis of UC was  $25.0 \pm 11.5$  years. The mean age of the studied population was  $41.0 \pm 12.1$  years. Out of 12 patients, 9 (75.0%) were female, 9 (75.0%) were Caucasian and 3 (25.0%) had a history of smoking. None of the patients had concurrent primary sclerosing cholangitis. None reported a family history of IBD or colon cancer. Three (25.0%) reported other extra-intestinal manifestations. A patient-selection flow diagram is shown in Figure 1.

All studied patients had undergone restorative proctocolectomy with ileal pouch anal anastomosis with restorative IPAA due to medical refractory UC. Eleven out of 12 patients (91.7%) had J pouches. One (8.3%) patient underwent one-stage pouch surgery, seven (58.3%) had two-stage pouch surgery and four (33.4%) had three-stage pouch surgery. The median duration from the pouch construction to data sensor was  $12.0 \pm 9.7$  years. The average duration of vedolizumab use was  $12.2 \pm 6.4$  months. Patients were followed for treatment response and adverse events at 6 months post therapy. A summary of demographic and clinical characteristics of patients included in the study is shown in Table 1.

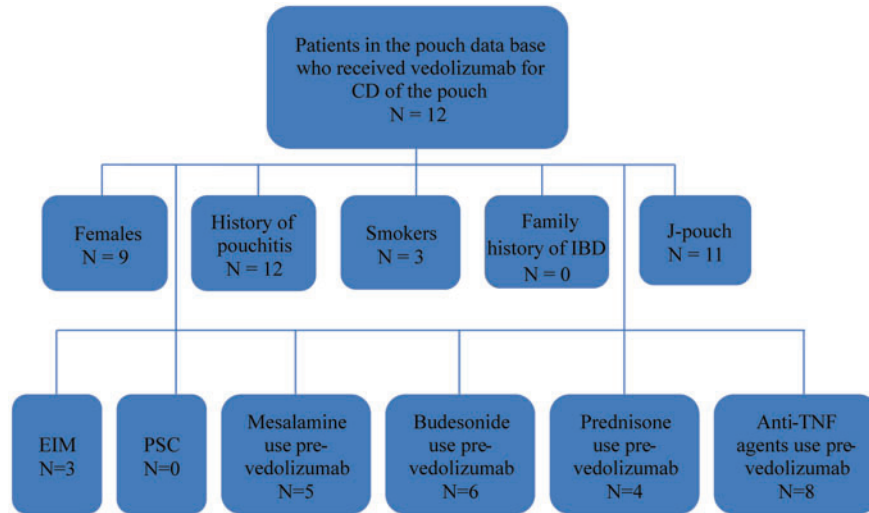


Figure 1. Flow diagram for patient selection. CD, Crohn’s disease; EIM, extra-intestinal manifestations; PSC, primary sclerosing cholangitis.

Table 1. Demographic and clinical characteristics in patients with Crohn’s disease of the pouch

Factor	Total (N=12)
Age at ulcerative diagnosis, years	25.0 ± 11.5
Mean age of patients, years	41.0 ± 12.1
Recent body mass index, kg/m <sup>2</sup>	23.7 ± 4.7
Body mass index before vedolizumab use, kg/m <sup>2</sup>	23.2 ± 4.2
Mean age of pouch duration, years	12.0 ± 9.7
Smoking, n (%)	3.0 (25.0)
Excessive alcohol use, n (%)	0
Family history of colon cancer, n (%)	0
Family history of IBD, n (%)	0
Duration of vedolizumab use, months	12.2 ± 6.4
Phenotype of disease, n (%)	
Fibrostenotic	6.0 (50.0)
Inflammatory	6.0 (50.0)
Pouch type, n (%)	
J	11.0 (91.7)
S	1.0 (8.3)
Stage of pouch surgery, n (%)	
1	1.0 (8.3)
2	7.0 (58.3)
3	4.0 (33.4)
Presence of extra-intestinal manifestations, n (%)	3.0 (25.0)
Primary sclerosing cholangitis, n (%)	0
Mesalamine use pre vedolizumab, n (%)	5.0 (41.7)
Concurrent vedolizumab and mesalamine use, n (%)	3.0 (25.0)
Oral budesonide use pre vedolizumab, n (%)	6.0 (50.0)
Concurrent vedolizumab and oral budesonide use, n (%)	4.0 (33.3)
Prednisone use pre vedolizumab, n (%)	4.0 (33.3)
Concurrent vedolizumab and prednisone use, n (%)	2.0 (16.7)
Anti-TNF agent use pre vedolizumab, n (%)	8.0 (66.7)

IBD, inflammatory bowel disease; TNF, anti-tumor necrosis factor.

### Concurrent medical therapy

Five patients (41.7%) used mesalamine, six (50.0%) took budesonide and four (33.3%) took prednisone prior to using vedolizumab. Concurrent medical therapy was also noted. Three patients (25.0%) took mesalamine, four (33.3%) used budesonide and two (16.7%) took prednisone while being

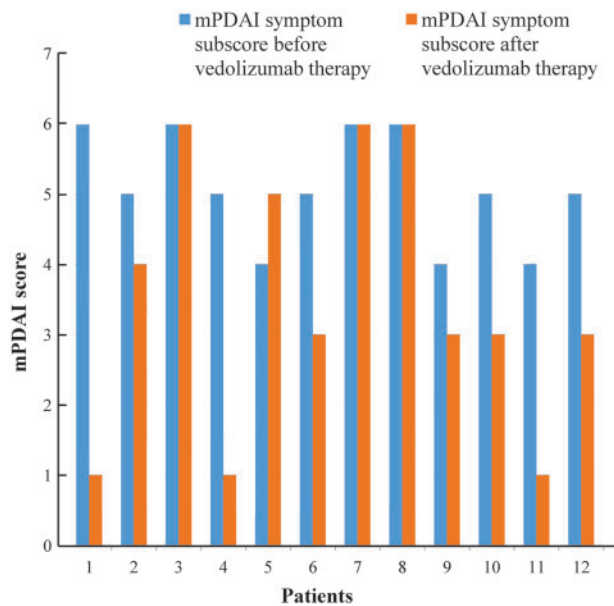


Figure 2. Modified Pouchitis Disease Activity Index (mPDAI) symptom subscores for 12 patients before and after vedolizumab therapy.

treated with vedolizumab. Eight (66.7%) had used anti-TNF agents prior to vedolizumab use.

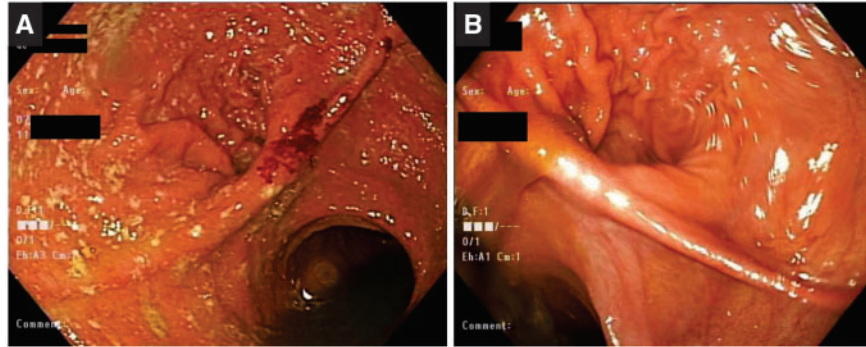
### Efficacy and safety of vedolizumab

Patients on vedolizumab therapy were noted to have statistically significantly lower mPDAI symptom subscores post treatment using univariate analysis. Numerical improvement in endoscopy subscores was also noted with vedolizumab use. Eight (66.7%) patients demonstrated significant reduction in mPDAI symptom subscores before and after vedolizumab therapy (5.08 ± 0.79 vs 3.50 ± 1.93, P=0.015). Pre- and post-vedolizumab therapy mPDAI symptom subscores for 12 patients included in this study are depicted in Figure 2.

Ten (83.3%) patients showed significant improvement in mPDAI endoscopy subscores in the afferent limb, pouch body

**Table 2.** Comparison of modified Pouchitis Disease Activity Index (mPDAI) symptom and endoscopy subscores pre and post treatment with vedolizumab

	Pre treatment	Post treatment	P-value
mPDAI symptom subscore	5.08 ± 0.79	3.50 ± 1.93	0.015
mPDAI endoscopy subscore in the afferent limb	1.25 ± 1.36	0.91 ± 1.50	0.583
mPDAI endoscopy subscore in the pouch body	2.58 ± 1.68	2.27 ± 2.05	0.701
mPDAI endoscopy subscore in the cuff	2.67 ± 1.93	2.09 ± 2.12	0.511

**Figure 3.** Pouchoscopy before (A) and after (B) vedolizumab therapy.

and cuff. The pre- and post-treatment mean endoscopy subscores were  $1.25 \pm 1.36$  and  $0.91 \pm 1.50$  in the afferent limb ( $P = 0.583$ );  $2.58 \pm 1.68$  and  $2.27 \pm 2.05$  ( $P = 0.701$ ) in the pouch body; and  $2.67 \pm 1.93$  and  $2.09 \pm 2.12$  ( $P = 0.511$ ) in the cuff, respectively (Table 2). None of the patients reported any side effects throughout the therapy. Pouchoscopy pictures before and after vedolizumab therapy are shown in Figure 3.

## Discussion

Our study showed that vedolizumab appeared to be effective in the treatment of the majority of patients with CD of the pouch by significantly reduced mPDAI symptom subscores and numerically reduced endoscopy subscores in the afferent limb, pouch body and cuff. The agent was also well tolerated. Some of those patients had failed therapy with corticosteroids or anti-TNF biologics.

IPAA is a well-established and possibly curative surgical procedure for patients with UC. Some patients are subsequently found to develop CD in the ileal pouch. CD of the pouch is being increasingly recognized in IPAA patients. The exact etiology and pathogenesis of CD of the pouch remain to be determined. However, genetic and environmental factors may contribute. The mucosal inflammation of CD of the pouch can be assessed by mPDAI symptom and endoscopy subscores in the afferent limb, pouch body and cuff [13].

There are three phenotypes of CD of the pouch: inflammatory, fibrostenotic and fistulizing [4]. Clinical manifestations of CD of the pouch vary upon phenotypes, disease location and degree of inflammation. Radiographic findings include nodules, thickened folds, ulcers, cobblestoning, sacculations, strictures, sinus tracks, fistulas or other abnormalities involving the pouch body or distal ileum [14].

Reported risk factors for CD of the pouch include the presence of family history of CD, smoking, longer duration of pouch, pre-operative diagnosis of indeterminate colitis and seropositivity for anti-*Saccharomyces cerevisiae*-IgA antibody

[15–18]. Another study showed that Ashkenazi Jewish ethnicity was associated with a higher risk for pouch complications, including CD of the pouch, suggesting a role of genetic predisposition [19].

The management of CD of the pouch has been challenging. Due to relapsing nature of the disease and various complications such as strictures, fistulas and abscesses, patients usually require aggressive medical management with various combination of antibiotics, corticosteroids, immunomodulators and anti-TNF [20]. Infliximab and adalimumab have been investigated for the treatment of CD of the pouch. A short-term follow-up study was conducted on 26 patients with an IPAA who received infliximab infusion. Findings showed that 16 out of 26 patients (62%) had a complete response, 6 (23%) had a partial response and 4 (15%) had no response [9]. Our group studied the efficacy and safety of adalimumab in treating CD of the pouch. Seven patients (41.2%) had a complete symptom response and six (35.3%) had a partial response at 4 weeks post therapy. Significant improvement was also noted with the PDAI endoscopy subscores at week 4 [10]. Despite aggressive medical therapy, approximately 10–48% of patients develop refractory CD in the ileal pouch requiring excision of the pouch with a permanent end ileostomy [5–8].

Vedolizumab has been used off-label for the treatment of chronic antibiotic-refractory pouchitis and has been shown to be beneficial with symptomatic and endoscopic improvement [21,22]. In a small case series of four patients, we showed improvement in symptoms and endoscopic appearance of pouch after 3 months of therapy with vedolizumab in patients who initially failed all other therapies including anti-TNF agents [23]. Our recent study on the efficacy and safety of vedolizumab in chronic antibiotic-refractory pouchitis demonstrated significant improvement in both endoscopic and total mPDAI scores after 3 months of therapy (submitted for publication).

To the best of our knowledge, this is the first study to illustrate the use of vedolizumab to treat CD of the pouch. This study also demonstrated that vedolizumab is safe to use in UC.

There are no published data to date on its efficacy and safety in CD of the pouch. Vedolizumab treatment in CD of the pouch has not been previously investigated, largely due to a relatively small number of patients scattered in private and academic practices. Taking advantage of established Pouchitis Clinic, we were able to evaluate 12 patients and performed statistical analyses. The efficacy of vedolizumab was supported by mPDAI symptom subscore as well as endoscopy subscores.

Our study is unique, as it is the first in the literature to provide information on vedolizumab therapy in UC patients who have undergone IPAA and developed CD of the pouch. Vedolizumab therapy may be recommended as the next treatment option in patients with CD of the pouch who showed no improvement with steroids and other biological therapies such as anti-TNFs. Its use will be advantageous in the long term by reducing the risk for pouch failure.

There are limitations to our study. First, there is the possibility of referral bias, as all patients in the study were seen in the setting of a subspecialty Pouchitis Clinic in which patients with a spectrum of pouch disorders were diagnosed and managed. Second, we included patients who used vedolizumab from June 2015 until June 2017. The sample size was small and the study was not controlled, as CD of the pouch is not common in the general population and vedolizumab has not become its standard treatment to date. The findings of the current study will help to set the stage for future randomized-controlled trials.

In conclusion, our study demonstrated that vedolizumab appears to be effective in the treatment of CD of the pouch by significantly reducing mPDAI symptom subscores and numerically reducing endoscopy subscores in the afferent limb, pouch body and cuff. The agent appears to be well tolerated.

*Conflict of interest statement:* none declared.

## Acknowledgements

F.K.—data gathering and entry; F.K., A.S. and X.-H.G.—manuscript preparation; J.P. and B.S.—concept, general supervision and manuscript revisions.

## Funding

Dr. Bo Shen has received research grant from Takeda Pharmaceutical Company.

## References

- Fazio VW, Ziv Y, Church JM et al. Ileal pouch-anal anastomosis: complications and function in 1005 patients. *Ann Surg* 1995;**222**:120–7.
- Wu H, Shen B. Crohn's disease of the pouch: diagnosis and management. *Expert Rev Gastroenterol Hepatol* 2009;**3**:155–65.
- Gu J, Remzi FH, Lian L et al. Practice pattern of ileal pouch surveillance in academic medical centers in the United States. *Gastroenterol Rep* 2016;**4**:119–24.
- Shen B, Remzi FH, Lavery IC et al. A proposed classification of ileal pouch disorders and associated complications after restorative proctocolectomy. *Clin Gastroenterol Hepatol* 2008;**6**:145–58.
- Deutsch AA, McLeod RS, Cullen J et al. Results of the pelvic-pouch procedure in patients with Crohn's disease. *Dis Colon Rectum* 1991;**34**:475–7.
- Grobler SP, Hosie KB, Affie E et al. Outcome of restorative proctocolectomy when the diagnosis is suggestive of Crohn's disease. *Gut* 1993;**34**:1384–8.
- Keighley MR. The final diagnosis in pouch patients for presumed ulcerative colitis may change to Crohn's disease: patients should be warned of the consequences. *Acta Chir Iugosl* 2000;**47**:27–31.
- Mylonakis E, Allan RN, Keighley MR. How does pouch construction for a final diagnosis of Crohn's disease compare with ileoproctostomy for established Crohn's proctocolitis? *Dis Colon Rectum* 2001;**44**:1137–43.
- Colombel JF, Ricart E, Loftus EV et al. Management of Crohn's disease of the ileoanal pouch with infliximab. *Am J Gastroenterol* 2003;**98**:2239–44.
- Shen B, Remzi FH, Lavery IC et al. Administration of adalimumab in the treatment of Crohn's disease of the ileal pouch. *Aliment Pharmacol Ther* 2009;**29**:519–26.
- Feagan BG, Rutgeerts P, Sands BE et al. Vedolizumab as induction and maintenance therapy for ulcerative colitis. *N Engl J Med* 2013;**369**:699–710.
- Du P, Sun C, Ashburn J et al. Risk factors for Crohn's disease of the neo-small intestine in ulcerative colitis patients with total proctocolectomy and primary or secondary ileostomies. *J Crohns Colitis* 2015;**9**:170–6.
- Shen B, Achkar JP, Connor JT et al. Modified pouchitis disease activity index: a simplified approach to the diagnosis of pouchitis. *Dis Colon Rectum* 2003;**46**:748–53.
- Wagner-Bartak NA, Levine MS, Rubesin SE et al. Crohn's disease in the ileal pouch after total colectomy for ulcerative colitis: findings on pouch enemas in six patients. *Am J Roentgenol* 2005;**184**:1843–7.
- Melmed GY, Fleshner PR, Bardakcioglu O et al. Family history and serology predict Crohn's disease after ileal pouch-anal anastomosis for ulcerative colitis. *Dis Colon Rectum* 2008;**51**:100–8.
- Shen B, Remzi FH, Hammel JP et al. Family history of Crohn's disease is associated with an increased risk for Crohn's disease of the pouch. *Inflamm Bowel Dis* 2009;**15**:163–70.
- Shen B, Fazio VW, Remzi FH et al. Risk factors for diseases of ileal pouch-anal anastomosis after restorative proctocolectomy for ulcerative colitis. *Clin Gastroenterol Hepatol* 2006;**4**:81–9.
- Delaney CP, Remzi FH, Gramlich T et al. Equivalent function, quality of life and pouch survival rates after ileal pouch-anal anastomosis for indeterminate and ulcerative colitis. *Ann Surg* 2002;**236**:43–8.
- Tyler AD, Milgrom R, Xu W et al. Antimicrobial antibodies are associated with a Crohn's disease-like phenotype after ileal pouch-anal anastomosis. *Clin Gastroenterol Hepatol* 2012;**10**:507–12.
- Achkar JP, Shen B. Medical management of postoperative complications of inflammatory bowel disease: pouchitis and Crohn's disease recurrence. *Curr Gastroenterol Rep* 2001;**3**:484–90.
- Fazio VW, Kiran RP, Remzi FH et al. Ileal pouch anal anastomosis: analysis of outcome and quality of life in 3707 patients. *Ann Surg* 2013;**257**:679–85.
- Shen B, Lashner BA. Can we immunogenotypically and immunophenotypically profile patients who are at risk for pouchitis? *Am J Gastroenterol* 2004;**99**:442–4.
- Shen B, Achkar JP, Lashner BA et al. Endoscopic and histologic evaluation together with symptom assessment are required to diagnose pouchitis. *Gastroenterology* 2001;**121**:261–7.