

Orthodontic Management of Dentofacial Discrepancies in Skeletal Class II Patients

Abstract

The skeletal Class II occurs when there is a marked discrepancy in the position and relationship between the maxilla and the jaw, resulting in patients with labial incompetence, convex profile and an Angle Class II malocclusion, to the consultation there is a female patient of 12 years of age presenting these characteristics, in addition to a marked proclination of incisors, and clicking when opening the mouth. The objective of this case report was to improve the profile of the patient, get Class I molar and canine, correct the incompetence labial, and improve dental occlusion. The treatment plan included dental extraction of the upper and lower first premolars, accompanied by retraction of canines and upper anteroposterior segment. Thanks to the application of the ROTH technique through the use of elastic chains and retraction arches, the initial objective was achieved, improving the esthetics and function of the facial structures.

Keywords: Dental extraction, dental occlusion, malocclusion, maxilla

Introduction

The malocclusions are of multifactorial origin, in most cases, there is no single etiological cause; however, there are many interacting with each other, and overlapping one another. However, two main components can be defined in their etiology, which are genetic predisposition, and exogenous or environmental factors, which includes all the elements capable of conditioning a malocclusion during craniofacial development. It is important that the clinician studies these multifactorial phenomena, to neutralize them, thus achieving the success of the treatment and avoiding subsequent recurrences.^[1]

Distocclusion, Class II according to angle, is that malocclusion in which there is a distal relationship of the lower jaw with respect to the upper one. Class II or distocclusion may result in a retrógnata jaw, a prognathic maxilla, or a combination of both.^[2]

Class II Division 1 is characterized by increased prominence and proclination of the upper incisors, in which the bite is likely to be deep, the retrognathic profile and excessive protrusion, require that the facial muscles and tongue adapt to abnormal

patterns of contraction.^[3] In Class II Division 2, the prominence is reduced and the crown of the upper incisors inclined toward the lingual. It is characterized by abnormal depth of bite, labioversion of the upper lateral incisors and more normal labial function; the facial skeleton is not as retrognathic as in Class II Division 1.^[4]

In recent decades, studies have shown that there is soft-tissue growth at certain ages, regardless of bone growth, especially in the area of nose, lip, and chin. In this way, orthodontic facial analysis in these areas should be emphasized.^[5]

The most challenging task for orthodontists and general clinicians is to develop clinical procedures to work in the field of dental modifications caused by the growth and development of the face and dentitions, identifying factors that cause occlusal anomalies that can adversely affect the normal growth and development of teeth and occlusion. These factors can be prevented, their effects can be minimized, or conditions can be treated early before their full manifestation.^[6]

This clinical case is justified since it is sought through a correct diagnosis and treatment plan to improve the esthetics and function of the patient. The objective of the treatment is to improve the patient's profile,

**William
Ubilla-Mazzini,
Fátima
Mazzini-Torres,
Tanya
Moreira-Campuzano**

*Department of Investigation,
Faculty of Dentistry, University
of Guayaquil, Guayaquil,
Ecuador*

Address for correspondence:
*Dr. William Ubilla-Mazzini,
Department of Investigation,
Faculty of Dentistry, University
of Guayaquil, Guayaquil,
Ecuador.
E-mail: william.ubillam@
ug.edu.ec*

Access this article online

Website:

www.contempclindent.org

DOI: 10.4103/ccd.ccd_68_18

Quick Response Code:



How to cite this article: Ubilla-Mazzini W, Mazzini-Torres F, Moreira-Campuzano T. Orthodontic management of dentofacial discrepancies in skeletal Class II patients. *Contemp Clin Dent* 2018;9:474-7.

This is an open access journal, and articles are distributed under the terms of the Creative Commons Attribution-NonCommercial-ShareAlike 4.0 License, which allows others to remix, tweak, and build upon the work non-commercially, as long as appropriate credit is given and the new creations are licensed under the identical terms.

For reprints contact: reprints@medknow.com

get Class I molar and canine, correct the incompetence labial and improve the occlusion.

Case Report

A 12-year-old female patient comes to the clinic stating that she is not under medical treatment, absence of systemic diseases, no allergy to medications, and no family medical history. She has neither had complications with anesthesia in the mouth nor is she prone to hemorrhages. In addition, the structures of the stomatognathic system are without alterations that affect their correct function. In the oral extra photos, it presents a facial dolicho biotype, with a soft convex profile and lip incompetence. In addition, the patient manifests noises (clicks) at the time of opening the jaw. In the intraoral photographs, the lower middle line was deviated to the right, 3 mm, marked dental inclinations, moderate dental crowding in both arches, an overjet of 12 mm, and an overbite of 3 mm. Class I molar on both sides and Class I canine on the left side, while on the right side does not apply since part 13 is in the process of eruption [Figure 1].

The panoramic radiograph that piece 43 was retained. Third molars in process of formation and eruption with apparent bad position. In Ricketts' cephalometric analysis, the patient presented skeletal Class II due to the maxillary protrusion, the divergent rotational behavior of the basal ones, mesofacial biotype with tendency to dólico and alveolar dentition biproclination. This gave us a conclusion of a Class II malocclusion [Figure 2].

The treatment plan initially contemplated aligning and leveling for 3 months to correct the problem of the mandibular opening (clicks) and waiting for the lower jaw to advance and correct the existing discrepancy (Class II). When this goal was not reached, the extractions of the pieces 14–24–34–44, upper and lower first premolars, use of maximum anchorage, transpalanance, to preserve all the spaces, align and level, distalization of upper canines and lower to reach Class I dog, retraction of the upper and lower anterior segment, parallel roots and contentions. We

worked with the ROTH technique with 022 slot brackets. Upper and lower 0.012 nickel-titanium arches were placed on January 30, 2013. Once the alignment and leveling were done for 3 months, on April 17, 2013, once performed the extractions, proceeded to cement the transpalanance, placed upper and lower 0.018 steel arches to initiate the distalization of the upper and lower canines with the use of elastic chains [Figure 3].

By September 11, 2013, distalization of the upper and lower canines had been achieved, proceeding to place a 0.016 × 0.016 superior steel retraction arch and placement of metallic ligature in the posterior and anterior sector to close spaces between canines and laterals, correcting the existing maxillary discrepancy. In the lower arch, only single elastic modules and a 0.016 niti arch were used to continue the tooth alignment and leveling, performing the same as the upper arch in the following appointment. For December 15, 2014, we proceeded to place niti arch 0.017 × 0.022 in both arches, metal ligature from piece 6 to piece 6 in the upper arch and elastic chain in lower arch for closing the minimum spaces existing. In addition, the use of 1/8 medium leagues in the posterior sector was indicated to obtain a correct intercuspation.

The orthodontic treatment was completed on April 09, 2014. The final photos are presented below. Panoramic and cephalometric radiographs were taken before the removal of the orthodontic appliances, in which a correct verticalization of roots is shown, in addition to third molars retained in the process of formation. The cephalometric analysis shows the considerable reduction of the angulations of the inclinations of the incisors. The patient remains Class II skeletal [Figure 4].

It can be noted that the facial biotype (Dólico) has not changed with the orthodontic treatment; however, the correction of the labial incompetence was achieved thanks to the extraction of upper and lower first premolars, to the correct distalization of the canines and the retraction of the

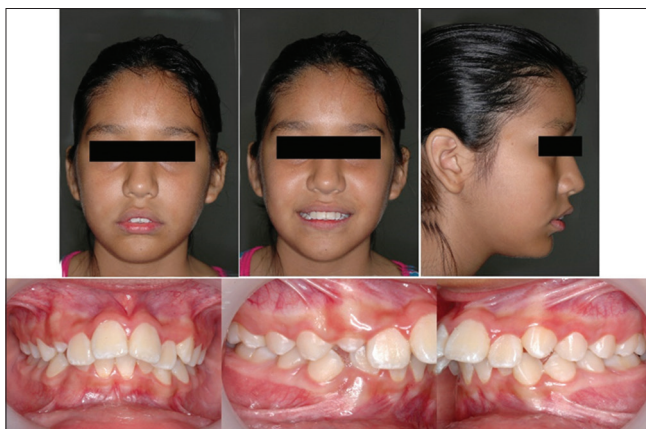

Figure 1: Before treatment

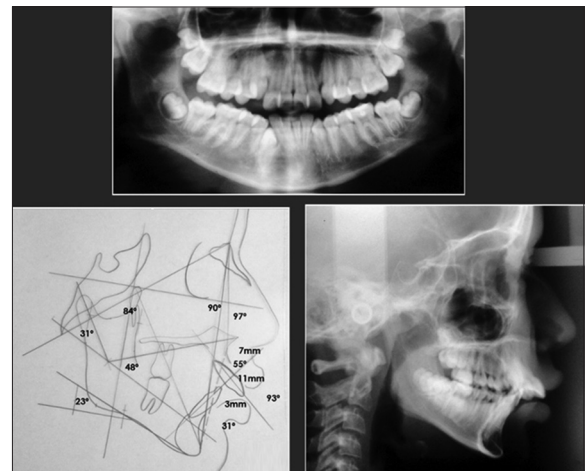


Figure 2: Before treatment

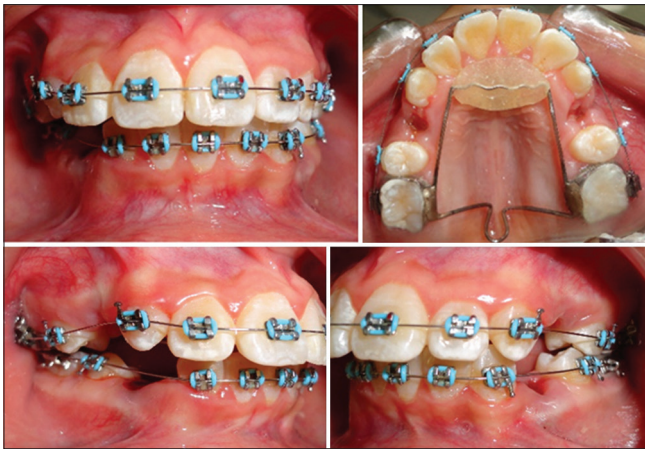

Figure 3: During treatment

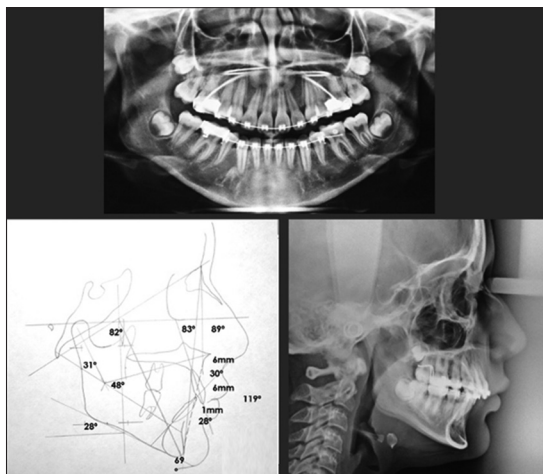


Figure 4: After treatment

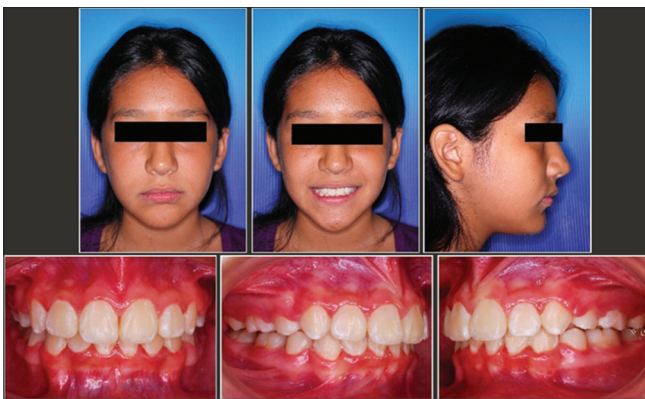

Figure 5: After treatment

segment. Superior antero with the use of the retraction arch in 16 × 16 steel with the ROTH technique. In the intraoral view, it can be observed that a coinciding midline was achieved, in addition to closing all spaces resulting from the extractions of the upper and lower first premolars. The molar class continues to be I on both sides. Canine Class I right and left and a correct intercuspitation was achieved [Figure 5].

Discussion

In a study conducted in the United States in 2004, the occlusion of 507 Latino adolescents between the ages of 12 and 18 years is analyzed. There more than 93% of the individuals demonstrated some type of malocclusion. The distribution of malocclusion patterns is presented and contrasts with the data published for other ethnic groups. Information on the prevalence and types of malocclusion in the Latino population should be of interest to dentists and general specialists. This is confirmed by the patient treated in the present case, whose origin is Latin, more precisely from Ecuador.^[7]

There is a subjective opinion that varies according to each person with respect to changes in the profile of soft tissues, where race, fashion, and social groups greatly influence.^[8] The important thing in any orthodontic treatment is to meet the expectations of the patient, thus achieving function and aesthetics.

Kesling *et al.* mention that the decision to perform extractions depends on the position of the lower incisor with the A-Po line or the patient's refusal to undergo surgery.^[9] Oynick finds better perception of the results in biprotrusos patients when the cases were treated with extractions.^[10] In the present case, there was no denial on the part of the patient as well as of the parents to perform extractions, which facilitated the completion of the treatment in a correct manner.

The alternative treatment with extractions positively influenced the profile and esthetics of the affected, Proffit says that treatments can be performed with or without extractions when the esthetics are affected, due to the great influence of the inheritance on the etiology of the malocclusions.^[11] Thus, with the use of the ROTH technique in this case, it was possible to achieve a correct closure of spaces and correction of lip incompetence, all thanks to the precise application of the technique and the patient's collaboration. The professional should review through a thorough analysis, the proportions, and normal adaptations of the soft tissue since the stability at the end of the orthodontic treatment will be influenced by the soft-tissue pressure and its effects of balance.

The careful study of the case as well as the correct structuring of the treatment plan was the keys to correct the maxillary discrepancies, thanks to the extraction of the upper and lower first premolars, to the correct application of the Roth treatment mechanics, that included the placement of a space maintainer along with a good distalization of canines and retraction of the anterior segment, and the patient's collaboration taking care of their orthodontic appliances and of course their parents fulfilling each scheduled appointment to finish the treatment in a little more than 13 months.

Declaration of patient consent

The authors certify that they have obtained all appropriate patient consent forms. In the form, the patient has given

her consent for her images and other clinical information to be reported in the journal. The patient understands that names and initials will not be published and due efforts will be made to conceal identity, but anonymity cannot be guaranteed.

Financial support and sponsorship

Nil.

Conflicts of interest

There are no conflicts of interest.

References

1. Canut JA. Clinical and Therapeutic Orthodontics. Madrid: Ed Masson; 2001.
2. Di Santi J, Vasquez V. Malocclusion class I: Definition, classification, clinical characteristics and treatment. *Latin Am J Orthod Pediatr Dent* 2003;3.1. Available from: <https://www.ortodoncia.ws/publicaciones/2003/art-8/>. [Last accessed on 2017 Nov].
3. Rodriguez E, Casasa R. Contemporary Orthodontics Diagnosis and Treatment. Amolca: Buenos Aires; 2005.
4. Ortiz M, Lugo V. Malocclusion class II division 1; etiopathogenesis, clinical characteristics and alternative treatment with a sustained reverse configurator II (crs II). *Latin Am Rev Orthod Pediatr Dent* 2007;7.1
5. Companioni Bachá A, Rodríguez Quiñónez M, de Villegas Rushkova D, Otaño Lugo R. Historical sketch of radiographic cephalometry. *Cuban J Stomatol* 2008;45:2.
6. Millán M, Katagiri M, Elorza H. Classification of class I, class II and class III malocclusions according to angle in the department of orthodontics of the UNAM. *Mex Odontol J* 2007;11:175-80.
7. Silva RG, Kang DS. Prevalence of malocclusion among Latino adolescents. *Am J Orthod Dentofacial Orthop* 2001;119:313-5.
8. Bravo LA. Soft tissue facial profile changes after orthodontic treatment with four premolars extracted. *Angle Orthod* 1994;64:31-42.
9. Kesling PC, Rocke RT, Kesling CK. Treatment with tip-edge brackets and differential tooth movement. *Am J Orthod Dentofacial Orthop* 1991;99:387-401.
10. Oynick CA. The Impact of Orthodontic Treatment on Perceived Facial Esthetics St. Louis: Saint Louis University; 1988.
11. Proffit WR. Orthodontics. Theory and Practice. 2nd ed. Madrid-Spain: Editorial Mosby; 1994.