



Haematopoietic Stem Cell Transplantation Arrests the Progression of Neurodegenerative Disease in Late-Onset Tay-Sachs Disease

Karolina M. Stepien · Su Han Lum ·
J. Edmond Wraith · Christian J. Hendriksz ·
Heather J. Church · David Priestman ·
Frances M. Platt · Simon Jones · Ana Jovanovic ·
Robert Wynn

Received: 15 August 2017 / Revised: 07 November 2017 / Accepted: 14 November 2017 / Published online: 07 December 2017
© Society for the Study of Inborn Errors of Metabolism (SSIEM) 2017

Abstract Tay-Sachs disease is a rare metabolic disease caused by a deficiency of hexosaminidase A that leads to accumulation of GM2 gangliosides predominantly in neural tissue. Late-onset Tay-Sachs disease variant is associated with a higher level of residual HexA activity. Treatment options are limited, and there are a few described cases who have undergone haematopoietic stem cell transplantation (HSCT) with variable outcome.

We describe a case of a 23-year-old male patient who presented with a long-standing tremor since 7 years of age. He had gait ataxia, a speech stammer and swallowing problems. His condition had had a static course apart from his tremor that had been gradually deteriorating. Because of the deterioration in his neurological function, the patient had an uneventful, matched-sibling donor bone marrow transplant at the age of 15 years. Eight years post-HSCT, at

the age of 23, he retains full donor engraftment, and his white cell beta-HexA of 191 nmol/mg/h is comparable to normal controls (in-assay control = 187). He continues to experience some intentional tremor that is tolerable for daily life and nonprogressive since HSCT.

Conclusion: HSCT is a potential treatment option which might arrest neurodegeneration in patients with LOTS.

Abbreviations

GA2	GalNAc beta1-4 Gal beta 1-4 Glc-ceramide
GM2	GalNAc beta 1-4 [NeuAc alpha 2-3] Gal beta 1-4 Glc-ceramide
Hexa A/B	Hexosaminidase A/B
HSC	Haematopoietic stem cell
HSCT	Haematopoietic stem cell transplantation
Lc3	GlcNAc beta1-3 Gal beta 1-4 Glc-ceramide
LOTS	Late-onset Tay-Sachs
LSD	Lysosomal storage disease
TSD	Tay-Sachs disease

Communicated by: Gregory M. Pastores, MD

K.M. Stepien (✉) · C.J. Hendriksz · A. Jovanovic
The Mark Holland Metabolic Unit, Adult Inherited Metabolic Disorders, Salford Royal NHS Foundation Trust, Salford, UK
e-mail: kstepien@doctors.org.uk

S.H. Lum · R. Wynn
Department of Paediatric Blood and Marrow Transplant,
Royal Manchester Children's Hospital, Manchester, UK

J.E. Wraith · H.J. Church · S. Jones
Willink Biochemical Genetics Department, St. Mary's Hospital,
Manchester, UK

D. Priestman · F.M. Platt
Department of Pharmacology, University of Oxford, Oxford, UK

C.J. Hendriksz
Steve Biko Academic Unit, Paediatrics and Child Health,
University of Pretoria, Pretoria, South Africa

Introduction

Tay-Sachs disease (TSD) (OMIM 272800) is a rare metabolic disease caused by a deficiency of hexosaminidase A (EC 3.2.1.52) that leads to accumulation of GM2 ganglioside predominantly in neural tissues and a diffuse apoptotic cell death phenomenon in the central nervous system (Mahuran 1995). Beta-hexosaminidase A (HexA), a

heterodimer of alpha-beta subunits, and beta-hexosaminidase B (HexB), a homodimer of beta subunits, represent the two major forms (Mahuran 1995). The alpha- and beta-subunits are encoded by two different genes, *HEXA* and *HEXB*, which are located on chromosomes 15 and 5, respectively. TSD is due to mutations affecting the alpha-subunit (Myerowitz 1997), whereas Sandhoff disease is caused by mutations in the beta-subunit.

The early-onset severe disease form is often associated with a very low hexosaminidase A activity (<0.5%). A late-onset Tay-Sachs (LOTS) disease variant has been described in compound heterozygotes or mild homozygotes and is linked to higher residual HexA activity (5–20% of normal activity) (Sandhoff and Christomanou 1979). Onset of symptoms depends on the residual enzyme activity, and patients with LOTS disease may present in childhood, adolescence, or early adulthood. Patients with juvenile form of illness typically develop signs and symptoms in early childhood (ages 1–9 years) and often die by their mid-teens. Others follow a benign course of the disorder and can live into adulthood (Rosebush et al. 1995). In these cases, the condition is generally designated adult GM2 gangliosidosis (Suzuki 1991; Gravel et al. 1995) or LOTS. It results in a more gradual course of neurodegeneration as evidenced by its delayed onset and a more gradual decline in motor, cerebral and spinocerebellar functions. Initial features may include weakness due to motor neuron disease, neuropathy, dysarthria, spasticity, dystonia, tremor, ataxia or psychosis (Rowland 2010; Rosebush et al. 1995; Shapiro et al. 2008). Several documented cases of TSD presented with childhood stutter (Shapiro and Natowicz 2009), axonal polyneuropathy affecting distal segments in the arms and legs and progressive spastic tetraparesis resembling primary lateral sclerosis (Godeiro-Junior et al. 2009). Additionally, LOTS is typically associated with psychiatric manifestations such as depression, bipolar disorder and psychosis (Neudorfer et al. 2005).

Treatment options for TSD have variable functional outcomes and survival rate. Preclinical studies described so far include substrate reduction therapy (Andersson et al. 2004), bone marrow (Jeyakumar et al. 2001) and neural stem cell transplantation (Lee et al. 2007; Lacorazza et al. 1996), anti-inflammatory drugs (Jeyakumar et al. 2004), intraventricular delivery of purified protein (Matsuoka et al. 2011) and adenoviral (Guidotti et al. 1998; Cachon-Gonzalez et al. 2006) and lentiviral vector-mediated gene therapy (Kyrkanides et al. 2007) causing expression of the functional enzyme. The response of LOTS disease to pharmacological chaperones (hexosaminidase A inhibitors) has been tested in experimental studies (Tropak et al. 2004; Rountree et al. 2009) and clinical trials (Clarke et al. 2011; Osher et al. 2015) to evaluate their effectiveness in reversion of the progressive nature of the disease.

We describe a case of TSD diagnosed aged 15 who presented with tremor and underwent haematopoietic stem cell transplantation (HSCT) that arrested the progression of his neurological disease.

Case

A 23-year-old male patient presented with a long-standing tremor since the age of 7 years. It continued to deteriorate, and by the age of 14, his tremor had increased in severity and was interrupting his day-to-day activities. It presented more noticeably with his hand shaking and was worse when he got up in the morning. At times his whole body shook. His tremor seemed to be worse in the morning and improved during the day. It was worse when he was tired or stressed.

Physical examination revealed low amplitude, low frequency tremor, but no frank cerebellar signs and normal eye movements. He had slightly increased tone in his legs, brisk reflexes and ankle clonus. He had a tremor at rest and on intention involving, at different times, his arms, his legs and his eyelids. There was unsteadiness on walking but no peripheral neuropathy or any corticospinal tract signs.

His development was normal and he was performing well at school. There appeared to have been deterioration in speech with stammering, difficulty finding words and pressure of speech. His difficulty with swallowing was in keeping with bulbar palsy. His writing was faint. His brain MRI was reported as unremarkable.

He was the fourth child of distantly related parents. There was no family history of tremor. He remained under the care of a paediatric neurologist who investigated him for various causes of tremor for many years. At the age of 15, he was diagnosed with a deficiency of beta-hexA (enzyme level, 5 nmol/mg/h) that was consistent with a diagnosis of juvenile (late-onset) TSD (compound heterozygous for two pathogenic mutations: c.872A>G p.(Asn291Ser), c.1496G>A p.(Arg499His)). While the c.872A>G p.(Asn291Ser) is a novel variant, the Arg499His mutation affecting alpha chain processing has been previously associated with a subacute clinical phenotype in patients (Codeiro et al. 2000). Despite the nonclassical course, his condition was gradually deteriorating. Initially his tremor was managed with propranolol, but eventually it made no difference and was discontinued. Treatment with primidone was commenced but stopped due to side effects.

In view of the deterioration of his neurological function, human leucocyte antigen (HLA)-matched sibling marrow transplant was done at 15 years old. He was conditioned with busulfan (with dose adjusted to target under the curve at 80 mg/L/h), cyclophosphamide (200 mg/kg) and alemtuzumab (0.3 mg/kg), and he received ciclosporin alone as

post-transplant graft-versus-host disease prophylaxis. The total nucleated cell dose and CD34 cell dose were $1.8 \times 10^8/\text{kg}$ and $3.9 \times 10^6/\text{kg}$, respectively. Neutrophil engraftment was demonstrated on Day + 12, and donor chimerism was 100%. Early transplant course was complicated by mucositis and asymptomatic cytomegalovirus reactivation, which was treated with ganciclovir. He was fully immune reconstituted and off all immunosuppressant and other therapies by 12 months post-transplant.

The most prominent clinical improvement post-HSCT was stabilisation of his neurological regression. His swallowing dysfunction has improved and his severity of tremor has remained static. Clinical assessment at 12 months post-HSCT indicated persistent upper motor neuron signs at both lower limbs but no new neurological signs. MRI brain at 12 months, 4 years and 8 years post-HSCT showed no progression compared to his pre-transplant scans. This further supports that HSCT has stabilised his disease. At the age of 23, he still experiences some mild intentional tremor predominantly in his upper limbs and occasionally in his whole body, which has not changed since his HSCT.

Eight years post-HSCT, he retained full donor chimerism, demonstrated using informative short tandem repeats (STR) to distinguish transplant donor from recipient. His white cell beta-HexA was 191 nmol/mg/h (in-assay control = 187) and was comparable to the normal controls. His plasma beta-HexA was 14.1 nmol/mg/h and was present at reduced level (NR = 50–250; control = 120) (Table 1). This reflects the significant contribution of plasma HexA from the liver in normal individuals.

Figure 1 shows concentrations of the three substrates for beta-hexosaminidase present in the circulation (GA2, Lc3 and GM2) in five control plasma samples and the patient

untreated and post-HSCT. These measurements were made using a robust and sensitive HPLC method (Neville et al. 2004). Post-HSCT, GA2, Lc3 and GM2 were reduced by 69, 33 and 29%, respectively, while all the other circulating GSLs remained exactly the same as they were prior to transplantation (data not shown). It is clear that GA2 has returned to normal levels. These data show that HSCT has effectively normalised the circulating concentrations of these three beta-hexosaminidase substrates and highlights their potential utility as biomarkers.

Discussion

TSD is a fatal neurodegenerative disease with an estimated incidence of 1 in 222,000 live births in general population and 1 in 3,900 live births among Ashkenazi Jews. Accumulation of GM2 ganglioside results in cellular death. Neuronal death occurs due to altered calcium homeostasis and activated microglia-mediated inflammatory process. The natural history without treatment would be one of slow deterioration over a number of years. This would have culminated in a vegetative existence eventually. The initial diagnosis in this patient was challenging as his neurologic symptoms observed were not pathognomonic and could have been caused by a wide array of other conditions including toxic or infectious agents. His mild tremor was undoubtedly subtle for many years, and only in combination with speech and swallowing difficulties, it raised some concerns that led to further, including metabolic, investigations.

The rationale for using HSCT in patients with lysosomal storage disease (LSD) was based on the concept that exogenous enzyme is able to enter lysosomes of abnormal

Table 1 Hexosaminidase A (HexA) activity both pre- and post-HSCT

	Diagnosis (age 14 years)	HSCT + 6 years	HSCT + 8 years	Reference range	Comments
Hexosaminidase A Plasma nmol/mg/h	5	14	15	50–250	Post-HSCT – Reduced to ~30% of lower limit of normal
Hexosaminidase A Leucocytes nmol/mg/h	Not measured	191	187	N/A normal controls 187 + 362	Post-HSCT – Activity comparable to normal controls
Graft status (QF-PCR)	N/A	100% donor?	100% donor	N/A	Full engraftment
Plasma GA2, Lc3, GM2 Plasma GA2	145, 24, 253	N/A	45, 16, 180	22–59, 6–12, 35–90	Decreased by 69, 33 and 29%, respectively Returned to normal levels

The deficiency of HexA measured in plasma pre-HSCT is consistent with a biochemical diagnosis of Tay-Sachs disease (TSD). HexA activity in leucocytes post-HSCT is comparable to normal controls, consistent with DNA analysis showing successful engraftment. The circulating HexA activity in plasma has not normalised. This is likely to reflect the contribution of HexA activity originating from the liver in normal individuals. GM2 GalNAc beta 1-4 [NeuAc alpha 2-3] Gal beta 1-4 Glc-ceramide, GA2 GalNAc beta1-4 Gal beta 1-4 Glc-ceramide, Lc3 GlcNAc beta1-3 Gal beta 1-4 Glc-ceramide. Plasma GA2, Lc3 and GM2 have been reduced by 69, 33 and 29%, respectively. GA2 has returned to normal levels

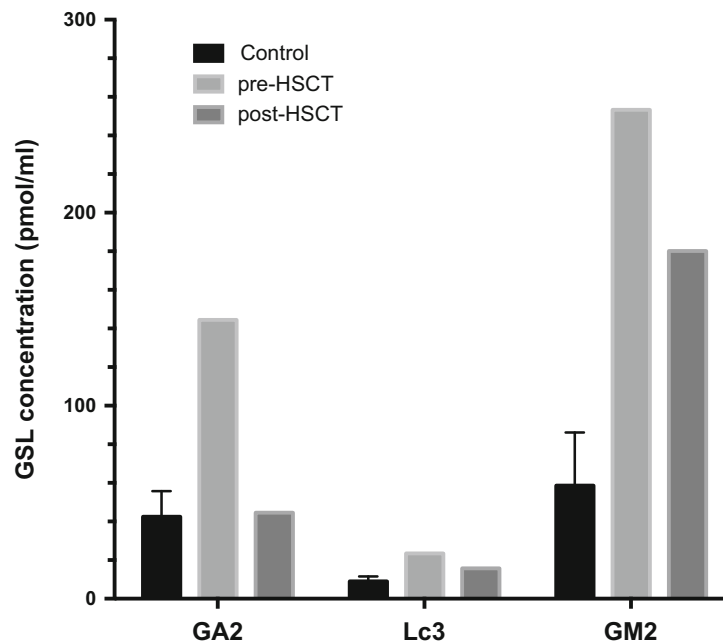


Fig. 1 Concentrations of the three substrates for beta-hexosaminidase present in the circulation (GA2, Lc3 and GM2) in five control plasma samples and the patient untreated and post-HSCT. Post-HSCT, GA2,

Lc3 and GM2 were reduced by 69, 33 and 29% respectively. GA2 has returned to normal levels

cells and ameliorate organ dysfunction. The ability of donor-derived microglia to secrete active enzyme in the central nervous system makes HSCT a suitable therapy for certain neuronopathic forms of LSD such as Hurler syndrome and metachromatic leukodystrophy (MLD). Reported disease outcomes in patients with gangliosidoses have been disappointing (Table 2). Despite having HSCT prior to the symptomatic phase, these children did not benefit from the treatment and had neuroregression similar to untreated affected family members. If outcomes were poor in other forms of TSD, then either it was because the enzyme dose was insufficient or it was performed too late. It raises the question of whether newborn screening for TSD should be considered as an option. To our knowledge, this patient is the first case of LOTS who has had a positive disease outcome with HSCT. His transplant course was uncomplicated, and his neurological progression was arrested post-transplant.

Besides bone marrow transplantation, many treatment strategies for the gangliosidoses have been studied. Patients undergoing HSCT may additionally benefit from further therapy with substrate reduction, using drugs that inhibit ceramide glucosyltransferase, the enzyme that catalyses the first step in the biosynthesis of gangliosides from ceramide (Jacobs et al. 2005). The data is additionally supported by experimental studies of bone marrow transplantation which augmented enzyme levels (Norflus et al. 1998; Wada et al. 2000) and, in combination with substrate reduction therapy, has been shown to extend life expectancy in a mouse model of HexB (Sandhoff disease) (Jeyakumar et al. 2001). No

improvement was observed in a trial of substrate reduction with glucosylceramide synthase inhibitor, as a monotherapy, in individuals with LOTS disease (Shapiro et al. 2009).

Apart from substrate reduction, there are other available treatment options for LOTS disease. Clinical studies have evaluated pharmacological chaperones – competitive inhibitors – of their target enzyme. Pyrimethamine at high doses enhanced HexA activity in leucocytes but caused side effects (Clarke et al. 2011). At low doses, administered in a cyclic manner, monitoring of lymphocyte HexA activity, it has been shown to increase this enzyme's activity in LOTS patients for periods of several weeks to months in patients with certain genotypes (Osher et al. 2015). In LOTS disease patients, residual enzyme activity is very low but detectable. Thus chaperone therapy is designed to rescue newly synthesised mutant enzymes in the endoplasmic reticulum before they are removed for degradation and to deliver them to the lysosome where they can function normally (Rountree et al. 2009). This treatment option is likely to be safe, non-invasive and cost-effective. Larger studies are required to evaluate its effectiveness in this treatment option as a monotherapy or in combination with HSCT. In our case when the decision regarding treatment of his condition was made, the potential benefit of pyrimethamine was not known. As it has not been licenced, it was never considered for this patient. However this therapy holds great promise especially if the tolerability issues can be resolved.

Gene therapy is an emerging potentially curative therapy for genetic diseases with ongoing clinical trials that have

Table 2 Transplant outcome for gangliosidoses

Author	Diagnosis and pre-transplant disease status	Age at transplant	Transplant details				Transplant complications	Transplant outcome	Disease outcome	Remarks
			Donor and stem cell	Conditioning	Cell dose					
GM1 gangliosidosis										
Shield et al. (2005)	Juvenile GM1 gangliosidosis Asymptomatic (normal development, MRI brain and EEG)	7 months	MSD (non-carrier)	NA	NA	None	Mixed chimerism (70–80% donor) at 7 years post-BMT	Neurological deterioration from 20–25 months: MRI brain at 29 months: Demyelination and dysmyelination EEG at 29 months: Diffuse cerebral dysfunction Wheelchair bound and seizure at 7 years old	Diagnosed by family screening Elder sister had late infantile/juvenile form	
GM2 gangliosidosis										
Jacobs et al. (2005)	Subacute Tay-Sachs disease 2 episodes of seizures Normal neurological, ophthalmological examination Normal neuropsychological testing Normal EEG MRI: Mild, non-specific signal abnormalities 3 Tay-Sachs disease 2 Sandhoff disease	3 years 10 months	MUD TCD marrow	Bu/cy/ATG	NA	Ciclosporin-related neurological toxicity	Mixed chimerism	Deterioration of neurological dysfunction Brain MRI, EEG and neuropsychological testing at 6 months and 18 months post-BMT showed pattern of deterioration of deterioration similar to the natural course of the disease in the patient's older, untreated sister with ISD No significant differences compared to untransplanted patients and no milestones were gained after procedure	Substrate reduction therapy started 18 months post-BMT	
Bley et al. (2011)		Average: 10.5 years	NA	NA	NA	NA	1 died of transplant-related complication 2 died of disease-related complication 1 died from aspiration pneumonia			

shown promising results in children with MLD and animal models of mucopolysaccharidoses (MPS). The principle of autologous haematopoietic stem cell (HSC) gene therapy in MLD uses a lentiviral vector to transfer a functional gene into HSCs, and genetically modified HSCs secrete the deficient enzyme to the abnormal cells. Gene therapy for the gangliosidoses was first explored using ex vivo gene transfer using ecotropic retroviruses encoding the human beta-hexosaminidase alpha-subunit cDNA and multipotent neural cell lines. Transfused progenitors were able to secrete high levels of biologically active enzyme and cross-correct the metabolic defect in a human Tay-Sachs fibroblasts cell line in vitro (Lacorazza et al. 1996). Ongoing pre-clinical gene therapy studies for the gangliosidoses include systemic gene transfer and direct intracranial injection of adeno-associated virus vector encoded with hexosaminidase gene (Sargeant et al. 2011; Golebiowski et al. 2017).

In summary, our case illustrates that HSCT is a potential treatment option that slows down neurodegeneration in patients with LOTS and suggests that measuring hexosaminidase substrates in the circulation can serve as potential biomarkers for this disease. Although HSCT has shown promise in this case, further supporting evidence is required before it can be accepted as a treatment option for LOTS disease.

Fran M. Platt is a Wellcome Trust Investigator in Science and a Royal Society Wolfson merit award holder.

Synopsis

HSCT is a potential disease modifying therapy for late-onset Tay-Sachs disease.

General Rules

Details of the Contributions of Individual Authors

KMS conception and design, analysis and interpretation of data, drafting the chapter and revising the chapter critically for important intellectual content.

SHM conception and design, analysis and interpretation of data, drafting the chapter and revising the chapter critically for important intellectual content.

JEW conception and design and analysis and interpretation of data.

CJH revising the chapter critically for important intellectual content.

HC acquisition of data and interpretation of data.

DP conception and design, analysis and interpretation of data, drafting the chapter and revising the chapter critically for important intellectual content.

FP revising the chapter critically for important intellectual content.

SJ acquisition of data and revising the chapter critically for important intellectual content.

AJ acquisition of data and revising the chapter critically for important intellectual content.

RW conception and design, analysis and interpretation of data, drafting the chapter and revising the chapter critically for important intellectual content.

All authors read and approved the manuscript before submission.

The Name of the Corresponding Author

Karolina M. Stepien.

The Mark Holland Metabolic Unit.

Adult Inherited Metabolic Disorders.

Salford, M6 8HD.

Tel 0161 2064365.

A Competing Interest Statement

KS received travel grants from Genzyme, Shire, BioMarin, Amicus and Alexion. She has conflict of interest for this publication.

SHL has no conflict of interest for this publication.

JEW has no conflict of interest for this publication.

CJH is a consultant for Actelion, BioMarin, Chiesi Inventiva, Sanofi, Genzyme and Shire and is owner director of FYMCA Medical Ltd.

HC has no conflict of interest for this publication.

DP has no conflict of interest for this publication.

FP is a co-founder of IntraBio and consultant to IntraBio, Actelion and Orphazyme. She has conflict of interest for this publication.

SJ has no conflict of interest for this publication.

AJ has no conflict of interest for this publication.

RW has no conflict of interest for this publication.

Details of funding: N/A.

Details of ethics approval: patient's consent to bone marrow transplant includes consent to use of transplant outcome data.

A patient consent statement: patient's consent was obtained.

Documentation of approval from the Institutional Committee for Care and Use of Laboratory Animals (or comparable committee): N/A.

Guarantor: RW.

References

- Andersson U, Smith D, Jeyakumar M et al (2004) Improved outcome of N-butyldeoxygalactonojirimycin-mediated substrate reduction therapy in a mouse model of Sandhoff disease. *Neurobiol Dis* 16:506–515
- Bley AE, Giannikopoulos OA, Hayden D et al (2011) Natural history of infantile GM2 gangliosidosis. *Pediatrics* 128(5):1233–1241
- Cachon-Gonzalez MB, Wang SZ, Lynch A et al (2006) Effective gene therapy in an authentic model of Tay-Sachs-related diseases. *Proc Natl Acad Sci U S A* 5:10373–10378
- Clarke JT, Mahuran DJ, Sathe S et al (2011) An open-label phase I/II clinical trial of pyrimethamine for the treatment of patients affected with chronic GM2 gangliosidosis (Tay-Sachs or Sandhoff variants). *Mol Genet Metab* 102:6–12
- Codeiro P, Hechtman P, Kaplan F (2000) The GM2 gangliosidosis databases: allelic variation at the HEXA, HEXB, and GM2A gene loci. *Genet Med* 2(6):319–327
- Godeiro-Junior C, Felicio AC, Benites V et al (2009) Late-onset hexosaminidase A deficiency mimicking primary lateral sclerosis. *Arq Neuropsiquiatr* 67:105–106
- Golebiowski D, van der Bom IMJ, Kwon CS et al (2017) Direct intracranial injection of AAVrh8 encoding monkey beta-N-acetylhexosaminidase causes neurotoxicity in the primate brain. *Hum Gene Ther* 28(6):510–522
- Gravel RA, Clarke JTR, Kaback MM et al (1995) The GM2 gangliosidosis. In: Scriver CR, Beaudet AL, Sly WS et al (eds) *The metabolic and molecular basis of inherited disease*, 7th edn. McGraw-Hill, New York, pp 2839–2882
- Guidotti JE, Akli S, Castelnau-Ptakhine L et al (1998) Retrovirus-mediated enzymatic correction of Tay-Sachs defect in transduced and non-transduced cells. *Hum Mol Genet* 7:831–838
- Jacobs JFM, Willemsen MAAP, Groot-Loonen JJ et al (2005) Allogenic BMT followed by substrate reduction therapy in a child with subacute Tay-Sachs disease. *Bone Marrow Transplant* 36:925–926
- Jeyakumar M, Norflus F, Tiffit CJ et al (2001) Enhanced survival in Sandhoff disease mice receiving a combination of substrate deprivation therapy and bone marrow transplantation. *Blood* 7:327–329
- Jeyakumar M, Smith DA, Williams IM et al (2004) NSAIDs increase survival in the Sandhoff disease mouse: synergy with N-butyldeoxygalactonojirimycin. *Ann Neurol* 56:642–649
- Kyrkanides S, Miller JN, Tallents RH et al (2007) Intraperitoneal inoculation of Sandhoff mouse neonates with an HIV-1 based lentiviral vector exacerbates the attendant neuroinflammation and disease phenotype. *J Neuroimmunol* 188:39–47
- Lacorazza HD, Flax JD, Snyder EY, Jendoubi M (1996) Expression of human beta-hexosaminidase alpha-subunit gene (the gene defect of Tay-Sachs disease) in mouse brains upon engraftment of transduced progenitor cells. *Nat Med* 2(4):424–429
- Lee JP, Jeyakumar M, Gonzalez R et al (2007) Stem cells act through multiple mechanisms to benefit mice with neurodegenerative metabolic disease. *Nat Med* 13:439–447
- Mahuran DJ (1995) Beta-hexosaminidase: biosynthesis and processing of the normal enzyme, and identification of mutations causing Jewish Tay-Sachs disease. *Clin Biochem* 28:101–106
- Matsuoka K, Tamura T, Tsuji D et al (2011) Therapeutic potential of intracerebroventricular replacement of modified human β -hexosaminidase B for GM2 gangliosidosis. *Mol Ther* 19:1017–1024
- Myerowitz R (1997) Tay-Sachs disease-causing mutations and neutral polymorphisms in the Hex A gene. *Hum Mutat* 9:195–208
- Neudorfer O, Pastores GM, Zeng BJ et al (2005) Late-onset Tay-Sachs disease: phenotypic characterization and genotypic correlations in 21 affected patients. *Genet Med* 7:119–123
- Neville DC, Coquard V, Priestman DA et al (2004) Analysis of fluorescently labeled glycosphingolipid-derived oligosaccharides following ceramide glycanase digestion and anthranilic acid labeling. *Anal Biochem* 331:275–282
- Norflus F, Tiffit CJ, McDonald MP et al (1998) Bone marrow transplantation prolongs life span and ameliorates neurologic manifestations in Sandhoff disease mice. *J Clin Invest* 101:1881–1888
- Osher E, Fattal-Valevski A, Sagie L et al (2015) Effect of cyclic, low dose pyrimethamine treatment in patients with late onset Tay Sachs: an open label, extended pilot study. *Orphanet J Rare Dis* 10:45
- Rosebush PI, MacQueen GM, Clarke JTR, Callahan JW, Strasberg PM, Mazurek MF (1995) Late-onset Tay-Sachs disease presenting as catatonic schizophrenia: diagnostic and treatment issues. *J Clin Psychiatry* 56(8):347–353
- Rountree JS, Butters TD, Wormald MR et al (2009) Design, synthesis, and biological evaluation of enantiomeric beta-N-acetylhexosaminidase inhibitors LABNAc and DABNAc as potential agents against Tay-Sachs and Sandhoff disease. *Chem Med Chem* 4:378–392
- Rowland LP (2010) Progressive muscular atrophy and other lower motor neuron syndromes of adults. *Muscle Nerve* 41:161–165
- Sandhoff K, Christomanou K (1979) Biochemistry and genetics of gangliosidosis. *Hum Genet* 50:107–143
- Sargeant TJ, Wang S, Bradley J, Smith NJ, Raha AA, McNair R, Ziegler RJ, Cheng SH, Cox TM, Cachón-González MB (2011) Adeno-associated virus-mediated expression of β -hexosaminidase prevents neuronal loss in the Sandhoff mouse brain. *Hum Mol Genet* 20(22):4371–4380
- Shapiro BE, Natowicz MR (2009) Late-onset Tay-Sachs disease presenting as a childhood stutter. *J Neurol Neurosurg Psychiatry* 80:94–95
- Shapiro BE, Logigian EL, Kolodny EH, Pastores GM (2008) Late-onset Tay-Sachs disease: the spectrum of peripheral neuropathy in 30 affected patients. *Muscle Nerve* 38:1012–1015
- Shapiro BE, Pastores GM, Gianutsos J, Luzy C, Kolodny EH (2009) Miglustat in late-onset Tay-Sachs disease: a 12-month, randomized, controlled clinical study with 24 months of extended treatment. *Genet Med* 11:425–433
- Shield JP, Stone J, Steward CG (2005) Bone marrow transplantation correcting beta-galactosidase activity does not influence neurological outcome in juvenile GM1-gangliosidosis. *J Inher Metab Dis* 28(5):797–798
- Suzuki K (1991) Neuropathology of late-onset gangliosidosis. *Dev Neurosci* 13:205–210
- Tropak MB, Reid SP, Guiral M, Withers SG, Mahuran D (2004) Pharmacological enhancement of beta-hexosaminidase activity in fibroblasts from adult Tay-Sachs and Sandhoff patients. *J Biol Chem* 279:13478–13487
- Wada R, Tiffit CJ, Proia RL (2000) Microglial activation precedes acute neurodegeneration in Sandhoff disease and is suppressed by bone marrow transplantation. *PNAS* 97:10954–10959