



Trauma and reconstruction

## Recurrent bilateral penile fracture: Case report

Francisco Marcos da Silva Barroso<sup>a,\*</sup>, Cristiano Silveira Paiva<sup>b</sup>, Juan Eduardo Rios Rodriguez<sup>c</sup>, Brígida Thaine Fernandes Cabral<sup>c</sup>, Hector Desidério de Araujo<sup>d</sup>, Paloma Menezes de Souza<sup>d</sup>

<sup>a</sup> Hospital Universitário Getúlio Vargas, Avenida Apuriná, 4 - Praça 14 de Janeiro, Manaus, Amazonas, 69020-170, Brazil

<sup>b</sup> Hospital Universitário Getúlio Vargas, Avenida Apuriná, 4 - Praça 14 de Janeiro, Manaus, Amazonas, 69020-170, Brazil

<sup>c</sup> Faculdade de Medicina da Universidade Federal do Amazonas: R. Afonso Pena, 1053 - Praça 14 de Janeiro, Manaus, Amazonas, 69020-160, Brazil

<sup>d</sup> Escola Superior de Ciências da Saúde da Universidade do Estado do Amazonas, Av. Carvalho Leal, 1777 - Cachoerinha, Manaus, Amazonas, 69065-001, Brazil

### Introduction

Penile fracture is a rare closed trauma event in the urological emergency, with immediate clinical diagnosis and surgical treatment. The most commonly reported causes of these accidents are during sexual intercourse and excessive masturbation.<sup>1</sup> The fracture is indeed a tear in the tunica albuginea that wraps the cavernous corpora, due to abrupt impact or reckless positioning during sexual relations, considering that when the penis is erect the thickness of the tunica albuginea decreases from 2 millimeters to 0,5–0,25 millimeters,<sup>2</sup> which results in a weakening of the protective layer, apart from that during erection the cavernous corpora itself increases its pressure because of the blood flow, about 1500 mmHg. Rarer cases are when the urethra is also injured, about 10% as the anatomy of the urethra doesn't present significant change during erection.<sup>2</sup>

The clinical diagnosis is classic in most of cases, which facilitates medical management in these situations. Along with the clinical diagnosis, there are image exams, as Ultrasonography and retrograde Urethrography, nevertheless these exams may only be applied when the history and the physical examination are considered uncertain, otherwise it would only cause a delay when used unnecessarily. The surgical treatment is recommended to be as immediate as possible, which is less than 24h after the trauma to achieve an effective treatment.<sup>1</sup> This time is related with the raise of postoperative complications with late treatment, the sort of flaw in erection or ejaculation.<sup>2</sup>

### Case report

Patient F. L. L. D., age 39, presented in the Urology service at the Hospital Pronto-Socorro 28 de Agosto in July 19th, 2017, reporting that he was having sexual relations with his wife 40 minutes ago, when heard a “click” during the act and felt pain in the genital area right after, besides losing erection. During physical examination the patient presented an increased penile volume and hematoma at the penile shaft.

After clinical diagnosis of penile fracture has been confirmed, it was

proceeded the exploration and surgical repair. Starting with a circular sub-coronal incision at 0,5 cm of the glans, an only 1cm injury was found in the tunica albuginea at middle height of the penile body, closed to the urethra. The suture of the injury was made with polypropylene 2.0. Before finishing the repair, it was made a circumcision. After surgery, it was started using Cephalothin 1 gram for prophylaxis matter, until the 22nd day, when the patient was discharged from hospital with postoperative pain relief, basic hygiene guidelines, analgesic medication, a warrant to a urology clinic service and a recommendation for sexual abstinence. The patient's improvement was complete, however, February 17th, 2018, the patient returns to service reporting pain during sexual intercourse less than 1 h ago, presenting the same physical examination from 8 months before. The operating room was immediately requested.

During the exploration of the region, it has been found a 1,5 centimeter lesion of the right cavernous body with extension to the back of the urethra, reaching the left cavernous body (Figs. 1 and 2).

The raffia of the lesion and incision was made with polyglactin 910 2.0 and 4.0 respectively. The surgery was finished with a compression dressing (Fig. 3). It was also used Cephalothin 1 gram for prophylaxis until February 21st, 2018, when the patient was discharged with total improvement of the symptoms, basic hygiene guidelines, dressings and a warrant to the Urology clinical service. In both cases, the patient didn't present urethrorrhagia and had normal diureses in the postoperative.

### Discussion

The penile fracture is a trauma with many reports and known complications, the sort of flaw in the penis erection and turn in the penile body. Nevertheless, the complications are less frequent and more associated with the delay in the surgical treatment.<sup>4</sup> About recurrence of the fracture in short time, there are little mention of cases, most of them between the 90's and early 2000, then reappearing cases after 2011, such as one recurrent fracture case in 5 years and one another in 2015 with less than one year between the events.<sup>1</sup> There are only 14

\* Corresponding author. Present address: Rua Rego Barros, 831. Parque 10 de novembro, Manaus, Amazonas, Brazil.

E-mail address: [msilvabarroso@hotmail.com](mailto:msilvabarroso@hotmail.com) (F.M.d.S. Barroso).

<https://doi.org/10.1016/j.eucr.2018.08.004>

Received 18 July 2018; Accepted 2 August 2018

Available online 09 August 2018

2214-4420/ © 2018 The Authors. Published by Elsevier Inc. This is an open access article under the CC BY-NC-ND license

(<http://creativecommons.org/licenses/by-nc-nd/4.0/>).

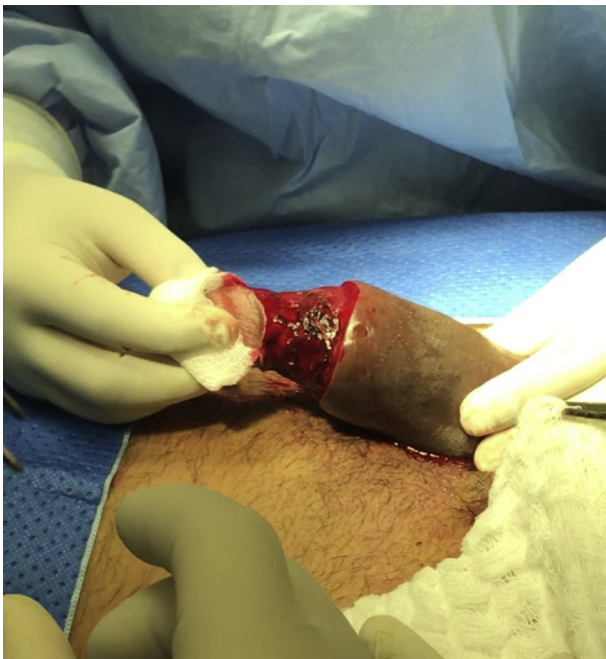

Fig. 1. First incision of pênis, with visualization of bruise in tunica albuginea.

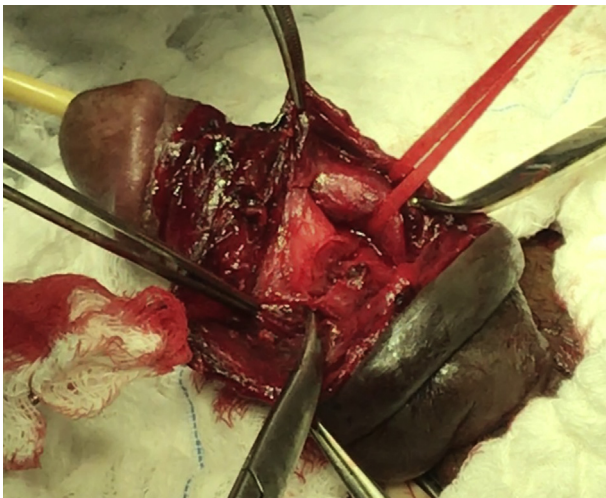


Fig. 2. Tunica albuginea wound in both cavernous corpora.

cases of recurrent penile fracture in literature, according to the team responsible for this article. The reported case was the first one, among the literature searched by this team, with two injuries in different locations in addition to the fact that the second one affected both cavernous bodies. Worth mentioning that none of the cases had a late treatment and all of them occurred less than 24h after the trauma, what could lead one to think in a postsurgical frailty, even using a non-

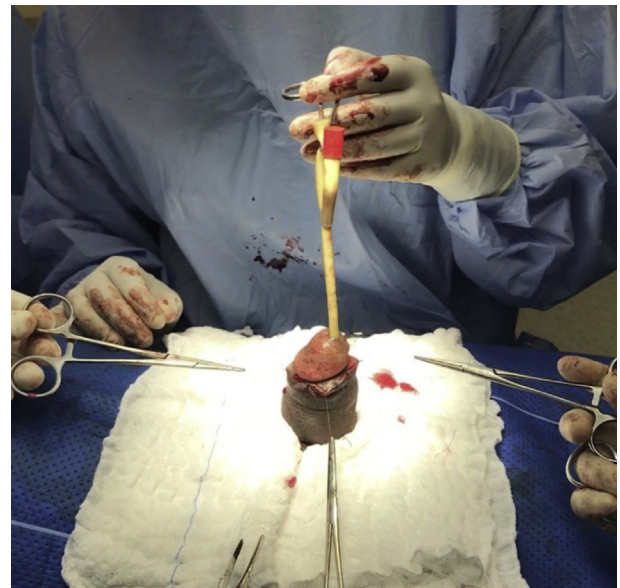


Fig. 3. Final result of surgery repair.

absorbable suture, not a full recovery from the previous lesion, or a leaning to penile fracture due to age and others risk factors.<sup>3,5</sup> Is also worth mentioning that during the patient's recovery, after the first fracture, there has been no complications, such as suture dehiscence or infection in the surgical site.

### Conclusion

There is no work in the present literature about the incidence of recurrent penile fractures or anything that mentions it as a complication in the long-term after surgical repair of previous injury. It's not possible to assume what could be a risk factor for this recurrency, neither how to avoid it, in order to improve the patient's sexual health, which is the main goal for the treatment of these cases. We expect that this work helps and motivates new researches in the same area in order to improve the management of similar situations.

### References

1. Falcone M, Garaffa G, Castiglione F, Ralph DJ. Current Management of Penile Fracture: an Up-to-date Systematic Review. *Sex Med Rev [Internet]*. 2018;6(2):253–260. Elsevier Inc. Available from: <https://doi.org/10.1016/j.sxmr.2017.07.009>.
2. Metzler IS, Reed-Maldonado AB, Lue TF. Suspected penile fracture: to operate or not to operate? *Transl Androl Urol [Internet]*. 2017;6(5):981–986. Available from: <http://tau.amegroups.com/article/view/16508/17399>.
3. Barros R, Guimarães Jr M, CN, Araújo LR, Koifman L, Favorito LA. *Penile Refracture: A Preliminary Report*. vol. 44. 2018; 2018:1–5 January 1982.
4. Nascimento B, Guglielmetti GB, Miranda EP, et al. Recurrent penile fracture — case report and alternative surgical approach. *Sex Med [Internet]*. 2018;5–8. Elsevier Inc. Available from: <https://doi.org/10.1016/j.esxm.2018.01.005>.
5. Ridyad DG, Phillips EA, Munarriz R. *Case Report Recurrent Penile Fracture: a Case Report and Review of Literature*. 2015; 2015:189–191.