

DATA REPORT

Open Access

Mitochondrial DNA 3243A>T mutation in a patient with MELAS syndrome

Takahiro Ikeda¹, Hitoshi Osaka¹, Hiroko Shimbo², Makiko Tajika³, Masayo Yamazaki¹, Ayako Ueda¹, Kei Murayama³ and Takanori Yamagata¹

Abstract

Approximately 80% of cases of mitochondrial myopathy, encephalopathy, lactic acidosis, and stroke-like episodes (MELAS) harbor a heteroplasmic m.3243A>G transition in the tRNA^{Leu (UUR)} (*MTTL1*) gene. We report a MELAS case with a rare heteroplasmic m.3243A>T mutation found by direct sequencing of *MTTL1*. This mutation has been previously reported in 5 cases, of which 2 cases had the MELAS phenotype. Our case also strengthens the hypothesis that the m.3243A>T mutation can cause the MELAS phenotype.

Mitochondrial myopathy, encephalopathy, lactic acidosis, and stroke-like episodes (MELAS) syndrome is caused by mitochondrial DNA (mtDNA) abnormalities^{1,2}. More than 80% of MELAS cases have a common m.3243A>G mutation in the mitochondrial tRNA^{Leu (UUR)} (*MTTL1*) gene^{3,4}. PCR followed by *ApaI* digestion, which detects the A to G substitution at position 3243, is commonly used as a screening tool⁴. However, this approach cannot detect an A to T mutation at the same position, which is another nucleotide change that does not generate the *ApaI* site. We identified an m.3243A>T mutation in a patient with MELAS and compared the phenotypes associated with the rare A>T and the common A>G mutations at m.3243.

The patient is a 15-year-old boy from non-consanguineous parents. His older sister suffered from depression, and his grandmother had diabetes mellitus. He showed normal development and growth until 11 years of age, when he presented with generalized tonic-clonic seizures. At the age of 13 years, he experienced partial seizures that started from the left side of the face and extended to generalized tonic-clonic seizures that

occurred several times a year. Carbamazepine, lamotrigine, and topiramate were administered for seizure control. His academic performance declined, and his intelligence quotient was assessed as 67 with WISC-III before he was admitted to our hospital at 14 years of age. In that same period, he lost 10% of body weight in a 3-month period. On admission, his height and weight (157 cm, -0.6 SD; 45 kg, -0.6 SD, respectively) were normal. He showed cerebellar symptoms, such as dysmetria and intention tremor. He also presented with mild muscle weakness (MMT: 4/5) at the left upper and lower extremities. Deep tendon reflexes were symmetrical and within normal limits. Pathological reflexes were not observed. Despite normal results of routine blood investigations, including lactate and pyruvic acid (13.9 and 0.63 mg/dL; normal range 3.7–16.3 and 0.30–0.90 mg/dL, respectively), cerebrospinal fluid (CSF) lactate and pyruvic acid were elevated (35.7 and 1.37 mg/dL; normal range 13.7–20.5 and 0.63–0.77 mg/dL, respectively). Fasting blood glucose was 93 mg/dL, and urinary sugar was negative. Brain magnetic resonance imaging (MRI) demonstrated high-intensity areas of small multifocal gray matter regions in the right temporal, parietal, and occipital lobes, and diffuse white matter lesions in the left temporal lobe on T2 and fluid-attenuated inversion recovery (FLAIR) images (Fig. 1a; left). No regions followed vascular territories or demonstrated restricted

Correspondence: Hitoshi Osaka (hosaka@jichi.ac.jp)

¹Division of Pediatrics, Jichi Medical University, Shimotsuke, Tochigi, Japan

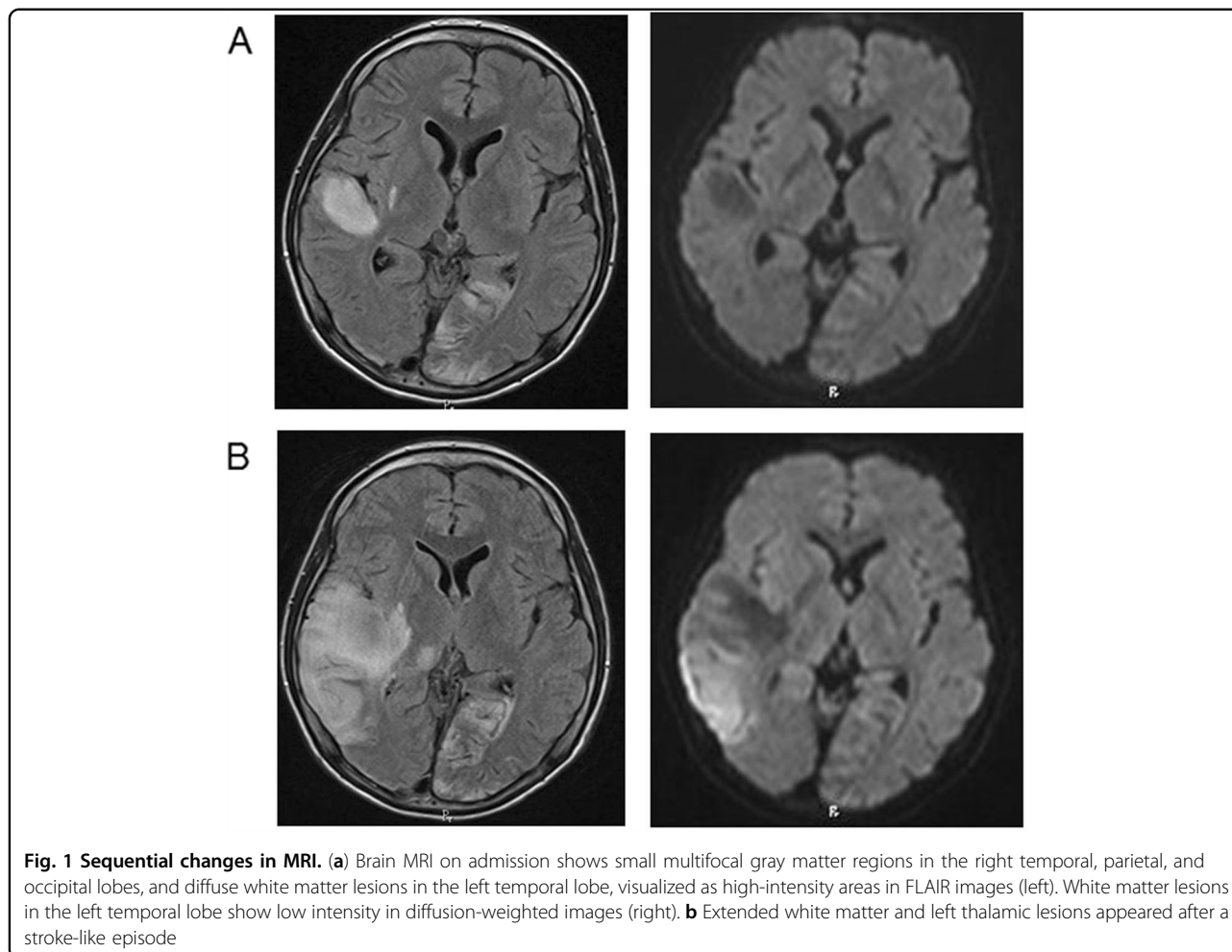
²Department of Pediatric Neurology, Kanagawa Children's Medical Center, Yokohama, Kanagawa, Japan

Full list of author information is available at the end of the article.

© The Author(s) 2018



Open Access This article is licensed under a Creative Commons Attribution 4.0 International License, which permits use, sharing, adaptation, distribution and reproduction in any medium or format, as long as you give appropriate credit to the original author(s) and the source, provide a link to the Creative Commons license, and indicate if changes were made. The images or other third party material in this article are included in the article's Creative Commons license, unless indicated otherwise in a credit line to the material. If material is not included in the article's Creative Commons license and your intended use is not permitted by statutory regulation or exceeds the permitted use, you will need to obtain permission directly from the copyright holder. To view a copy of this license, visit <http://creativecommons.org/licenses/by/4.0/>.



diffusion, thus indicating a subacute/chronic pattern. Auditory brain responses revealed no abnormalities.

After admission, he suffered a stroke-like episode that consisted of frequent generalized tonic-clonic seizures, prolonged consciousness disturbance, and left hemiplegia with expansion of the MRI lesions (Fig. 1b). Intravenous injections of arginine for 3 days, mannitol for 10 days, and edaravone for 14 days were used. Oral arginine, coenzyme Q10, vitamin B1 and B6 were also initiated. His left hemiplegia and mild cerebellar dysfunction remained.

Stroke-like episodes, CSF, and brain MRI findings were consistent with MELAS syndrome. After obtaining informed consent, his DNA was extracted from white blood cells. PCR for *MTTL1* and *ApaI* digestion did not identify a new restriction site introduced by the A to G substitution at position 3243. Direct sequencing of *MTTL1* and mitochondrially encoded NADH dehydrogenase 5 (*ND5*) from blood was performed, and an m.3243A>T mutation was found in *MTTL1*. This mutation created a new restriction site for the *TspRI* enzyme. PCR was performed using a forward primer (m.3114–3134) and a reverse primer (m.3432–3451). The

amplified products were digested with *TspRI* at 65 °C for 1 h and separated in 2.5% agarose gels. Estimated levels of heteroplasmy were 22% in blood, 31% in nail, 37% in saliva, 26% in hair, and 35% in fibroblasts (Fig. 2, Suppl. Figure 1). RNA-folding analysis predicted different secondary structures when A, G, or T occupied position 3243 (Mfold; <http://unafold.rna.albany.edu/?q=mfold/mfold-references>; Suppl. Figure 2). We measured the oxygen consumption rate (OCR) in fibroblast by using an extracellular flux analyzer (Seahorse XF96; Agilent, Santa Clara, CA, USA). Compared to the maximum respiration rates in the control, the maximum respiration rates were reduced to 58% in glucose medium and 47% in galactose medium. The activities of the respiratory chain complexes were within normal range.

Although magnetic resonance spectroscopy and muscle biopsy were not performed, a stroke-like episode, MRI findings, and elevation of lactate in CSF suggested the diagnosis of MELAS syndrome in this case. Therefore, PCR of *MTTL1* and digestion with *ApaI* to detect a new restriction recognition site generated by m.3243A>G, which is the major cause of MELAS, were performed^{4,5}.

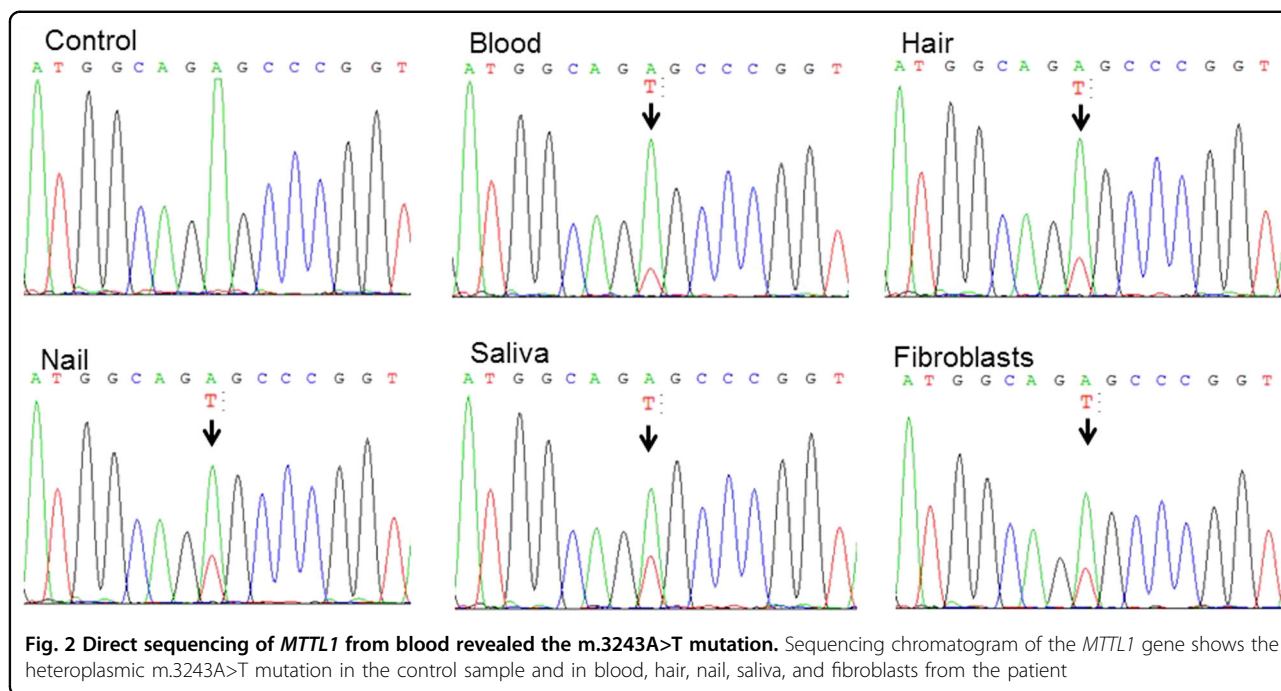


Table 1 Cases with m.3243A>T mutation

Reference	Case	Sex	Onset	Phenotype	Family history	Presentation	Images	Prognosis	Mutation rate
Shaag et al. ⁵	1	F	6 y	MELAS	N.A.	Encephalopathy Muscle weakness Fatigue	CT: ventriculomegaly	10 y vegetative state	Muscle 81% skin 69% blood 14%
Longo et al. ⁶	2	F	7 y	MELAS	N.A.	Stroke-like episodes Hearing loss Visual impairment Short stature Fatigue	MRI, MRA: partial atrophy, multi embolisms	9 y died	Muscle 50% blood 50% skin 50%
Alston et al. ⁷	3	M	6 y	Hearing loss	None	Hearing loss Recurrent keratitis Short stature	CT: basal ganglia calcification	22 y normal IQ	Muscle 87% urinary 88% blood 46% buccal 16%
	4	F	8 y	CPEO	Mother and aunt had short stature	Visual impairment Muscle weakness Ophthalmoplegia Short stature	N.A.	N.A.	Blood 5–10%
Czell et al. ⁸	5	M	29 y	Rhabdomyolysis	Two cousins had diabetes mellitus	Muscle ache after physical exercise	N.A.	N.A.	Muscle 30%
Our case	6	M	11 y	MELAS	Grandmother had diabetes mellitus Sister had depression	Stroke-like episodes Visual impairment Muscle weakness Short stature	MRI: multi-focal stroke like lesions		Blood 22% nail 31% saliva 37% hair 26% fibroblasts 35%

urinary urinary sediment, buccal buccal epithelia, MELAS mitochondrial myopathy, encephalopathy, lactic acidosis, and stroke-like episodes, CPEO chronic progressive external ophthalmoplegia, N.A. not available

However, this approach was unable to detect the G to T substitution that was present in this case. Then, we performed direct sequencing of *MTTL1* and identified the m.3243A>T mutation. We also detected a decrease in the maximum respiration rate of OCR. To the best of our knowledge, the m.3243A>T mutation has been reported in 5 cases (Table 1). Shaag et al. reported a case of a 9-year-old female with rapid progressive encephalopathy and marked lactic acidosis⁵. She presented with a loss of appetite, progressive muscle weakness, and exercise intolerance before the onset of encephalopathy. She then moved into a vegetative state at 10 years of age. Longo et al. also reported a case of a girl with a severe MELAS phenotype with recurrent cerebral infarcts who died at 9 years of age⁶. However, Alston et al. reported two cases that did not have MELAS syndrome: one adult female with normal intellect, sensorineural deafness, and short stature; the other was also a female with chronic progressive external ophthalmoplegia⁷. Czwell et al. also reported an adult case of exercise-induced myalgia and rhabdomyolysis. The patient was normal, except for muscle ache after physical exercise⁸. Including our case, 3 of the 6 cases with the m.3243A>T mutation presented with the MELAS phenotype. Although the secondary structure is predicted to be different between the G and T mutants at m.3243 (Suppl. Figure 2), there are no differences in clinical features between the 3 observed cases with the m.3243A>T mutation and those with the m.3243A>G mutations (Table 1).

In addition to m.3243A>G, mutations causing MELAS mainly include m.3271T>C (~7.5%) and m.3252A>G (<5%) in *MTTL1* and m.13513G>A (<15%) in *NDS*⁴. As the screening m.3243 with *ApaI* digestion is routinely performed, the m.3243A>T transition may have been missed in other cases. Accumulation of new cases with the m.3243A>T mutation may reveal the clinical characteristics of this mutation.

HGV database

The relevant data from this Data Report are hosted at the Human Genome Variation Database at <https://doi.org/10.6084/m9.figshare.hgv.2369>

Acknowledgements

This work was supported by JSPS KAKENHI grant, number 15552768-56006973, to H.O. and by the Project for Health Research on Infants, Children, Adolescents, and Young Adults grant from the Agency of Medical Research and Development to T.Y.

Author details

¹Division of Pediatrics, Jichi Medical University, Shimotsuke, Tochigi, Japan.

²Department of Pediatric Neurology, Kanagawa Children's Medical Center, Yokohama, Kanagawa, Japan. ³Department of Metabolism, Chiba Children's Hospital, Chiba, Chiba, Japan

Conflict of interest

The authors declare that they have no conflict of interest.

Publisher's note

Springer Nature remains neutral with regard to jurisdictional claims in published maps and institutional affiliations.

Supplementary Information is available for this paper at <https://doi.org/10.1038/s41439-018-0026-6>.

Received: 8 April 2018 Revised: 10 June 2018 Accepted: 29 July 2018.

Published online: 4 September 2018

References

1. Yamamoto, M., Clemens, P. R. & Engel, A. G. Mitochondrial DNA Deletions in Mitochondrial Cytopathies: Observations in 19 Patients. *Neurology* **41**, 1822–1828 (1991).
2. Ciafaloni, E. et al. Melas: clinical features, biochemistry, and molecular genetics. *Ann. Neurol.* **31**, 391–398 (1992).
3. Hirano, M. & Pavlakis, S. G. Mitochondrial myopathy, encephalopathy, lactic acidosis, and stroke-like episodes (melas): current concepts. *J. Child Neurol.* **9**, 4–13 (1994).
4. Goto, Y., Nonaka, I. & Horai, S. A mutation in the Trna(Leu)(Uur) gene associated with the melas subgroup of mitochondrial encephalomyopathies. *Nature* **348**, 651–653 (1990).
5. Shaag, A., Saada, A., Steinberg, A., Navon, P. & Elpeleg, O. N. Mitochondrial encephalomyopathy associated with a novel mutation in the mitochondrial Trna leu (Uur) gene (A3243t). *Biochem. Biophys. Res. Commun.* **233**, 637–639 (1997).
6. Longo, N. et al. Progressive cerebral vascular degeneration with mitochondrial encephalopathy. *Am. J. Med. Genet. A* **146A**, 361–367 (2008).
7. Alston, C. L. et al. The pathogenic M.3243a>T mitochondrial dna mutation is associated with a variable neurological phenotype. *Neuromuscul. Disord.* **20**, 403–406 (2010).
8. Czwell, D., Abicht, A., Hench, J., Weber, M. Exercise-induced myalgia and rhabdomyolysis in a patient with the rare M.3243a>T mtDNA mutation. *BMJ Case Rep.* 1–3 (2012). <https://doi.org/10.1136/bcr-2012-006980>.