

Anaplastic lymphoma kinase-negative uterine inflammatory myofibroblastic tumor containing the *ETV6-NTRK3* fusion gene: a case report

Journal of International Medical Research

2018, Vol. 46(8) 3498–3503

© The Author(s) 2018

Article reuse guidelines:

sagepub.com/journals-permissions

DOI: 10.1177/0300060518780873

journals.sagepub.com/home/imr

Akimasa Takahashi¹ , Manabu Kurosawa²,
Mao Uemura¹, Jun Kitazawa¹ and
Yoshihiko Hayashi¹

Abstract

Inflammatory myofibroblastic tumors (IMTs) are neoplasms with low malignant potential, and the most common tumor in the lung and orbit. Their occurrence in the uterus is rare. Approximately 50% of IMT patients have anaplastic lymphoma kinase gene (*ALK*) rearrangements. Recent studies described novel fusions involving *ROS1*, platelet-derived growth factor receptor beta (*PDGFR-β*), and *ETS* translocation variant (*ETV6*) genes in a subset of *ALK*-negative patients. We report a 44-year-old woman with anemia and uterine IMT. Ultrasonography and magnetic resonance imaging revealed a myxoid degenerative myoma-like mass, 7.4 cm in maximum diameter, on the left uterine side wall. Hysterectomy was performed as a definitive treatment. Microscopic examination revealed spindle cell proliferation with numerous lymphocytes and plasma cells. Immunohistochemically, the spindle cells were negative for *ALK*-I, desmin, and smooth muscle actin. The pathological diagnosis was IMT arising from the uterus. Fluorescence *in situ* hybridization demonstrated an *ETV6*–neurotrophic tyrosine kinase, receptor, type 3 gene (*NTRK3*) translocation but no *ALK*, *ROS1*, or *PDGFR-β* translocations. Lung and abdomen computed tomography at 31 months postoperatively revealed no disease recurrence. This association of an *ETV6*–*NTRK3* fusion oncogene with an *ALK*-negative uterine IMT increases our understanding of this neoplasm, which may help the development of specific therapies.

¹Department of Obstetrics and Gynecology, Nagahama City Hospital, Shiga, Japan

²Department of Pathology, Nagahama City Hospital, Shiga, Japan

Corresponding author:

Akimasa Takahashi, Department of Obstetrics and Gynecology, Nagahama City Hospital, 313 Ooinui-cho, Nagahama, Shiga 526-8580, Japan.
Email: akimasat2009@gmail.com



Keywords

Inflammatory myofibroblastic tumor, uterus, crizotinib, *ETV6–NTRK3* fusion gene, fluorescence *in situ* hybridization, anaplastic lymphoma kinase

Date received: 11 January 2018; accepted: 10 May 2018

Introduction

Inflammatory myofibroblastic tumors (IMTs) are rare neoplasms with a wide spectrum of histological features that range from plasma cell-rich lesions to myofibroblast-predominant lesions. In the World Health Organization (WHO) classification of soft tissue tumors, IMTs are classed as intermediate malignancies.¹ IMT primarily occurs in soft tissue and at any anatomical location. However, uterine involvement is extremely rare, with only 74 cases of uterine IMT reported to date. Regardless of the occurrence site, complete excision has been the mainstay of treatment.

In approximately 50% of IMT cases, a clonal rearrangement of chromosome 2p23 involving the anaplastic lymphoma kinase gene (*ALK*) is found, resulting in the overexpression and hyperactivation of this receptor tyrosine kinase.² However, characterization of the remaining *ALK*-negative cases remains incomplete. Recent studies described novel fusions involving *ROS1*, platelet-derived growth factor receptor beta (*PDGFR-β*), and ETS translocation variant (*ETV6*) genes in a subset of *ALK*-negative patients.^{3–5}

Here we present a case of a rare uterine IMT that was treated by hysterectomy. To our knowledge, this is the first report in which uterine IMT showed a novel rearrangement of *ETV6*.

Case report

A 44-year-old woman with no relevant previous medical history presented with

anemia. Laboratory test results revealed hemoglobin levels of 9.0 g/dL, and remaining basic laboratory work was unremarkable. Her physical examination was also normal. A pelvic ultrasound revealed an oval-shaped mass, measuring 7.2 × 6.8 cm, showing heterogeneous echogenicity on the posterior aspect of the uterus. Both ovaries were normal. Magnetic resonance imaging revealed a myxoid degenerative myoma-like mass, measuring 7.4 × 6.6 × 5.2 cm, on the left uterine side wall. The anatomical zone of the uterus was preserved, and the endometrium was enlarged. The parametrium was also normal (Figure 1). Following a diagnosis of hypermenorrhagia because of uterine myoma, total abdominal hysterectomy was performed as a definitive treatment. This study was approved by the research ethics board of Nagahama City Hospital. Written informed consent was obtained from the patient for study entry.

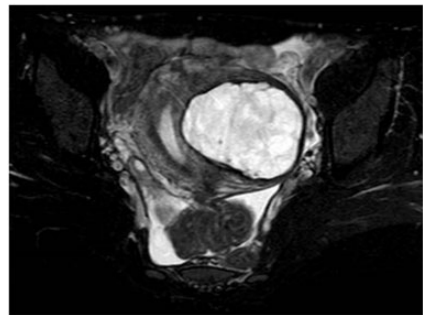


Figure 1. Axial MRI T2-weighted fat-suppressed sequence demonstrating the local lesion with an inhomogeneous hyperintensity on the left uterine side wall.

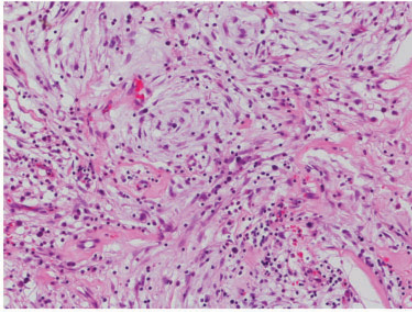


Figure 2. Histopathological findings showing plump spindle and epithelioid cells admixed with lymphocytes and plasma cells in an abundant myxoid extracellular matrix. Cells were stained with hematoxylin and eosin (magnification, $\times 200$).

Microscopic examination of the excised specimen showed proliferation of spindle cells embedded in a storiform pattern together with numerous lymphocytes, plasma cells, and histiocytes in variable amounts of myxoid matrix (Figure 2). Overall, mitotic activity was scant, and necrosis was absent. Focal immunoreactivity for estrogen receptor, progesterone receptor, and cytokeratin AE1/AE3 was present. Immunostaining for ALK-1, ROS1, desmin, vimentin, smooth muscle actin, S-100 protein, CD34, CD31, and h-caldesmon was negative. A diagnosis of IMT was made, based on morphological and immunohistochemical findings.

To confirm the diagnosis, we conducted fluorescence *in situ* hybridization studies to assess the characteristic genetic rearrangements for IMT using *ALK*, *ROS1*, *PDGFR- β* , and *ETV6* break-apart assays.^{3,4} These studies were positive for *ETV6* rearrangement, i.e., the *ETV6*-neurotrophic tyrosine kinase, receptor, type 3 gene (*NTRK3*) fusion oncogene (Figure 3), and negative for *ALK*, *ROS1*, and *PDGFR- β* .

The patient did not undergo any adjuvant therapies, including radiotherapy. Lung and abdomen computed tomography

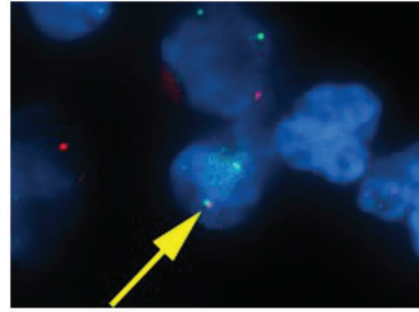


Figure 3. Fluorescent *in situ* hybridization analysis. Yellow arrow indicates *ETV6* arrangement. The presence of the *ETV6-NTRK3* fusion is demonstrated by the close proximity of a green signal (*ETV6* from chromosome 12) with a red signal (*NTRK3* from chromosome 15) in multiple tumor cells.

at 31 months postoperatively showed no disease recurrence.

Discussion

To our knowledge, this is the first study to genetically confirm the presence of the *ETV6-NTRK3* fusion oncogene in an *ALK*-negative IMT of the uterus.

The WHO classification of soft tissues defines IMT as a distinctive neoplasm comprising myofibroblastic and fibroblastic spindle cells accompanied by an inflammatory infiltrate of plasma cells, lymphocytes, and/or eosinophils.¹ IMT most commonly occurs in the lung but can also be observed in the soft tissue, retroperitoneum, head, laryngeal region, and central nervous system.⁶ The uterine body is an extremely rare location for IMTs, with even the largest series of uterine IMT reporting only 13 cases.⁷ Thus, IMTs may often be misdiagnosed because difficulties are associated with their histological differentiation from uterine smooth muscle tumors such as leiomyomas and leiomyosarcomas. Three microscopic patterns have been described: myxoid, fascicular, and hyalinized,⁶ and

the tumor in our patient showed a myxoid pattern.

ALK expression in IMTs of the female genital tract appears to be frequent, similar to other anatomical sites.⁸ Indeed, a review article reported that 58 of 62 (93.6%) uterine IMT patients were positive for ALK immunostaining.⁹ Immunohistochemical expression of the ALK protein is therefore a very important hallmark for differentiating IMTs from other tumors. The review also stated that only four of the 47 ALK-positive immunostaining patients with follow-up information died of disease, and had a mean overall survival time of 52.8 months.⁹ Therefore, if spindle cell lesions are detected in the uterus, IMTs should be included in the differential diagnosis, and an immunohistochemical examination of ALK protein expression is required.

We confirmed that IMT in our case did not have the *ALK* fusion gene. Typically, 50%–60% of IMTs carry translocations involving *ALK* on chromosome 2p23,^{10,11} resulting in the constitutive activation of ALK tyrosine kinase. Clinically, the presence of ALK expression is determined by immunohistochemistry, and the lack of ALK expression is associated with a higher age overall, subtle histological differences, and death from disease or distant metastases.¹⁰ However, the characterization of *ALK*-negative IMT remains incomplete. A recent study using targeted next-generation sequencing described novel fusions involving *ROS1*, *PDGFR β* , and *ETV6* in *ALK*-negative cases.^{3,4} In a previous study, only two cases of IMT contained the *ETV6-NTRK3* fusion gene: one in the lung and the other in the liver.⁴ To our knowledge, our study is the fourth to report IMTs with the *ETV6-NTRK3* fusion gene, and the first to report IMT of the uterus.

ETV6-NTRK3 is an oncogenic chimeric tyrosine kinase. This fusion gene has been discovered in various tumors such as

congenital infantile fibrosarcoma, acute myeloblastic leukemia, secretory breast cancer, mammary analog secretory carcinoma of the salivary gland, and papillary thyroid carcinoma.^{12–16} Tumors with *ETV6-NTRK3* expression demonstrated downstream hyperactivation of phosphoinositide 3-kinase and RAS signaling pathways,¹⁷ and only show a limited response to cytotoxic anticancer agents;¹⁸ however, acute lymphoblastic leukemia cell lines with *ETV6-NTRK3* fusions were sensitive to crizotinib.¹⁹ Although crizotinib may be a promising therapeutic agent for IMT with the *ETV6-NTRK3* fusion gene, the effect of crizotinib on this tumor is unknown. Therefore, the therapeutic relevance of identifying fusion genes for *ALK*-negative IMT is unclear. In general, uterine IMTs require surgical removal, but there is a propensity for local recurrence. When surgical resection is difficult, drug therapy may be necessary, but no effective drugs have been identified. Therefore, we believe that our findings will contribute to the development of novel targeted therapeutic agents against IMT.

In summary, we demonstrated to our knowledge the first occurrence of the *ETV6-NTRK3* fusion oncogene in an *ALK*-negative IMT of the uterus. These results suggest that a subset of *ALK*-negative IMTs have *ETV6-NTRK3* rearrangements as a possible oncogenic mechanism, and that detection of these alterations may be of diagnostic value and help for determining promising therapeutic strategies.

Acknowledgments

The authors thank Chromosome Science Labo Inc. (Hokkaido, Japan) for *in situ* hybridization studies. The authors would also like to thank Enago (www.enago.jp) for their English language review.


Declaration of conflicting interest

The authors declare that there is no conflict of interest.

Funding

This research received no specific grant from any funding agency in the public, commercial, or not-for-profit sectors.

ORCID iD

Akimasu Takahashi  <http://orcid.org/0000-0001-5698-553X>

References

- Jo VY and Fletcher CD. WHO classification of soft tissue tumours: an update based on the 2013 (4th) edition. *Pathology* 2014; 46: 95–104.
- Coffin CM, Patel A, Perkins S, et al. ALK1 and p80 expression and chromosomal rearrangements involving 2p23 in inflammatory myofibroblastic tumor. *Mod Pathol* 2001; 14: 569–576.
- Lovly CM, Gupta A, Lipson D, et al. Inflammatory myofibroblastic tumors harbor multiple potentially actionable kinase fusions. *Cancer Discov* 2014; 4: 889–895.
- Alassiri AH, Ali RH, Shen Y, et al. ETV6-NTRK3 is expressed in a subset of ALK-negative inflammatory myofibroblastic tumors. *Am J Surg Pathol* 2016; 40: 1051–1061.
- Yamamoto H, Yoshida A, Taguchi K, et al. ALK, ROS1 and NTRK3 gene rearrangements in inflammatory myofibroblastic tumours. *Histopathology* 2016; 69: 72–83.
- Coffin CM, Watterson J, Priest JR, et al. Extrapulmonary inflammatory myofibroblastic tumor (inflammatory pseudotumor). A clinicopathologic and immunohistochemical study of 84 cases. *Am J Surg Pathol* 1995; 19: 859–872.
- Bennett JA, Nardi V, Rouzbahman M, et al. Inflammatory myofibroblastic tumor of the uterus: a clinicopathological, immunohistochemical, and molecular analysis of 13 cases highlighting their broad morphologic spectrum. *Mod Pathol* 2017; 30: 1489–1503.
- Fuehrer NE, Keeney GL, Ketterling RP, et al. ALK-1 protein expression and ALK gene rearrangements aid in the diagnosis of inflammatory myofibroblastic tumors of the female genital tract. *Arch Pathol Lab Med* 2012; 136: 623–626.
- Mandato VD, Valli R, Mastrofilippo V, et al. Uterine inflammatory myofibroblastic tumor: more common than expected: Case report and review. *Medicine* 2017; 96: e8974.
- Coffin CM, Hornick JL and Fletcher CD. Inflammatory myofibroblastic tumor: comparison of clinicopathologic, histologic, and immunohistochemical features including ALK expression in atypical and aggressive cases. *Am J Surg Pathol* 2007; 31: 509–520.
- Saab ST, Hornick JL, Fletcher CD, et al. IgG4 plasma cells in inflammatory myofibroblastic tumor: inflammatory marker or pathogenic link? *Mod Pathol* 2011; 24: 606–612.
- Knezevich SR, Garnett MJ, Pysner TJ, et al. ETV6-NTRK3 gene fusions and trisomy 11 establish a histogenetic link between mesoblastic nephroma and congenital fibrosarcoma. *Cancer Res* 1998; 58: 5046–5048.
- Eguchi M, Eguchi-Ishimae M, Tojo A, et al. Fusion of ETV6 to neurotrophin-3 receptor TRKC in acute myeloid leukemia with t(12;15)(p13;q25). *Blood* 1999; 93: 1355–1363.
- Tognon C, Knezevich SR, Huntsman D, et al. Expression of the ETV6-NTRK3 gene fusion as a primary event in human secretory breast carcinoma. *Cancer Cell* 2002; 2: 367–376.
- Skálová A, Vanecek T, Sima R, et al. Mammary analogue secretory carcinoma of salivary glands, containing the ETV6-NTRK3 fusion gene: a hitherto undescribed salivary gland tumor entity. *Am J Surg Pathol* 2010; 34: 599–608.
- Leeman-Neill RJ, Kelly LM, Liu P, et al. ETV6-NTRK3 is a common chromosomal rearrangement in radiation-associated thyroid cancer. *Cancer* 2014; 120: 799–807.
- Tognon C, Garnett M, Kenward E, et al. The chimeric protein tyrosine kinase

- ETV6-NTRK3 requires both Ras-Erk1/2 and PI3-kinase-Akt signaling for fibroblast transformation. *Cancer Res* 2001; 61: 8909–8916.
18. Arce C, Cortes-Padilla D, Huntsman DG, et al. Secretory carcinoma of the breast containing the ETV6-NTRK3 fusion gene in a male: case report and review of the literature. *World J Surg Oncol* 2005; 3: 35.
19. Roberts KG, Li Y, Payne-Turner D, et al. Targetable kinase-activating lesions in Ph-like acute lymphoblastic leukemia. *N Engl J Med* 2014; 371: 1005–1015.