



# Swellings of the sternoclavicular joint: review of traumatic and non-traumatic pathologies

John Edwin<sup>1</sup>  
Shahbaz Ahmed<sup>2</sup>  
Shobhit Verma<sup>1</sup>  
Graham Tytherleigh-Strong<sup>3</sup>  
Karthik Karuppaiah<sup>1</sup>  
Joydeep Sinha<sup>1</sup>

- The sternoclavicular joint (SCJ) is an integral part of the shoulder girdle that connects the upper limb to the axial skeleton.
- Swelling of the SCJ is commonly due to trauma, degeneration, infections and other disease processes that affect synovial joints.
- This review also focuses on uncommon conditions that could affect the SCJ, including SAPHO (synovitis, acne, pustulosis, hyperostosis, osteitis) syndrome, Friedrich's disease and Tietze syndrome.
- The scope of this review is limited to the analysis of the current evidence on the various conditions affecting the SCJ and also to provide an algorithm to manage these conditions.

**Keywords:** instability; sternoclavicular; trauma

Cite this article: *EFORT Open Rev* 2018;3:471-484.  
DOI: 10.1302/2058-5241.3.170078

## Introduction

Sternoclavicular joint pathology has been less understood in the past, and there has been greater interest recently due to improved understanding of the biomechanics, and improved diagnostic and treatment modalities. Like any other joint, trauma, infections, inflammatory and degenerative conditions affecting the sternoclavicular joint are well known. The rarity of these problems compounded with a paucity of literature could indirectly lead to delayed diagnosis and inappropriate treatment, which might lead to increased morbidity and poor outcomes. This study aims to review the management of traumatic and systemic conditions that affect the sternoclavicular joint, including the role of arthroscopic surgery.

## Anatomy of the sternoclavicular joint

The sternoclavicular joint is a diarthrodial saddle joint formed by the sternal end of the clavicle, the clavicular notch of the manubrium and the cartilage of the first rib. The intra-articular disc, anterior and posterior sternoclavicular (SC) ligaments, the costoclavicular (CC) or rhomboid ligament and the interclavicular ligament provide stability to the shallow articular surfaces.<sup>1</sup> The bony articulation between the medial end of the clavicle and the manubrium is < 50%, thus rendering the joint potentially unstable.<sup>2</sup> The sternoclavicular joint (SCJ) glides up to 30 degrees anteroposteriorly, pivots up to 30 degrees superoinferiorly and rotates up to 45 degrees axially. Disruption to this capsuloligamentous structure can cause migration of the medial clavicle. The posterior capsule is an important stabilizer preventing anterior and posterior translation of the SC joint, while the anterior capsule resists anterior translation. This probably explains the higher incidence of anterior as compared to posterior dislocations.<sup>3-5</sup> The costoclavicular ligament, comprising two laminae, is thought to become taut at opposite extremes of axial rotation of the clavicle. When a direct impact is applied to the posterolateral aspect of the shoulder due to trauma, this ligament acts as a fulcrum resulting in a medial and posterior displacement of the medial clavicle.

Passive stabilizers of the SCJ are the intra-articular disc ligament and the rhomboid ligaments which are extra-articular. The articular disc is circular and is attached to the articular surface of the clavicle superiorly and to the first rib near its insertion to the manubrium, inferiorly dividing the joint into two synovial cavities. The rhomboid ligament along with anterior and posterior sternoclavicular ligaments and the interclavicular ligament provide stability in the coronal plane (Fig. 1).

Movement at the SC joint occurs passively in the axial, horizontal and vertical planes. This is usually produced as

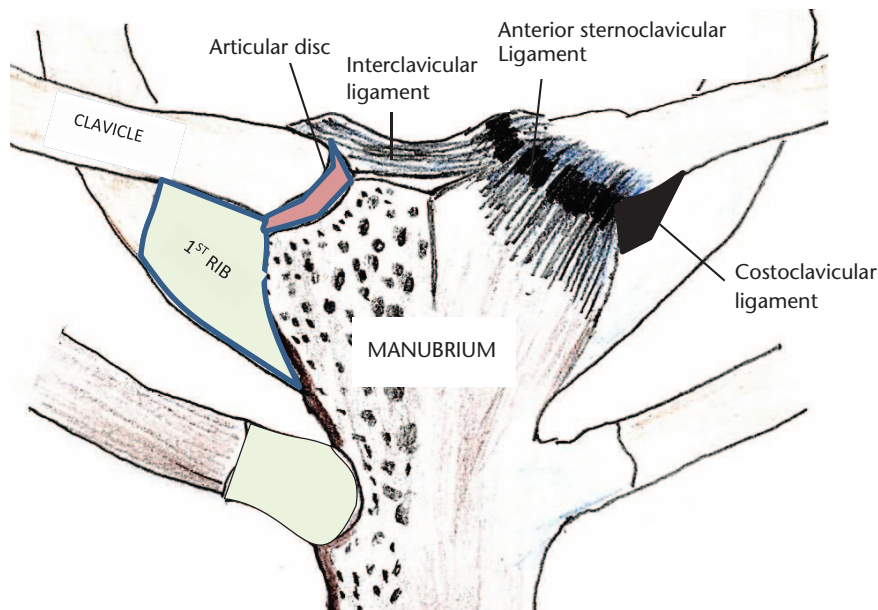


Fig. 1 Illustration of the sternoclavicular joint.

transmitted movements of the scapula on the chest wall. The clavicle is the first long bone to ossify but the medial end of the clavicle is the last epiphysis to close. The medial end ossifies around 18 to 20 years of age and fuses with the shaft of the clavicle around the age of 23 to 25 years.<sup>6</sup> The growth plate remains the weakest point until fusion and hence a displaced physal fracture is usually more common than a true dislocation.<sup>7</sup> Many mediastinal structures are at risk following posterior dislocation of the SCJ, as described in the clinical presentation section.<sup>8–16</sup>

## Materials and methods

A comprehensive search of the EBSCO-hosted National Library of Medicine (Medline) database, PubMed, NICE Evidence Healthcare (databases provided through NLH search 2.0, AMED [Ovid], BNI [Ovid], CINAHL [EBSCO], Embase [Ovid], HMIC:DH-Data and Kings Fund [Ovid], Medline [Ovid] and Psycinfo), COCHRANE and EMBASE was conducted for English-language articles published between 1975 and March 2016 using the keywords: “sternoclavicular”, “sternoclavicular swelling”, “sternoclavicular instability”, “sternoclavicular joint dislocation”, “tumour”, “SAPHO”, “condensing osteitis of clavicle”, “sternoclavicular injury”, “sternoclavicular joint arthritis”, “sternoclavicular osteomyelitis”, “sternoclavicular joint infection”, “sternoclavicular septic”, “sternoclavicular septic arthritis” and “operative treatment”. Additionally, grey literature and references from the relevant articles were hand searched. The initial search yielded 275 articles and after applying strict inclusion and exclusion criteria, 54 articles were chosen for review. We included all

relevant studies with full articles and minimum 1-year follow-up, at least six patients for traumatic pathology and no minimum number of cases for non-traumatic causes. We excluded studies that included revision surgery, associated acromioclavicular injury or fracture of the clavicle.

For the purpose of this review, the causes for SCJ swelling have been classified into traumatic, degenerative, inflammatory, infective and finally disorders relatively specific to the SCJ.

## Traumatic injuries to the sternoclavicular joint

### Epidemiology

Traumatic sternoclavicular injuries are rare and account for less than 3% of all traumatic joint injuries.<sup>3</sup> Dislocations of the sternoclavicular joint comprise 1% of all joint dislocations, and 3% of those in the upper limb.<sup>17</sup> Boesmueller et al<sup>18</sup> found that the incidence of SCJ injuries was 0.9% in all shoulder-girdle lesions and 1.1% in all dislocations. Young, active males are more likely to present with this injury after high-energy trauma. Instability of the SCJ can be described by severity (sprain, subluxation or dislocation) and onset (acute or chronic).<sup>19,20</sup>

### Pathophysiology

Sternoclavicular joint dislocation occurs after high-energy injuries including road-traffic accidents, sporting injuries and falls from height.<sup>21</sup> Anterior dislocation has been reported to be up to three times more common than

posterior dislocation.<sup>9,22</sup> Allman described the severity of injury as either Grade 1, minor injury with no joint laxity; Grade 2, subluxation of joint; or Grade 3, complete disruption of the SC and CC ligament with instability.<sup>19</sup> Anterior dislocation can occur as a result of non-traumatic conditions including ligamentous laxity, collagen disorders and aplasia of the medial end of the clavicle. The symptoms are usually mild and typically occur when the involved arm is hyperabducted. In contrast, posterior dislocation is usually the result of indirect trauma but can occur because of direct injury to the medial clavicle.<sup>23</sup> It may also occur due to a force directed to the posterior aspect of the shoulder, causing the lateral end of the clavicle to protract anteriorly.<sup>3</sup> Studies have shown that the force required to dislocate the SCJ posteriorly is 50% greater than the force needed for an anterior dislocation.<sup>3</sup> Cadaver studies have demonstrated that the posterior capsuloligamentous structure is the most important of the four constraints. It produces instability in anterior and posterior directions on releasing its attachment.<sup>3</sup>

Sewell et al<sup>24</sup> extrapolated the Stanmore instability triangle concept described previously for the shoulder joint to explain the pathology of sternoclavicular instability. They described the causative factors as Type I, traumatic structural; Type II, atraumatic structural; and Type III, muscle patterning (neuromuscular). The treatment for Type I injuries has been discussed above. Type II may rarely require stabilization and Type III injuries are almost always treated with biofeedback physiotherapy.

#### Clinical presentation

Usual presentation is trauma followed by pain, swelling and deformity over the sternoclavicular joint. A prominent medial clavicle in anterior dislocation and a palpable defect next to the sternum in posterior dislocation are usually apparent on inspection and palpation. Following a posterior dislocation of the sternoclavicular joint, all the ligamentous attachments are disrupted.<sup>8</sup> The relation of the thoracic inlet and its neurovascular contents to the SCJ makes posterior dislocations of this joint particularly dangerous.<sup>9–12,25</sup> Fortunately they are less common than anterior dislocations.<sup>13,26</sup> In addition to SCJ dislocation, concomitant injury to the acromioclavicular joint or clavicular fracture<sup>27,28</sup> has been reported. It is very difficult to differentiate true dislocation from displacement of the medial clavicle physeal fracture in patients up to 25 years of age.<sup>16,29</sup>

#### Investigations

Routine radiographic studies of the sternoclavicular joint are difficult to interpret due to overlap of the medial clavicle, ribs, sternum, and vertebrae. Additional views such as the 'serendipity' (40° cephalic tilt radiograph showing both sternoclavicular joints developed by Wirth and Rockwood) oblique (Hobbs) and lateral (Heinig) are helpful in diagnosis.

Computed tomography (CT) scan is the imaging technique of choice for evaluation of isolated sternoclavicular injury to observe additional injuries to the upper thoracic ring.<sup>7,29,30</sup> Intravenous contrast administration may be beneficial for accurate evaluation of mediastinal structures.<sup>14,31</sup> Magnetic resonance imaging (MRI) is useful in differentiating physeal injury from sternoclavicular dislocation in younger patients aged < 23–25 years.<sup>29</sup>

#### Management

##### Anterior dislocation

Based on Allman's classification, acute Grade 1 and 2 (sprain and subluxation) injuries are treated conservatively<sup>16</sup> and Grade 3 injuries are treated by closed reduction. The technique for closed reduction is to place a sandbag/rolled towel between the scapulae followed by direct posterior pressure on the medial end of the clavicle. Some patients develop recurrent instability and the incidence varies from 21–100%.<sup>32</sup> If closed reduction fails, the options may be open reduction and stabilization of the joint or to accept the dislocation, as long-term results can still be satisfactory.

Fery and Sommelet<sup>26</sup> reviewed long-term results of SCJ dislocations. In their series, operative treatment had 66% excellent results, whereas immobilization, particularly with unreduced dislocations, accounted for most of the unsatisfactory results. They concluded that the joint should be reduced either closed or open. Eskola<sup>32</sup> reviewed 12 cases of SCJ dislocation. Eight cases were reduced with closed technique, out of which five redislocated. Out of the five redislocations, two patients had surgery with one good and one poor result. All cases with primary open reduction and stabilization did well. Eskola suggested open reduction for all cases. Glass et al<sup>33</sup> in their systematic review of 241 cases found that acute anterior dislocations treated initially by closed reduction achieved better functional outcomes than if treated solely by open reduction (92% vs. 76% excellent/good results). De Jong and Sukul<sup>34</sup> have reported good long-term results with conservative treatment. Ten patients were evaluated after a mean follow-up period of 62.9 months. The results were good in seven patients, fair in two patients, and poor in one patient. Other authors have suggested that functional outcomes in spite of instability remain unaffected, and that operative intervention may be mainly cosmetic as instability and deformity can persist despite surgery.<sup>13,16,20</sup> Morell and Thyagarajan<sup>35</sup> emphasized the non-surgical treatment of anterior SCJ dislocations in their review (Fig. 2).

##### Surgical management

Surgical options can broadly be classified into excision of the medial end of the clavicle or stabilization of the SCJ.

*Excision of the medial clavicle.* Glass et al<sup>33</sup> in their systematic review found that resection had relatively

ALGORITHM FOR MANAGEMENT FOR TRAUMA INVOLVING THE STERNOCLAVICULAR JOINT

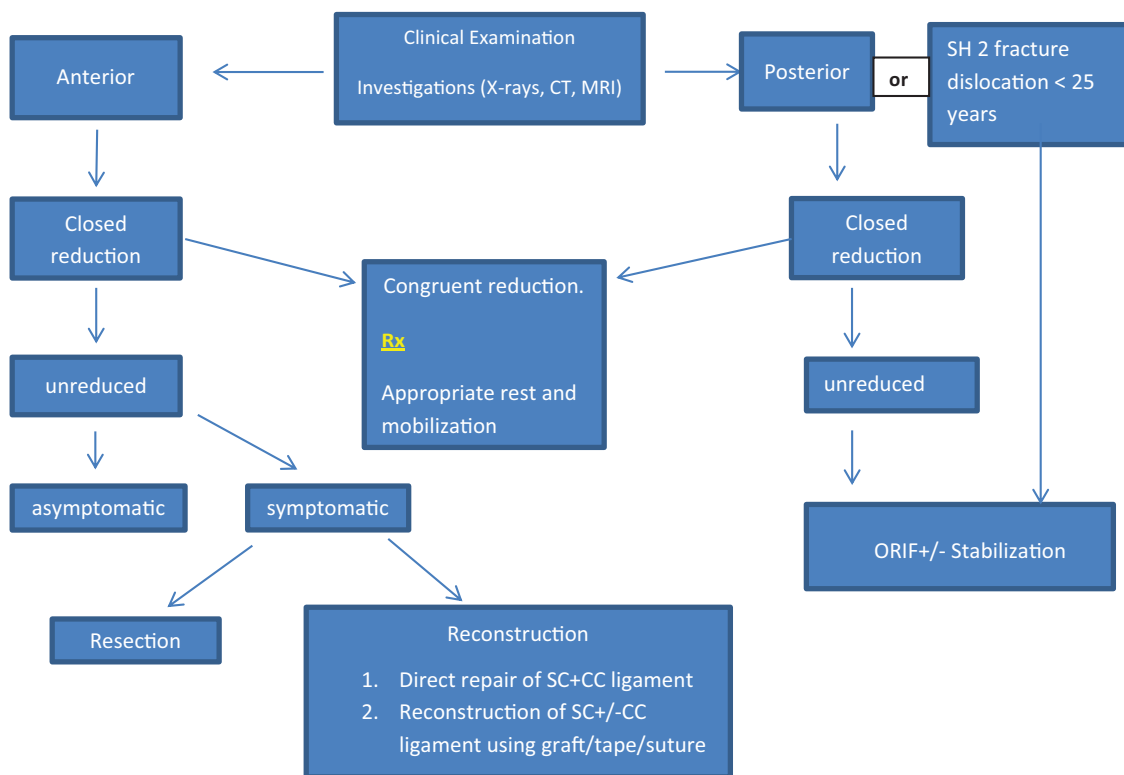


Fig. 2 Management algorithm for traumatic sternoclavicular joint dislocation.

Note. CT, computed tomography; MRI, magnetic resonance imaging; SC, sternoclavicular; CC, costoclavicular.

poorer outcomes than other procedures, although this may have been due to the large amounts of clavicle resected (1–1.5 inches). The key to this procedure is to retain the costoclavicular ligament, and good results have been shown by others.<sup>20,36</sup> Bisson et al<sup>37</sup> in a cadaveric study have shown that resection of 1.0 cm of the medial clavicle would preserve the costoclavicular ligament in 84% of men, and resection of 0.9 cm would do the same in 89% of women. In a recent cadaveric study, Katthagen et al<sup>38</sup> suggested that resection of the articular disc alone is insufficient to decompress the SCJ. Resection of 5 mm of the medial end of the clavicle with the parallel resection technique reliably decompressed the SC joint better than with the oblique resection technique.

*Stabilization of the SCJ.* Stabilization of the SCJ can be carried out by either direct suturing/fixation or ligament reconstruction of the SCJ. Direct repair of the SC and costoclavicular ligaments is a technique that can be used in acute cases using a variety of suture materials, anchors, wiring, plating or tension band fixation. Witvoet and Martinez<sup>39</sup> and Eskola<sup>32</sup> have employed combinations of techniques using wiring and ligamentous repair with Palmaris longus/subclavius with good

results. Lehmann et al<sup>40</sup> used a suture anchor that was placed in the sternum using Polydioxanone (PDS) suture in the medial clavicle and first rib. Abiddin et al<sup>41</sup> used suture anchors in the manubrium with capsular plication with good results in eight cases. Kirby et al<sup>10</sup> have used intraosseous sutures, Mersilene tape or plates for stabilization in patients requiring open reduction in 13 patients (10 posterior, two anterior and one superior) with good outcomes. Franck et al used Balser plates hooked under the medial clavicle to reduce dislocation with good results in 10 cases (seven anterior and three posterior),<sup>42</sup> the disadvantage being a second surgery for plate removal. Chen et al<sup>43</sup> have described tension band wiring of the SCJ in nine cases with excellent outcome in eight cases. Ferrandez et al<sup>13</sup> fixed acute dislocations in 10 patients using K-wires augmented with wiring of the manubrium to the clavicle in four patients. Functionally, all patients returned to work. However, wires have historically acquired a poor reputation in the SCJ with reports of migration, vascular injury and death.<sup>13,21,30,44</sup>

Reconstruction of the anterior sternoclavicular joint is the most common procedure for chronic symptomatic anterior SC dislocation. Historically, fascia lata graft was

used. Different autografts have been used to stabilize the joint. Armstrong and Dias<sup>45</sup> and Uri et al<sup>46</sup> successfully used the medial portion of the sternal head of the sternocleidomastoid muscle or the subclavius muscle (Jackson Burrows technique).<sup>47</sup> Bak and Fogh<sup>48</sup> utilized hamstring or Palmaris longus tendon with good results in 27 prospectively reviewed patients. Quayle et al<sup>49</sup> have shown promising results treating chronic SCJ instability using an artificial ligament weave (LARS: Ligament Augmentation and Reconstruction System). Surgilig LockDown™ (Lock-Down, Redditch, UK)<sup>50</sup> has also been used with good results in SCJ stabilization. In addition, the costoclavicular ligament can be reconstructed as a sole procedure<sup>51</sup> or augmented with a SCJ ligament reconstruction.<sup>52</sup> With this technique, different autografts including the use of semitendinosus and sternocleidomastoid have been used to reconstruct the costoclavicular ligament.<sup>51</sup> Lee et al<sup>52</sup> used sternocleidomastoid muscle for SCJ reconstruction with costoclavicular ligament augmentation using the palmaris longus free tendon graft to secure the medial end of the clavicle to the first rib. Spencer and Kuhn<sup>53</sup> have suggested that stabilization using a figure of eight technique is biomechanically superior to other techniques. This has been supported by clinical results in recent literature.<sup>54–56</sup>

In their systematic review, Glass et al<sup>33</sup> identified 251 sternoclavicular dislocations in which 117 patients had anterior dislocations. They found excellent or good results were achieved in the non-operative group in 69% of patients with anterior dislocations. Patients with acute dislocations managed with closed reduction fared better than patients treated solely by surgical treatment (92% vs. 76% excellent/good results). The outcomes for chronic anterior dislocation were not significantly different between the non-operative and operative groups.

In summary, not all cases of anterior dislocation need surgery. A small subgroup of these patients develops persistent symptomatic anterior instability. This is related to overhead physical activity and these patients show satisfactory results with surgical stabilization.

#### *Retrosternal (posterior) dislocation*

Traumatic posterior SC dislocations are rare, but complications are more common than after anterior dislocations. Posterior dislocations remain stable after reduction, whereas anterior dislocations remain unstable if untreated or managed conservatively, although they are not usually symptomatic.<sup>20,34,57</sup> With delayed presentation, the whole area becomes swollen and it can be difficult to clinically differentiate between anterior and posterior dislocation.

The mediastinal structures at risk from a posterior dislocation are the subclavian veins crossing the first rib, the internal jugular vein, the internal thoracic artery with its two venae comitantes, the subclavian artery, the brachiocephalic

vessels,<sup>58</sup> the trachea, the oesophagus, and the phrenic and vagus nerves.<sup>8</sup> These injuries can result in swelling and cyanosis of the corresponding arm, cervical bruit, respiratory distress, stridor, tracheal haematoma, diaphragmatic paralysis and death.<sup>9</sup> A CT-based study demonstrated that the most frequent structure at risk to SCJ dislocation is the brachiocephalic vein at an average distance of 6 mm (range 1–10 mm).<sup>14</sup> It is also possible for the posteriorly displaced medial clavicle to damage the dome of the pleura and the lungs and lead to a haemothorax, pneumothorax or a pneumomediastinum.<sup>15,29</sup> Thoracic outlet syndrome and compression of the brachial plexus have been reported in cases of chronic posterior dislocation of the SCJ requiring surgical decompression.<sup>11</sup> It is prudent to have the thoracic surgery team in the operating theatre during reduction, due to the risk of vascular or local soft viscera injury.<sup>16</sup>

#### *Management*

Closed reduction is the mainstay of treatment in the acute stage. A commonly described reduction technique is the abduction traction method. The patient is supine with a sandbag between the shoulder blades, with the shoulder near the edge of the table. Traction in abduction is employed to dis-impact the medial end of the clavicle from the manubrium, followed by extension of the abducted shoulder to reduce the SCJ. Groh et al<sup>9</sup> successfully reduced six of eight acute (< 10 days old) dislocations using this method. The other two were reduced operatively by employing a towel clip to reduce the medial end of the clavicle. Most techniques for the treatment of anterior SCJ dislocations can also be used for posterior SCJ dislocations. The number of reported cases of open reduction, tenodesis, suture fixation, and open reduction and internal fixation have been low in the literature, but have had the highest percentage of excellent/good results in adults without associated high-risk complications.<sup>22</sup>

While Leighton et al<sup>59</sup> have had good outcomes in adolescents with closed reduction, excellent outcomes were noted following open reduction +/- stabilization by Waters et al<sup>60</sup> in the same age group. Laffosse et al<sup>30</sup> described their results of 30 posterior sternoclavicular dislocations which included four epiphyseal disruptions. A closed reduction was attempted in 14 cases. It was successful in only five of 10 dislocations and, significantly, failed in all four epiphyseal disruptions. Functional scores were better when an associated stabilization procedure had been performed rather than reduction alone at follow-up at 60 months. Any soft tissue repair must include the costoclavicular ligament as it is one of the main stabilizers of the sternoclavicular joint.<sup>3,60</sup> Balser plates can be used in retrosternal dislocations, positioned retrosternally, but this can lead to damage to the cartilage, articular meniscus



and physis.<sup>42</sup> Brinker et al<sup>61</sup> have used cannulated screws to stabilize the SCJ. Excision of the medial clavicle with or without reconstruction has also been described.<sup>62</sup> More recently, Kirby et al<sup>10</sup> have treated posterior SCJ dislocations with open reduction and internal fixation using transosseous sutures/mersilene tape in a figure of eight configuration in 10 posterior dislocations. All patients had relief of symptoms of mediastinal compromise. Two patients required plate fixation and a second surgery to remove metalwork. Figure of eight reconstruction has also been used by Singer et al,<sup>55</sup> employing hamstring tendons with good results. Other recent methods of stabilization described include LARS ligament reconstruction weave,<sup>49</sup> locking plate osteosynthesis<sup>63</sup> and tension band wiring using K-wires.<sup>43</sup>

In summary, posterior SCJ dislocation can cause significant mediastinal compromise and may have to be reduced. Results are similar with open or closed reduction as the joint is stable post-reduction. Surgical management is indicated in failed closed reduction. Techniques for reduction and stabilization are as per surgeon preference with most methods having good results.

#### *Traumatic SCJ fracture: dislocation in children*

Traumatic anterior fracture dislocation in children is more of a physeal separation than a true dislocation. Although radiographs are helpful, CT/MRI scans help in establishing the diagnosis.<sup>29</sup> Closed reduction can be attempted in most patients.<sup>64</sup> This is, however, likely to dislocate due to instability and frequently needs subsequent surgical management.<sup>60</sup> Asymptomatic subluxations do not require surgical intervention.<sup>64</sup> Surgical stabilization can be performed using vicryl® sling, free tendon graft or a non-absorbable suture material anchored to the first rib.

Approximately 40–50% of all posterior fracture dislocations are physeal separations.<sup>65,66</sup> Although various reduction techniques have been described, the principles include hyperextension of the shoulder of the involved side either on a padded wedge or the surgeon's knee and, if required, additionally disengaging the dislocation either manually or using towel clamps with suitable anaesthesia. Gobet et al<sup>7</sup> successfully reduced two of their three patients with posterior fracture dislocations, while Yang et al<sup>67</sup> were successful with four cases of posterior dislocations. However, Laffosse et al<sup>30</sup> and Waters et al<sup>60</sup> have reported failures with closed reduction in their studies. Physeal injury does not warrant reduction unless it causes symptoms of compression of posterior mediastinal structures. Operative stabilization methods include polyester<sup>60,68</sup> and polydioxanone suture.<sup>30</sup> Postoperative rehabilitation involves maintaining the arm in a sling with early mobilization as permitted. Weight-bearing restrictions are recommended for six weeks and contact sports to commence by three months.

## Non-traumatic disorders of the SCJ

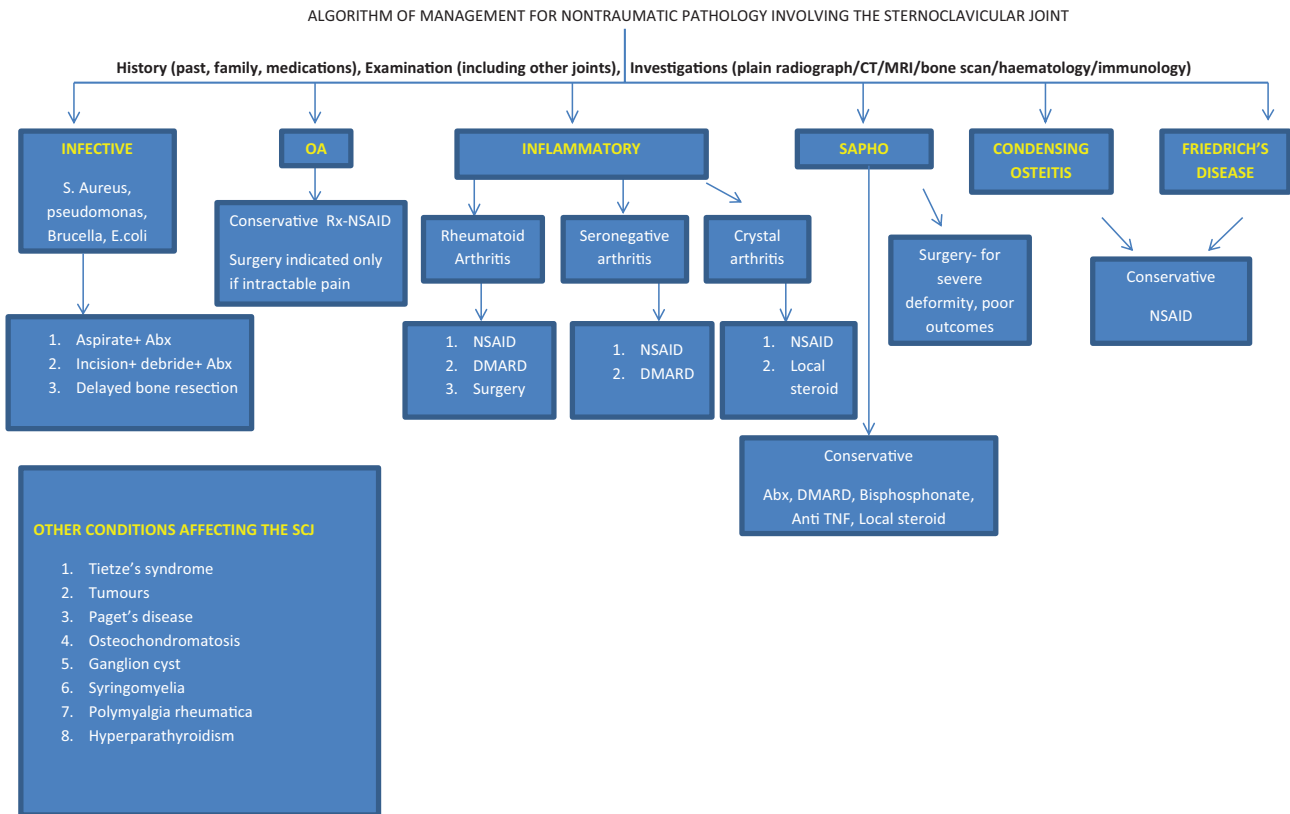
Sternoclavicular joint swellings can be secondary to many non-traumatic pathologies including infective, degenerative, and inflammatory causes. Patients usually present with bony or soft tissue swelling, deformity, localized tenderness and signs of inflammation. Initial screening tests such as for inflammatory markers (white cell count, erythrocyte sedimentation rate (ESR), C-reactive protein (CRP)), rheumatoid factor (RA), antinuclear antibodies (ANA) and tissue antigen tests for human leukocyte antigen (HLA-B27) are useful to diagnose chronic inflammatory conditions and infections.

Conventional radiography may be helpful in detecting degenerative arthritis, hyperostosis and calcification of the surrounding tissues. Radiographs can be difficult to interpret because of variations in anatomy and overlap of the underlying superior mediastinal structures. CT and MRI are more sensitive as well as specific in detecting certain pathologies.<sup>69,70,71</sup> Aspiration of the joint under ultrasonography (USG) or CT guidance can help in isolating organisms and demonstrating crystals.<sup>72–74</sup> We describe management and outcomes of common non-traumatic causes of sternoclavicular swellings and have also included a few rare but important differential diagnoses (Fig. 3).

### *Infective conditions*

#### *Septic arthritis*

Sternoclavicular septic arthritis accounts for 1% of all septic arthritis.<sup>74</sup> There can be serious complications including osteomyelitis, chest wall abscess or phlegmon and mediastinitis.<sup>74–77</sup> In a large review of 180 cases by Ross and Shamsuddin,<sup>74</sup> sepsis is classically associated with subacute presentation with a median duration of symptoms of two weeks. Common clinical features include local pain, chest pain, swelling, tenderness and pyrexia.<sup>74</sup> Most patients are male, with predisposing causes being intravenous drug misuse, infective focus, immunosuppression, diabetes mellitus, osteo or rheumatoid arthritis of the joint, recent sternal trauma, recent central line insertion or other risk factor for bacteraemia.<sup>74,75</sup> Sternoclavicular infections can occur in healthy individuals.<sup>78</sup> The most commonly isolated organism is *Staphylococcus aureus*.<sup>74,79</sup> Other common organisms include *Pseudomonas*, *Brucella* and *E.coli*.<sup>74,80</sup> Patients with risk factors such as intravenous drug abuse historically were infected with *Pseudomonas aeruginosa*,<sup>81</sup> but occurrence of this is now decreasing.<sup>74</sup> *Neisseria gonorrhoeae* and *Candida albicans* might be responsible in HIV-positive patients.<sup>32</sup> Isolated cases of infection with rarer organisms such as *Salmonella*,<sup>82</sup> and *Coxiella burnetii*,<sup>83</sup> have been described. There have been reports of joint enlargement in congenital syphilis and leprosy.<sup>84</sup> Tuberculosis needs to be borne in mind as a differential diagnosis for patients travelling to



**Fig. 3** Management algorithm for management of non-traumatic sternoclavicular swellings.

endemic areas. A high index of suspicion and appropriate culture of aspirate/tissue sample with imaging gives the diagnosis. An appropriate course of anti-tuberculous treatment is curative in most cases.<sup>85–87</sup> In resistant cases immunomodulation may be needed.<sup>85</sup>

CT scan is 83% sensitive and MRI is 100% sensitive for detecting infection.<sup>88,89</sup> CT-guided aspirations are safe and have yielded positive cultures in more than 50% of cases;<sup>72</sup> alternatively, USG-guided aspiration can be carried out.<sup>73</sup> Needle aspiration in the review by Ross and Shamsuddin<sup>74</sup> confirmed positive cultures in 77% of cases. In acute cases, CT scan shows erosions, widening and periosteal reaction, whereas in chronic cases there may be sclerosis. MRI is more specific and should be regarded as the investigation modality of choice. A delay in diagnosis of over two weeks was found by Bodker et al<sup>89</sup> in 10 patients with SCJ sepsis when investigative modalities other than MRI were used. Johnson et al<sup>90</sup> have compared MRI findings of septic and degenerative SCJ distension greater than 10 mm extending over both clavicle and sternum, and bone marrow signal changes are significantly associated with sepsis. Although markers are elevated in healthy patients, they may be normal in debilitated or immunocompromised patients.

Treatment depends on the extent of involvement of bone and soft tissues. Aspiration with antibiotics with or without debridement in early cases can be curative.<sup>74,78,91,92</sup> However, when radiographic evidence of infection beyond the sternoclavicular joint is present, incision and drainage with resection of the medial clavicle or en bloc resection with grafting or interposition arthroplasty may be needed.<sup>73,74,92,93</sup> These may need to be staged procedures after debridement.<sup>91</sup> Total claviclectomy has been described after multiple failed procedures.<sup>94</sup> Given the proximity to vascular structures, the procedures are best carried out in conjunction with thoracic surgeons.<sup>74</sup>

Song et al<sup>73</sup> reported results of simple incision, debridement and antibiotic therapy, which failed in five out of six patients. These patients subsequently underwent a resection of their sternoclavicular joint with soft tissue coverage by advancement flap from the ipsilateral pectoralis major muscle. There were no complications and good function was restored. Nusselt et al<sup>92</sup> concluded that septic arthritis without bony involvement can be treated with simple incision, debridement and drainage with antibiotic therapy. With osseous involvement, resection of the involved bone is needed. They had good results in five cases using

these treatment steps. Carlos et al<sup>75</sup> described eight patients with septic arthritis of the SCJ. Four patients were each treated with an open-joint exploration with drainage and debridement or en bloc resection of the sternoclavicular joint and the ipsilateral pectoralis major muscle flap. There was complete healing with no apparent limitations in the range of motion in all patients, even after en bloc resection. Muesse et al<sup>91</sup> reported their results in 12 cases with osteomyelitis affecting the SCJ. The most successful modality described was debridement with delayed bone resection and muscle flap coverage in five of five cases. Chun et al<sup>77</sup> reviewed results of resection arthroplasty in 10 cases with septic arthritis and osteomyelitis with resolution of infection in all cases. One patient developed systemic sepsis and pneumonia. Surgery was needed in 102 of 174 (58%) patients in the review by Ross and Shamsuddin.<sup>74</sup>

#### *Osteoarthritis*

Moderate to severe degenerative joint changes have been found in asymptomatic individuals (CT scan or post-mortem) in 50–90% of individuals aged over 60 years.<sup>69,84,95</sup> Lawrence et al<sup>95</sup> reviewed CT scans of 137 asymptomatic patients with arthritic changes in 89.6% of patients older than 50 years and in all patients older than 61 years. Symptomatic arthritic involvement of the sternoclavicular joint can be a result of trauma, infection, sternocostoclavicular hyperostosis, post-menopausal arthritis, condensing osteitis of the proximal clavicle, or can be secondary to an underlying arthropathy.<sup>84</sup> Symptoms include pain with movement of the shoulder, particularly high elevation. Arthritic SCJ can be swollen, tender to palpate and limited in movement with possible crepitus on shoulder movement.<sup>96</sup> Radiographic changes are usually bilateral, and often asymmetrical.<sup>69</sup> CT shows signs of osteoarthritis with narrowing of the joint space, subchondral cysts and sclerosis and the formation of osteophytes, which is most prominent on the inferior aspect of the medial clavicle.<sup>70,95</sup> Sclerosis produces a low-signal intensity on all MRI sequences, but subchondral cysts produce foci of hyperintense signal on T2-weighted images.<sup>71</sup> MRI is the preferred diagnostic tool to rule out infection.<sup>89,90</sup>

Non-operative management is the mainstay of treatment<sup>96</sup> and includes rest, modification of activities, analgesia and intra-articular injection of corticosteroids.<sup>70,97</sup> Most cases have transitory symptoms, which resolve within a few months.<sup>96,97</sup> Surgery is only reserved for those with intractable pain. Case series have been published discussing various surgical modalities including excision<sup>62,97,98</sup> with or without reconstruction of the sternoclavicular ligaments with graft material,<sup>46</sup> arthroscopic procedures<sup>99–101</sup> and interpositional arthroplasty.<sup>93</sup> Poor results can be associated with workers' compensation

patients.<sup>93</sup> Resection should leave the CC ligament intact to avoid instability and poor results.<sup>36,37,98</sup>

#### *Inflammatory conditions*

The SCJ can be affected by inflammatory arthritis.<sup>81,102</sup> It usually affects a younger population; however, with the advent of biological treatment, the incidence has significantly reduced.

#### *Rheumatoid arthritis*

Rheumatoid arthritis can affect the sternoclavicular joint like any other joint with formation of pannus, bony erosion and degeneration of the intra-articular disc in one-third of patients with this systemic disease.<sup>81</sup> The radiological changes show bony erosions with destruction of the joint.<sup>103</sup> Rodríguez-Henriquez et al,<sup>104</sup> in their case control study of ultrasound assessment of 406 patients, noted ultrasonographic abnormalities in 89 joints (43%) in the rheumatoid group compared with 36 (17%) in the control group.

Non-steroidal anti-inflammatory drugs, steroids and disease-modifying anti-rheumatic drugs are the first line of management and their use should be supervised by a rheumatologist. Resection of the medial clavicle may be undertaken in the presence of severe symptoms which are refractory to medical treatment.<sup>103</sup>

#### *Seronegative spondyloarthropathies*

The SCJ can be involved in other inflammatory conditions including psoriasis, ankylosing spondylitis, Reiter's syndrome and inflammatory bowel disease.<sup>102,103,105</sup> These conditions are now classified into a common group as spondyloarthritis by the Assessment of SpondyloArthritis International Society (ASAS). Verhoeven et al<sup>106</sup> prospectively assessed 131 cases with spondyloarthritis. They found clinical involvement (SCJ or manubriosternal joint) in 39% and ultrasound involvement in 35% of cases. The involvement of these joints is significantly associated with disease duration, sacroiliitis and presence of inflammatory bowel disease. Psoriatic arthritis has a predilection for the SCJ with clinical involvement in 50% of cases.<sup>102</sup> SCJ involvement can be present in 4% of patients with ankylosing spondylitis.<sup>107</sup> Detection of HLA-B27 is one of the diagnostic criteria for spondyloarthritis. Treatment is primarily conservative with non-steroidal anti-inflammatory drugs and disease-modifying agents under the supervision of a rheumatologist.

#### *Crystal-deposition arthropathy*

In a CT-scan-based study, the relevance of calcium pyrophosphate dihydrate (CPPD) crystal deposition in the SCJ was 17% (36/209), with a significant association between SCJ CPPD and osteoarthritic changes.<sup>108</sup> Presentation can be with acute pain and swelling of joint<sup>109</sup> with or



without systemic symptoms.<sup>110</sup> Alternatively, it can present with swelling, mimicking a tumour.<sup>111</sup> Aspiration of the acutely swollen joint can diagnose gout or pseudo-gout. Both conditions can affect the sternoclavicular joint.<sup>110–112</sup> Treatment consists of conservative measures such as non-steroidal anti-inflammatory agents and local injection of corticosteroids.<sup>109</sup> Long-term medical prophylaxis for gout can be undertaken.<sup>112</sup>

#### *Atypical conditions affecting the SCJ*

##### *SAPHO syndrome*

Synovitis–acne–pustulosis–hyperostosis–osteitis (SAPHO) is an acronym for various osteoarticular and dermatological manifestations that can appear in the same patient. The syndrome has been also known by other names including subacute and chronic symmetric osteomyelitis, non-bacterial osteitis, pustulotic arthro-osteitis, chronic recurrent multifocal osteomyelitis (CRMO), spondyloarthritis hyperostotica pustulo-psoriatica etc.<sup>113</sup> The pathogenesis of SAPHO is likely to be multifactorial and includes a combination of genetic, infectious, and immunological factors.<sup>114</sup> Implicated factors include infection by low-virulence pathogen such as *Propionibacterium acnes*, immunological factors such as polymorphonuclear (PMN), interleukin-8 (IL-8), tumour necrosis factor  $\alpha$  (TNF $\alpha$ ) and genes LPIN2 and NOD2 located on chromosome 18.<sup>113</sup>

Lack of awareness can lead to delayed diagnosis.<sup>115</sup> Symptoms can be unilateral but most patients develop bilateral involvement.<sup>116</sup> The disease predominantly affects middle-aged women.<sup>117,118</sup> The axial skeleton is involved in 91% and the peripheral joints in 36% of cases. Sternocostal and sternoclavicular joints are most commonly affected but it can also affect the sacroiliac or hip joints, knees, and ankles.<sup>113</sup> Dermatoses such as pustular psoriasis, acne conglobata, acne fulminans, hidradenitis suppurativa, and psoriasis vulgaris have been associated with the syndrome<sup>119</sup> and can be difficult to treat.<sup>113</sup> Kahn's revised criteria<sup>120</sup> can be used to aid diagnosis, but the diagnostic criteria have not been validated.<sup>113,121</sup>

Radiographs with the characteristic findings of expanded bone, sclerosis, osteolysis, periosteal reaction and enthesopathic new bone formation are usually seen in adults after three months of disease but MRI might be required in the paediatric age group to avoid radiation and detect sub-clinical lesions.<sup>122</sup> Imaging findings can be difficult to differentiate from infection and neoplasia.<sup>123</sup> Bone scintigraphy is helpful in diagnosing unexpected locations and shows focal hot spots of the spine, sacroiliac joints and/or the appendicular skeleton in many cases. The bull-head-like tracer uptake of the sternocostoclavicular region is very typical of this disease and can avoid unnecessary biopsies.<sup>124</sup> Although bullhead sign is specific to SAPHO, it may not be very sensitive. In the series by Fu et al<sup>125</sup> only 11/48 had a positive bullhead sign but all patients had

anterior chest wall involvement. Spinal involvement can have a typical curvilinear or semi-circular pattern of vertebral involvement, contiguous vertebral body involvement, and absence of intervertebral disc oedema and enhancement.<sup>118</sup> Although inflammatory markers such as erythrocyte sedimentation rate (ESR),  $\alpha$ 2-globulin, and C-reactive protein have been reported to be high,<sup>113,117</sup> they do not relate to the disease activity. Blood tests are neither diagnostic nor prognostic.<sup>113,126</sup> Aspiration and biopsies are only indicated to rule out other differential diagnoses including tumours and infections.<sup>84</sup>

Treatment is usually aimed at symptomatic relief and modifying disease progression under the care of rheumatology and dermatology.<sup>113</sup> There is as yet no standardized treatment algorithm.<sup>117</sup> Antibiotics such as doxycycline, azithromycin, sulfamethoxazole/trimethoprim, and clindamycin have been reported to be successful.<sup>127,128</sup> Bisphosphonates not only inhibit bone resorption and turnover but also have possible anti-inflammatory activity that suppresses the production of IL-1, IL-6, and TNF $\alpha$ , which is proposed to be beneficial.<sup>117,128–130</sup> In resistant cases, anti-TNF $\alpha$  agents, IL-1 inhibition with anakinra and ustekinumab, an antibody against the p40 subunit of IL-12 and IL-23, can be used.<sup>131</sup> Hayem et al have used local corticosteroid injections with some benefit, in their review of 120 cases.<sup>132</sup> Others were unable to show any effect of steroids.<sup>133</sup> Wide resections are reserved for severe deformity or painful loss of function<sup>134</sup> but can have high recurrence rates.<sup>114</sup> SAPHO is a disease of unclear aetiology, with varied presentation, which is difficult to diagnose. Early referral for suspected cases to rheumatology and dermatology for diagnosis and treatment are important to prevent osteoarticular progression of the disease.

##### *Condensing osteitis*

First described by Brower et al,<sup>135</sup> condensing osteitis is sclerosis of the medial end of the clavicle not involving the SCJ. Since then, many case reports have described the condition.<sup>136–138</sup> Clinically it causes local swelling with no inflammatory skin changes and pain on arm abduction.<sup>71</sup> It is almost always unilateral<sup>139</sup> and does not affect other anterior chest wall joints, thus differentiating it from SAPHO. It almost exclusively affects women<sup>137,138,140,141</sup> 20–60 years of age.<sup>140</sup> The sternoclavicular joint is typically never involved. It is also known as aseptic enlarging osteosclerosis of the medial end of the clavicle. It is a disease of unknown aetiology, although trauma, stress<sup>142</sup> and infection have been postulated as possible causes.<sup>143</sup> Condensing osteitis of the clavicle resembles condensing osteitis of the pubis and ilium, but no definite association has been reported.

Laboratory findings are usually normal, but there might be an increase in white blood cell count and ESR.<sup>140</sup>

Characteristic radiographic findings are a homogeneously dense sclerotic patch in the medial end of the clavicle, limited to the inferior margin, sparing of the sternoclavicular joint and absence of periosteal reaction or bony erosion.<sup>136</sup> MRI usually shows a low-signal intensity on T1- and low or intermediate signal on T2-weighted images with occasional interspersed areas of bright signal on T2-weighting and bone and peri-osseous enhancement. It is difficult to differentiate osteitis from a primary or metastatic bone tumour without a biopsy.<sup>141</sup> Biopsy is recommended to rule out other diagnoses<sup>140</sup> unless clinical and radiological assessment is clearly indicative of condensing osteitis.<sup>142</sup>

Treatment is symptomatic with most patients responding to observation and non-steroidal anti-inflammatory drugs.<sup>139,144</sup> Historically, surgical excision was used as a treatment method.<sup>135,140</sup> Most of the pain settles by six months, but the swelling and radiological changes may persist.<sup>145</sup> Condensing osteitis is a relatively benign condition with good outcomes. The importance of the condition lies in identifying it and ruling out other sinister causes of the swelling.

#### *Friedrich's disease*

Spontaneous necrosis of the medial end of the clavicle was first described by Friedrich in 1924. Idiopathic osteonecrosis of the medial end of the clavicle is rare, usually unilateral and presents with normal inflammatory and rheumatological markers. Most of the reports describe a swelling with no or minimal pain overlying the SCJ. CT scans show destruction of compact bone at the medial end of the clavicle and irregularity of the cancellous bone; biopsy again shows non-specific necrosis.<sup>146</sup> MRI may demonstrate areas of necrosis or cystic degeneration. Treatment is symptomatic with restriction of activity and administration of oral non-steroidal anti-inflammatory medication for relief from pain. The symptoms are usually self-limiting and complete resolution with remodelling of the medial clavicle typically occurs over a period of 12 to 18 months.<sup>146</sup> Since this is a self-resolving benign condition, awareness of this disease prevents unnecessary surgery.<sup>146,147</sup>

#### *Other conditions*

Tietze's syndrome can rarely affect the sternoclavicular joint as well. It usually affects the second to fourth costochondral junctions, together with hypertrophy and calcification of the costal cartilages, presenting with unilateral discomfort and swelling over the anterior chest wall. The diagnosis is largely clinically based since laboratory and radiological investigations are usually normal.<sup>148</sup> Isolated reports of tumours such as Ewings sarcoma,<sup>149</sup> lymphoma<sup>150</sup> and metastases to the SCJ have been described.<sup>151</sup> Other rarer conditions include Paget's disease,<sup>152</sup> osteochondromatosis,<sup>153</sup> ganglion cysts<sup>154</sup> and neuropathic

joint due to syringomyelia.<sup>155</sup> SCJ changes have also been described with other systemic pathologies such as polymyalgia rheumatica<sup>2</sup> and hyperparathyroidism.<sup>156</sup>

#### *Arthroscopy of the SCJ*

Arthroscopy of the SCJ has been described as a diagnostic tool as well as an option for definitive treatment especially in the management of chronic non-traumatic conditions. It has been proposed that arthroscopy reduces the damage to the underlying mediastinal structures, instability, and scarring<sup>100,157</sup> when compared to open surgery.

Tavakkolizadeh et al<sup>157</sup> reported that arthroscopy of the SCJ enhances patient outcomes by improving visualization, minimizing surgical trauma, limiting the risk to vital retrosternal structures, avoiding postoperative instability, and hastening recovery times while also improving cosmesis. Tytherleigh-Strong et al<sup>100</sup> describe their first arthroscopic procedures for an inflammatory monoarthropathy of the SCJ with a large effusion, wherein they took an aspirate and synovial biopsy specimen. The therapeutic indications have been extended to treat intra-articular conditions including meniscectomy/discectomy for acute and chronic disk tears, excision of loose bodies, excision of the medial end of the clavicle for degenerative arthritis, and washout plus debridement after infection have been performed. Capsular tissue that is inferior and lateral to the anterior capsular ligament is relatively pathologic and has been described as a preferred location for intra-articular injections and arthroscopic portal placement.<sup>158</sup> Both Tavakkolizadeh et al<sup>157</sup> and Warth et al<sup>101</sup> have reported satisfactory outcomes in their patients following therapeutic SCJ arthroscopy.

The case series of 10 patients with SCJ osteoarthritis treated with arthroscopic medial clavicle excision by Tytherleigh-Strong et al<sup>100</sup> reported no complications and no cases of postoperative instability. Warth et al<sup>101</sup> in their article conclude that arthroscopic SCJ decompression can be a safe and effective treatment method for symptomatic SCJ osteoarthritis when performed by experienced surgeons who are familiar with the unique anatomy of the region and when the surgery is performed at a high-volume SC referral centre with cardiothoracic backup. They recommend that since arthroscopy of the SCJ is an uncommon procedure it should not be performed by inexperienced surgeons.

In conclusion, injuries to the SCJ can result in a spectrum of conditions that range from asymptomatic instability to symptomatic dislocation. While most anterior dislocations can be managed conservatively, posterior dislocations would benefit from surgical intervention. The SCJ, being a synovial joint, could be affected by all the conditions that affect this type of joint, and in addition there are a few uncommon conditions that are

specific to the SCJ. Awareness of these conditions and better understanding of SCJ patho-anatomy by the treating surgeon is essential. Recent advances have been made in arthroscopic management of SCJ pathologies and more evidence is needed to substantiate its widespread use.

#### AUTHOR INFORMATION

<sup>1</sup>Kings College Hospital, London, UK.

<sup>2</sup>Pulvertaft Hand Centre, Royal Derby Hospital, Derby, UK.

<sup>3</sup>Cambridge University Hospitals, UK.

Correspondence should be sent to: J. Edwin, Kings College Hospital, London SE5 9RS, UK.

Email: drjohnedwin73@rediffmail.com

#### ICMJE CONFLICT OF INTEREST STATEMENT

None declared.

#### FUNDING STATEMENT

No benefits in any form have been received or will be received from a commercial party related directly or indirectly to the subject of this article.

#### LICENCE

© 2018 The author(s)

This article is distributed under the terms of the Creative Commons Attribution-Non Commercial 4.0 International (CC BY-NC 4.0) licence (<https://creativecommons.org/licenses/by-nc/4.0/>) which permits non-commercial use, reproduction and distribution of the work without further permission provided the original work is attributed.

#### REFERENCES

- Brossmann J, Stähler A, Preidler KW, Trudell D, Resnick D.** Sternoclavicular joint: MR imaging—atomic correlation. *Radiology* 1996;198:193–198.
- Paice EW, Wright FW, Hill AG.** Sternoclavicular erosions in polymyalgia rheumatica. *Ann Rheum Dis* 1983;42:379–383.
- Spencer EE, et al.** Ligamentous restraints to anterior and posterior translation of the sternoclavicular joint. *J Shoulder Elbow Surg* 2002;11:43–47.
- Bearn JG.** Direct observations on the function of the capsule of the sternoclavicular joint in clavicular support. *J Anat* 1967;101(Pt 1):159–170.
- Marker LB, Klareskov B.** Posterior sternoclavicular dislocation: an American football injury. *Br J Sports Med* 1996;30:71–72.
- Webb PA, Suchey JM.** Epiphyseal union of the anterior iliac crest and medial clavicle in a modern multiracial sample of American males and females. *Am J Phys Anthropol* 1985;68(4):457–466.
- Gobet R, et al.** Medial clavicular epiphysiolysis in children: the so-called sternoclavicular dislocation. *Emerg Radiol* 2004;10:252–255.
- Jougon JB, Lepront DJ, Dromer CE.** Posterior dislocation of the sternoclavicular joint leading to mediastinal compression. *Ann Thorac Surg* 1996;61:711–713.
- Groh GI, Wirth MA, Rockwood CA Jr.** Treatment of traumatic posterior sternoclavicular dislocations. *J Shoulder Elbow Surg* 2011;20:107–113.
- Kirby JC, Edwards E, Kamali Moaveni A.** Management and functional outcomes following sternoclavicular joint dislocation. *Injury* 2015;46:1906–1913.
- Rayan GM.** Compression brachial plexopathy caused by chronic posterior dislocation of the sternoclavicular joint. *J Okla State Med Assoc* 1994;87:7–9.
- Nakayama E, et al.** Tracheal stenosis caused by retrosternal dislocation of the right clavicle. *Ann Thorac Surg* 2007;83:685–687.
- Ferrandez L, et al.** Sternoclavicular dislocation: treatment and complications. *Ital J Orthop Traumatol* 1988;14:349–355.
- Ponce BA, et al.** Sternoclavicular joint surgery: how far does danger lurk below? *J Shoulder Elbow Surg* 2013;22:993–999.
- Rajaratnam S, Kerins M, Apthorp L.** Posterior dislocation of the sternoclavicular joint: a case report and review of the clinical anatomy of the region. *Clin Anat* 2002;15:108–111.
- Yeh GL, Williams GR Jr.** Conservative management of sternoclavicular injuries. *Orthop Clin North Am* 2000;31:189–203.
- Renfree KJ, Wright TW.** Anatomy and biomechanics of the acromioclavicular and sternoclavicular joints. *Clin Sports Med* 2003;22:219–237.
- Boesmueller S, et al.** Incidence, characteristics, and long-term follow-up of sternoclavicular injuries: an epidemiologic analysis of 92 cases. *J Trauma Acute Care Surg* 2016;80:289–295.
- Allman FL Jr.** Fractures and ligamentous injuries of the clavicle and its articulation. *J Bone Joint Surg Am* 1967;49:774–784.
- Bicos J, Nicholson GP.** Treatment and results of sternoclavicular joint injuries. *Clin Sports Med* 2003;22:359–370.
- Wirth MA, Rockwood CA Jr.** Acute and chronic traumatic injuries of the sternoclavicular joint. *J Am Acad Orthop Surg* 1996;4:268–278.
- Van Tongel A, De Wilde L.** Sternoclavicular joint injuries: a literature review. *Muscles Ligaments Tendons J* 2011;1:100–105.
- Mehta JC, Sachdev A, Collins JJ.** Retrosternal dislocation of the clavicle. *Injury* 1973;5:79–83.
- Sewell MD, et al.** Instability of the sternoclavicular joint: current concepts in classification, treatment and outcomes. *Bone Joint J* 2013;95-B:721–731.
- Mirza AH, Alam K, Ali A.** Posterior sternoclavicular dislocation in a rugby player as a cause of silent vascular compromise: a case report. *Br J Sports Med* 2005;39:e28.
- Fery A, Sommelet J.** Sternoclavicular dislocations: observations on the treatment and result of 49 cases. *Int Orthop* 1988;12:187–195.
- Thomas CB Jr, Friedman RJ.** Ipsilateral sternoclavicular dislocation and clavicle fracture. *J Orthop Trauma* 1989;3:355–357.
- Eni-Olotu DO, Hobbs NJ.** Floating clavicle: simultaneous dislocation of both ends of the clavicle. *Injury* 1997;28:319–320.
- Groh GI, Wirth MA.** Management of traumatic sternoclavicular joint injuries. *J Am Acad Orthop Surg* 2011;19:1–7.
- Laffosse JM, et al.** Posterior dislocation of the sternoclavicular joint and epiphyseal disruption of the medial clavicle with posterior displacement in sports participants. *J Bone Joint Surg Br* 2010;92:103–109.
- Salgado RA, Ghysen D.** Post-traumatic posterior sternoclavicular dislocation: case report and review of the literature. *Emerg Radiol* 2002;9:323–325.
- Eskola A.** Sternoclavicular dislocation: a plea for open treatment. *Acta Orthop Scand* 1986;57:227–228.

- 33. Glass ER, et al.** Treatment of sternoclavicular joint dislocations: a systematic review of 251 dislocations in 24 case series. *J Trauma* 2011;70:1294–1298.
- 34. de Jong KP, Sukul DM.** Anterior sternoclavicular dislocation: a long-term follow-up study. *J Orthop Trauma* 1990;4:420–423.
- 35. Morell DJ, Thyagarajan DS.** Sternoclavicular joint dislocation and its management: a review of the literature. *World J Orthop* 2016;7:244–250.
- 36. Rockwood CA Jr, et al.** Resection arthroplasty of the sternoclavicular joint. *J Bone Joint Surg Am* 1997;79:387–393.
- 37. Bisson LJ, Dauphin N, Marzo JM.** A safe zone for resection of the medial end of the clavicle. *J Shoulder Elbow Surg* 2003;12:592–594.
- 38. Katthagen JC, et al.** Biomechanical comparison of surgical techniques for resection arthroplasty of the sternoclavicular joint. *Am J Sports Med* 2016;44:1832–1836.
- 39. Witvoet J, Martinez B.** Treatment of anterior sternoclavicular dislocations: apropos of 18 cases. *Rev Chir Orthop Repar Appar Mot* 1982;68:311–316.
- 40. Lehmann W, et al.** Refixation of sternoclavicular luxation with a suture anchor system. *Unfallchirurg* 2010;113:418–421.
- 41. Abiddin Z, et al.** Suture anchors for treatment of sternoclavicular joint instability. *J Shoulder Elbow Surg* 2006;15:315–318.
- 42. Franck WM, et al.** Balsaer plate stabilization: an alternate therapy for traumatic sternoclavicular instability. *J Shoulder Elbow Surg* 2003;12:276–281.
- 43. Chen QY, et al.** K-wire and tension band wire fixation in treating sternoclavicular joint dislocation. *Chin J Traumatol* 2011;14:53–57.
- 44. Lyons FA, Rockwood C.** Migration of pins used in operations on the shoulder. *J Bone Joint Surg Am* 1990;72:1262–1267.
- 45. Armstrong AL, Dias JJ.** Reconstruction for instability of the sternoclavicular joint using the tendon of the sternocleidomastoid muscle. *J Bone Joint Surg Br* 2008;90:610–613.
- 46. Uri O, et al.** Clinical outcome after reconstruction for sternoclavicular joint instability using a sternocleidomastoid tendon graft. *J Bone Joint Surg Am* 2014;96:417–422.
- 47. Jackson H.** Tenodesis of subclavius in the treatment of recurrent dislocation of the sternoclavicular joint. *J Bone Joint Surg Br* 1951;33B:240–243.
- 48. Bak K, Fogh K.** Reconstruction of the chronic anterior unstable sternoclavicular joint using a tendon autograft: medium-term to long-term follow-up results. *J Shoulder Elbow Surg* 2014;23:245–250.
- 49. Quayle JM, et al.** Artificial ligament reconstruction of sternoclavicular joint instability: report of a novel surgical technique with early results. *Tech Hand Up Extrem Surg* 2014;18:31–35.
- 50. Wallace W, Thyagarajan D.** Open reduction and stabilisation of a locked posterior dislocation of the sterno-clavicular joint with lockdown [abstract]. SICOT Orthopaedic World Congress, 2013.
- 51. Booth CM, Roper BA.** Chronic dislocation of the sternoclavicular joint: an operative repair. *Clin Orthop Relat Res* 1979;140:17–20.
- 52. Lee SU, et al.** Stabilization for chronic sternoclavicular joint instability. *Knee Surg Sports Traumatol Arthrosc* 2010;18:1795–1797.
- 53. Spencer EE Jr, Kuhn JE.** Biomechanical analysis of reconstructions for sternoclavicular joint instability. *J Bone Joint Surg Am* 2004;86-A:98–105.
- 54. Sabatini JB, et al.** Outcomes of augmented allograft figure-of-eight sternoclavicular joint reconstruction. *J Shoulder Elbow Surg* 2015;24:902–907.
- 55. Singer G, et al.** Reconstruction of the sternoclavicular joint in active patients with the figure-of-eight technique using hamstrings. *J Shoulder Elbow Surg* 2013;22:64–69.
- 56. Petri M, et al.** Clinical outcomes after autograft reconstruction for sternoclavicular joint instability. *J Shoulder Elbow Surg* 2015;25:435–441.
- 57. Martetschlager F, Warth RJ, Millett PJ.** Instability and degenerative arthritis of the sternoclavicular joint: a current concepts review. *Am J Sports Med* 2013;42:999–1007.
- 58. di Mento L, et al.** Posterior sternoclavicular joint dislocation with brachiocephalic vein injury: a case report. *Injury* 2015;46(suppl 7):S8–S10.
- 59. Leighton RK, Buhr AJ, Sinclair AM.** Posterior sternoclavicular dislocations. *Can J Surg* 1986;29:104–106.
- 60. Waters PM, Bae DS, Kadiyala RK.** Short-term outcomes after surgical treatment of traumatic posterior sternoclavicular fracture-dislocations in children and adolescents. *J Pediatr Orthop* 2003;23:464–469.
- 61. Brinker MR, et al.** A method for open reduction and internal fixation of the unstable posterior sternoclavicular joint dislocation. *J Orthop Trauma* 1997;11:378–381.
- 62. Acus RW III, Bell RH, Fisher DL.** Proximal clavicle excision: an analysis of results. *J Shoulder Elbow Surg* 1995;4:182–187.
- 63. Shuler FD, Pappas N.** Treatment of posterior sternoclavicular dislocation with locking plate osteosynthesis. *Orthopedics* 2008;31:273.
- 64. Gil-Albarova J, et al.** Management of sternoclavicular dislocation in young children: considerations about diagnosis and treatment of four cases. *Musculoskelet Surg* 2013;97:137–143.
- 65. Tepolt F, et al.** Posterior sternoclavicular joint injuries in the adolescent population: a meta-analysis. *Am J Sports Med* 2014;42:2517–2524.
- 66. Lee JT, et al.** Posterior sternoclavicular joint injuries in skeletally immature patients. *J Pediatr Orthop* 2014;34:369–375.
- 67. Yang J, al-Etani H, Letts M.** Diagnosis and treatment of posterior sternoclavicular joint dislocations in children. *Am J Orthop* 1996;25:565–569.
- 68. Garg S, Alshameeri ZA, Wallace WA.** Posterior sternoclavicular joint dislocation in a child: a case report with review of literature. *J Shoulder Elbow Surg* 2012;21:e11–e16.
- 69. Kier R, et al.** Osteoarthritis of the sternoclavicular joint: radiographic features and pathologic correlation. *Invest Radiol* 1986;21:227–233.
- 70. Thongngarm T, McMurray RW.** Osteoarthritis of the sternoclavicular joint. *J Clin Rheumatol* 2000;6:269–271.
- 71. Harden SP, Argent JD, Blaquiére RM.** Painful sclerosis of the medial end of the clavicle. *Clin Radiol* 2004;59:992–999.
- 72. Taneja AK, et al.** Diagnostic yield of CT-guided sampling in suspected sternoclavicular joint infection. *Skeletal Radiol* 2013;42:479–485.
- 73. Song HK, et al.** Current presentation and optimal surgical management of sternoclavicular joint infections. *Ann Thorac Surg* 2002;73:427–431.
- 74. Ross JJ, Shamsuddin H.** Sternoclavicular septic arthritis: review of 180 cases. *Medicine (Baltimore)* 2004;83:139–148.
- 75. Carlos GN, et al.** Aggressive surgical management of sternoclavicular joint infections. *J Thorac Cardiovasc Surg* 1997;113:242–247.
- 76. Randell PA, Somers L.** Case of the month: “bugs are eating my soul” – sternal abscess, osteomyelitis, and mediastinitis complicating a closed sternal fracture. *Emerg Med J* 2006;23:736–737.
- 77. Chun JM, et al.** Resection arthroplasty for septic arthritis of the sternoclavicular joint. *J Shoulder Elbow Surg* 2012;21:361–366.
- 78. Henriksen J, Tang M, Hjortdal V.** Abscess formation after septic arthritis in the sternoclavicular joint of two healthy men. *Case Rep Surg* 2015. doi:10.1155/2015/292854 [Epub ahead of print].



- 79. Kachala SS, et al.** Surgical management of sternoclavicular joint infections. *Ann Thorac Surg* 2016;101:2155–2160.
- 80. Lee A, Coleman P.** *Escherichia coli*: marauding masquerading microbe. *J Clin Orthop Trauma* 2013;4:194–198.
- 81. Yood RA, Goldenberg DL.** Sternoclavicular joint arthritis. *Arthritis Rheum* 1980;23:232–239.
- 82. Bachmeyer C, et al.** Unusual sites of *Salmonella* osteoarthritis in patients with sickle cell disease: two cases. *Clin Rheumatol* 2007;26:1356–1358.
- 83. Angelakis E, et al.** Sternoclavicular joint infection caused by *Coxiella burnetii*: a case report. *J Med Case Rep* 2016;10:139.
- 84. Robinson CM, et al.** Disorders of the sternoclavicular joint. *J Bone Joint Surg Br* 2008;90:685–696.
- 85. Jain A, et al.** Tuberculosis of the sternoclavicular joint. *J Orthop Surg (Hong Kong)* 2015;23:315–318.
- 86. Chakraborty PP, et al.** Poncet's disease: an unusual presentation of tuberculosis in a diabetic lady. *World J Clin Cases* 2015;3:385–388.
- 87. Bassir RA, et al.** Bifocal musculoskeletal tuberculosis in upper limb: unusual case. *Int J Mycobacteriol* 2014;3(3):217–219.
- 88. Fordham S, Cope S, Sach M.** Optimal management of sternoclavicular septic arthritis. *Eur J Emerg Med* 2009;16:219–220.
- 89. Bodker T, et al.** Diagnostics of septic arthritis in the sternoclavicular region: 10 consecutive patients and literature review. *Acta Radiol* 2013;54:67–74.
- 90. Johnson MC, et al.** The sternoclavicular joint: can imaging differentiate infection from degenerative change? *Skeletal Radiol* 2010;39:551–558.
- 91. Muesse JL, et al.** Treatment of sternoclavicular joint osteomyelitis with debridement and delayed resection with muscle flap coverage improves outcomes. *Surg Res Pract* 2014. doi:10.1155/2014/747315 [Epub ahead of print].
- 92. Nusselt T, et al.** Surgical management of sternoclavicular septic arthritis. *Arch Orthop Trauma Surg* 2011;131:319–323.
- 93. Meis RC, et al.** Operative treatment of the painful sternoclavicular joint: a new technique using interpositional arthroplasty. *J Shoulder Elbow Surg* 2006;15:60–66.
- 94. Oheim R, et al.** Medium-term results after total clavicle resection in cases of osteitis: a consecutive case series of five patients. *Int Orthop* 2012;36:775–781.
- 95. Lawrence CR, et al.** The prevalence of osteoarthritis of the sternoclavicular joint on computed tomography. *J Shoulder Elbow Surg* 2017;26:e18–e22.
- 96. Sternheim A, et al.** Transient sternoclavicular joint arthropathy, a self-limited disease. *J Shoulder Elbow Surg* 2014;23:548–552.
- 97. Arlet J, Ficat P.** Osteo-arthritis of the sterno-clavicular joint. *Ann Rheum Dis* 1958;17:97–100.
- 98. Pingsmann A, Patsalis T, Michiels I.** Resection arthroplasty of the sternoclavicular joint for the treatment of primary degenerative sternoclavicular arthritis. *J Bone Joint Surg Br* 2002;84:513–517.
- 99. Tytherleigh-Strong G, Griffith D.** Arthroscopic excision of the sternoclavicular joint for the treatment of sternoclavicular osteoarthritis. *Arthroscopy* 2013;29:1487–1491.
- 100. Tytherleigh-Strong GM, Getgood AJ, Griffiths DE.** Arthroscopic intra-articular disk excision of the sternoclavicular joint. *Am J Sports Med* 2012;40:1172–1175.
- 101. Warth RJ, et al.** Arthroscopic sternoclavicular joint resection arthroplasty: a technical note and illustrated case report. *Arthrosc Tech* 2014;3:e165–e173.
- 102. Taccari E, et al.** Sternoclavicular joint disease in psoriatic arthritis. *Ann Rheum Dis* 1992;51:372–374.
- 103. Higginbotham TO, Kuhn JE.** Atraumatic disorders of the sternoclavicular joint. *J Am Acad Orthop Surg* 2005;13:138–145.
- 104. Rodriguez-Henriquez P, et al.** Sternoclavicular joint involvement in rheumatoid arthritis: clinical and ultrasound findings of a neglected joint. *Arthritis Care Res (Hoboken)* 2013;65(7):1177–1182.
- 105. Spar I.** Psoriatic arthritis of the sternoclavicular joint. *Conn Med* 1978;42:225.
- 106. Verhoeven F, et al.** Ultrasonographic evaluation of the anterior chest wall in spondyloarthritis: a prospective and controlled study. *J Rheumatol* 2015;42:87–92.
- 107. Emery RJ, Ho EK, Leong JC.** The shoulder girdle in ankylosing spondylitis. *J Bone Joint Surg Am* 1991;73:1526–1531.
- 108. Shirazian H, et al.** Prevalence of sternoclavicular joint calcium pyrophosphate dihydrate crystal deposition on computed tomography. *Clin Imaging* 2014;38:380–383.
- 109. De Marco G, et al.** A rare case of chondrocalcinosis in the left sterno-clavicular joint. *Rheumatology (Oxford)* 2011;50:2317–2318.
- 110. Hanai S, et al.** Pseudogout of the sternoclavicular joints. *Intern Med* 2014;53:521–522.
- 111. Richman KM, et al.** Tophaceous pseudogout of the sternoclavicular joint. *AJR Am J Roentgenol* 1999;172:1587–1589.
- 112. Sant GR, Dias E.** Primary gout affecting the sternoclavicular joint. *BMJ* 1976;1:262.
- 113. Rukavina I.** SAPHO syndrome: a review. *J Child Orthop* 2015;9:19–27.
- 114. Eyrych GK, et al.** Primary chronic osteomyelitis associated with synovitis, acne, pustulosis, hyperostosis and osteitis (SAPHO syndrome). *J Oral Pathol Med* 1999;28:456–464.
- 115. Roed B, et al.** Sternocostoclavicular hyperostosis: an ill-recognized disease. *Diagnostics (Basel)* 2016;6(3).
- 116. Prevo RL, Rasker JJ, Kruijssen MW.** Sternocostoclavicular hyperostosis or pustulotic arthroosteitis. *J Rheumatol* 1989;16:1602–1605.
- 117. Li C, et al.** Synovitis, acne, pustulosis, hyperostosis and osteitis syndrome: a single centre study of a cohort of 164 patients. *Rheumatology (Oxford)* 2016;55:1023–1030.
- 118. McGauvran AM, et al.** SAPHO syndrome: imaging findings of vertebral involvement. *AJNR Am J Neuroradiol* 2016;37:1567–1572.
- 119. Ferguson PJ, Sandu M.** Current understanding of the pathogenesis and management of chronic recurrent multifocal osteomyelitis. *Curr Rheumatol Rep* 2012;14:130–141.
- 120. Hayem G.** SAPHO syndrome. *Rev Prat* 2004;54:1635–1636.
- 121. Zimmermann P, Curtis N.** Synovitis, acne, pustulosis, hyperostosis, and osteitis (SAPHO) syndrome: a challenging diagnosis not to be missed. *J Infect* 2016;72(Suppl):S106–S114.
- 122. Thakur U, et al.** Synovitis, acne, pustulosis, hyperostosis and osteitis (SAPHO) and chronic recurrent multifocal osteomyelitis (CRMO): role of imaging in diagnosis. *Radiography* 2012;18:221–224.
- 123. Depasquale R, et al.** SAPHO: what radiologists should know. *Clin Radiol* 2012;67:195–206.
- 124. Freyschmidt J, Sternberg A.** The bullhead sign: scintigraphic pattern of sternocostoclavicular hyperostosis and pustulotic arthroosteitis. *Eur Radiol* 1998;8:807–812.
- 125. Fu Z, et al.** Is the bullhead sign on bone scintigraphy really common in the patient with SAPHO syndrome? A single-center study of a 16-year experience. *Nucl Med Commun* 2015;37:387–392.



- 126. Nungu S, Olerud C, Rehnberg L.** Sternocostoclavicular hyperostosis: presentation and long-term follow-up of three cases. *Ups J Med Sci* 1992;97:177–182.
- 127. Wagner A, et al.** Long-term antibiotic therapy successful in patients with SAPHO-syndrome [abstract]. *Arthritis Rheum* 1997;40:S62.
- 128. Amital H, et al.** SAPHO syndrome treated with pamidronate: an open-label study of 10 patients. *Rheumatology (Oxford)* 2004;43:658–661.
- 129. Ringe JD, Faber H, Farahmand P.** Rapid pain relief and remission of sternocostoclavicular hyperostosis after intravenous ibandronate therapy. *J Bone Miner Metab* 2006;24:87–93.
- 130. Zwaenepoel T, Vlam K.** SAPHO: treatment options including bisphosphonates. *Semin Arthritis Rheum* 2016;46:168–173.
- 131. Firinu D, et al.** SAPHO syndrome: current developments and approaches to clinical treatment. *Curr Rheumatol Rep* 2016;18:35.
- 132. Hayem G, et al.** SAPHO syndrome: a long-term follow-up study of 120 cases. *Semin Arthritis Rheum* 1999;29:159–171.
- 133. Jung J, et al.** Intra-articular glucocorticosteroid injection into sternocostoclavicular joints in patients with SAPHO syndrome. *Semin Arthritis Rheum* 2012;42:266–270.
- 134. Mochizuki Y, et al.** Chronic mandibular osteomyelitis with suspected underlying synovitis, acne, pustulosis, hyperostosis, and osteitis (SAPHO) syndrome: a case report. *J Inflamm Res* 2012;5:29–35.
- 135. Brower AC, Sweet DE, Keats TE.** Condensing osteitis of the clavicle: a new entity. *Am J Roentgenol Radium Ther Nucl Med* 1974;121:17–21.
- 136. Cone RO, et al.** Condensing osteitis of the clavicle. *AJR Am J Roentgenol* 1983;141:387–388.
- 137. Imran MB, Othman S.** Bilateral condensing osteitis of clavicles: differential diagnosis of an unusual case. *Rheumatol Int* 2012;32:2921–2923.
- 138. Weiner SN, et al.** Condensing osteitis of the clavicle: a case report. *J Bone Joint Surg Am* 1984;66:1484–1486.
- 139. Greenspan A, et al.** Condensing osteitis of the clavicle: a rare but frequently misdiagnosed condition. *AJR Am J Roentgenol* 1991;156:1011–1015.
- 140. Kruger GD, Rock MG, Munro TG.** Condensing osteitis of the clavicle: a review of the literature and report of three cases. *J Bone Joint Surg Am* 1987;69:550–557.
- 141. Rand T, et al.** Condensing osteitis of the clavicle: MRI. *J Comput Assist Tomogr* 1998;22:621–624.
- 142. Petrov D, et al.** Asymptomatic enlargement of the clavicle: a review of underlying aetiologies. *Acta Orthop Belg* 2010;76:715–718.
- 143. Jones MW, et al.** Condensing osteitis of the clavicle: does it exist? *J Bone Joint Surg Br* 1990;72:464–467.
- 144. Wein S, Kessler D, Bos G.** Asymptomatic enlargement of the medial clavicle: report of five cases. *South Med J* 2003;96:310–315.
- 145. Sng KK, et al.** Condensing osteitis of the medial clavicle: an intermediate-term follow-up. *Ann Acad Med Singapore* 2004;33:499–502.
- 146. Levy M, et al.** Friedrich's disease: aseptic necrosis of the sternal end of the clavicle. *J Bone Joint Surg Br* 1981;63B:539–541.
- 147. Macule F, et al.** Aseptic necrosis of the sternal end of the clavicle Friedrich's disease. *Acta Orthop Belg* 1990;56:613–615.
- 148. Aeschlimann A, Kahn MF.** Tietze's syndrome: a critical review. *Clin Exp Rheumatol* 1990;8:407–412.
- 149. Searle AE, et al.** Sternoclavicular joint swellings: diagnosis and management. *Br J Plast Surg* 1991;44:403–405.
- 150. Adunsky A, Yaretsky A, Klajman A.** Malignant lymphoma presenting as sternoclavicular joint arthritis. *Arthritis Rheum* 1980;23:1330–1331.
- 151. Rozboril MB, et al.** Sternoclavicular joint arthritis: an unusual presentation of metastatic carcinoma. *J Rheumatol* 1983;10:499–502.
- 152. Gerscovich EO, Greenspan A, Szabo RM.** Benign clavicular lesions that may mimic malignancy. *Skeletal Radiol* 1991;20:173–180.
- 153. Azouz EM.** Synovial osteochondromatosis of the sternoclavicular joint. *Pediatr Radiol* 2000;30:720.
- 154. Haber LH, et al.** Sternoclavicular joint ganglion cysts in young children. *J Pediatr Orthop* 2002;22:544–547.
- 155. Chidgey LK, Szabo RM, Benson DR.** Neuropathic sternoclavicular joint secondary to syringomyelia. *Case Rep Orthop* 1988;11:1571–1573.
- 156. Teplick JG, Eftekhari F, Haskin ME.** Erosion of the sternal ends of the clavicles: a new sign of primary and secondary hyperparathyroidism. *Radiology* 1974;113:323–326.
- 157. Tavakkolizadeh A, Hales PF, Janes GC.** Arthroscopic excision of sternoclavicular joint. *Knee Surg Sports Traumatol Arthrosc* 2009;17:405–408.
- 158. van Tongel A, et al.** A cadaveric study of the structural anatomy of the sternoclavicular joint. *Clin Anat* 2012;25:903–910.