

# Plastic Surgery after Massive Weight Loss

by Samer W. Cabbabe, MD

**Bariatric surgery and bariatric plastic surgery continue to surge in the United States.**



Samer W. Cabbabe, MD, FACS, MSMA member since 2010, is with Cabbabe Plastic Surgery in St Louis. Contact: [cabbabes@yahoo.com](mailto:cabbabes@yahoo.com)

## Abstract

Bariatric surgery rates have increased in the United States concurrent with the rise in obesity. As a result of the massive weight loss from these surgeries, patients are left with a different set of functional and cosmetic issues related to excess skin. Plastic surgery has evolved to treat these unique issues faced by this patient population and has demonstrated beneficial effects. This article will provide an overview of the options available to massive weight loss patients to treat specifically affected area of the body.

## Introduction

In the United States, obesity (BMI > 30) affects approximately 35% of adults. More than two-thirds of adults are overweight or obese (BMI > 25). Some studies project that three-fourths of the U.S. adults will be overweight or obese by 2020. The annual medical cost of obesity in 2008 in the U.S. was \$147 billion with the annual medical cost for an obese person at \$1,429 more than that of an average weight individual.<sup>1</sup>

## Bariatric Surgery Procedures

As obesity rates have continued to rise in the U.S., bariatric surgery rates have correspondingly increased. According to the American Society for Metabolic and Bariatric Surgery (ASMBS), the number of bariatric surgeries increased to 179,000 in 2013. Of the procedures performed 42.1% were gastric sleeve, 34.2% Roux-en-Y (RNY), 14% gastric bypass, 14% gastric

banding, 6% revision surgery, 2.7% were defined as other, and 1% duodenal switch.<sup>2</sup>

## Bariatric Plastic Surgery

Published articles have indicated a sustained quality-of-life improvement in post - bariatric surgery patients after body contouring surgery.<sup>3</sup> Other articles have determined that patients with body contouring present better long - term weight control after bypass surgery.<sup>4</sup>

Similarly, bariatric plastic surgery procedures including tummy tuck, thighs, breasts, and arm lifts grew at their fastest rate in four years in recent years. In 2014, nearly 45,000 patients opted to have plastic surgery to correct changes resulting from weight loss surgery. According to the American Society of Plastic Surgeons (ASPS), thighs and upper arms lifts had their biggest single-year increase (9%) in five years in 2014. Tummy tucks increased four percent while breast lift procedures posted a ten percent increase, in the same year, making it the largest single-year gain since 2009 when the ASPS began tracking procedures performed on massive weight loss patients.<sup>5</sup>

Massive weight loss (MWL) is defined as 50% or greater loss of a person's excess weight.<sup>6</sup> After rapid MWL, a patient may be left with excess skin and fat and loss of skin elasticity, resulting in stretch marks or striae. These patients are left with significant functional and cosmetic issues related to the excess skin and represent unique problems and challenges to plastic surgeons. Many plastic surgeons and

patients refer to the areas of the body including the face, breasts and buttocks as “deflated.” In the upper torso, this can cause upper and mid-back rolls, breast droopiness or ptosis, and excess skin in the arms. In the lower torso, a pannus or apron may develop in the mid abdomen, lower abdomen and pubic area as well as excess tissue in the flanks. Excess skin develops in the inner thighs as well, creating skin excess both vertically and horizontally as well as cellulite in the hips. Due to the newly formed skin folds, patients may experience intertrigo, pain or irritation. Most of these manifestations are refractory to topical therapy.

### Candidates for Surgery

Body contouring after MWL surgery is a growing field in constant evolution. Conventional procedures are not always able to address these patients needs. MWL patients tend to be higher risk than non-bariatric patients undergoing similar procedures due to the extent of surgery needed and their frequent comorbidities such as hypertension, diabetes, possible malnutrition, hygiene issues, and persistent obesity.

A patient becomes a good candidate for bariatric plastic surgery approximately one year after weight loss surgery when their weight has been stable for at least three to six months. The average range of BMI at time of presentation is approximately 25-35. The best candidates are those with a BMI < 30, have no or few medical conditions, do not smoke and have reasonable expectations. Poor candidates include those with BMI 35 or greater, active smokers, poor overall medical condition, on anticoagulants, and unrealistic expectations.

MWL patients need to understand that body contouring is a process rather than a one-time event. They may require two or even three procedures to address all of their concerns. This is not always physically or economically feasible and some compromise may need to be realized. MWL patients readily accept scars in exchange for improved contour. Proper selection of the correct patient, operative technique, and accurate markings prior to surgery are imperative in ensuring correct placement of scars.

Generally speaking, several insurance plans may conditionally cover few of these procedures. This differs significantly from one plan to another. Conditions that favor coverage include intertrigo or recurrent infections in the skin folds, and problems with maintaining hygiene. Some of the procedures covered include: apronectomy/panniculectomy, tummy tuck, and breast reduction.

### Risks

Risks of bariatric plastic surgery are related to the number of procedures done, operative time, surgeon experience, and co-morbidities. They generally include

hematoma, infection, seromas, wound dehiscence, skin necrosis, deep venous thrombosis (DVT), pulmonary emboli (PE), and death. Generally speaking, there is good data demonstrating elective operative times should be kept to no more than six hours in healthy patients.<sup>7</sup> Longer operative times can lead to increased risk of transfusion, infection, DVT and PE. Prior to surgery, patients are given a dose of an IV antibiotic, prepped with antiseptic, and SCD's are placed on their legs prior to induction. Drains are usually used in any significant skin excision procedure and kept in place one to two weeks minimum. Patients are ambulated immediately post-operatively and most are able to go home immediately after surgery or the next day. DVT prophylaxis is administered for patients kept overnight. Existing scars such as subcostal scars from open cholecystectomy must be considered for operative planning as they pose a threat to tissue viability after undermining. Similarly, midline incisions resist stretching needed when performing abdominoplasty and may result in wound dehiscence.

### Procedures Offered to Weight Loss Patients After Bariatric Surgeries:

#### Liposuction

Liposuction is the manual removal of fat cells using small cannulas. The procedure involves making small stab incisions and introducing lidocaine and/or epinephrine through small cannulas into the area to be treated. The infiltrated epinephrine decreases the blood loss resulting from the procedure while the lidocaine decreases the amount of the general anesthetic needed. Patients with low BMI generally require skin excision alone whereas those with BMI > 30 may benefit from liposuction in combination with skin excision procedures to remove or debulk some areas. Areas that may be treated with liposuction include the neck, arms, thighs, flanks and back. This may be done in combination with skin excision procedures or in staged fashion where liposuction is performed first followed by skin excision months later.

#### Trunk

The abdomen is the area of most frequent consultation. As a result of the weight loss, a pannus or apron often forms. There can be mid - abdominal pannus formation at or above the umbilicus and/or lower abdominal pannus formation at the level of the pubis. Existing lower transverse scars often exacerbate this as they create a “fixed” scar where the lower abdominal tissue then hangs over and covers the pubic area. Special attention needs to be given in the history and physical exam as patients may have scars which can affect the procedure and outcome as described previously. Hernias, if present, need to be addressed and rectus diastasis ( separation

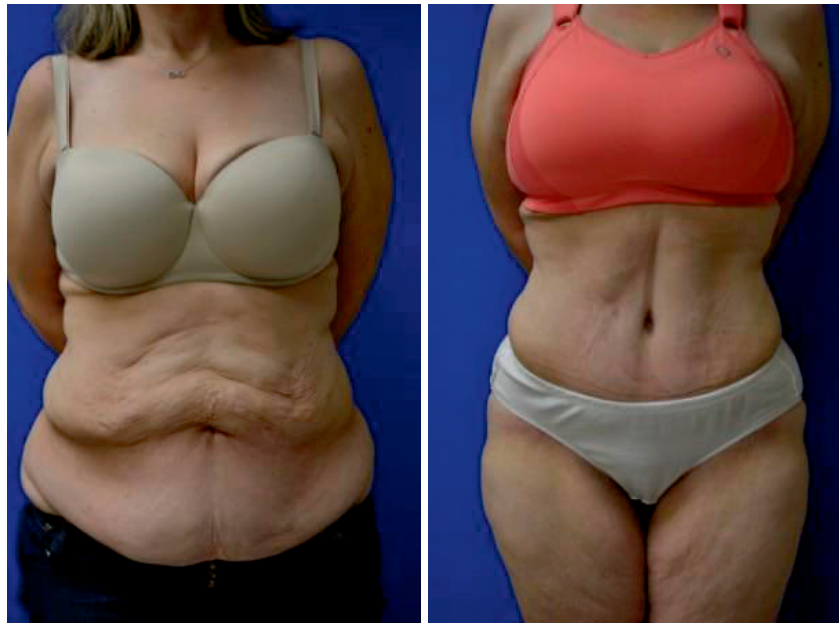of the rectus muscles due to the intra-abdominal pressure exerted from being obese or having had children ) must be corrected.

Two main procedures are used to address the abdomen: apronectomy/ panniculectomy and abdominoplasty. (See Figure 1.)

In a panniculectomy, the patient is placed in a supine position and the lower abdominal pannus is removed without any undermining or separation of the skin and fat from the abdominal wall. The lower incision is placed inside the mons pubis area and the upper incision is placed below the umbilicus. This procedure does not address the upper abdomen or flanks or the rectus diastasis. The umbilicus is left in place or sometimes “floated” where it is undermined or released from the abdominal wall and re-positioned lower than its anatomic position. At least two drains are used and left in place for one to two weeks. Panniculectomy may be the most likely procedure to be covered by some insurance plans.<sup>8</sup>

An abdominoplasty, on the other hand, addresses the entire abdomen. With the patient in the supine position, the lower abdominal tissue is removed. The lower incision is usually placed inside the mons pubis area in order to lift the ptotic mons and the upper incision extends above the umbilicus, depending on the degree of tissue laxity. After circumscribing the skin around the umbilicus to preserve the belly button, the entire abdomen is then undermined up to the level of the costal margin and xiphoid. The rectus muscles are plicated with sutures and the skin is then closed in layers. A new umbilical site is marked and created with a knife and the umbilicus is brought out to the skin and sutured in place. One to two drains are used and kept in place for one to two weeks. Liposuction may be incorporated on the flanks for improved contour.<sup>9</sup>

As the deformities of MWL are circumferential, many MWL patients require circumferential procedures. Patient with excess skin and/or fat in their lower back, lateral thighs and those with ptotic buttocks are candidates. Different approaches are offered based on the location and volume of the excess tissue to be removed. In these patients, the surgeon has to perform an abdominoplasty to treat the anterior trunk, remove posterior skin with or without lifting of the lateral thighs and buttocks. For example, a belt lipectomy results in a scar above the iliac crest and has the effect of “cinching” the torso. A lower body lift results



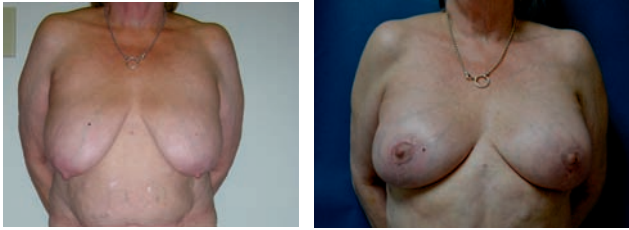**Figure 1**  
Abdominoplasty - Before (left) and after (right) of a patient who had massive weight loss surgery prior.

in a scar below the iliac crest and involves more aggressive undermining of the lateral hips and elevation of the buttocks. Cannulas and special dissectors may be used to undermine the lateral thighs and lift them simultaneously. The buttocks may be auto - augmented as needed with tissue which would normally be discarded from the lower back or by injecting liposuctioned fat.<sup>10</sup> These procedures may be done in one or two stages, depending on the number of other procedures simultaneously performed. If the procedure is done in one surgery, re-positioning of the patient on the operating table is required. This can be done supine - prone or in a lateral decubitus position, depending on surgeon preference and other procedures' positions. Patients stay in the hospital one or two night for this particular surgery.<sup>11</sup>

## Breast

Most MWL patients lose significant volume from the loss of fat in their breasts along with their trunk. Some with residual high BMI may benefit from a breast reduction. Most MWL patients, however, have breast deflation with excess inelastic skin and low nipples resulting in ptosis. These patients require mastopexy or breast lift surgery. In a mastopexy procedure, the nipple areolar complex (NAC) diameter is reduced and transposed to a more anatomic position on the breast. Excess skin is removed vertically and horizontally, extending laterally onto the lateral chest to contour this area.<sup>12</sup>

Some patients opt to increase their breast volume by



**Figure 2**  
Augmentation - Mastopexy: Before (left) and after (right).

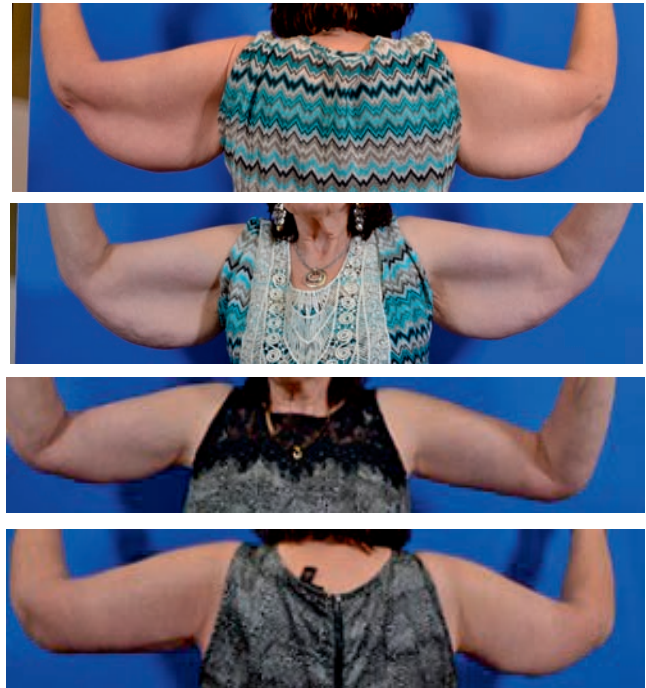
having an implant or by the use of autologous fat which has been suctioned from another area. Techniques of auto-augmentation with derma-glandular flaps, that would normally be resected during mastopexy, have been described with mixed results.<sup>13</sup> An augmentation-mastopexy may be done in one or two stages depending on the size of the implant desired, surgeon experience, patient co-morbidities, and expectations. (See Figure 2.) A small implant may be used in one stage whereas if a larger implant is needed, two stages are preferred since less skin can be removed in order to contour the breast. Moreover, combining mastopexy with augmentation reduces the vascularity of the tissue flap containing the NAC and may lead to delayed healing, implant infection and loss of the NAC. Furthermore, the position of the implant is difficult to control and asymmetries may result as there are several variables being addressed simultaneously. For most patients, two-stage mastopexy-augmentation surgeries are safer and reduce the need for revisions later. Drains are generally not needed in these procedures.<sup>14</sup>

Men with MWL may have deflation of their chest with resultant excess skin and benefit from rejuvenation of the breast. As opposed to a woman, a mastopexy would produce a shaped, projecting breast and be feminizing for a man. Therefore, the goals for a male would be skin removal in a cosmetically sensitive fashion so as not to be embarrassing when in public. This is usually accomplished through an inverted T- scar with transposition of the NAC or an inframammary crease scar with free nipple grafting. The latter procedure involves removal of the NAC then skin grafting the NAC back into an appropriate position on the chest. Liposuction is used as needed for further contouring.

### Brachioplasty

In MWL patients, excess skin and fat present around the arms in between the elbow and the axilla. This is often an area of concern for women due to difficulty finding clothes that fit and inability to “hide” the deformity often likened to wings. Liposuction alone is insufficient treatment but may be used to debulk the arms in select patients in a staged procedure done three to six months apart.

Skin excision for brachioplasty is done on either the



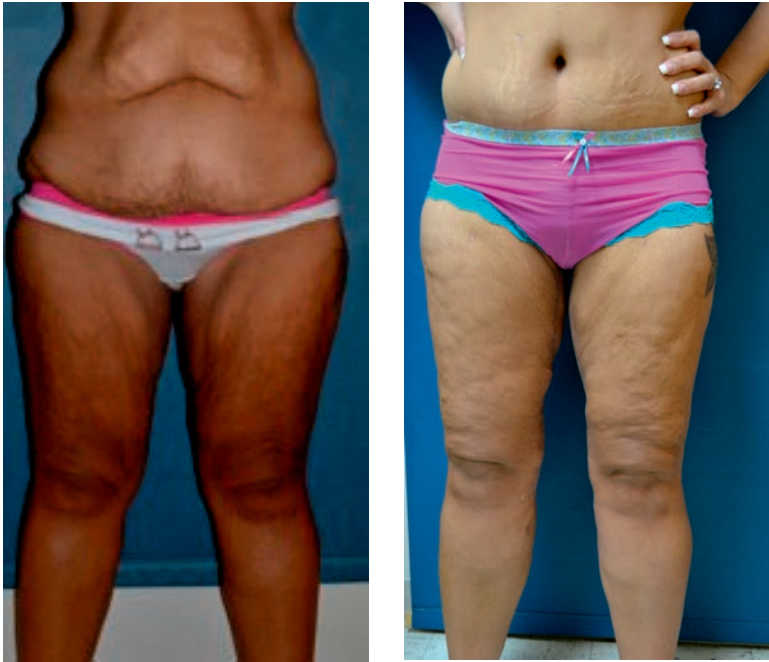**Figure 3**  
Brachioplasty: Before (top) and after (bottom).

posterior or medial brachium with the patient in the supine position and arms flexed at 90 degrees. The skin excess is determined by pinching and placing marks on the arms. Excess fat is accounted for at this point and secondary marks can be made. The skin is removed segmentally to account for discrepancies from the existing marks.<sup>15</sup> Over-aggressive removal of tissue may result in widened or hypertrophic scars which can be uncomfortable and unsightly to patients. Scars that cross the axilla and extend onto the chest wall may incorporate a z-plasty to prevent hypertrophic scarring. Drains are used liberally as well as compressive dressings.<sup>16</sup> (See Figure 3.)

### Thigh Lift

The thighs are arguably the most difficult area to treat in MWL patients. Many women retain adiposity in their thighs despite weight loss. Excess skin in the lateral thigh may be addressed through lower body lifting or belt lipectomy as previously described. Liposuction may be needed to contour the lateral thighs or debulk the thighs in cases of severe lipodystrophy. There is more horizontal excess than vertical excess in these patients even though the opposite is perceived by the patients.<sup>17</sup>

Multiple techniques have been described to treat the thighs and some involve fascial anchoring to prevent labial spreading and scar migration.<sup>18, 19</sup> However, the medial thigh skin excess must be addressed whether it is proximally



**Figure 4**  
Thigh Lift: Before (left) and after (right).

located near the groin or diffusely down the entire thigh. Essentially, a wedge of skin and fat is removed full thickness from the medial thigh. The concept is similar to a brachioplasty. The incision extends proximally in the groin or gluteal crease and distally to the knee as needed to remove dog ears and produce a satisfactory contour. The procedure is done with the patient in lithotomy position and drains are incorporated. In the author's opinion, this procedure carries a higher risk for dehiscence, lymphedema and infection than other body contouring procedures. This is likely secondary to the greater adiposity in this region, the dependent edema that occurs and the mobility of the tissues as an ambulatory structure.<sup>20</sup> (See Figure 4.)

### Face and Neck

The face and neck are the least commonly treated areas for MWL patients. This is due to the severity of skin laxity present in other areas including the abdomen. Face and neck procedures are similar to non-MWL patients with two exceptions: the amount of deflation present from the loss of adipose tissue in the face is often more significant and the eyebrow tends to be more ptotic. The goal of facial rejuvenation in these patients is to remove excess skin and restore structures to their anatomic position and augment the volume of the subcutaneous tissue. This can be done via face, neck and brow lifting supplemented with the use of temporary fillers or permanent fat injections to restore the volume in the cheeks with the latter being the author's preference.<sup>21</sup>

### Conclusion

Bariatric surgery and bariatric plastic surgery continue to surge in the United States. MWL patients are more complex surgical patients than non-MWL patients. They can be successfully treated by plastic surgeons adept in their care who customize staging of the procedures as needed to yield a faster recovery, better results, and lower complications.

### References

1. <http://www.cdc.gov/obesity/adult/defining.html>
2. <http://asmbs.org/resources/estimate-of-bariatric-surgery-numbers>
3. Van der Beek, Eva S. J. M.D.; Geenen, Rinie Ph.D.; de Heer, Francine A. G.; van der Molen, Aebele B. Mink M.D., Ph.D.; van Ramshorst, Bert M.D., Ph.D. Quality of Life Long-Term after Body Contouring Surgery following Bariatric Surgery: Sustained Improvement after 7 Years. *Plastic & Reconstructive Surgery*: November 2012 - Volume 130 - Issue 5 - p 1133–1139
4. Balagué, Nicolas M.D.; Combesure, Christophe M.D.; Huber, Olivier; Pittet-Cuénod, Brigitte M.D.; Modarressi, Ali M.D.; Shermak MA, Chang D, Magnuson TH, Schweitzer MA. Plastic Surgery Improves Long-Term Weight Control after Bariatric Surgery. *Plastic & Reconstructive Surgery*: October 2013 - Volume 132 - Issue 4 - p 826–833
5. <http://www.plasticsurgery.org/news/2015/massive-weight-loss-fuels-surge-in-plastic-surgery.html>
6. An outcomes analysis of patients undergoing body contouring surgery after massive weight loss. *Plast Reconstr Surg*. 2006;118:1026–31.
7. Haeck PC, Swanson JA, Iverson RE, Schechter LS, Singer R, Basu CB, Damitz LA, Glasberg SB, Glassman LS, McGuire MF; ASPS Patient Safety Committee. *Plast Reconstr Surg*. 2009 Oct;124(4 Suppl):6S-27S. doi: 10.1097/PRS.0b013e3181b8e880. Review.
8. Panniculectomy before and after. Note that the umbilicus is left in place and prevents re-draping of the abdominal skin.
9. Abdominoplasty before and after. The entire anterior torso is contoured and excess skin is removed as well as tightening of the rectus muscles
10. Hunstad JP, Repta R. Purse - string gluteoplasty. *Plas Recon Surg* 2009 Mar;123(3):123e-125e.
11. Lower body lift before and after - A considerable amount of skin and fat are removed anterior and posterior with lifting of the buttocks and the lateral thighs
12. Mastopexy before and after - excess skin on the breast is removed and the nipple - areolar complex is repositioned.
13. Rubin JP Mastopexy in the massive weight loss patient: Dermal suspension and total parenchymal reshaping. *Aesthet Surg J*. 2006;26:214–22.
14. Augmentation mastopexy before and after - a silicone implant was used to enhance the volume with a breast lift
15. Aly A, Cram AE, Pace D. Brachioplasty in the patient with massive weight loss. *Aesthet Surg J*. 2006;26:76–84.
16. Brachioplasty before and after - excess skin and fat removed from the posterior arms
17. Prabhat Shrivastava, Aditya Aggarwal, and Rakesh Kumar Khazanchi Body contouring surgery in a massive weight loss patient: An overview. *Plast Surg*. 2008 Oct; 41(Suppl): S114–S129.
18. Lockwood TE. Fascial anchoring technique in medial thigh lifts. *Plast Reconstr Surg*. 1988;82:299–304.
19. Lockwood T. Lower bodylift with superficial fascial system suspension. *Plast Reconstr Surg*. 1993;92:1112–22.
20. Medial thigh lift before and after - excess skin and fat removed from the inner thighs
21. Face lift before and after - brow lift with face and neck lift, repositioning of the cheeks, tightening of the neck and removal of excess skin in the eyelids, face and neck

### Disclosure

None reported.

MM