

# The influence of His bundle pacing on tricuspid valve functioning using three-dimensional echocardiography



Eriko Hasumi, MD, PhD,<sup>\*†</sup> Katsuhito Fujiu, MD, PhD,<sup>\*†‡</sup> Takayuki Kawata, MD, PhD,<sup>\*</sup> Issei Komuro, MD, PhD<sup>\*</sup>

From the <sup>\*</sup>Department of Cardiovascular Medicine, Graduate School of Medicine, The University of Tokyo, Tokyo, Japan, <sup>†</sup>Department of Ubiquitous Health Informatics, Graduate School of Medicine, The University of Tokyo, Tokyo, Japan, and <sup>‡</sup>Department of Advanced Cardiology, Graduate School of Medicine, The University of Tokyo, Tokyo, Japan.

## Introduction

The His bundle (HB) is located in the right atrium and right ventricle under the membranous ventricular septum. Recently, His bundle pacing (HBP) has re-emerged as an alternative to ventricular pacing strategy; it has been shown to successfully narrow the surface QRS complex and improve left ventricular dyssynchrony. However, ventricular lead-induced tricuspid regurgitation (TR) can occur as a complication of HBP and is associated with a poor prognosis.

In most patients, the HBP lead is positioned on the atrial side of the HB; in others, it is positioned in the tricuspid valve (TV) or on the ventricular side of the HB. An association was established between the HBP lead position and lead-induced TR using three-dimensional (3D) echocardiography in our research. In a previous study, long-term follow-up echocardiography during the 1 to 1.5 years after device implantation showed that 38% of the patients developed right ventricular lead-induced TR, defined as an increase to grade 2 or 3 TR.<sup>1</sup> However, TR induced by the HBP remains poorly understood. Therefore, in the present study, we determined the association between the HBP lead position and lead-induced TR using 3D echocardiography.

## Case report

We successfully implanted permanent HBP (dual-chamber pacemakers) in 45 patients according to the guidelines. In most of these patients, the tip positions of the HBP leads

**KEYWORDS** His bundle; His bundle pacing; Lead-induced tricuspid regurgitation; Three-dimensional echocardiography; Tricuspid valve commissure (Heart Rhythm Case Reports 2018;4:437–438)

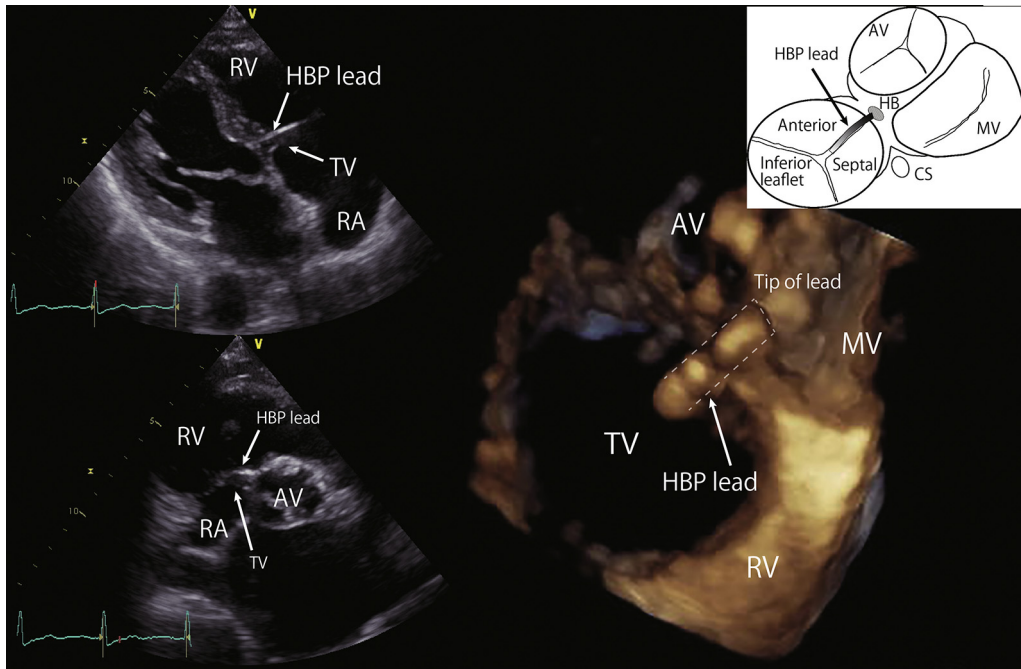
**Address reprint requests and correspondence:** Dr Eriko Hasumi or Dr Katsuhito Fujiu, Department of Cardiovascular Medicine, The University of Tokyo, 7-3-1 Hongo, Bunkyo, Tokyo, Japan 113-8655. E-mail address: [ehasumi-circ@umin.ac.jp](mailto:ehasumi-circ@umin.ac.jp); [fujiu-tyk@umin.ac.jp](mailto:fujiu-tyk@umin.ac.jp).

## KEY TEACHING POINTS

- In most patients, the His bundle pacing (HBP) lead is positioned on the atrial side of the His bundle; in others, it is positioned in the tricuspid valve or on the ventricular side of the His bundle.
- Echocardiography showed no worsening of tricuspid regurgitation severity in any patient with a permanent HBP, even in those whose leads were located on or under the tricuspid valve.
- The HBP lead tip can be positioned in a commissural position in the right ventricle without impinging on leaflet mobility.

were located. However, we were able to visualize the device lead crossing the TV using 3D echocardiography in 6 patients. In 5 of these patients, we observed that the tips were positioned under the TV, where the branching portion of the HB is suggested. In 1 patient, the tip of the lead was located on the TV, where the penetrating portion of the HB is suggested. The penetrating portion of the HB is located near the tricuspid septal leaflet, whereas the branching portion of the HB is located on the posterior sites of the muscular interventricular septum just inferior to the tricuspid septal leaflet. In all 5 patients in whom the tip of the HBP lead was located under the TV, the 3D echocardiogram revealed that the tip of the HBP lead was located in the ventricle via the commissure of the anterior and septal leaflets without impinging leaflet mobility (Figure 1 and Supplemental Video 1).

During long-term follow-up (mean duration of 12.5 months), 3D echocardiography showed no deterioration in TR in any patient, even the 6 patients whose leads were



**Figure 1** Three-dimensional echocardiographic image of the His bundle pacing lead, seen from the right ventricular apex. The tip of the lead (*white arrow*) was positioned under the tricuspid valve through the anteroseptal commissure. AV = aortic valve; CS = coronary sinus; HBP = His bundle pacing; MV = mitral valve; RA = right atrium; RV = right ventricle; TV = tricuspid valve.

positioned on or under the TV. Three patients had trace-to-mild (grade 0–1) and 2 patients had moderate-to-severe (grade 2–3) TR. Moderate-to-severe TR in these 2 patients improved to mild after pacemaker implantation. Before and after pacemaker implantation, pulmonary artery pressure was calculated for each patient from the peak TR jet velocity; this showed no significant change (before,  $32 \pm 2.5$  mm Hg; after,  $30 \pm 2.4$  mm Hg;  $P = .53$ ). No rise in pacing threshold or lead dislodgment was seen during long-term follow-up.

## Discussion

Previous studies have demonstrated that positioning of the HBP in the commissural position is associated with a less severe TR.<sup>2</sup> In the present study, we assessed the relationship between the HBP lead position and TV functioning using 3D echocardiography. We found that the tip of the HBP lead could be positioned in a commissural position in the right ventricle without impinging on leaflet mobility. These results confirmed that the HBP lead position does not affect

TV function, even if the lead is implanted on the ventricular side of the HB. It is thought that HBP can be applied without negatively affecting long-term prognosis, when compared with the use of right ventricular apical or septal pacing.

## Appendix Supplementary data

Supplementary data associated with this article can be found in the online version at <https://doi.org/10.1016/j.hrcr.2018.06.003>.

## References

1. Höke U, Auger D, Thijssen J, Wolterbeek R, van der Velde ET, Holman ER, Schalij MJ, Bax JJ, Delgado V, Marsan NA. Significant lead-induced tricuspid regurgitation is associated with poor prognosis at long-term follow-up. *Heart* 2014;100:960–968.
2. Mediratta A, Addetia K, Yamat M, Moss JD, Nayak HM, Burke MC, Weinert L, Maffessanti F, Jeevanandam V, Mor-Avi V, Lang RM. 3D echocardiographic location of implantable device leads and mechanism of associated tricuspid regurgitation. *JACC Cardiovasc Imaging* 2014;7:337–347.