



## Diagnosis and management of postpartum ovarian vein thrombosis

Bethany T. Samuelson Bannow<sup>1</sup> and Leslie Skeith<sup>2,3</sup>

<sup>1</sup>Division of Hematology, Department of Medicine, University of Washington, Seattle, WA; <sup>2</sup>Division of Hematology, Department of Medicine, University of Ottawa, Ottawa, Ontario, Canada; and <sup>3</sup>Clinical Epidemiology Program, Ottawa Hospital Research Institute, Ottawa, Ontario, Canada

**Case presentation: A 26-year-old woman experienced persistent fever (39.5°C), chills, and right-lower-quadrant tenderness 3 days after caesarean delivery. A computed tomography (CT) scan of the abdomen and pelvis with contrast revealed enlargement of her right ovarian vein with an associated intraluminal filling defect. What is the best treatment of this patient?**

### Learning Objectives

- Identify appropriate imaging investigations for suspected ovarian vein thrombosis in pregnancy or the postpartum period
- Manage a patient with symptomatic postpartum ovarian vein thrombosis

### Discussion

Ovarian vein thrombosis (OVT), a known complication during pregnancy and postpartum, often presents as fever and lower abdominal pain within weeks after delivery.<sup>1</sup> Symptomatic postpartum OVT complicates 0.01% to 0.05% of deliveries,<sup>2,3</sup> more often after cesarean delivery. Complications of symptomatic OVT include sepsis and thrombus extension (25% to 30%) to the inferior vena cava or left renal vein or rarely pulmonary embolism.<sup>2,3</sup> Asymptomatic OVT is more common and may be benign, with a 30% incidence of pelvic (iliac and ovarian) vein thrombosis reported on screening magnetic resonance imaging (MRI) after vaginal delivery<sup>4</sup> and 80% detected in a nonpregnancy population after major gynecological surgery.<sup>5</sup> In a study of 15 patients after cesarean delivery with additional risk factors, 46% had asymptomatic pelvic vein thrombosis, primarily involving the iliac veins,<sup>6</sup> with no evidence of symptomatic venous thromboembolism (VTE) progression or recurrence after clinical follow-up at 1 week or repeat MRI imaging after 6 weeks (Marc Rodger, personal communication, June 26, 2017). These data are based on screening MRI studies of asymptomatic patients who were at varying thrombotic risk, so is not directly comparable to a patient with symptomatic postpartum OVT. Given the variation in diagnostic imaging techniques and treatment of OVT, we sought to review the evidence for diagnosis and management of OVT during pregnancy or the postpartum period.

We conducted a systematic search of MEDLINE, EMBASE, and the Cochrane Database, from the earliest available date to 11 May 2017. Our systematic search included MeSH and keywords “pregnancy,”

“postpartum period,” “ovary,” “venous thrombosis,” and “thrombophlebitis” and yielded 850 abstracts. References of included studies and narrative reviews were screened. There were 559 articles excluded after 280 duplicates were removed: 401 were not studies of patients with postpartum OVT, 116 were case reports only, 22 included <5 patients with postpartum OVT, 18 were reviews, one was not English language, and one did not report outcomes (Figure 1). Nineteen papers underwent full text review and data extraction by 2 independent reviewers, and 11 studies were included: 1 randomized, controlled trial,<sup>7</sup> 4 retrospective case series,<sup>8-11</sup> 4 prospective cohort studies,<sup>1,3,10,12</sup> and 2 retrospective cohort studies.<sup>2,13</sup>

### Diagnostic imaging techniques

Four studies (119 patients) reported on different imaging techniques used to diagnose OVT including ultrasonography (4 studies), CT scan (3 studies), and MRI (3 studies) (Table 1). Two prospective studies compared all 3 imaging techniques, basing the diagnosis of OVT on panel consensus after independent, blinded review by 2 radiologists,<sup>14</sup> or at least 2 of 3 positive test results after 1 blinded and 1 unblinded review.<sup>12</sup> Symptoms that prompted imaging included persistent fever, lower abdominal pain, palpable pelvic mass, sepsis, nausea, vomiting, or constipation/ileus.

Characteristic imaging findings on simple ultrasonography include tubular, hypochoic adnexal, and/or iliac fossa masses.<sup>9,10</sup> Doppler improves the sensitivity of simple ultrasonography by allowing the examiner to clearly identify permeable ovarian veins, and it allowed for the documentation of resolution, if required.<sup>9,10</sup> Limitations of Doppler ultrasonography include body habitus and abdominal gaseous distension.<sup>9</sup> Findings on CT scans include enlargement of the vein with a low-density lumen within the contrast-enhanced vessel wall.<sup>15</sup> This imaging strategy has high sensitivity/specificity (63% to 100% and 78% to 90%, respectively) but requires exposure to pelvic radiation and IV contrast, an important consideration during pregnancy or postpartum.<sup>14</sup> MRI offered improved sensitivity and specificity (92% to 100% and 100%, respectively), allowing for visualization of the entire course of the ovarian veins in patients with

Conflict-of-interest disclosure: B.T.S.B. declares no competing financial interests. L.S. has received research funding from CSL Behring and has received honoraria from Leo Pharma.

Off-label drug use: None disclosed.

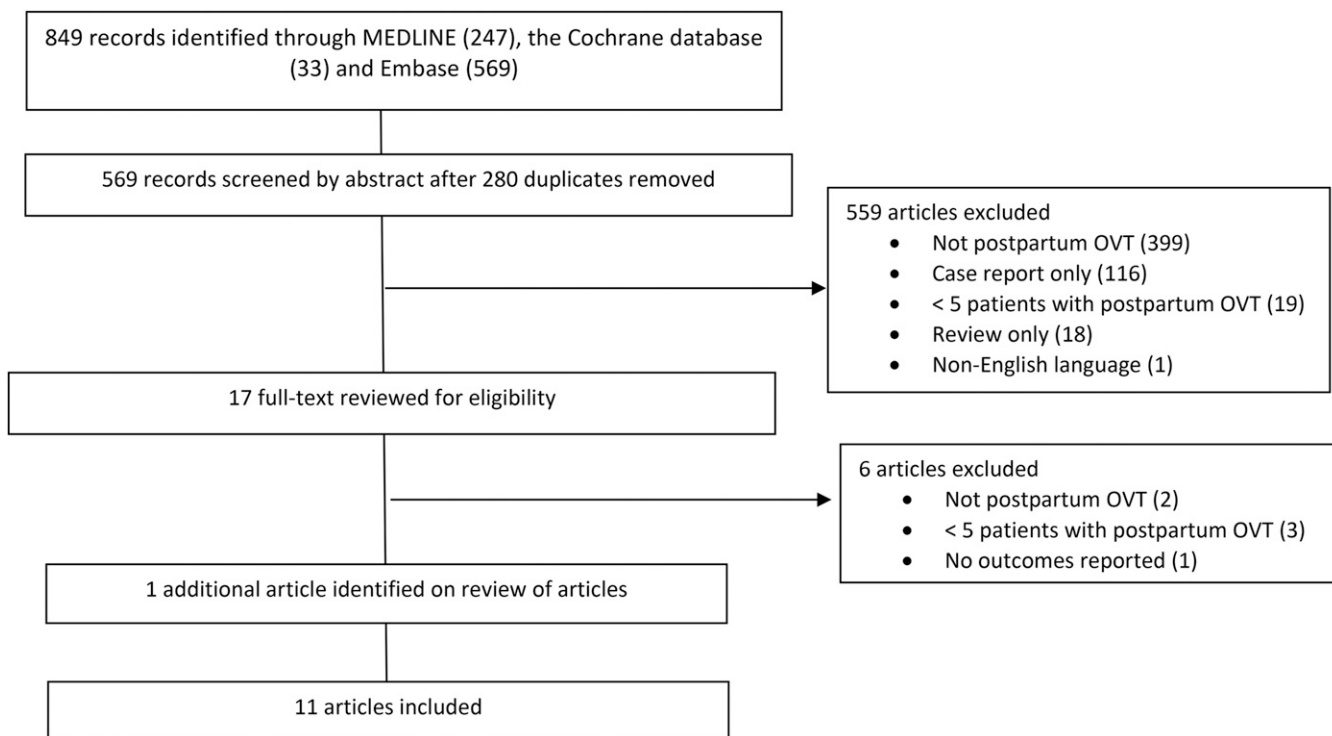


Figure 1. Study flow diagram.

an inconclusive CT scan or ultrasonography. Limitations of MRI include access, increased time requirement, cost, and inferior imaging of bowel-containing areas of the abdomen and pelvis.<sup>14</sup> In summary, based on the information available, there is no clear gold standard for the diagnosis of OVT.

#### Management of OVT

Eight studies reported different management strategies and outcomes for patients with confirmed OVT during pregnancy or postpartum (Table 2). Of 143 patients, 3 cases (2.1%)<sup>2</sup> of OVT were diagnosed antepartum, with the majority of cases in the postpartum period.

Table 1. Findings of 5 studies of various imaging techniques for symptomatic postpartum OVT

Reference	Study design	N	Clinical presentation (n)	Imaging modality (n)	Test characteristics
10	Retrospective case series	7	Postpartum flank pain (4), fever (3), dyspnea (1), leukocytosis (1)	Ultrasonography with Doppler (7) CT with contrast (3)	Sensitivity: 100% (7/7) Sensitivity: 100% (3/3)
14	Prospective cohort study	26 (9 confirmed cases)	Postpartum fever unresponsive to $\geq 48$ h of antibiotics	Doppler ultrasonography (26) CT with contrast (25) MRI/MRA method (24)	Sensitivity: 55.6% Specificity: 41.2% Sensitivity: 77.8% Specificity: 62.5% Sensitivity: 100% Specificity: 100%
12	Prospective cohort study	76 (12 confirmed cases)	Postpartum fever for $\geq 5$ d unresponsive to antibiotics	Ultrasonography CT with contrast MRI	Sensitivity: 50% (95% CI, 22-78%) Specificity: 99% (95% CI, 95-100%) NPV: 95% (95% CI, 89-98%) PPV: 85% (95% CI, 42-49) Sensitivity: 100% (95% CI, 70-100%) Specificity: 99% (95% CI, 95-100%) NPV: 100% (95% CI, 96-100%) PPV: 92% (95% CI, 62-100%) Sensitivity: 92% (95% CI, 60-100%) Specificity: 100% (95% CI, 96-100%) NPV: 99% (95% CI, 95-100%) PPV: 100% (95% CI, 68-100%)
9	Retrospective case series	10	Postpartum fever/septic shock (9) and abdominal pain (9)	Doppler ultrasonography (10)	Sensitivity: 80% (8/10: 1 false negative confirmed on laparotomy; 1 inconclusive confirmed on CT scan)

MRA: magnetic resonance angiography; NPV, negative predictive value; PPV, positive predictive value.

**Table 2. Findings of 7 studies evaluating management strategies of postpartum OVT**

Reference	Study design	N	Treatment (n)	Anticoagulant duration	Resolution of fever, n/N (%)	Recurrent VTE, n/N (%)	Bleeding, n/N (%)
2	Retrospective cohort study	60	Anticoagulation alone (24) Antibiotics and anticoagulation (36)	Median, 3 mo (3-6 mo)	NR NR	0/24 (0) 0/36 (0)	NR NR
3	Prospective cohort study	13	LMWH*	3 mo	NR	0/13 (0)	NR
7	Randomized controlled trial	14	Antibiotics alone (8) Antibiotics and heparin (6)	— 0-6 d	8/8 (100) (140 ± 39 h) 5/5 (100) (134 ± 65 h)	0/8 (0) 0/5 (0)	NR NR
1	Retrospective cohort study	22	Heparin/VKA (22)†	1-60 mo	0/18 (0)‡	0/22 (0)	NR
9	Retrospective case series	10	Antibiotics and anticoagulation (36) Operative intervention (adnexal excision) (1)	10-60 d —	9/10 (90) 1/1 (100)	0/36 (0) 0/1 (0)	NR NR
13	Retrospective cohort study	11	Initial antibiotics alone (11) Heparin/VKA (11)	— 7 d to 3 mo	0/11 (0) 11/11 (100)	1/11 (9)‡ 1/11 (9)‡, extension of OVT	0/11 (0) 1/11 (9)‡
8	Retrospective case series	6	Initial antibiotics alone (5) Antibiotics and heparin (4) Operative intervention (vein ligation and/or oophorectomy/hysterectomy) (3)	— NR —	0/5 (0) 2/4 (50) 2/3 (67)	1/6 (16.6)§ 0/6 (0) 1/6 (16.6), PE-related death intraoperatively§	NR NR NR
11	Retrospective case series	6	Initial antibiotics alone (4) Antibiotics and heparin/VKA (4)¶ Operative intervention (vein ligation/resection and/or hysterectomy) (6)	— NR —	0/4 (0) 3/4 (75) 4/6 (67)	0/6 (0) 0/6 (0) 1/6 (16.6), possible PE postoperatively	NR NR NR

VTE includes recurrent ovarian vein thrombosis, deep vein thrombosis or pulmonary embolism.

LMWH, low-molecular-weight heparin; NR: not reported; PE: pulmonary embolism; VKA: vitamin K antagonist.

\*The LMWH regimen consisted of enoxaparin 1 mg/kg subcutaneously twice daily for 2 weeks, followed by 1 mg subcutaneously daily for 3 mo.

†Concomitant antibiotic use was not reported, but it was likely given in a subset of cases where fever was present.

‡Extension of left OVT and new right OVT despite treatment with 8 d of antibiotics and 6 d of heparin. The bleed reported was a subcutaneous hemorrhage in a different patient.

§In combination with antibiotics alone (2 cases) or antibiotics and heparin (1 case). A patient with PE had initial antibiotics alone followed by surgery.

¶Received antibiotics and anticoagulation postoperatively after diagnostic and treatment laparotomy. One patient was treated with dicumaryl postoperatively without heparin therapy.

Follow-up duration ranged from hospitalization (duration not specified) to a median of 40 months.<sup>2</sup> Interventions included antibiotics and/or anticoagulants, with older studies reporting operative interventions (ligation of ovarian veins or the inferior vena cava and/or hysterectomy)<sup>8,11</sup> often after failure of antibiotics. Earlier studies primarily included patients with refractory fever,<sup>8,11</sup> whereas more recent studies also included patients with OVT and no fever, where antibiotics were not given unless signs of infection were present.<sup>1,3</sup> Studies including antibiotic/anticoagulant therapy were limited by the fact that OVT was considered only among patients not responding to antibiotics.<sup>8,11</sup> In a small randomized trial (14 patients), there was no difference in fever resolution between women with septic thrombophlebitis who received antibiotics and women who received antibiotic/anticoagulant therapy after 5 days of fever refractory to antibiotics.<sup>7</sup> In more recent studies all women received anticoagulant therapy (with or without antibiotics) at the time of diagnosis with good outcomes reported; however, there was not a “no-treatment” arm available for comparison. Information on the duration of anticoagulation was limited, but outcomes (largely resolution of fever and symptoms) were similar among those treated with extended anticoagulation (>3 months) and those treated for shorter periods. Bleeding outcomes were rarely reported. One death (0.78%) was reported and was in the intraoperative setting.<sup>8</sup> There were 2 women with asymptomatic OVT diagnosed in the postpartum period after trauma, both successfully treated with anticoagulation.<sup>2</sup>

The duration of anticoagulation was not specifically addressed in several articles, and the reported duration ranged from 11 days to

60 months. Two of the largest cohorts of patients received a median duration of 3 months of anticoagulation.<sup>2,3</sup> In the absence of high-quality data, a treatment duration of 3 months can be extrapolated from other types of VTE, particularly if there are provoking risk factors, such as the postpartum period. Additional studies evaluating the duration of anticoagulation in this specific population are still needed.

Limitations to our review include the inclusion of retrospective studies with variable follow-up and outcome reporting, selection bias with inclusion of a refractory fever, a small number of patients who did not receive anticoagulation therapy, and changes in peripartum care over time. Additionally, we were unable to include screening studies of asymptomatic pelvic vein thrombosis because of lack of outcome (VTE recurrence) data for OVT, although in all cases no treatment was given. A recent retrospective cohort of 50 patients found no new or progressive symptomatic VTE among patients with OVT who were not treated with anticoagulants or antibiotics (24%); however, the treatment and outcomes for the postpartum patient subgroup were not reported.

In summary, although conclusive recommendations cannot be made based on the small number of studies, lack of comparator arms, and standardization of outcomes, we offer the following suggestions. Pelvic MRI has the highest sensitivity and specificity for suspected postpartum OVT when compared with CT or ultrasonography with Doppler, but CT or ultrasonography may be more practical to use in many cases. Based on the current evidence and extrapolation from principles of treatment of other forms of VTE, anticoagulant therapy is indicated for patients with symptomatic postpartum OVT, and

antibiotics should be used adjunctively when infection is suspected. Asymptomatic postpartum OVT is common in the general obstetrical population, and treatment may not be needed.

### Recommendations

1. The choice of the initial imaging technique for suspected OVT may vary based on test availability and patient characteristics. Pelvic MRI appears to have the highest sensitivity and specificity for diagnosis of OVT (Grading of Recommendations Assessment, Development, and Evaluation [grade] 2C).
2. If ultrasonography is used to diagnose OVT, we suggest the addition of Doppler imaging to improve test accuracy (grade 2C).
3. For symptomatic postpartum OVT we suggest a short duration (3 months) of anticoagulation, with the addition of antibiotics in the cases of suspected infection (grade 2C). We suggest against use of an extended duration (>3 months) of anticoagulation (grade 2C) and emphasize the need for additional studies to determine the most appropriate duration of treatment.
4. For asymptomatic postpartum OVT, we suggest against the use of anticoagulation unless there is evidence of thrombus extension or pulmonary embolism (grade 2C).

### Correspondence

Bethany Samuelson Bannow, 1100 Fairview Ave N, D5-100, Seattle, WA 98109; e-mail: bts99@uw.edu.

### References

1. Salomon O, Apter S, Shaham D, et al. Risk factors associated with postpartum ovarian vein thrombosis. *Thromb Haemost.* 1999;82(3):1015-1019.
2. Rottenstreich A, Da'as N, Kleinstern G, Spectre G, Amsalem H, Kalish Y. Pregnancy and non-pregnancy related ovarian vein thrombosis: Clinical course and outcome. *Thromb Res.* 2016;146:84-88.
3. Salomon O, Dulitzky M, Apter S. New observations in postpartum ovarian vein thrombosis: experience of single center. *Blood Coagul Fibrinolysis.* 2010;21(1):16-19.

4. Khalil H, Avruch L, Olivier A, Walker M, Rodger M. The natural history of pelvic vein thrombosis on magnetic resonance venography after vaginal delivery. *Am J Obstet Gynecol.* 2012;206(4):356.e1-356.e4.
5. Yassa NA, Ryst E. Ovarian vein thrombosis: a common incidental finding in patients who have undergone total abdominal hysterectomy and bilateral salpingo-oophorectomy with retroperitoneal lymph node dissection. *AJR Am J Roentgenol.* 1999;172(1):45-47.
6. Rodger MA, Avruch LI, Howley HE, Olivier A, Walker MC. Pelvic magnetic resonance venography reveals high rate of pelvic vein thrombosis after cesarean section. *Am J Obstet Gynecol.* 2006;194(2):436-437.
7. Brown CE, Stettler RW, Twickler D, Cunningham FG. Puerperal septic pelvic thrombophlebitis: incidence and response to heparin therapy. *Am J Obstet Gynecol.* 1999;181(1):143-148.
8. Allan TR, Miller GC, Wabrek AJ, Burchell RC. Postpartum and post-abort ovarian vein thrombophlebitis. *Obstet Gynecol.* 1976;47(5):525-528.
9. Giraud JR, Poulain P, Renaud-Giono A, et al. Diagnosis of post-partum ovarian vein thrombophlebitis by color Doppler ultrasonography: about 10 cases. *Acta Obstet Gynecol Scand.* 1997;76(8):773-778.
10. Hadas-Halpern I, Patlas M, Fisher D. Postpartum ovarian vein thrombophlebitis: sonographic diagnosis. *Abdom Imaging.* 2002;27(1):93-95.
11. Lotze EC, Kaufman RH, Kaplan AL. Postpartum ovarian vein thrombophlebitis. *Obstet Gynecol Surv.* 1966;21(6):853-870.
12. Twickler DM, Setiawan AT, Evans RS, et al. Imaging of puerperal septic thrombophlebitis: prospective comparison of MR imaging, CT, and sonography. *AJR Am J Roentgenol.* 1997;169(4):1039-1043.
13. Witlin AG, Sibai BM. Postpartum ovarian vein thrombosis after vaginal delivery: a report of 11 cases. *Obstet Gynecol.* 1995;85(5 Pt 1):775-780.
14. Kubik-Huch RA, Hebisch G, Huch R, Hilfiker P, Debatin JF, Krestin GP. Role of duplex color Doppler ultrasound, computed tomography, and MR angiography in the diagnosis of septic puerperal ovarian vein thrombosis. *Abdom Imaging.* 1999;24(1):85-91.
15. Brown CE, Lowe TW, Cunningham FG, Weinreb JC. Puerperal pelvic thrombophlebitis: impact on diagnosis and treatment using x-ray computed tomography and magnetic resonance imaging. *Obstet Gynecol.* 1986;68(6):789-794.