

## Mitral Regurgitation – A Multidisciplinary Challenge

Eduardo Alegria-Barrero<sup>1</sup> and Olaf W Franzen<sup>2</sup>

1. Interventional Cardiology, Torrejon University Hospital, Madrid, Spain; Cardiovascular Biomedical Research Unit, Royal Brompton Hospital, London, UK;

2. Interventional Cardiology, Klinik im Park, Hirslanden Zurich, Zurich, Switzerland

### Abstract

Mitral regurgitation is an increasing valvular disease that represents a difficult management challenge. Surgical treatment for degenerative mitral regurgitation is the standard of care treatment. Percutaneous therapies have emerged rapidly over the past years as an option for treatment of mitral regurgitation for selected, predominantly high-risk patients. Catheter-based devices mimic these surgical approaches with less procedural risk. Mitraclip® implantation mimics the surgical edge-to-edge leaflet repair technique, reducing the regurgitant area. We review the increasing evidence with the Mitraclip device reported to date.

### Keywords

Mitral valve, mitral regurgitation, mitral valve surgery, mitraclip, functional mitral regurgitation, degenerative mitral regurgitation

**Disclosure:** Olaf W Franzen is a consultant for Abbott Vascular. Eduardo Alegria-Barrero has no conflicts of interest to declare.

**Received:** 24 June 2014 **Accepted:** 5 July 2014 **Citation:** *European Cardiology Review*, 2014;9(1):49–53

**Correspondence:** Eduardo Alegria-Barrero, Interventional Cardiology, Torrejon University Hospital, Mateo Inurria s/n. 28850, Madrid, Spain.

E: ealegriabarrero@secardiologia.es

Diseases of the mitral valve (MV) are the second most frequent clinically significant form of valvular disease in adults. In particular, MV regurgitation occurs with increasing frequency as part of degenerative changes in the ageing process.<sup>1</sup>

The annual incidence of degenerative MV disease is estimated at approximately 2–3 %. In addition to degenerative valve disease, MV regurgitation can be caused by cardiac ischaemia (functional mitral regurgitation), infective endocarditis and rheumatic diseases (prevalent in less developed countries).<sup>1</sup> Severe mitral regurgitation (MR) develops gradually over the years and carries a high annual mortality rate of at least 5 %.<sup>2</sup> Medical therapy relieves symptoms but does not reverse the underlying mitral pathology.

Conventional surgical repair or replacement has been the standard of care for symptomatic severe MR.<sup>3,4</sup> Those with degenerative MR (DMR) have excellent outcomes with repair surgery.<sup>5</sup> However, the long-term benefits of surgical treatment of functional MR (FMR) are harder to demonstrate and remain controversial.<sup>6,7</sup>

Before the emergence of transcatheter valve therapies, optimal medical therapy and cardiac resynchronisation therapy in selected candidates have been the only treatment for patients deemed too high-risk for conventional surgery.<sup>8–11</sup> Although a variety of MV transcatheter therapies grew in parallel with aortic valve therapies, the MV therapies have had a slower development path.<sup>2</sup> Percutaneous edge-to-edge MV repair with the Mitraclip® system was demonstrated to be a safe and feasible alternative to surgical treatment for severe MR.<sup>12–15</sup> Adverse valve morphology and severe left ventricular dysfunction have been the two major challenges for the treatment with the Mitraclip system.<sup>16–18</sup>

Multidisciplinary assessment is essential for high-risk patients. A heart team including surgeons, interventional cardiologists, clinical cardiologists and imaging experts should discuss individual cases, considering the surgeon's/institution experience with MV repair versus replacement.

### Degenerative Mitral Regurgitation

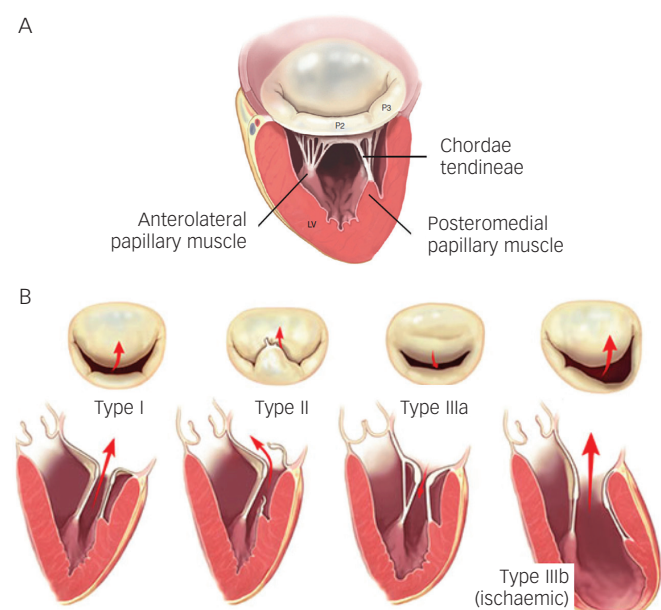
Degenerative MV disease frequently have leaflet prolapse due to elongation or rupture of the chordal apparatus, resulting in varying degrees of MV regurgitation due to leaflet malcoaptation during ventricular systole. Physiopathology of systolic flow reversal into the left atrium leads to atrial dilatation/fibrillation, ventricular function impairment and dilatation, secondary pulmonary hypertension and risk of sudden death.

### Surgical Treatment

There are several types of degenerative MV regurgitation<sup>19,20</sup> (see *Figure 1*). Current guidelines recommend MV repair when patients develop New York Heart Association (NYHA) class II symptoms, any deterioration in left ventricular function or an end-systolic diameter of 4.5 cm.<sup>21</sup> Recent evidence suggests that the best outcomes after repair of severe DMR are achieved in asymptomatic or minimally symptomatic patients, who are selected for surgery soon after diagnosis on the basis of echocardiography.<sup>22</sup>

Valve repair in patients with degenerative MV disease is associated with an improved quality of life with less morbidity as well as better long-term survival as opposed to replacement. Recent guidelines on valvular heart disease<sup>21</sup> contain a reported mortality for isolated MV repair of 1.6–2.1 % and 4.3–7.8 % mortality for MV replacement. More than 80 % of the patients are free from re-operation at five years.

Figure 1: Carpentier's Classification of Mitral Regurgitation



(A) Normal mitral valve anatomy. (B) Types of mitral regurgitation: Type I, normal leaflet motion; Type II, increased leaflet motion (leaflet prolapse); Type IIIa, restricted motion during systole and diastole (restricted leaflet opening); Type IIIb, restricted leaflet motion predominantly during systole (restricted leaflet closure)\*.

\* Modified from Carpentier, et al., 2010.<sup>45</sup>

However, even in developed countries, MV replacement remains frequent in this setting. In the Euro Heart Survey, repair rates were documented around 50 %, meaning that MV replacement continues to be performed far too frequently in the modern era of reconstructive valve surgery.<sup>23</sup>

MV repair for degenerative disease follows two fundamental principles:

- restore a good surface of leaflet coaptation (5–8 mm); and
- correct for annular dilatation – Carpentier's techniques being the most commonly performed worldwide.<sup>19,24</sup>

Long-term survival following MV repair is similar to age matched controls if the operation is performed before the onset of symptoms, ventricular dysfunction or atrial fibrillation.<sup>25</sup>

### Percutaneous Edge-to-Edge Repair

To date, up to 14,000 patients have been treated with the Mitraclip device worldwide, with nearly 2,000 enrolled in prospective clinical trials. The majority of patients included were considered at high peri-operative risk for MV surgery. After CE mark in 2008, numerous patients have been recruited in several studies. In 2013, the Food and Drug Administration (FDA) approved the Mitraclip device for symptomatic degenerative mitral valve regurgitation for patients at prohibitive risk for MV surgery by a heart team.

The Mitraclip system consists of a steerable guide catheter and a clip delivery system (CDS), which includes the clip attached at the end of the CDS (see Figure 2).<sup>26,27</sup> The guide catheter is 24 Fr proximally, and tapers to 22 Fr at the point where it crosses the interatrial septum (see Figure 2). These steering controls allow the operator to manoeuvre the clip over the MV. The clip is Dacron-covered with two clip arms that are opened and closed by control mechanisms on the CDS. Leaflet tissue is secured between

the clip arms and opposing grippers (see Figure 2). The clip arms are then closed to zero degrees, then locked to effect and maintain coaptation of the two leaflets.<sup>28</sup> Technical success is achieved in a high number of procedures.<sup>29,30</sup> In this technically demanding procedure, the co-operation and communication between the operators and the guidance by transoesophageal echocardiography (see Figure 3) are of great importance. Therefore, the effect of learning curve and co-operation between heart team members could impact on the clinical outcome in terms of MR reduction and complication rates.

The safety and efficacy of the percutaneous edge-to-edge with Mitraclip was initially tested in the Endovascular Valve Edge-to-Edge REpair Study (EVEREST I),<sup>15</sup> and then compared with surgery in the randomised standard-risk patients EVEREST II trial.<sup>31</sup> Procedural success was defined as successful and stable Mitraclip placement with residual MR  $\leq 2+$  on discharge. However, most of the patients enrolled in the EVEREST trials had DMR and all patients were surgical candidates. The real-world setting is very different from the original EVEREST trials – most of the patients treated with MitraClip are at high surgical risk and MR is more often functional rather than degenerative (see Table 1).

Of note, during the implantation of MitraClip, there is often a compromise between complete reductions of MR and resultant mitral stenosis by placing further clips. Several studies have reported that in these patients, significant improvement in symptoms can still be achieved despite a complete resolution of MR.<sup>30,32,33</sup>

EVEREST II trial<sup>31</sup> included 74 % patients with FMR randomised to surgery or Mitraclip treatment. Latest five-year data have recently been presented at the EuroPCR2014, Paris, France. Mean age in the DMR Mitraclip group was 67 years, 45 % of the patients were in NYHA class III/IV and mean ejection fraction was 64 %. Adverse event rates at 30-days (cardiac, vascular, renal, neurological) were low (25 %) compared with surgical DMR patients (33 %). At one-year, nine patients experienced single leaflet device attachment but no embolisation was observed. From one to five years follow-up, no further single device attachment or embolisation was observed. Survival rates at five years were similar in the Mitraclip and surgical groups (89.4 % versus 85.9 %, respectively). There was a concern on the need of re-operation for the Mitraclip patients. At one-year after the procedure, 75 % of the Mitraclip patients were free from re-operation/MV surgery compared with 100 % of the surgical group. However, from one to five years follow-up, 69 % Mitraclip patients were free from re-operation/MV surgery compared with 96 % of the surgical group, meaning that beyond one-year they observed comparable success rates for surgery and Mitraclip when index Mitraclip procedure was successful (92.2 % versus 95.8 % at five years).

MR grade at five years follow-up, was  $\leq 2+$  in 81 % of the Mitraclip patients and in all surgical patients (100 %), and both groups exerted reduction of left ventricular (LV) end-diastolic diameters. NYHA I/II functional class at five years was present in DMR in 95 % of the Mitraclip patients compared with 97 % of surgical survivors at five years. Mitraclip patients had comparable stability of mitral annular dimensions at five years compared to baseline (4.0 cm versus 3.9 cm,  $p=0.18$ ). Improved clinical performance in the six-minute walking test have also been reported.<sup>34</sup> In the EVEREST II high surgical risk cohort, a 55 % reduction of the annual rate of hospitalisations was observed (0.71–0.32,  $p=0.006$ ) after Mitraclip implantation.

Figure 2: MitraClip® Delivery System and Guiding Catheter and Characteristics of the Clip

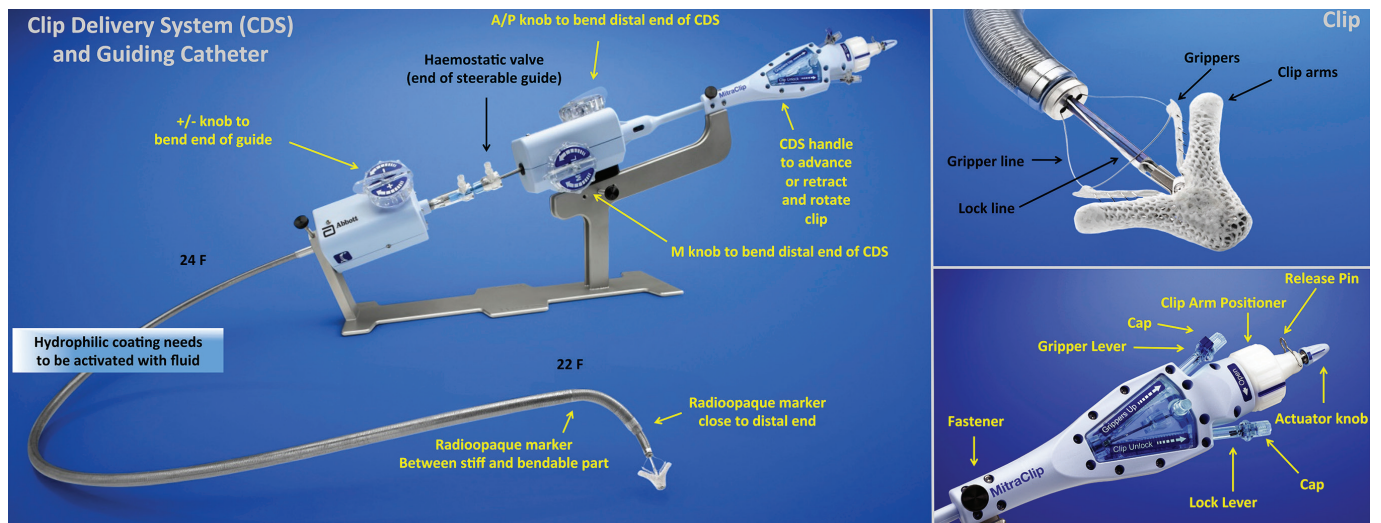
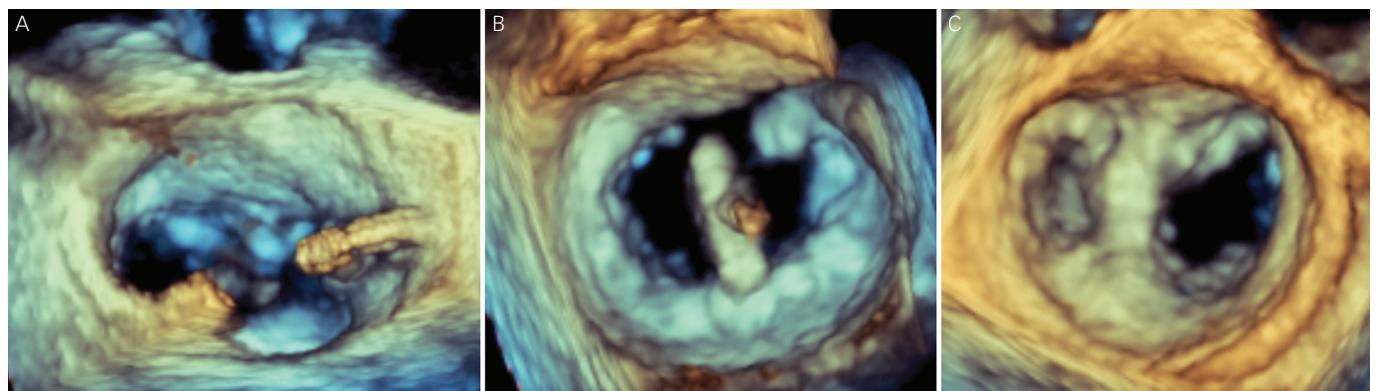


Figure 3: Three-dimensional Transoesophageal Echocardiogram Guidance During MitraClip® Implantation



(A) After transseptal puncture, the position and distance to the mitral valve is measured. A high and posterior puncture is aimed. (B) Orientation of the clip in the mitral valve (MV), perpendicular to the MV opening, assessed by three-dimensional transoesophageal echocardiogram (3D-TOE), from the left atrium (LA). (C) Final result after MitraClip implantation from the LA with two MV orifices, mimicking the Alfieri's surgical edge-to-edge leaflet technique.

Table 1: Guidelines Recommendations for Percutaneous Edge-to-Edge Mitral Valve Repair

<p><b>ESC/EACTS Guidelines on the management of valvular heart disease (version 2012)<sup>21</sup></b></p> <ul style="list-style-type: none"> <li>• Percutaneous edge-to-edge procedure may be considered in patients with symptomatic severe primary MR who fulfil the echo criteria of eligibility, are judged inoperable or at high surgical risk by a 'heart team' and have a life expectancy &gt;1 year (recommendation class IIb, level of evidence C)</li> <li>• The percutaneous mitral clip procedure may be considered in patients with symptomatic severe secondary MR despite optimal medical therapy (including CRT if indicated), who fulfil the echo criteria of eligibility, are judged inoperable or at high surgical risk by a team of cardiologists and cardiac surgeons, and who have a life expectancy &gt;1 year (recommendation class IIb, level of evidence C)</li> </ul>
<p><b>ESC Guidelines for the diagnosis and treatment of acute and chronic heart failure 2012<sup>42</sup></b></p> <p>In (secondary MR) patients with an indication for valve repair but judged inoperable or at unacceptably high surgical risk, percutaneous edge-to-edge repair may be considered in order to improve symptoms</p>
<p><b>2013 ACCF/AHA Guideline for the management of heart failure<sup>43</sup></b></p> <p>Transcatheter mitral valve repair or mitral valve surgery for functional mitral insufficiency is of uncertain benefit and should only be considered after careful candidate selection and with a background of GDMT (recommendation class IIb, level of evidence B)</p>
<p><b>2014 AHA/ACC Guideline for the management of patients with valvular heart disease<sup>44</sup></b></p> <p>Transcatheter MV repair may be considered for severely symptomatic patients (NYHA class III/IV) with chronic severe primary MR (stage D) who have a reasonable life expectancy but a prohibitive surgical risk* because of severe co-morbidities (recommendation class IIb, level of evidence B)</p>

\* Prohibitive surgical risk is defined as having one of the following:  
 • Predictive risk with surgery of death or major morbidity (all-cause) >50 % at one-year.  
 • ≥3 major organ system compromise not to be improved post-operatively (cardiac – severe left ventricular [LV] systolic or diastolic dysfunction or right ventricular [RV] dysfunction, fixed pulmonary hypertension; chronic kidney disease stage 3 or worse; pulmonary dysfunction with FEV1 <50 % or DLCO2 <50 % of predicted; neurological dysfunction [dementia, Alzheimer's disease, Parkinson's disease, vascular disease with persistent physical limitation]; gastrointestinal dysfunction – Crohn's disease, ulcerative colitis, nutritional impairment or serum albumin <3.0; cancer – active malignancy; and liver – any history of cirrhosis, variceal bleeding or elevated INR in the absence of therapy).  
 • Severe procedure-specific impediment (for example: tracheostomy present, heavily calcified ascending aorta, chest malformation, arterial coronary graft adherent to posterior chest wall or radiation damage).

ACC = American College of Cardiology; ACCF = American College of Cardiology Foundation; AHA = American Heart Association; CRT = cardiac resynchronisation therapy; DLCO2 = diffusing lung capacity for carbon dioxide; EACTS = European Association for Cardio-Thoracic Surgery; ESC = European Society of Cardiology; FEV1 = forced expiratory volume in one second; GDMT = guideline-directed medical therapy; INR = international normalised ratio; MR = mitral regurgitation; NYHA = New York Heart Association.

## Functional Mitral Valve Regurgitation

Ischaemic MR is characterised by restrictive mitral leaflet mobility due to dyskinesia or akinesia of the ventricular wall involving one or both papillary muscles, thus, extending the distance between the ventricular wall and the leaflets. The posterior papillary muscle is the most frequently affected.

FMR is associated with a poor prognosis in heart failure patients with post-ischaemic or idiopathic dilated cardiomyopathy.<sup>3</sup> Surgical MV repair may be considered in severely symptomatic patients with severe FMR despite optimal medical therapy and cardiac resynchronisation therapy.<sup>35,36</sup> Although several studies have reported reverse LV remodelling and improvements in symptoms and quality of life after surgical mitral repair,<sup>36</sup> operative mortality is not negligible, ranging from 8.8 % to 21.0 %.<sup>37</sup> Moreover, there is a high number of patients with severe FMR who are not referred for surgery because of advanced age, high surgical risk and co-morbidities.<sup>8</sup>

## Surgical Treatment

Historically, the surgical approach to patients with FMR was to perform MV replacement, but it had a high impact on LV systolic function and exerted high mortality rates. Techniques of MV replacement, such as prosthesis implantation with preservation of the subvalvular apparatus, and prosthesis implantation with preservation of one or both leaflets (usually posterior) have evolved to improve the long-term haemodynamic function and clinical status of these patients.<sup>38</sup> Replacement should be reserved for cases of acute papillary muscle rupture in relation to acute myocardial infarction.<sup>39</sup> In appropriately selected patients, restrictive annuloplasty is associated with low operative mortality and is effective in eliminating MR.

Acker et al.<sup>40</sup> have recently published the randomised comparison of MV repair versus replacement for severe ischaemic MR. At 12 months, the rate of death was 14.3 % in the repair group and 17.6 % in the replacement group (hazard ratio with repair, 0.79; 95 % confidence interval, 0.42–1.47;  $p=0.45$ ), with an increased rate of moderate or severe recurrence of MR at 12 months in the repair group compared with the replacement group (32.6 % versus 2.3 %,  $p<0.001$ ). Patient selection for repair is crucial. When the pre-operative clinical and echocardiographic data suggest that annuloplasty alone is unlikely to be successful and durable, additional surgical procedures should be used to enhance the effectiveness of MV repair.<sup>39</sup>

Since FMR exerts high mortality and high incidence of recurrence of MR after repair, several alternative treatments have been proposed.

## Percutaneous Edge-To-Edge Repair

EVEREST II trial included 26 % patients with FMR randomised to surgery or Mitraclip treatment. Recently reported five-year data (EuroPCR2014) have shown that freedom from mortality in Mitraclip patients ( $n=48$ ) and surgical patients ( $n=18$ ) is comparable within aetiologies: FMR Mitraclip 59.7 % and FMR Surgery 55.0 %, compared

with a 86.0–89.0 % survival for the DMR group. Moreover, 90 % of FMR patients treated with Mitraclip were free from MV surgery or re-operation at five years, compared with 81 % treated surgically. Durability of the Mitraclip repair was confirmed at five years follow-up, with 86 % of the patients in both groups with MV regurgitation grades 1+ or 2+. NYHA I/II functional class at five years was present in FMR in 76 % of the Mitraclip patients compared with 100 % of surgical survivors at five years. Mitraclip patients had comparable stability of mitral annular dimensions at five years compared to baseline (3.8 cm versus 3.7 cm,  $p=0.20$ ).

Taramasso et al.<sup>41</sup> have recently published the results of Mitraclip implantation in 109 consecutive patients with FMR and prohibitive surgical risk (logistic EuroSCORE [LogEuroscore]  $22 \pm 16$  %). Mean ejection fraction (EF) was  $28 \pm 11$  %; left ventricular end-diastolic diameter (LVEDD) was  $68 \pm 8$  mm. Procedural success was 99.0 % and 30-day mortality was 1.8 %. At discharge, 87 % patients had MR  $\leq 2+$ . At 12 months, EF was  $34.7 \pm 10.4$  % ( $p=0.002$  compared with pre-operative value). Actuarial survival at three years was  $74.5 \pm 7.0$  %. Actuarial freedom from MR  $\geq 3+$  at 2.5 years was  $70 \pm 6$  %. At one-year follow-up, 86 % of patients were in NYHA Class I-II. Pre-operative pro-B-type natriuretic peptide (pro-BNP) level  $\geq 1,600$  pg/ml was identified as an independent risk factor of mortality at follow-up.

Recently, the new European guidelines included the MitraClip as a treatment option in high-risk and inoperable patients with FMR and severe symptoms despite optimal medical therapy (class IIb indication with evidence C) (see *Table 1*).<sup>21, 42–44</sup> In the EVEREST II high surgical risk cohort, a 44 % reduction of the annual rate of hospitalisations was observed (0.82–0.46,  $p=0.0004$ ) after Mitraclip implantation.

After EVEREST II trial results (EuroPCR2014), including standard-risk patients, future guidelines may consider Mitraclip treatment as an option for FMR since it exerts sustained reduction of MR severity, sustained improvement in LV volumes and dimensions, and sustained improvement in NYHA functional class at five years, with low rates of conversion to MV surgery overall.

## Conclusions

MitraClip therapy is a safe procedure in selected high-risk patients and can be accomplished with low morbidity and mortality.

MV repair is the preferred treatment for degenerative MV regurgitation. However, Mitraclip implantation should be considered for high-risk surgical patients.

For FMR, Mitraclip is a valuable clinical option in patients with adequate anatomy who are considered inoperable or with a high surgical risk, and should be considered as an important therapeutic modality in the multidisciplinary treatment of heart failure. We need to treat patients at an earlier stage to achieve better prognostic outcomes. ■

1. Perlowski A, St Goar F, Glower DG, Feldman T. Percutaneous therapies for mitral regurgitation, *Curr Probl Cardiol*, 2012;37(2):42–68.
2. Feldman T, Young A. Percutaneous approaches to valve repair for mitral regurgitation, *J Am Coll Cardiol*, 2014;63(20):2057–68.
3. Franzen O, van der Heyden J, Baldus S, et al., MitraClip® therapy in patients with end-stage systolic heart failure, *Eur J Heart Fail*, 2011;13(5):569–76.
4. Maisano F, Franzen O, Baldus S, et al., MitraClip therapy

- demonstrates favourable mid-term outcomes in ACCESS-EUROPE heart failure patients with left ventricular ejection fraction 30%: preliminary report from the 6-month ACCESS-EU analysis cohort, *Eurointerv*, 2011;7(Suppl M).
5. Ling LH, Enriquez-Sarano M, Seward JB, et al., Clinical outcome of mitral regurgitation due to flail leaflet, *N Engl J Med*, 1996;335(19):1417–23.
6. Bonow RO, Carabello BA, Chatterjee K, et al., 2008 focused update incorporated into the ACC/AHA 2006 guidelines for the management of patients with valvular heart disease:

- a report of the American College of Cardiology/American Heart Association Task Force on Practice Guidelines (Writing Committee to revise the 1998 guidelines for the management of patients with valvular heart disease). Endorsed by the Society of Cardiovascular Anesthesiologists, Society for Cardiovascular Angiography and Interventions, and Society of Thoracic Surgeons, *J Am Coll Cardiol*, 2008;52(13):e1–142.
7. Diodato MD, Moon MR, Pasque MK, et al., Repair of ischemic mitral regurgitation does not increase mortality or improve long-term survival in patients undergoing coronary artery

- revascularization: a propensity analysis, *Ann of Thorac Surg*, 2004;78(3):794–9.
8. Mirabel M, lung B, Baron G, et al., What are the characteristics of patients with severe, symptomatic, mitral regurgitation who are denied surgery?, *Eur Heart J*, 2007;28(11):1358–65.
  9. van den Heuvel AFM, Alfieri O, Mariani MA, MitraClip in end-stage heart failure: a realistic alternative to surgery?, *Eur J Heart Fail*, 2011;13(5):472–4.
  10. Otto CM, Verrier ED, Mitral regurgitation—what is best for my patient?, *N Engl J Med*, 2011;364(15):1462–3.
  11. Cabrera-Bueno F, Molina-Mora MJ, Alzueta-Rodríguez FJ, Mitral regurgitation and cardiac resynchronization therapy: how long and what should we expect?, *Europace*, 2011;13(12):1801–2.
  12. Slaughter MS, Rogers JG, Milano CA, et al., Advanced heart failure treated with continuous-flow left ventricular assist device, *N Engl J Med*, 2009;361(23):2241–51.
  13. Franzen O, Baldus S, Rudolph V, et al., Acute outcomes of MitraClip therapy for mitral regurgitation in high-surgical-risk patients: emphasis on adverse valve morphology and severe left ventricular dysfunction, *Eur Heart J*, 2010;31(11):1373–81.
  14. Alqoofi F, Feldman T, Percutaneous approaches to mitral regurgitation, *Curr Treat Options Cardiovasc Med*, 2009;11(6):476–82.
  15. Feldman T, Kar S, Rinaldi M, et al., Percutaneous mitral repair with the MitraClip system: safety and midterm durability in the initial EVEREST (Endovascular Valve Edge-to-Edge REpair Study) cohort, *J Am Coll Cardiol*, 2009;54(8):686–94.
  16. Feldman T, Cilingsiroglu M, Percutaneous Leaflet Repair and Annuloplasty for Mitral Regurgitation, *J Am Coll Cardiol*, 2011;57(5):529–37.
  17. Taylor J, The percutaneous approach to mitral valve repair, *Eur Heart J*, 2011;32:249–51.
  18. Chan PH, Di Mario C, Franzen O, Dissociation between anatomical and functional results after MitraClip implantation, *Int J Cardiol*, 2012;155(2):175–6.
  19. Carpentier A, Chauvaud S, Fabiani JN, et al., Reconstructive surgery of mitral valve incompetence: ten-year appraisal, *J Thorac Cardiovasc Surg*, 1980;79(3):338–48.
  20. Castillo JG, Solis J, González-Pinto A, Adams DH, [Surgical echocardiography of the mitral valve], *Rev Esp Cardiol*, 2011;64(12):1169–81.
  21. Joint Task Force on the Management of Valvular Heart Disease of the European Society of Cardiology (ESC), European Association for Cardio-Thoracic Surgery (EACTS), Vahanian A, Alfieri O, Andreotti F, et al., Guidelines on the management of valvular heart disease (version 2012), *Eur Heart J*, 2012;33(19):2451–96.
  22. Kang DH, Kim JH, Rim JH, et al., Comparison of early surgery versus conventional treatment in asymptomatic severe mitral regurgitation, *Circulation*, 2009;119(6):797–804.
  23. lung B, Baron G, Tornos P, et al., Valvular heart disease in the community: a European experience, *Curr Probl Cardiol*, 2007;32(11):609–61.
  24. Braunberger E, Deloche A, Berrebi A, et al., Very long-term results (more than 20 years) of valve repair with carpentier's techniques in nonrheumatic mitral valve insufficiency, *Circulation*, 2001;104(12 Suppl 1):18–11.
  25. Enriquez-Sarano M, Sundt TM, Early surgery is recommended for mitral regurgitation, *Circulation*, 2010;121(6):804–11.
  26. Feldman T, Franzen O, Low R, et al., *Atlas of Percutaneous Edge-to-Edge Mitral Valve Repair*, London, UK: Springer, 2013;669.
  27. Alegría-Barrero E, Chan PH, Di Mario C, Franzen O, Tools and techniques: edge-to-edge percutaneous MitraClip® implantation, *EuroIntervention*, 2012;7(12):1476–8.
  28. Borgia F, Di Mario C, Franzen O, Adenosine-induced asystole to facilitate MitraClip placement in a patient with adverse mitral valve morphology, *Heart*, 2011;97(10):864.
  29. Ledwoch J, Franke J, Baldus S, et al., Impact of the learning curve on outcome after transcatheter mitral valve repair: results from the German Mitral Valve Registry, *Clin Res Cardiol*, 2014 [Epub ahead of print].
  30. Alegría-Barrero E, Chan PH, Foin N, et al., Concept of the central clip: when to use one or two MitraClips®, *EuroIntervention*, 2014;9(10):1217–24.
  31. Feldman T, Foster E, Glower DD, et al., Percutaneous repair or surgery for mitral regurgitation, *N Engl J Med*, 2011;364(15):1395–406.
  32. Chan PH, She HL, Alegría-Barrero E, et al., Real-world experience of MitraClip for treatment of severe mitral regurgitation, *Circ J*, 2012;76(10):2488–93.
  33. Chan PH, She HL, Alegría-Barrero E, et al., Effects of dynamic annular shape changes on MitraClip therapy and combining mitral cerclage annuloplasty—reply, *Circ J*, 2013;77(2):551.
  34. Maisano F, Franzen O, Baldus S, et al., Percutaneous mitral valve interventions in the real world: early and 1-year results from the ACCESS-EU, a prospective, multicenter, nonrandomized post-approval study of the MitraClip therapy in Europe, *J Am Coll Cardiol*, 2013;62(12):1052–61.
  35. Bolling SF, Deeb GM, Brunsting LA, Bach DS, Early outcome of mitral valve reconstruction in patients with end-stage cardiomyopathy, *J Thorac Cardiovasc Surg*, 1995;109(4):676–82.
  36. Bolling SF, Mitral repair for functional mitral regurgitation in idiopathic dilated cardiomyopathy: a good operation done well may help, *Eur J Cardiothorac Surg*, 2012;42(4):646–7.
  37. Crabtree TD, Bailey MS, Moon MR, et al., Recurrent mitral regurgitation and risk factors for early and late mortality after mitral valve repair for functional ischemic mitral regurgitation, *Ann Thorac Surg*, 2008;85(5):1537–42.
  38. David TE, Uden DE, Strauss HD, The importance of the mitral apparatus in left ventricular function after correction of mitral regurgitation, *Circulation*, 1983;68(3 Pt 2):1176–82.
  39. Madesis A, Tsakiridis K, Zarogoulidis P, et al., Review of mitral valve insufficiency: repair or replacement, *J Thorac Dis*, 2014;6 (Suppl 1):S39–51.
  40. Acker MA, Parides MK, Perrault LP, et al., Mitral-valve repair versus replacement for severe ischemic mitral regurgitation, *N Engl J Med*, 2014;370(1):23–32.
  41. Taramasso M, Maisano F, Latib A, et al., Clinical outcomes of MitraClip for the treatment of functional mitral regurgitation, *EuroIntervention*, 2014 [Epub ahead of print].
  42. McMurray JJ, Adamopoulos S, Anker S, et al., ESC guidelines for the diagnosis and treatment of acute and chronic heart failure 2012: The Task Force for the Diagnosis and Treatment of Acute and Chronic Heart Failure 2012 of the European Society of Cardiology. Developed in collaboration with the Heart Failure Association (HFA) of the ESC, *Eur J Heart Fail*, 2012;14(8):803–69.
  43. Yancy CW, Jessup M, Bozkurt B, et al., 2013 ACCF/AHA guideline for the management of heart failure: a report of the American College of Cardiology Foundation/American Heart Association Task Force on practice guidelines, *Circulation*, 2013;128:e240–327.
  44. Nishimura RA, Otto CM, Bonow RO, et al., 2014 AHA/ACC Guideline for the Management of Patients With Valvular Heart Disease: A Report of the American College of Cardiology/American Heart Association Task Force on Practice Guidelines, *J Am Coll Cardiol*, 2014;63(22):e57–185.
  45. Carpentier A, Adams DH, Filsoufi F, Carpentier's Reconstructive Valve Surgery. From Valve Analysis to Valve Reconstruction, Philadelphia, US: Saunders, Elsevier, 2010.