

Early Macular Vessel Density Loss in Acute Ischemic Optic Neuropathy Compared to Papilledema: Implications for Pathogenesis

Masoud Aghsaei Fard¹, Hosein Ghahvechian¹, Alireza Sahrayan¹, and Prem S. Subramanian²

¹ Farabi Eye Hospital, Eye Research Center, Tehran University of Medical Science, Tehran, Iran

² Department of Ophthalmology, University of Colorado, School of Medicine, Aurora, CO, USA

Correspondence: Masoud Aghsaei Fard, Farabi Eye Hospital, Eye Research Center, South Kargar, Qazvin SQ, Tehran, Iran, 13352. e-mail: masood219@gmail.com

Received: 11 June 2018

Accepted: 1 August 2018

Published: 26 September 2018

Keywords: optic neuropathy; macula; vessel density

Citation: Fard MA, Ghahvechian H, Sahrayan A, Subramanian PS. Early macular vessel density loss in acute ischemic optic neuropathy compared to papilledema: implications for pathogenesis. *Trans Vis Sci Tech.* 2018;7(5):10, <https://doi.org/10.1167/tvst.7.5.10>

Copyright 2018 The Authors

Purpose: This study compares macular and parafoveal vasculature in patients with optic disc swelling.

Methods: Twenty eyes with acute nonarteritic anterior ischemic optic neuropathy (NAION), 39 eyes with papilledema at first presentation, and 22 eyes of normal subjects were imaged using optical coherence tomography angiography (OCT-A). Macular ganglion cell complex (GCC) and peripapillary retinal nerve fiber layer thicknesses were measured in addition to macula and parafovea superficial and deep vasculature.

Results: Age- and gender-mixed models showed that the macular and parafoveal superficial and deep vasculature density values were significantly lower in NAION eyes than control eyes ($P \leq 0.0001$ for all comparisons). All vessel density values were not statistically different between papilledema eyes and control eyes. Whole superficial and deep macula vasculature in the NAION eyes ($45.9\% \pm 4.2\%$, $50.9\% \pm 6.5\%$) were significantly lower than in papilledema eyes ($50.5\% \pm 4.6\%$, $57.3\% \pm 6.1\%$) ($P = 0.03$ and $P = 0.01$, respectively). No significant differences in GCC thickness were observed among NAION, papilledema, and control eyes. Whole superficial and deep macular vasculatures, but not macular GCC thickness, were significantly correlated with visual field mean deviation ($r = 0.39$, $P = 0.001$ and $r = 0.41$, $P < 0.001$, respectively).

Conclusions: Macular OCT-A is able to show early macular vasculature abnormalities associated with optic nerve damage; this change occurs before detectable macular GCC atrophy.

Translational Relevance: Macular vessel density measurement offers an opportunity to evaluate the optic nerve damage at initial presentation, but further longitudinal studies are needed.

Introduction

Optic disc swelling in both nonarteritic anterior ischemic optic neuropathy (NAION) and papilledema occurs when there is obstruction of axonal transport at the level of the lamina cribrosa; the resultant peripapillary retinal nerve fiber layer (RNFL) edema may progress to death of the retinal ganglion cells (RGCs) and permanent loss of function.¹ RGC loss cannot be predicted by acute peripapillary RNFL measurements, and thus macular ganglion cell-inner

plexiform (GCIPL) thicknesses have been measured in different types of optic neuropathies with the goal of predicting visual outcomes.^{2,3} However, even ganglion cell loss may not be appreciable at first presentation of patients with acute optic disc swelling and visual field defects. Baseline optical coherence tomography (OCT) measurement of papilledema in the IHH Treatment Trial showed macular region GCIPL thinning in only 7.3% of eyes.⁴ In our previous work, mean inner and outer macular ring GCIPL thicknesses were not different between newly

diagnosed papilledema and control eyes.⁵ Likewise, ganglion cell loss does not occur at presentation in NAION eyes, with a decline in GCIPL found only 1 month after presentation.⁶

Quantitative assessment of macular and peripapillary vasculature using OCT angiography (OCT-A)⁷ has allowed the detection of vessel loss in various optic neuropathies. Reduced peripapillary and macular microcirculation in the normal hemisphere of glaucomatous eyes and unaffected fellow eyes suggests that perfusion defects may precede optic disc structural changes and visual field loss.^{8–10} Furthermore, the rate of macular vessel density loss may exceed that of macular GCIPL loss in glaucomatous eyes with preexisting damage.¹¹ Macular vessel density recently was reported to be reduced in NAION eyes studied by OCT-A more than 3 months after onset of symptoms,¹² in contrast to earlier work showing no macular vascular changes.¹³ In addition, it is also unclear whether the microvascular reduction in NAION eyes is only a result of retinal ganglion cell axonal loss or whether it can be caused by optic disc axonal swelling.¹² Therefore, we recruited two types of optic disc swelling due to NAION and papilledema in this study. No data have been reported on acute macular vasculature densities in these optic neuropathies, nor has a potential relationship between early OCT-A findings and visual function been explored.

We hypothesized that macular vascular abnormalities may be a very early sign of damage in NAION and/or papilledema and might occur before detectable macular ganglion cells and/or RNFL loss. In addition, we sought to determine if we could correlate visual function, as determined by automated perimetry, with macular cellular (GCIPL) or vascular properties at presentation of disc swelling.

Materials and Methods

Subjects

Patients with acute NAION or papilledema who were seen the outpatient clinic of Farabi Eye Hospital between February 2016 and December 2017 were eligible for this prospective comparative study. All investigations adhered to the tenets of the Declaration of Helsinki, and the study was approved by the Ethics Committee of Tehran University of Medical Science. Written informed consent was obtained from each participant after receiving a detailed explanation of the nature and objective of the study.

All subjects underwent a thorough ophthalmic

evaluation, including best-corrected visual acuity (BCVA), slit-lamp biomicroscopy, intraocular pressure (IOP) by Goldman applanation tonometry, and dilated fundus examination.

Perimetry was performed using the standard 24-2 Swedish Interactive Thresholding Algorithm on the Humphrey Field Analyzer (Carl Zeiss Meditec, Dublin, CA), and visual field mean deviation (MD) was recorded. Patients also underwent macular and peripapillary RNFL OCT and macular OCT-A imaging using Optovue OCT (see below).

Inclusion criteria for acute NAION were painless, acute, unilateral vision loss within 2 weeks of the initial evaluation and optic disc edema with or without superficial hemorrhage. Patients with evidence of glaucoma or arteritic anterior ischemic optic neuropathy (systemic manifestations of giant cell arteritis, an erythrocyte sedimentation rate >50 mm/h and a positive C-reactive protein and/or systemic findings) were excluded.

The papilledema group consisted of patients with idiopathic intracranial hypertension diagnosed <1 month prior to evaluation meeting the following criteria: normal magnetic resonance imaging results and normal magnetic resonance venography of the brain, lumbar puncture showing intracranial pressure >250 mm H₂O with normal cerebrospinal fluid (CSF) contents, and mild or moderate disc swelling (Frisén grade 1–4). Exclusion criteria were severe (Frisén grade 5)¹⁴ papilledema, chronic papilledema as defined by swelling with pallor and/or macular exudate, and more than 1 month duration of diagnosed papilledema.

The control group comprised subjects with a BCVA \geq 20/30, IOP \leq 21 mm Hg, an open angle, and normal optic disc appearance on fundus examination.

In all groups, patients <18 years of age, those with history of ocular surgery (except for uncomplicated cataract surgery), a glaucomatous or neurological disease, macular abnormalities such as subretinal fluid,⁶ or refractive errors \geq +6.00 or \leq -6.00 diopter (D) or more than \pm 3.00 D astigmatism were also excluded.

OCT Measurements

Spectral-domain (SD)-OCT (Avanti; Optovue, Inc., Fremont, CA) was used to map ganglion cell complex (GCC) and RNFL thickness. Images were obtained using OCT after pupil dilation, and images with poor quality or signal strength index of less than 45 were excluded. The measurement of the RNFL was performed using 3.4-mm diameter circular scan with

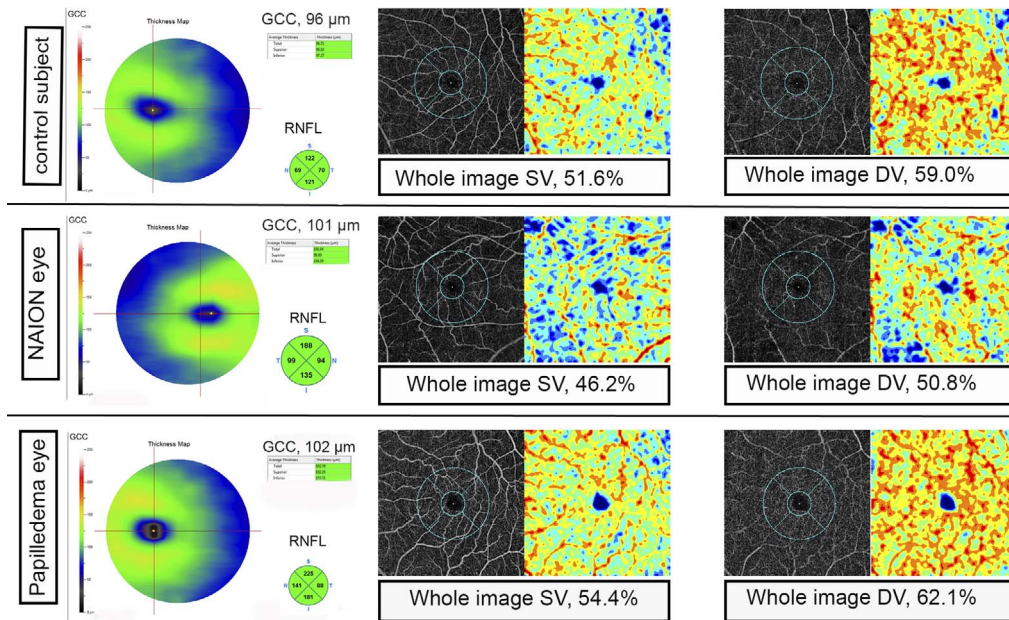


Figure. OCT-A of macular vasculature in control, NAION, and papilledema eyes with optic disc swelling. Left column: GCC maps and RNFL thickness of three subjects. Three subjects had similar GCC thickness values. Second column: OCT-A images of SV with two concentric circles with 3 mm (parafovea and its four sectors) and 1 mm diameter. Third column: Deep macular vasculatures (DV). Vessel density values both in SV and DV of NAION eye is lower than papilledema and control eyes.

recording average RNFL and four sectors. The GCC thickness was measured from the internal limiting membrane (ILM) to the outer inner plexiform layer (IPL) boundary. Macular GCC scan protocol was used to sample the macula over a 7-mm diameter, and parafovea GCC was measured over a 3-mm diameter centered on the fovea. Total, superior, and inferior hemispheres GCC were recorded for both macular and parafoveal areas.¹⁵

Macular OCT-A

AngioVue (software version 2016.2; Optovue, Inc.) uses an 840-nm light source with an A-scan rate of 70,000 scans/s in a 6×6-mm rectangle scan centered on the fovea. The AngioVue shows blood flow information at various retinal layers as a vessel density map (%), which was acquired by the split spectrum amplitude-decorrelation angiography algorithm. Superficial retinal vasculatures (SVs) were imaged in the slab images from the inner boundary 3 μ m beneath the internal limiting membrane to the outer boundary 15 μ m beneath the IPL, whereas the deep retinal vasculatures (DVs) were imaged in slab images from the inner boundary 15 μ m beneath the IPL to the outer boundary 70 μ m beneath the IPL, according to the default setting of the manufacturer's software (Optovue, Inc.).^{16,17} Superficial and deep

retinal measurements of the vasculatures were obtained in two regions: (1) macular vessel density was calculated in a 6-mm diameter region and divided into whole macula, superior hemi-macula, and inferior hemi-macula to calculate the hemispheric measurements; (2) parafoveal vessel density was measured in an annular region with an inner diameter of 1 mm and outer diameter of 3 mm centered on the fovea, and the parafoveal region was divided into four sectors (superior, inferior, temporal, and nasal) in addition to superior and inferior hemispheric areas as shown in the [Figure](#).

Statistical Analysis

The distribution of numerical data was tested for normality using the Shapiro-Wilk test. Descriptive statistics were calculated as the mean and standard deviation. Categorical variables were compared using the χ^2 test. Age- and gender-adjusted linear mixed modeling was used for the comparison between groups after accounting for intereye correlation. In linear mixed model regression, the correlation in outcomes between paired eyes of a subject was accounted for by adding a random effect.¹⁸ Bonferroni correction was also performed to adjust for multiple comparisons between groups. In addition, univariable linear regression models were built using

Table 1. Demographic and Ocular Characteristics of Healthy, NAION, and Papilledema Eyes

	NAION Eye (n = 20)	Control (n = 22)	Papilledema (n = 39)	NAION vs. Control	Papilledema vs. Control	Papilledema vs. NAION
Age, y	56.1 ± 11.3	46.7 ± 15.7	40.8 ± 11.2	0.05	0.24	<0.001
Gender, female:male	6:14	8:14	37:2	0.45	<0.001	<0.001
Visual acuity, LogMAR	0.64 ± 0.43	0.06 ± 0.11	0.11 ± 0.12	<0.001	0.74	<0.001
Visual field, MD, dB	-17.2 ± 7.1	-0.6 ± 1.5	-2.4 ± 1.7	<0.001	0.36	<0.001
Average RNFL, μm	151.9 ± 36.5	97.1 ± 11.5	131.6 ± 37.4	<0.001	<0.001	>0.99
Superior RNFL, μm	178.5 ± 40.6	117.8 ± 13.9	155.6 ± 50.7	<0.001	0.003	>0.99
Nasal RNFL, μm	134.4 ± 43.4	78.1 ± 10.9	112.5 ± 42.1	<0.001	0.001	>0.99
Inferior RNFL, μm	179.3 ± 48.3	122.0 ± 17.5	163.6 ± 39.0	<0.001	0.004	0.84
Temporal RNFL, μm	123.0 ± 46.2	72.1 ± 10.6	91.6 ± 37.7	<0.001	0.06	0.50

visual field MD as the dependent variable and OCT-A parameters, macular and parafoveal SV and DV, and total macular and parafoveal GCC as the independent variables. Multivariable linear regression model also was used to evaluate the relationship between the visual field MD with age, macular vessel density (macular SV and DV) and GCC.

Results

Sixty-five subjects in total, including controls, were eligible. Three subjects were excluded because of poor signal quality, poor vision, and/or eye movement. Therefore, 20 eyes of 20 patients with unilateral acute NAION, 39 eyes of 20 patients with papilledema, and 22 eyes of 22 control subjects were included in this study.

Table 1 summarizes the demographic information and structural biometric measurements. Mean age of the control group did not differ significantly from either the NAION or papilledema group. However, the mean age of the papilledema group was significantly lower than the NAION group ($P < 0.001$) and had a female predominance ($P < 0.001$). Therefore, all comparisons were adjusted for age and gender

differences between groups. Nine NAION eyes had predominantly inferior altitudinal visual field defect, and generalized depression was found in the rest of NAION cases. The most common visual field pattern in papilledema cases was enlarged blind spot (20 out of 39).

Average and all sectoral RNFL thicknesses (except temporal sector of papilledema eyes) were greater in acute NAION eyes and papilledema eyes than control subjects (all $P < 0.001$). RNFL data were not different between papilledema and NAION eyes (Table 1). No significant differences in GCC thickness were observed among NAION, papilledema, and control eyes when total macular and parafoveal areas, as well as superior and inferior hemiretinal component areas, were evaluated (Table 2).

Superficial Retinal Vasculature Density

Age- and gender-adjusted mixed modeling showed that the macular and parafoveal vessel density and component sector values were significantly lower in NAION eyes compared to controls. Specifically, whole macular SV ($45.9\% \pm 4.2\%$) and whole parafoveal SV measurements ($49.5\% \pm 4.7\%$) in the NAION eyes were lower than whole macular SV

Table 2. OCT Macular GCC Thicknesses in Healthy, NAION, and Papilledema Eyes

Retinal GCC Thickness	NAION Eye	Control	Papilledema	NAION vs. Control	Papilledema vs. Control	Papilledema vs. NAION
Total macular	94.8 ± 9.8	96.1 ± 10.6	90.5 ± 17.0	>0.99	0.38	0.79
Superior hemi-macula	93.6 ± 11.5	95.7 ± 10.3	88.6 ± 17.1	>0.99	0.13	0.53
Inferior hemi-macula	96.1 ± 12.7	96.3 ± 10.7	92.3 ± 17.1	>0.99	>0.99	>0.99
Total parafovea	119.1 ± 13.7	121.6 ± 11.0	119.6 ± 17.3	>0.99	0.21	0.42
Superior hemi-parafovea	117.5 ± 16.4	119.9 ± 10.8	117.7 ± 17.7	>0.99	0.14	0.35
Inferior hemi-parafovea	120.7 ± 14.5	123.1 ± 11.3	121.5 ± 17.7	>0.99	0.45	0.67

Table 3. OCT-A Superficial Retinal Vascular Densities in Healthy, NAION, and Papilledema Eyes

SV Complex Density, %	NAION	Control	Papilledema Eye	NAION vs. Control	Papilledema vs. Control	Papilledema vs. NAION
Whole macula	45.9 ± 4.2	52.5 ± 3.3	50.5 ± 4.6	<0.001	0.57	0.03
Superior hemi-macula	45.5 ± 3.7	53.0 ± 3.3	50.3 ± 4.8	<0.001	0.21	0.02
Inferior hemi-macula	46.4 ± 5.3	52.0 ± 3.7	50.6 ± 4.5	0.003	>0.99	0.06
Whole parafovea	49.5 ± 4.7	55.7 ± 3.6	54.3 ± 4.7	0.001	>0.99	0.04
Superior hemi-parafovea	49.0 ± 4.3	56.6 ± 3.8	54.5 ± 5.0	<0.001	0.56	0.03
Inferior hemi-parafovea	50.1 ± 5.4	54.7 ± 3.7	54.0 ± 4.7	0.02	>0.99	0.09
Temporal parafovea	50.2 ± 4.8	55.8 ± 4.4	54.6 ± 4.4	0.007	0.79	0.24
Superior parafovea	48.6 ± 5.0	56.6 ± 3.8	54.1 ± 5.6	<0.001	0.66	0.02
Nasal parafovea	50.1 ± 4.9	55.7 ± 3.3	54.5 ± 4.7	0.002	>0.99	0.01
Inferior parafovea	49.2 ± 5.7	54.4 ± 4.7	53.8 ± 5.4	0.03	>0.99	0.13

(52.5% ± 3.3%) and whole parafoveal (55.7% ± 3.6%) measurements in the control eyes ($P < 0.001$ and $P = 0.001$, respectively). No SV values were statistically different between papilledema eyes and control eyes. Whole macular and parafoveal SV values and superior sector SV also were significantly lower in NAION than papilledema eyes; however, inferior macular and inferior parafoveal sector values did not differ between these two groups (Table 3).

Deep Retinal Vasculature Density

Significantly lower DV values for whole and sectoral macular and parafoveal areas were found in NAION eyes compared to control and papilledema eyes. Whole macular DV value of NAION eyes was 50.9% ± 6.5%, which was lower than the DV measurements of 57.3% ± 6.1% and 60.6% ± 4.0% in the papilledema and control eyes, respectively (both $P < 0.001$). In contrast, subjects with papilledema did

not show significant differences in any DV values from healthy subjects (Table 4).

Calculated Pearson correlations for different variables showed that visual acuity was negatively correlated to SV of whole macula ($r = -0.28$, $P = 0.01$) and whole parafovea ($r = -0.26$, $P = 0.02$) as well as DV of whole macula ($r = -0.31$, $P = 0.006$) and parafovea ($r = -0.33$, $P = 0.004$). Neither macular nor parafoveal GCC values were correlated to visual acuity ($P = 0.92$ and $P = 0.50$, respectively). Similarly, visual field MD correlated to both macular and parafovea whole SV and DV, with r values of 0.39, 0.35, 0.41, 0.43, respectively ($P = 0.001$, $P = 0.002$, $P < 0.001$, and $P < 0.001$, respectively). No association was found between GCC thickness and visual field MD. Multivariate regression analysis for visual field MD as the dependent variable showed strong correlations to both macular SV ($P = 0.001$) and DV ($P < 0.001$), without significant association with macular GCC or age. Multivariate linear regression

Table 4. OCT-A DV Densities in Healthy, NAION, and Papilledema Eyes

Deep Retinal Vascular Complex Density, %	NAION Eyes	Control Eyes	Papilledema Eyes	NAION vs. Control	Papilledema vs. Control	Papilledema vs. NAION
Whole macula	50.9 ± 6.5	60.6 ± 4.0	57.3 ± 6.1	<0.001	0.24	0.01
Superior hemi-macula	50.4 ± 6.1	60.9 ± 3.7	57.3 ± 6.4	<0.001	0.16	0.01
Inferior hemi-macula	51.4 ± 7.5	60.2 ± 4.7	57.3 ± 6.0	<0.001	0.44	0.04
Whole parafovea	54.7 ± 6.8	63.5 ± 3.3	61.4 ± 5.7	<0.001	0.77	0.006
Superior hemi-parafovea	54.0 ± 6.4	64.2 ± 3.1	61.2 ± 5.9	<0.001	0.35	0.003
Inferior hemi-parafovea	55.5 ± 7.7	62.8 ± 3.9	61.6 ± 5.8	0.001	>0.99	0.01
Temporal parafovea	54.1 ± 6.7	63.0 ± 4.1	60.8 ± 5.7	<0.001	0.63	0.01
Superior parafovea	54.3 ± 8.7	65.2 ± 2.8	61.7 ± 6.3	<0.001	0.36	0.003
Nasal parafovea	54.6 ± 6.1	63.1 ± 2.8	60.8 ± 6.2	<0.001	0.59	0.01
Inferior parafovea	55.9 ± 7.8	62.6 ± 5.3	62.4 ± 5.8	0.006	>0.99	0.02

analysis that controlled for the effect of age also showed that each 1% loss in macula SV and DV was associated with 0.67 dB and 0.52 dB decrease in visual field MD, respectively.

Discussion

The quantitative characteristics of SV and DV in the 6-mm macular and 3-mm parafoveal areas in acute NAION, newly diagnosed papilledema, and normal control eyes were evaluated. The major findings include the following: (1) The whole macular and parafoveal SV and DV density values and the vessel density in each hemisphere demonstrated a significant reduction in NAION eyes compared to control eyes, even though GCC in the macula and parafovea was not affected; (2) there were no differences in any macular and parafoveal vessel densities between papilledema eyes and control eyes; (3) whole macular, parafoveal, and superior sector values were lower in NAION eyes than papilledema eyes; and (4) macular and parafoveal SV and DV, but not GCC, values were correlated with visual acuity and visual field MD.

Prior studies using OCT-A have demonstrated decreased macular SV and DV in eyes with postacute NAION, in which RNFL and macular ganglion cell damage had already occurred.¹² Indeed, a significant correlation between vascular dropout and RNFL and macular GCC losses^{9,12,19,20} and nonspecific and similar reduction of peripapillary capillary density in a variety of optic neuropathies²¹ has been reported, leading to the proposition that vascular dropout is a degenerative response to loss of metabolically active tissues (RGCs and their axons).^{20,21} Our results provide evidence to the contrary, with demonstration of reduced SV and DV densities that are evident despite normal GCC thicknesses. Our findings are similar to observations of vascular changes that appear to precede detectable structural or visual field damage in eyes of glaucoma patients.^{8–10,22}

The mechanism by which macular SV and DV are affected in NAION remains unclear. Central retinal arterial flow has been shown by color Doppler imaging to decrease after NAION,^{23–25} despite the anatomic separation of the central retinal artery and posterior ciliary artery circulations.²⁶ Although OCT-A does not directly quantify flow, the vessel density measurements are based on amplitude decorrelation resulting from red blood cell motion. It is possible that the reduced macula SV and DV densities that we observed could be the result of very slow rates of blood flow rather than capillary dropout.¹¹ Augstburger et al.¹² speculated

that the macular vessel loss they observed weeks after acute NAION might have resulted from compression of superficial macular capillaries by axonal swelling in the acute phase of the disease, in addition to secondary degeneration from GCC loss. As noted above, our results demonstrate reduced SV and DV densities in NAION eyes without GCC loss. In addition, we found similar levels of axonal swelling (as determined by peripapillary RNFL thickness) in study eyes with either NAION or papilledema, but macular/parafoveal vessel densities were reduced in NAION alone. Thus, we do not believe that direct capillary compression by enlarged axons would account for the observed changes. Additionally, typical inferior altitudinal visual field defects in our NAION eyes and sparing of the superior visual field in these cases might explain why corresponding inferior parafoveal sector VD values were similar between NAION and papilledema eyes.

Studies using OCT-A of the optic disc and peripapillary region have shown areas of nonperfusion in acute NAION,^{27,28} findings in accord with earlier work using fluorescein angiography.²⁹ However, those studies could not evaluate early RNFL loss or capillary abnormalities at the same time due to optic nerve edema. In addition, the observed decrease in peripapillary vasculature may be the result of mechanical impedance of blood flow from the disc swelling or signal attenuation secondary to disc edema and/or hemorrhage.²⁷ Furthermore, peripapillary retinal layer segmentation is hampered by the disc edema and can create an artifact in both OCT-A and RNFL thickness measurements.⁴ Assessing the macular area provides an opportunity to measure macular GCC and vessel density simultaneously in the acute phase without the confounding effect of disc edema.

In this study, we included NAION patients with symptom onset of <14 days, and we found moderate correlations between visual functions (visual acuity and visual field MD) and vessel density values. Such correlation did not exist between GCC and visual function. Indeed, we previously reported a lack of an association between ganglion cell thickness and baseline visual acuity at first presentation of NAION eyes but noted GCC loss at 1 month after onset.⁶ Similarly, in eyes with papilledema and vision loss, progressive GCC loss >10 μm over 2 to 3 weeks correlated with worse final visual outcomes, but initial GCC values did not.³⁰

Our multivariable analysis showed that each 1% loss in macular SV and DV was associated with a 0.67 and 0.52 dB decrease in visual field MD; therefore, OCT-A findings of macular and parafoveal vessel density values

at presentation of NAION and papilledema can be used as an estimate of visual field, whereas GCC and RNFL measurements are not helpful.

There were several limitations in our study. Because of the cross-sectional design, we could only identify microvascular abnormalities and their associations with visual function. We did not have longitudinal data to allow us to assess the true prognostic value of reduced macular vessel density in predicting long-term visual outcomes in both NAION and papilledema. In addition, prior OCT-A work has shown that flow projection artifacts can cause SV to be duplicated on deeper slabs and overestimate the DV measurements.³¹ However, we measured lower DV values, and therefore, we do not believe that projection artifact affected our measurements.

In conclusion, we showed that all macular and parafoveal SV and DV values were significantly lower in acute NAION eyes compared to control eyes, and macular vessel density was affected at first presentation of NAION (before GCC involvement). We speculate that these results could reflect early macular vasculature damage that precedes and perhaps results in macular ganglion atrophy. Macular vascular findings did not differ between control eyes and papilledema eyes, which had RNFL edema and GCC thickness similar to NAION eyes. Furthermore, NAION eyes had significantly lower whole macular and parafoveal vessel densities compared with papilledema eyes. Further longitudinal studies are needed to identify the full prognostic implications of our findings.

Acknowledgments

Supported in part by a Challenge Grant to the Department of Ophthalmology, University of Colorado School of Medicine, from Research to Prevent Blindness, Inc.

Disclosure: **M.A. Fard**, None; **H. Ghahvechian**, None; **A. Sahrayan**, None; **P.S. Subramanian**, Quark Pharmaceuticals (S), Santhera Pharmaceuticals (S), National Institutes of Health (S), GenSight Biologics (S), Quark (S)

References

1. Trobe JD. Papilledema: the vexing issues. *J neuroophthalmol*. 2011;31:175–186.
2. Fard MA, Afzali M, Abdi P, Ebrahimi KB, Moghimi S. Comparison of the pattern of macular ganglion cell-inner plexiform layer defect between ischemic optic neuropathy and open-angle glaucoma. *Invest Ophthalmol Vis Sci*. 2016; 57:1011–1026.
3. Aghsaei Fard M, Fakhree S, Ameri A. Posterior pole retinal thickness for detection of structural damage in anterior ischaemic optic neuropathy. *Neuroophthalmology*. 2013;37:183–191.
4. OCT Sub-Study Committee for NORDIC Study Group, Auinger P, Durbin M, et al. Baseline OCT measurements in the idiopathic intracranial hypertension treatment trial, part I: quality control, comparisons, and variability. *Invest Ophthalmol Vis Sci*. 2014;55:8180–8188.
5. Aghsaei Fard M, Okhravi S, Moghimi S, Subramanian PS. Optic nerve head and macular OCT measurements in papilledema compared to pseudopapilledema [published online February 22, 2018]. *J Neuroophthalmol*. <https://doi.org/10.1097/WNO.0000000000000641>.
6. Akbari M, Abdi P, Fard MA, et al. Retinal ganglion cell loss precedes retinal nerve fiber thinning in nonarteritic anterior ischemic optic neuropathy. *J Neuroophthalmol*. 2016;36:141–146.
7. Spaide RF, Klancnik JM Jr, Cooney MJ. Retinal vascular layers imaged by fluorescein angiography and optical coherence tomography angiography. *JAMA Ophthalmol*. 2015;133:45–50.
8. Chen CL, Bojikian KD, Wen JC, et al. Peripapillary retinal nerve fiber layer vascular microcirculation in eyes with glaucoma and single-hemifield visual field loss. *JAMA Ophthalmol*. 2017;135:461–468.
9. Yarmohammadi A, Zangwill LM, Diniz-Filho A, et al. Peripapillary and macular vessel density in patients with glaucoma and single-hemifield visual field defect. *Ophthalmology*. 2017;124: 709–719.
10. Yarmohammadi A, Zangwill LM, Manalastas PIC, et al. Peripapillary and macular vessel density in patients with primary open-angle glaucoma and unilateral visual field loss. *Ophthalmology*. 2018;125:578–587.
11. Shoji T, Zangwill LM, Akagi T, et al. Progressive macula vessel density loss in primary open-angle glaucoma: a longitudinal study. *Am J Ophthalmol*. 2017;182:107–117.
12. Augstburger E, Zéboulon P, Keilani C, Baudouin C, Labbé A. Retinal and choroidal microvasculature in nonarteritic anterior ischemic optic neuropathy: an optical coherence tomography

- angiography study. *Invest Ophthalmol Vis Sci.* 2018;59:870–877.
13. Liu CH, Wu WC, Sun MH, Kao LY, Lee YS, Chen HS. Comparison of the retinal microvascular density between open angle glaucoma and nonarteritic anterior ischemic optic neuropathy. *Invest Ophthalmol Vis Sci.* 2017;58:3350–3356.
 14. Frisén L. Swelling of the optic nerve head: a staging scheme. *J Neurol Neurosurg Psychiatry.* 1982;45:13–18.
 15. Tan O, Chopra V, Lu AT, et al. Detection of macular ganglion cell loss in glaucoma by Fourier-domain optical coherence tomography. *Ophthalmology.* 2009;116:2305–2314.
 16. Gołębiowska J, Olechowski A, Wysocka-Mincewicz M, et al. Optical coherence tomography angiography vessel density in children with type 1 diabetes. *PLoS One.* 2017;12:e0186479.
 17. Coscas F, Sellam A, Glacet-Bernard A, et al. Normative data for vascular density in superficial and deep capillary plexuses of healthy adults assessed by optical coherence tomography angiography. *Invest Ophthalmol Vis Sci.* 2016;57:OCT211–223.
 18. Ying GS, Maguire MG, Glynn R, Rosner B. Tutorial on biostatistics: statistical analysis for correlated binary eye data. *Ophthalmic Epidemiol.* 2018;25:1–12.
 19. Choi J, Kwon J, Shin JW, Lee J, Lee S, Kook MS. Quantitative optical coherence tomography angiography of macular vascular structure and foveal avascular zone in glaucoma. *PLoS One.* 2017;12:e0184948.
 20. Lee EJ, Lee KM, Lee SH, Kim TW. OCT angiography of the peripapillary retina in primary open-angle glaucoma. *Invest Ophthalmol Vis Sci.* 2016;57:6265–6270.
 21. Fard MA, Suwan Y, Moghimi S, et al. Pattern of peripapillary capillary density loss in ischemic optic neuropathy compared to that in primary open-angle glaucoma. *PLoS One.* 2018;13:e0189237.
 22. Sehi M, Goharian I, Konduru R, et al. Retinal blood flow in glaucomatous eyes with single-hemifield damage. *Ophthalmology.* 2014;121:750–758.
 23. Kaup M, Plange N, Arend KO, Remky A. Retrobulbar haemodynamics in non-arteritic anterior ischaemic optic neuropathy. *Br J Ophthalmol.* 2006;90:1350–1353.
 24. Flahaty PM, Sergott RC, Lieb W, et al. optic nerve sheath decompression may improve blood flow in anterior ischemic optic neuropathy. *Ophthalmology.* 1993;100:297–305.
 25. Zhu W, Cui M, Yao F, et al. Retrobulbar and common carotid artery haemodynamics and carotid wall thickness in patients with non-arteritic anterior ischaemic optic neuropathy. *Graefes Arch Clin Exp Ophthalmol.* 2014;252:1141–1146.
 26. Hayreh SS. Ischemic optic neuropathy. *Prog Retin Eye Res.* 2009;28:34–62.
 27. Sharma S, Ang M, Najjar RP, et al. Optical coherence tomography angiography in acute non-arteritic anterior ischaemic optic neuropathy. *Br J Ophthalmol.* 2017;101:1045–1051.
 28. Balducci N, Morara M, Veronese C, et al. Optical coherence tomography angiography in acute arteritic and non-arteritic anterior ischemic optic neuropathy. *Graefes Arch Clin Exp Ophthalmol.* 2017;255:2255–2261.
 29. Arnold AC, Badr MA, Hepler RS. Fluorescein angiography in nonischemic optic disc edema. *Arch Ophthalmol.* 1996;114:293–298.
 30. Chen JJ, Thurtell MJ, Longmuir RA, et al. Causes and prognosis of visual acuity loss at the time of initial presentation in idiopathic intracranial hypertension. *Invest Ophthalmol Vis Sci.* 2015;56:3850–3859.
 31. Zhang M, Hwang TS, Campbell JP, et al. Projection-resolved optical coherence tomography angiography. *Biomed Opt Express.* 2016;7:816–828.