

Bone Morphogenetic Protein-2 Sustained Delivery by Hydrogels with Microspheres Repairs Rabbit Mandibular Defects

Wei-Yi Song^{1†}, Guo-Min Liu^{2†}, Juan Li^{1*}, Yun-Gang Luo^{3*}

¹College of Public Health, Jilin University, Changchun, Jilin, P R, China

²Department of Orthopedics, The Second Hospital of Jilin University, Changchun, Jilin, P R, China

³Department of Stomatology, The Second Hospital of Jilin University, Changchun, Jilin, P R, China

Mandible defect is a difficult issue in dental surgery owing to limited therapeutic options. Recombinant human bone morphogenetic protein-2 (rhBMP2) is osteoinductive in bone regeneration. This article prepared chitosan/collagen hydrogels with rhBMP2-incorporated gelatin microsphere (GMs) for a sustained release of rhBMP2 to induce bone regeneration in rabbits. In experiments, mandibular defects of 8 mm in diameter and 3 mm in depth were surgically prepared on the right cheek of 27 rabbits. Either chitosan/collagen hydrogels alone, rhBMP2-incorporated hydrogels, or hydrogels with rhBMP2-incorporated GMs were implanted to the defect sites. The animals were euthanized at 2, 6, 12 weeks following surgery. In results, scanning electronic microscope images revealed spherical GMs. The complex delivery systems, hydrogels with rhBMP2-incorporated GMs, exhibited ideal release profiles *in vitro*. The complex delivery systems resulted in apparent new bone formation within 12 weeks, as evidenced by computed tomography and histological observations. All these results demonstrated that the chitosan/collagen hydrogels with rhBMP2-incorporated GMs had a better capacity to heal mandible defects than other two hydrogel scaffolds. Chitosan/collagen hydrogels with rhBMP2-incorporated GMs might be potential carriers of rhBMP2 for accelerating the repair of mandibular defects.

Tissue Eng Regen Med 2016;13(6):750-761

Key Words: Bone morphogenetic protein-2; Bone substitutes; Dental implants; Microsphere; Hydrogel

INTRODUCTION

The treatment of mandibular defects resulting from accident, cysts, tumors, trauma, infection and fractures is an urgent issue for patients and a great challenge to orthopedic doctors [1]. Currently, the general method for repairing mandibular defects is autogenous bone graft with excellent osteoinductivity, osteoconductivity and osteogenicity, but cannot avoid a series of problems such as infection, hemorrhage, nerve damage, cosmetic disability, inadequate donor site and bone resorption after grafting [2]. To overcome these disadvantages, it is imperative to explore ef-

fective and convenient methods for treating mandibular defects. Bone tissue engineering has become an attractive and potential strategy for repairing mandibular defects utilizing three-dimensional (3D) scaffolds, different growth factors, and/or stem cells [3,4].

The combination of osteoinductive bone morphogenetic proteins (BMPs) and scaffolds might be used as a substitute to autogenous bone in reconstructive surgery. As a subgroup of the transforming growth factor- β superfamily, BMPs are a large group of proteins that induce osteoblasts differentiation and play pivotal roles in bone and cartilage regeneration [5]. Among BMPs, recombinant human BMP2 (rhBMP2) is one of the most potent osteoinductive growth factors and has been widely used in various orthopedic fields and dental therapeutic trials in clinic. The European Medicines Agency and US Food and Drug Administration have approved the clinical use of rhBMP2 in the placement of dental implants, alveolar bone augmentation and spinal fusion [6]. Although rhBMP2 proteins have apparent osteogenic effects, they always appear a burst-release at an early period and remarkable loss of activity *in vivo* due to their short

Received: December 10, 2015

Revised: February 17, 2016

Accepted: March 14, 2016

***Corresponding author:** Yun-Gang Luo, Department of Stomatology, The Second Hospital of Jilin University, 218 Ziqiang Street, Changchun, Jilin 130041, P R China.

Tel: 86-431 85612708, Fax: 86-431 85612708, E-mail: luoygjlu@sina.com

***Corresponding author:** Juan Li, College of Public Health, Jilin University, 828 Xinmin Street, Changchun, Jilin 130021, P R China.

Tel: 86-431 85619419, Fax: 86-431 85645486, E-mail: liuyedao123@163.com

[†]These authors contributed equally to this work.

half-lives when they are simply mixed with bone grafts. A series of scaffolds or carriers has been explored in the past decade, such as collagen gels, sponges, chitosan, dextran, hyaluronic acid, and fibrin scaffolds. These biomaterials can be used as the delivery systems with the prolonged release of BMP2 and/or an enhanced efficacy *in vivo* [7]. Moreover, these biomaterials can provide structural matrices maintaining BMP2 retention at the bone defect site. Therefore, using a suitable scaffold for carrying rhBMP2 may play an important role in bone regeneration.

Natural biomaterials chitosan and collagen, or their composites have been extensively used as efficient carriers of rhBMP2 because of their enzyme-regulatory degradation, biocompatibility, minimal foreign body reactions and osteoconductive ability [8,9]. Studies have indicated that incorporating BMP2 into chitosan/collagen hydrogels facilitates the prolonged activity and retention of rhBMP2 at the site of bone defects [10]. However, some limitations remain in the application of chitosan/collagen hydrogels because their low mechanical stability and fast degradation result in large initial burst release and short release periods. In addition, this formulation not only influences bone regeneration but also raises the concerns regarding pathological risk because the concentrations of BMP2 may exceed the physiological demands [11,12]. Therefore, we tend to introduce a new carrier of rhBMP2 in combination with chitosan/collagen hydrogels that reduce the amount of rhBMP2 delivered and enhance bone regeneration.

Microspheres have attracted much attention as the carrier of growth factors in recent years because they can be tailored for a desired release profile, and can be easily encapsulated or absorbed [13]. Gelatin has been extensively investigated for biomedical applications as a carrier of growth factors and antibiotics. Gelatin microspheres (GMs) have been reported to be ideal carriers for controlled release [14,15]. However, GMs migrate easily from the implant sites and their intrinsic brittleness does not provide good support for tissues. A combination of GMs and chitosan/collagen hydrogel scaffolds may provide sequential or prolonged release of rhBMP2.

The current study fabricated a sustained delivery system consisting of chitosan/collagen hydrogels and GMs for a sustained release of rhBMP2. GMs were embedded within chitosan/collagen hydrogels. The release kinetics of rhBMP2 from the hydrogel/GMs composites, and the morphology of GMs were investigated *in vitro*. A rabbit model of mandibular defect was created for evaluating the capacity to heal bone defects. We expected that the chitosan/collagen hydrogels with rhBMP2-incorporated GMs were superior delivery systems that promote mandibular repair *in vivo*.

MATERIALS AND METHODS

Materials

Chitosans (MW=1526 Da, 95% deacetylation) were denoted from Shanghai Alladin Co., Ltd. (Shanghai, China). rhBMP2 was kindly provided by Beijing ZhongKeWuYuan Biotechnology Co., Ltd. (98% purity; Beijing, China). BMP2 ELISA kit was purchased from R&D Systems (Minneapolis, MN, USA).

Preparation of chitosan/collagen hydrogels

Collagen type I was isolated from fresh rat tail tendon according the method of Rajan et al. [16]. Sterilized chitosan and collagen type I were dissolved in 0.1 mol/L and 0.02 mol/L acetic acid respectively, forming 2.0 wt% chitosan solutions and 5.0 mg/mL collagen solutions. Two solutions were mixed at a chitosan/collagen mass ratio of 1:1 on ice for 10 min. Beta-glycerophosphate (β -GP) was dissolved in distilled water, forming 60 wt% solutions, and filtered by $\Phi 0.22$ μ m membranes. Pre-cooled β -GP solutions were dripped into the chitosan/collagen mixture solutions at a volume ratio of 1:9. Then the mixture solutions were incubated at 37°C in syringes, forming cylindrical hydrogels of 8 mm diameter and 3 mm height. The mobility of chitosan/collagen solutions was monitored through inverting syringes, and the turbidity of the solutions from clear liquid to white-gray gels was also monitored for determining gel formation and gelation time [17].

Preparation of gelatin microspheres

GMs were prepared using a water-in-oil emulsion technique as referenced [14]. Briefly, 1.5 g gelatin powders were dissolved in 10 mL distilled water and heated up to 60°C. The gelatin solution was dripped into 100 mL olive oil containing 2 vol% Tween-80 at 50°C, with stirring at 450 rpm using a magnetic stirrer for 15 min, forming the water-in-oil (w/o) emulsion. Subsequently, the emulsion was chilled to 4°C with stirring at 450 rpm for 40 min, forming GMs. The GMs were extracted from olive oil by filtration and washed with precooled acetone and ethanol. The GMs were soaked in 5 wt% genipin solution at 4°C for 12 h for cross-linking. The crosslinked GMs were washed with deionized water and then suspended in 1% (W/V) glycine solutions at room temperature for 2 h for removing the free genipins. Finally, the GMs were freeze-dried overnight for use.

Fabrication of hydrogel scaffolds

Hydrogel scaffolds were fabricated under sterile conditions. Three types of hydrogel scaffolds were prepared. Chitosan/collagen hydrogels alone were prepared as above. The rhBMP2-incorporated chitosan/collagen hydrogels (hydrogels+rhBMP2) and chitosan/collagen hydrogels with rhBMP2-incorporated

GMs (hydrogels/GMs+rhBMP2) were prepared as follows. Briefly, 100 μ L of 0.5 mg/mL rhBMP2 in phosphate buffer were dripped onto 1 mg of dry GMs for absorption of rhBMP2 onto GMs by a charge-mediated diffusional loading as referenced [15,18]. Following vortexing, the rhBMP2-loaded GMs were incubated at 4°C overnight. Either 10 μ g rhBMP2 alone or GMs containing 10 μ g rhBMP2 were directly added into prepared chitosan/collagen mixture solutions on ice and vortexed. Then 60 wt% cold β -GP solutions were added drop-wise. The gel-forming solutions were allowed to become hydrogels at 37°C in syringes. All hydrogel scaffolds were gelled in syringes, forming cylindrical gels of 8 mm diameter and 3 mm height, and stored at 4°C for use. GMs+ rhBMP2, hydrogels+rhBMP2, and hydrogels/GMs+rhBMP2 were sputter-coated with gold and observed under a scanning electron microscope (XL-30, FEI, Hillsboro, OR, USA) in high-vacuum mode at 15 kV.

In vitro release studies

The rhBMP2 release profiles *in vitro* were investigated within a period of 4 weeks. The test groups were hydrogels+10 μ g rhBMP2, GMs+10 μ g rhBMP2, and hydrogels/GMs+10 μ g rhBMP2. These delivery systems were suspended in 2 mL of PBS (pH 7.4), and incubated at 37°C with shaking at 80 rpm for 4 weeks. At predetermined time points, 50 μ L of supernatants were harvested and then 50 μ L of fresh PBS (pH 7.4) was supplemented. The concentrations of released rhBMP2 in the harvests were detected using the rhBMP2 ELISA kit (R&D Systems, Shanghai, China). The cumulative release of rhBMP2 was computed.

Animal treatment

Thirty adult New Zealand white rabbits weighing 2.0–2.5 kg were obtained from the Experimental Animal Center of Jilin University. Animal experiments were approved by Jilin University Animal Ethics Committee (IACUC no. XS2014021514). Twenty-seven rabbits were randomly divided into three groups: chitosan/collagen hydrogels alone, hydrogels+rhBMP2, and hydrogels/GMs+rhBMP2. Each group contained 3 time points 2, 6, and 12 weeks, 3 rabbits for each time point. Three surgery-free rabbits were normal controls. During surgery, all test rabbits were anesthetized by intramuscular injection of xylazine hydrochloride at concentrations of 0.2–0.25 mL/kg. The mandibular skin was shaved, and a 20 mm-long incision was made to expose the mandible. Circular mandible defects of 8.0 mm diameter and 3.0 mm depth were created in the buccal-lingual direction on the right mandible of each rabbit as referenced [19], and the periosteum was removed. Subsequently, the defect sites were rinsed with 0.9% NaCl solution and filled with prepared hydrogel scaffolds. The defect sites were covered with bone wax. Fi-

nally the underlying musculature and skin were sutured. The operation procedure was recorded in Figure 1. After the surgery, all rabbits were caged individually, fed routinely under the same conditions and monitored for postoperative movements and wound healing. Eighty units of penicillin were injected intramuscularly daily for 3 days. All rabbits were sacrificed by ear vein air embolism at 2, 6 and 12 weeks respectively and right mandibles were harvested for examinations.

Computed tomography

Gross mandibular healing was monitored by Spiral CT (SIEMENS, Beijing, China) at 120 kV and 400 mA with FOV of 500 mm and reconstruction matrix 512 \times 512. After scanning, the original data were input into Siemens workstations for 3D reconstruction using Syngo software. Mandibular healing was monitored carefully by micro-computed tomography (GE Explore Locus SP micro-CT, GE Medical Systems, Shanghai, China). The conditions for micro-CT were set to 80 kV, 80 μ A, an integration time of 2960 ms, and an isotropic voxel size of 29 μ m for the scanning region. On micro-CT, all mandibular defect areas were measured to be 8 mm diameter and 3 mm depth and these defect areas were the regions of interest (ROI). 3D reconstruction on ROI was performed by using the MicroView software. ROI was analysed using the ABA analysis software to determine bone mineral density (BMD), bone mineral content (BMC), and bone volume fraction (BVF).

Histological staining

The harvested mandibular specimens were fixed in 10% neutral formaldehyde and rinsed by flowing water overnight. The specimens were decalcified in 5% nitric acid for 3 days, dehydrated through graded ethanol and embedded in paraffin. Specimens were sectioned into slices of 5 μ m thick. The paraffin-embedded slices were cleaned with xylene for 15 min and dyed using the hematoxylin & eosin (H&E) staining and the Masson's trichrome staining, respectively. Slices were observed under a microscope (TH4-200, Olympus, Tokyo, Japan). At least ten images were randomly captured for each slice. Two experienced histologists checked the transverse sections separately. The bone area fraction was analysed using image analysis software Image-ProPlus (Media Cybernetics, Rockville, MD, USA) and was expressed as a percentage (%) of the total tissue area.

Statistical analysis

All data were expressed as the mean \pm standard deviation. One-way ANOVA with Tukey post-hoc test was performed using the SPSS version 21.0 software package (SPSS Inc., Chicago, IL, USA). Differences were considered significantly at the level of $p < 0.05$.

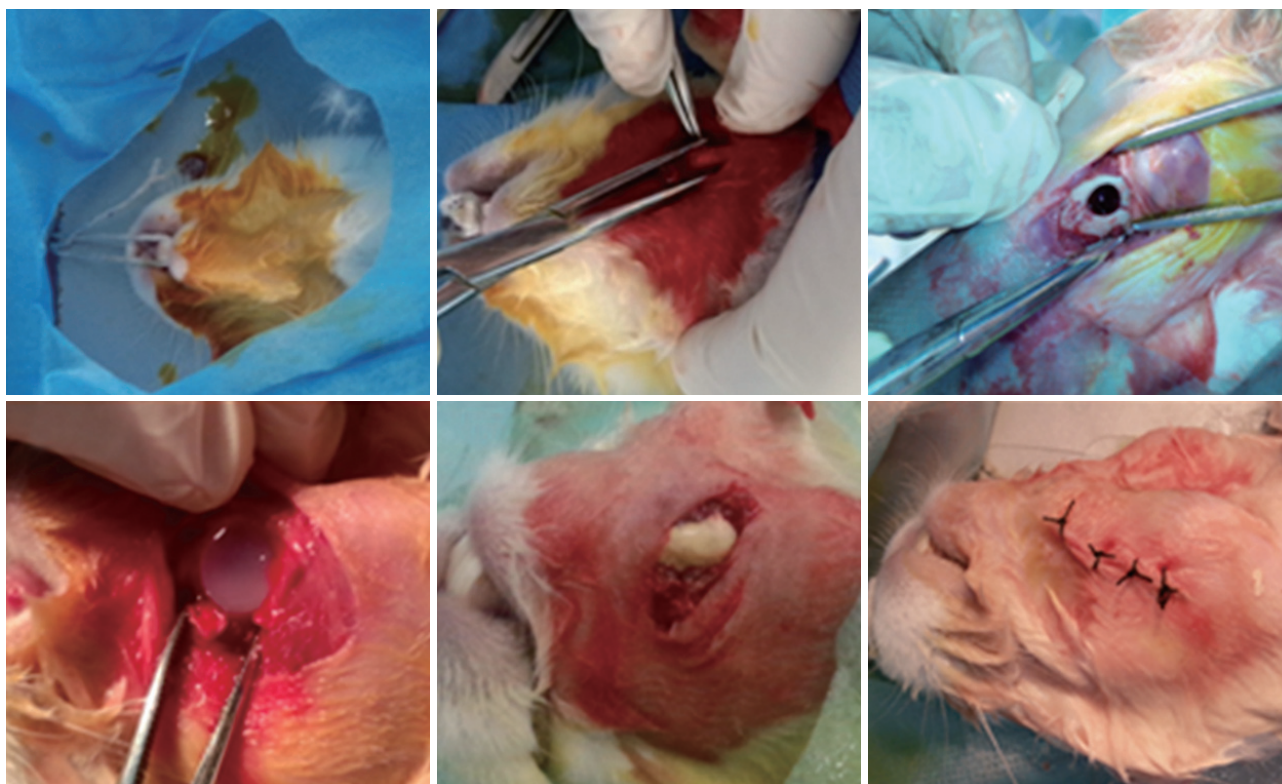


Figure 1. The surgical procedures.

RESULTS

Fabrication of gelatin microspheres and chitosan/collagen hydrogels

The optical microscopic images showed the non-cross-linked GMs (Fig. 2A) and cross-linked GMs (Fig. 2B). GMs were spherical under SEM (Fig. 2C). Sizes of GMs were 50–150 μm . Their polyporous surfaces could be resulted from dehydration process because GMs needed to be dehydrated during SEM sample preparation. The prepared hydrogels/GMs+rhBMP2 were shown in Figure 2D and E. SEM showed that their surfaces were full of interconnected micropores (Fig. 2F), illustrating that many spherical GM granules distributed uniformly throughout the porous chitosan/collagen hydrogels.

In vitro release of rhBMP2

The *in vitro* release behaviors of rhBMP2 were interpreted as the percentage cumulative release of rhBMP2 over time (Fig. 3). The hydrogels+rhBMP2 group showed remarkably initial burst releases in first 7 days (68.74%), and then 88.11% cumulative releases were achieved in 30 days. Burst releases in the early stage were also observed in the GMs+rhBMP2 group, followed by continuous releases. The amount of rhBMP2 released from GMs in the initial 7 days was 50.65%, and 86.47% until 30 days.

The release rate of rhBMP2 from GMs+rhBMP2 was lower than that from hydrogels+rhBMP2. The hydrogels/GMs+rhBMP2 group showed minimal burst releases in 7 days, followed by moderate releases in 30 days.

CT analysis

Gross bone healing was monitored by Spiral CT (Fig. 4A, B, and C). There were no signs of bone formation in three groups at 2 weeks after the surgery. The hydrogels alone group formed minimal new bones along the defect edges at 6 weeks. At 12 weeks, edges of bone defects did not bridge completely (Fig. 4A). In the hydrogels+rhBMP2 group, good bone repair was seen as early as 6 weeks, but bone defects seemed not to heal completely at 12 weeks (Fig. 4B). The hydrogels/GMs+rhBMP2 group was seen maximal bone formation bridging the defect areas at 6 weeks, and the mandibular defects seemed to be almost completely repaired at 12 weeks (Fig. 4C).

New bones were also scanned by micro-CT. 3D-reconstructed ROI at 12 weeks were shown in Figure 5. Upon the hydrogels/GMs+rhBMP2 group, substantially plate-like bone structures were seen in the center of the ROI at 12 weeks, and the plate-like bone structures expanded to fill the mandibular defects (Fig. 5A- a, b and c). In the hydrogels+rhBMP2 group, more than half of the bone defect areas were filled at 12 weeks




Figure 2. Photographs of non-crosslinked GMs (A), cross-linked GMs (B). SEM photographs of dehydrated GMs (C). Chitosan/collagen mixtures are liquid at room temperature (D), and form hydrogels at 37°C (E). SEM photographs of the hydrogels (F). GMs: gelatin microspheres, SEM: scanning electron microscopy.

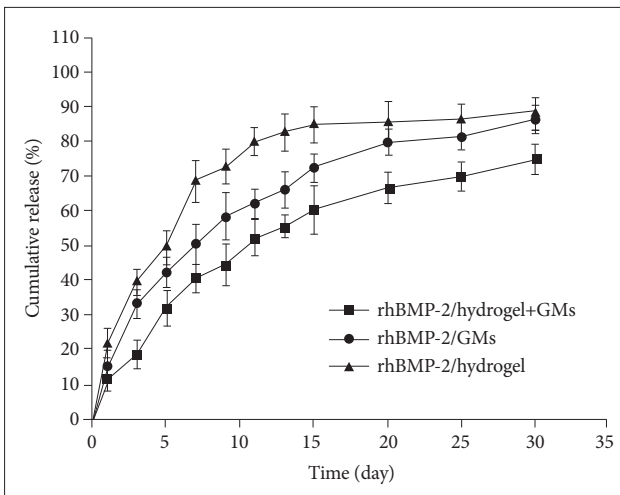


Figure 3. *In vitro* cumulative release profiles of rhBMP-2 from three scaffolds pattern in PBS for 30 days. The cumulative release amounts of rhBMP-2 from the scaffolds were determined as a function of time by rhBMP-2 ELISA kits at 450 nm. Each value represents the mean±SD (n=3). rhBMP-2: recombinant human bone morphogenic protein-2, PBS: phosphate buffer saline, ELISA: enzyme-linked immunosorbent assay.

(Fig. 5B- d, e and f), more trabecular bone formations were found compared with the hydrogels alone group (Fig. 5C- g, h and i). In the hydrogels alone group, only few mature bone trabeculae and less regenerated bones were seen along the defect sites, and only about 1/3 of the defect areas were filled at 12 weeks (Fig. 5C- g, h and i).

New bones in ROI scanned by micro-CT were quantitatively

characterized at each healing period (Fig. 6). BMC referred to the total BMC in ROI, BVF referred to the ratio of the bone volume and total volume (BV/TV) in ROI, and BMD denoted the ratio of BMC to ROI volume. BMCs at 2, 6, and 12 weeks were compared among three groups (Fig. 6A). Small amount of BMCs in the hydrogels alone group was found at different time periods, with unsatisfied new bone formations, indicating slow repair because of absent induction of growth factors. Relatively high BMCs of both the hydrogels+rhBMP2 and hydrogels/GMs+rhBMP2 groups at each point were observed compared with the hydrogels alone group. At 12 weeks, the BMCs for the hydrogels alone, hydrogels+rhBMP2 and hydrogels/GMs+rhBMP2 groups were 34.59 ± 6.2 , 49.34 ± 4.89 , and 57.29 ± 3.2 mg, respectively. At 12 weeks, the ratio BV/TV, as an indicator of the relative amount of newly-formed bones, was significantly higher in the hydrogels/GMs+rhBMP2 group than other two groups respectively (Fig. 6B). The conditions of BMDs at 12 weeks were consistent with those in BMCs, the lowest in the hydrogels alone group, the highest in hydrogels/GMs+rhBMP2 group (Fig. 6C). These results indicated that the hydrogels/GMs+rhBMP2 complex delivery systems benefited bone generations in the defect areas, and had obvious effects on promoting osteogenesis.

Histological analysis

Newly formed bone tissues in the mandible defects were analysed by the H&E staining (representative images in Fig. 7) and

the Masson's trichrome staining (representative images in Fig. 8). At least ten images were randomly captured for each slice. Separately two experienced histologists checked the transverse sections surrounding the implants (Figs. 7 and 8) and measured the bone area fractions (Fig. 9). The histological bone regeneration chronologically was scaffold materials>fibrous tissues>chondrocytes>woven or loose newly-formed bones>mature lamellar new bones, that was to say, large areas of lamellar new bones would indicate good bone regeneration.

Upon the hydrogels alone group, the scaffold implants were found to be surrounded by fibrous tissues, and scaffolds were easily observed at 2 weeks (Fig. 7A-a); only partially new cartilagi-

nous tissues and few loose new bones could be observed, and the hydrogels were degraded at 6 weeks (Fig. 7A-b); large vacancies consisting of fibrous tissues were still observed evidently in the center of mandibular defects at 12 weeks (Fig. 7A-c). Compared with hydrogels alone, hydrogels+rhBMP2 had better effects on promoting newly-formed bones at each point. At 2 weeks, the newly-formed bones consisting of woven bones were observed in loose fibrous tissues (Fig. 7B-d). At 6 weeks, mature lamellar bones transformed from primary bone trabecula were observed, but few ingrowths of new bones could be observed, and a small amount of scaffold residuals that had not degraded could be observed still (Fig. 7B-e). At 12 weeks, scaffolds were

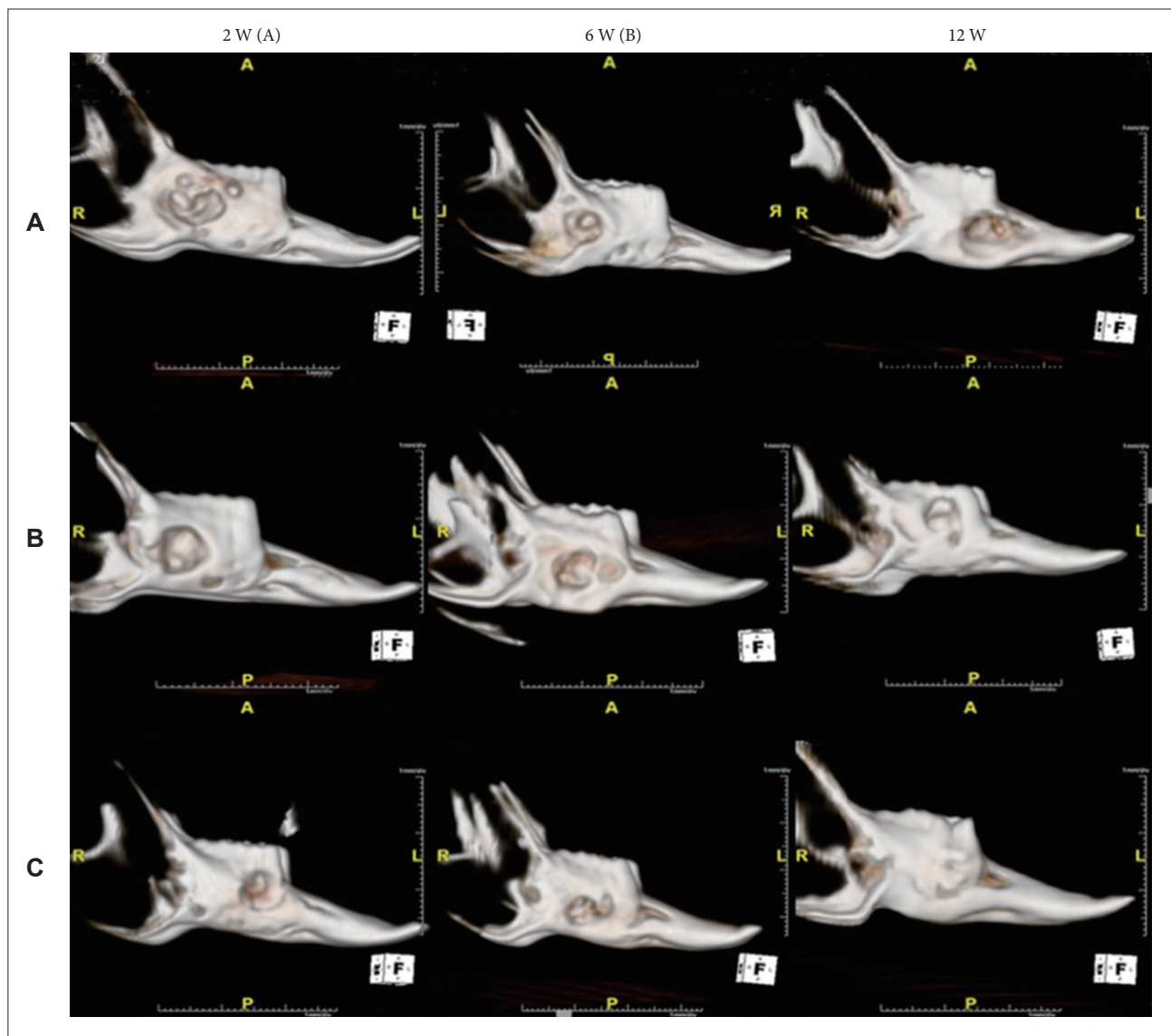


Figure 4. Representative images of three-dimensional CT reconstruction of the mandible bone at the different stages. (A) Hydrogel alone. (B) Hydrogels+rhBMP2. (C) Hydrogels/GMs+rhBMP2. rhBMP2: recombinant human bone morphogenic protein-2, GMs: gelatin microspheres.

degraded completely that leave large vacancies, no fibrous tissues were observed, and mature lamellar bones were seen (Fig. 7C-f). Hydrogels/GMs+rhBMP2 had the densest arrays of trabecular bones among three groups at each time period (Fig. 7C-g to -i), and new bones seemed greater than the hydrogels+rhBMP2 group at 2 weeks; at 6 weeks, plenty of lamellar bones appeared, and hydrogel scaffolds were surrounded by fibrous tissues, indicating the acceleration of bone regeneration. At 12 weeks, along with the reconstruction process, the trabecular bones tend to mature into dense lamellar bones, and vacancies derived from completely degraded scaffolds were occupied by

in-growths of lamellar bones.

The Masson's trichrome staining images confirmed these results further (Fig. 8A-I). For instance, in the hydrogels alone group at 12 weeks, the mandibular defects remained unhealed in a large area, vacancies were still visible and new cartilaginous tissues were observed at the outer edge of the lamellar bones (Fig. 8A-c), illustrating the imperfect transformation from the new bones to mature bones. As to the hydrogels+rhBMP2 and hydrogels/GMs+rhBMP2 groups at 12 weeks, Obvious degradation of biomaterials was observed, a large amount of newly-formed bones with mature trabecular bones was found, and the

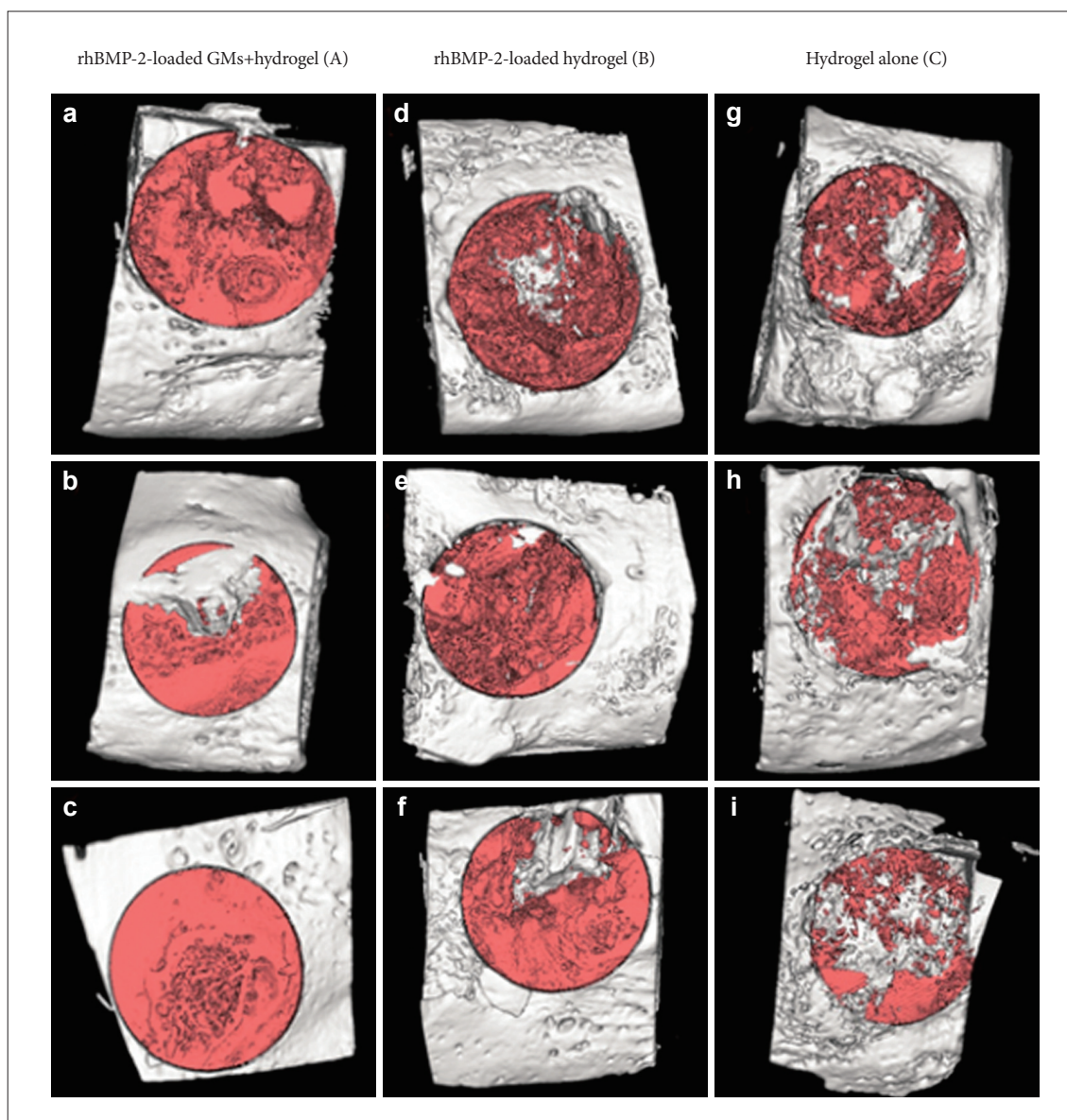


Figure 5. Micro-computed tomography images of the bone regeneration in mandibular defects of rabbits at 12 weeks. Mandibular defects were treated with hydrogels/GMs+rhBMP2 (A, a to c), hydrogels+rhBMP2 (B, d to f), and hydrogels alone (C, g to i). Region of interest was set as the volume of the original surgical defects that measured 8×8 (diameter)×3 (depth) mm for all specimens (n=3). rhBMP2: recombinant human bone morphogenic protein-2, GMs: gelatin microspheres.

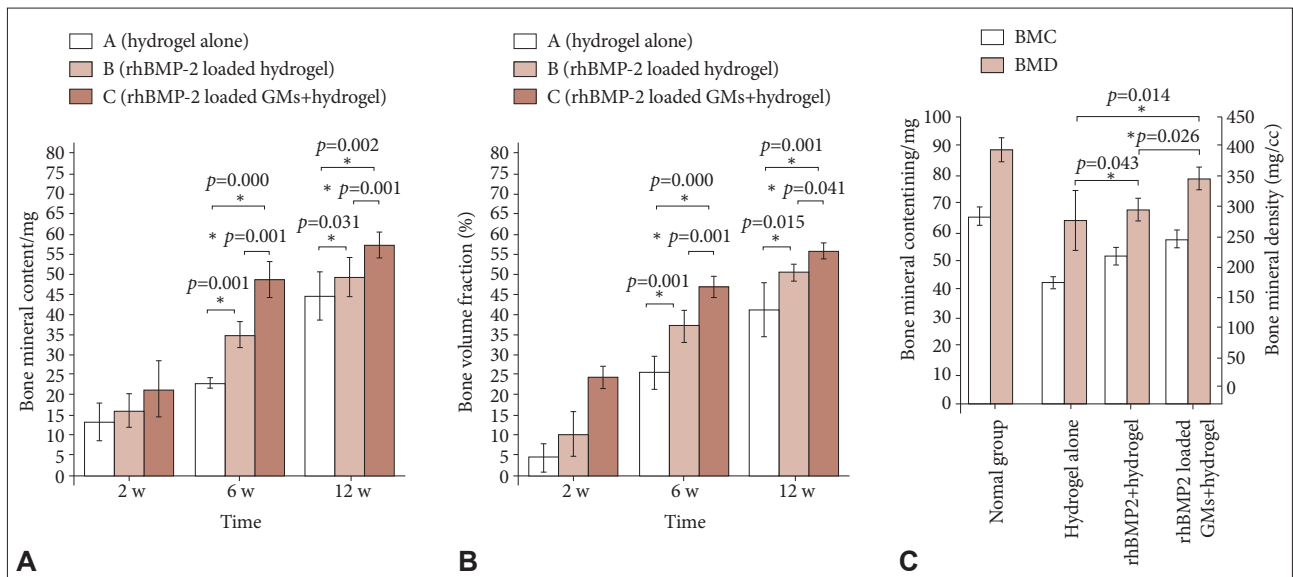


Figure 6. Quantitative micro-computed tomographic data of mandibular bone formation with different implants. (A) The bone mineral content (BMC) of three groups at different stages of bone reconstruction process. (B) The bone volume fraction (BV/TV) of three groups at different stages. (C) BMC and BMD of three groups at 12 weeks. * $p < 0.05$, significant differences were found. rhBMP2: recombinant human bone morphogenic protein-2, GMS: gelatin microspheres, BMD: bone mineral density.

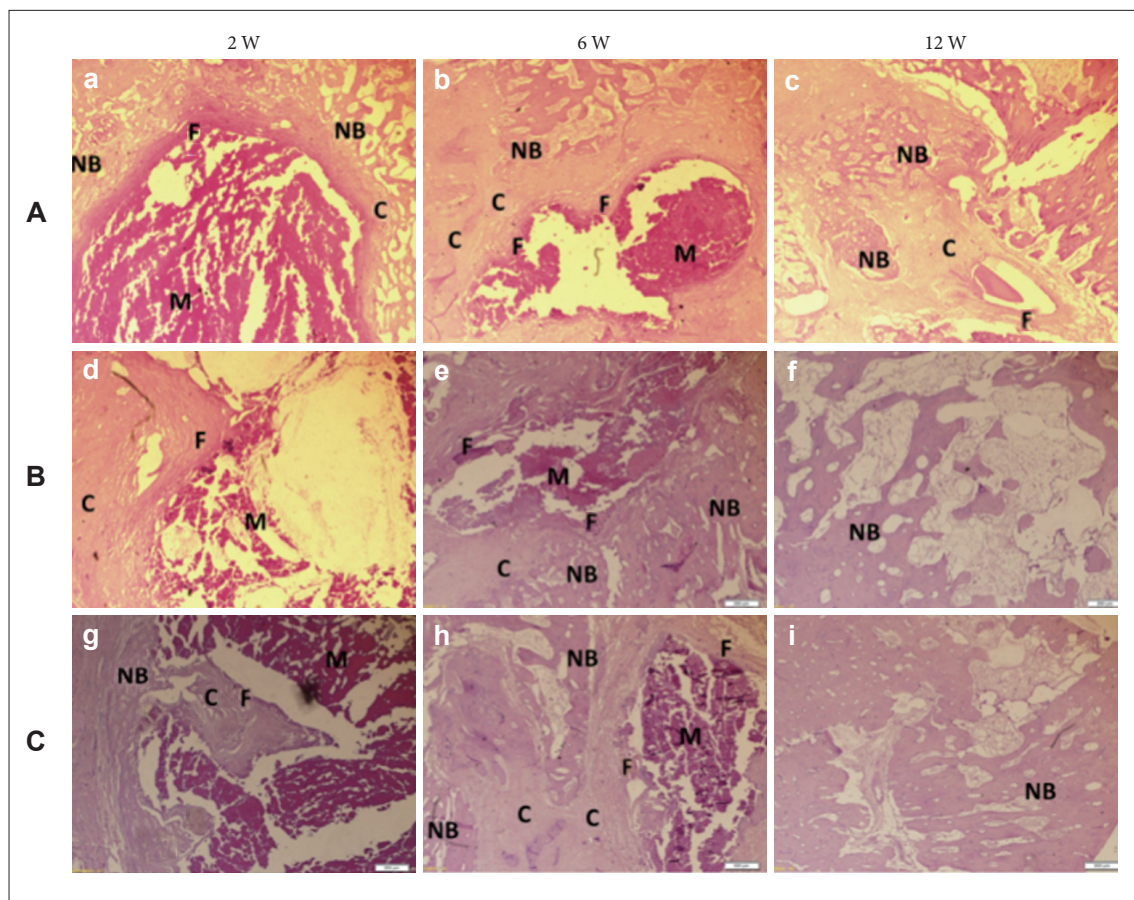


Figure 7. Representative H&E staining micrographs (a to i) of bone defect area at 2, 6, 12 weeks. A (a to c): hydrogels/GMS+rhBMP2, B (d to f): hydrogels+rhBMP2, C (g to i): hydrogels alone. Scale bar: 100 μ m. GMS: gelatin microspheres, rhBMP2: recombinant human bone morphogenic protein-2, NB: new bones, C: chondrocytes, M: scaffold materials, F: fibrous tissues.

large blue areas revealed the formation of mature bones (Fig. 8B-f, 8C-i). In particular, densely lamellar bones were arrayed regularly in the hydrogels/GMs+rhBMP2 group, and a large proportion of mandibular defects were occupied by the newly-formed bones (Fig. 8C-i). Newly-formed bone area fractions at 12 weeks were quantitatively measured on the histological slices (Fig. 9). The hydrogels/GMs+rhBMP2 group had larger bone areas than the hydrogels/GMs+rhBMP2 group, and the latter larger than the hydrogel alone group.

By summarized the results of micro-CT and histological staining, the degree of bone healing and quality of newly-formed bones were related to the treatment by an order: hydrogels/GMs+rhBMP2>hydrogels+rhBMP2>hydrogel alone.

DISCUSSION

BMPs have been reported to be effective in bone formation in a variety of animal studies. Among the BMPs, rhBMP2 has the strongest and most marked biological activities [20]. In the current study, rhBMP2 was used to repair mandibular bone defects because of its strong osteoinductive properties in bone regeneration. However, rhBMP2 has a short biological half-life *in vivo* due to rapid degradation and deactivation by enzymes as well as other chemical or physical reactions [21,22]. A large number of local delivery carriers, especially natural polymers, have been developed for the controlled and sustained release of rhBMP2. Several pharmaceutical studies have shown that chitosan/collagen hydrogels can serve as useful vehicles for controlled release of drugs because of their biocompatibility, biodegradability, and

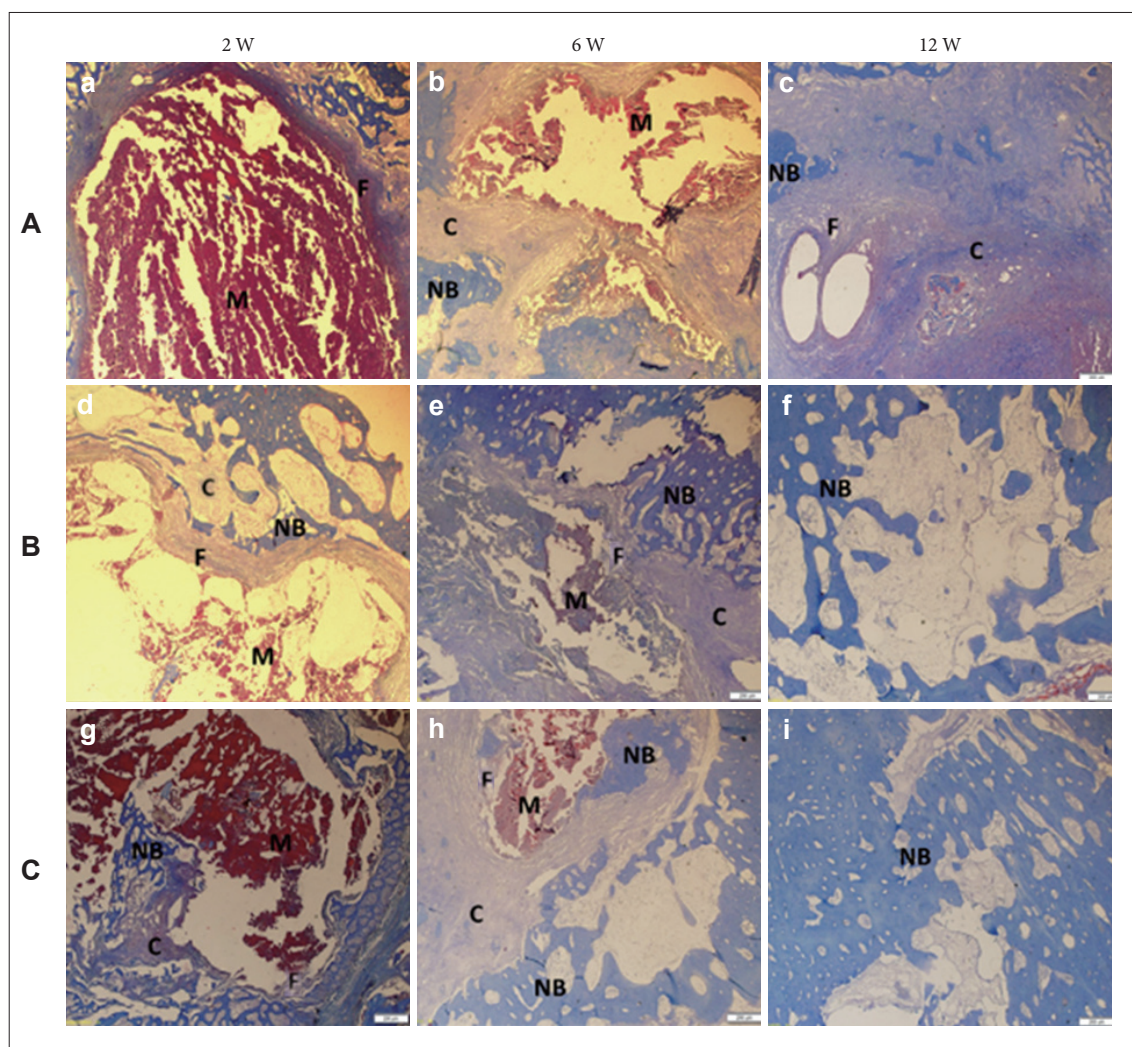


Figure 8. Representative Masson staining images (a to i) of bone defect area at 2, 6, 12 weeks. A (a to c): hydrogels/GMs+rhBMP2, B (d to f): hydrogels+rhBMP2, C (g to i): hydrogels alone. Scale bar: 100 μ m. GMs: gelatin microspheres, rhBMP2: recombinant human bone morphogenic protein-2, NB: new bones, C: chondrocytes, M: scaffold materials, F: fibrous tissues.

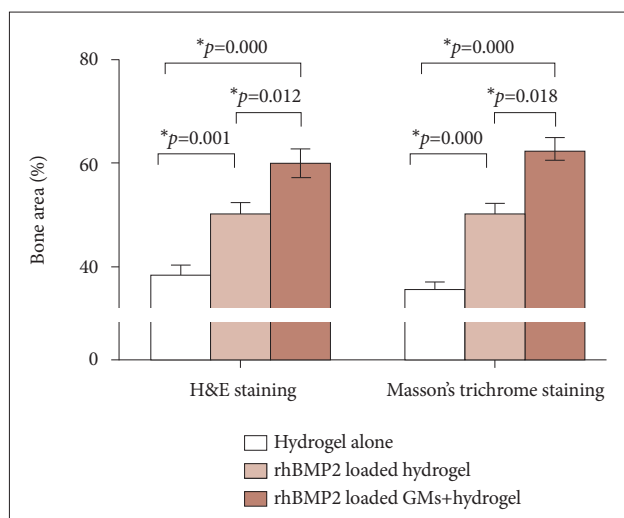


Figure 9. Bone area fractions of histological staining at 12 weeks. rhBMP2: recombinant human bone morphogenic protein-2, GMs: gelatin microspheres. * $p < 0.05$, significant differences were found.

osteoconductive ability. But the initial burst release of rhBMP2 is not beneficial for bone healing [3,10,12]. Therefore, there is a great need for drug delivery systems with features of improved release kinetics of rhBMP2 in order to enhance therapeutic efficacy.

GMs have been testified to be ideal carriers for delivery of many growth factors due to their good ability to encapsulate more drugs and characteristics of sustained release [14]. Previous studies have shown that GMs have adequate porosities that allow higher absorbability [22-24]. In the current study, GMs were prepared as referenced to the literature [14], providing the possibility that use GMs as delivery carriers of rhBMP2. However, GMs alone are difficult to apply as bone fillers in the treatment of mandibular defects because of the intrinsic brittleness and fast degradation [25]. Furthermore, sustained delivery vehicles should have diverse roles during bone formation *in vivo*. As maintaining local drug concentrations at sufficient levels over time, the implants should also provide mechanically stable and biodegradable frameworks that enhance cell migration, attachment, and differentiation [15,26,27]. Therefore, we encapsulated GMs+rhBMP2 into chitosan/collagen hydrogels in the current study. Chitosan/collagen hydrogels not only were used to bind the GMs and kept them at the implant sites, but also modified the release behavior. Our results indicated that the hydrogels/GMs+rhBMP2 group exhibited minimal burst release, while the GMs+rhBMP2 group resulted in a noticeable initial burst release (Fig. 3). In view of the information mentioned above, the hydrogels/GMs+rhBMP2 scaffolds were the optimal delivery systems of rhBMP2 in the current study. Subsequent animal studies illustrated that the hydrogels/GMs+rhBMP2 did possess osteoinductive properties, and the rhBMP2 releasing from the scaffolds still maintained their bioactivity [28].

As shown in Figure 6A-C, the hydrogels+rhBMP2 and hydrogels/GMs+rhBMP2 groups showed higher BMC, BV/TV, and BMD compared with hydrogels alone. This might imply an increasing retention of rhBMP2 at the defect sites to help the new bone formation as reported in the literature [29]. As the results of 3D micro-CT, the rates of new bone formation were higher in the hydrogels/GMs+rhBMP2 group than the hydrogels+rhBMP2 group or the hydrogels alone group. Therefore, it was likely that the lower burst release and prolonged retention of rhBMP2 was partially responsible for the enhanced osteoinductive capacity [7].

Chitosan/collagen hydrogels have been considered the promising candidates for bone tissue engineering because of their excellent biocompatibility with the human body [12,30]. In the current study, chitosan/collagen hydrogels showed good tissue compatibility when hydrogels/GMs+rhBMP2 were implanted in defect sites in rabbits. Chitosan/collagen hydrogels were surrounded by fibrous connective tissues without adverse reaction at 2 and 6 weeks after implantation. Subsequently, these materials were degraded and replaced well by newly-formed bones in a large proportion (Figs. 7 and 8). From the histological observations, the degradation of these materials matched the tissue in-growth at the defect sites. Moreover, histological observations indicated that neither the materials nor their degradation provoked inflammation or toxicity [20,29,31].

Recent studies have shown that rhBMP2 proteins play important roles in bone formation during early and late periods, from the migration of mesenchymal stem cells to differentiation of osteoblasts. Therefore, it is important to investigate the effects of rhBMP2 at different stages of bone healing and optimize its release behavior. The current data suggested that chitosan/collagen hydrogels with GMs were potential carriers for the delivery of rhBMP2 to accelerate bone regeneration.

The current study had problems to be discussed. A size of bone defect that cannot heal spontaneously is termed a critical size defect (CSD). Studies have suggested that 15 mm is the lower limit for a CSD of mandible in rabbits as the periosteum is removed [32]. Even the CSD of mandible in rabbits should be larger 20 mm [33]. The 8 mm diameter defect in the current study was smaller than a CSD. Considering that dental surgery needs small-size implants, a size of 8 mm diameter may be suitable. In fact, Xu et al. [19] have reported an individual case in 2015 that a circular CSD of 8 mm diameter in rabbit mandible is repaired by electrospun gelatin/ β -TCP composite nanofibrous membranes. Our current study followed the operation in this literature [19]. At the same time, the spontaneous healing capacity had been tested in our preliminary experiments that a mandible defect of 8 mm diameter and 3 mm depth in rabbits healed about 25% determined by micro-CT at a time period of 12 weeks

(data not shown). Nevertheless, one notable limitation of the current study was the absence of immediate control group to consider the spontaneous healing capacity. Another limitation of the current study was only 3 samples in each group. More repeated samples should be included to make a statistical significance powerful in the next study.

In addition, the current modeling defects were made on the ramus area of the mandible in rabbits. Clinically, bone grafting is generally performed in the alveolar ridge for functional restoration [34,35]. Exactly, the ramus is an area that is normally used as a donor site for harvest of block bone, and is well-known to heal spontaneously. From this perspective, many efforts should be made prior to the clinic application of chitosan/collagen hydrogels with rhBMP2-incorporated GMs prepared in the current study. However, a comparative study, regardless of defect site or size, can also provide some hints that chitosan/collagen hydrogels with rhBMP2-incorporated GMs benefited bone repair than other two hydrogel scaffolds.

In conclusions, chitosan/collagen hydrogels with rhBMP2-incorporated GMs exhibited an ideal releasing profile of rhBMP2 *in vitro*. These composite scaffolds had a better capacity to heal mandible defects than other two hydrogel scaffolds. Chitosan/collagen hydrogels with rhBMP2-incorporated GMs might be potential carriers of rhBMP2 for accelerating the repair of bone defects.

Conflicts of Interest

The authors have no financial conflicts of interest.

Ethical Statement

This study was approved by Jilin University Animal Ethics Committee (IACUC no. XS2014021514).

REFERENCES

- Cheng G, Li Z, Wan Q, Lv K, Li D, Xing X, et al. A novel animal model treated with tooth extraction to repair the full-thickness defects in the mandible of rabbits. *J Surg Res* 2015;194:706-716.
- Li ZJ, Lu CT, Feng ZQ, Zhao QT, Zhou ZY, Lai RF. Antigen-extracted xenogeneic cancellous bone graft with recombinant human bone morphogenetic protein-2 enhances bone regeneration in repair of mandibular defect in rabbits. *Kaohsiung J Med Sci* 2015;31:18-25.
- Yun YP, Lee SY, Kim HJ, Song JJ, Kim SE. Improvement of osteoblast functions by sustained release of bone morphogenetic protein-2 (BMP-2) from heparin-coated chitosan scaffold. *Tissue Eng Regen Med* 2013;10:183-191.
- Sun B, Ma W, Su F, Wang Y, Liu J, Wang D, et al. The osteogenic differentiation of dog bone marrow mesenchymal stem cells in a thermo-sensitive injectable chitosan/collagen/ β -glycerophosphate hydrogel: *in vitro* and *in vivo*. *J Mater Sci Mater Med* 2011;22:2111-2118.
- Luca L, Rougemont AL, Walpoth BH, Boure L, Tami A, Anderson JM, et al. Injectable rhBMP-2-loaded chitosan hydrogel composite: osteoinduction at ectopic site and in segmental long bone defect. *J Biomed Mater Res A* 2011;96:66-74.
- Jung UW, Lee IK, Park JY, Thoma DS, Hämmerle CH, Jung RE. The efficacy of BMP-2 preloaded on bone substitute or hydrogel for bone regeneration at peri-implant defects in dogs. *Clin Oral Implants Res* 2015;26:1456-1465.
- Liu X, Zhao K, Gong T, Song J, Bao C, Luo E, et al. Delivery of growth factors using a smart porous nanocomposite scaffold to repair a mandibular bone defect. *Biomacromolecules* 2014;15:1019-1030.
- Mirahmadi F, Tafazzoli-Shadpour M, Shokrgozar MA, Bonakdar S. Enhanced mechanical properties of thermosensitive chitosan hydrogel by silk fibers for cartilage tissue engineering. *Mater Sci Eng C Mater Biol Appl* 2013;33:4786-4794.
- Ding K, Yang Z, Zhang YL, Xu JZ. Injectable thermosensitive chitosan/ β -glycerophosphate/collagen hydrogel maintains the plasticity of skeletal muscle satellite cells and supports their *in vivo* viability. *Cell Biol Int* 2013;37:977-987.
- Yun YP, Yang DH, Kim SW, Park K, Ohe JY, Lee BS, et al. Local delivery of recombinant human bone morphogenetic protein-2 (rhBMP-2) from rhBMP-2/heparin complex fixed to a chitosan scaffold enhances osteoblast behavior. *Tissue Eng Regen Med* 2014;11:163-170.
- Huang H, Zhang X, Hu X, Dai L, Zhu J, Man Z, et al. Directing chondrogenic differentiation of mesenchymal stem cells with a solid-supported chitosan thermogel for cartilage tissue engineering. *Biomed Mater* 2014;9:035008.
- Yunoki S, Ohyabu Y, Hatayama H. Temperature-responsive gelation of type I collagen solutions involving fibril formation and genipin cross-linking as a potential injectable hydrogel. *Int J Biomater* 2013;2013:620765.
- Yang IA, Fong KM, Sim EH, Black PN, Lasserson TJ. Inhaled corticosteroids for stable chronic obstructive pulmonary disease. *Cochrane Database Syst Rev* 2007;(2):CD002991.
- Kodali A, Lim TC, Leong DT, Tong YW. Cell-microsphere constructs formed with human adipose-derived stem cells and gelatin microspheres promotes stemness, differentiation, and controlled pro-angiogenic potential. *Macromol Biosci* 2014;14:1458-1468.
- Kim S, Kang Y, Krueger CA, Sen M, Holcomb JB, Chen D, et al. Sequential delivery of BMP-2 and IGF-1 using a chitosan gel with gelatin microspheres enhances early osteoblastic differentiation. *Acta Biomater* 2012;8:1768-1777.
- Rajan N, Habermehl J, Coté MF, Doillon CJ, Mantovani D. Preparation of ready-to-use, storable and reconstituted type I collagen from rat tail tendon for tissue engineering applications. *Nat Protoc* 2006;1:2753-2758.
- Wang L, Stegemann JP. Thermogelling chitosan and collagen composite hydrogels initiated with beta-glycerophosphate for bone tissue engineering. *Biomaterials* 2010;31:3976-3985.
- Patel ZS, Yamamoto M, Ueda H, Tabata Y, Mikos AG. Biodegradable gelatin microparticles as delivery systems for the controlled release of bone morphogenetic protein-2. *Acta Biomater* 2008;4:1126-1138.
- Xu M, Zhang X, Meng S, Dai X, Han B, Deng X. Enhanced critical size defect repair in rabbit mandible by electrospun gelatin/ β -TCP composite nanofibrous membranes. *J Nanomater* 2015;2015:1-9.
- Kim J, Yang HJ, Cho TH, Lee SE, Park YD, Kim HM, et al. Enhanced regeneration of rabbit mandibular defects through a combined treatment of electrical stimulation and rhBMP-2 application. *Med Biol Eng Comput* 2013;51:1339-1348.
- Srouji S, Rachmiel A, Blumenfeld I, Livne E. Mandibular defect repair by TGF-beta and IGF-1 released from a biodegradable osteoconductive hydrogel. *J Craniomaxillofac Surg* 2005;33:79-84.
- Hou J, Wang J, Cao L, Qian X, Xing W, Lu J, et al. Segmental bone regeneration using rhBMP-2-loaded collagen/chitosan microspheres composite scaffold in a rabbit model. *Biomed Mater* 2012;7:035002.
- Zamora DO, Natesan S, Christy RJ. Constructing a collagen hydrogel for the delivery of stem cell-loaded chitosan microspheres. *J Vis Exp* 2012;(64):e3624.

24. Dreifke MB, Ebraheim NA, Jayasuriya AC. Investigation of potential injectable polymeric biomaterials for bone regeneration. *J Biomed Mater Res A* 2013;101:2436-2447.
25. Yao L, Phan F, Li Y. Collagen microsphere serving as a cell carrier supports oligodendrocyte progenitor cell growth and differentiation for neurite myelination in vitro. *Stem Cell Res Ther* 2013;4:109.
26. Niu X, Feng Q, Wang M, Guo X, Zheng Q. Porous nano-HA/collagen/PLLA scaffold containing chitosan microspheres for controlled delivery of synthetic peptide derived from BMP-2. *J Control Release* 2009;134:111-117.
27. Li W, Lan Y, Guo R, Zhang Y, Xue W, Zhang Y. In vitro and in vivo evaluation of a novel collagen/cellulose nanocrystals scaffold for achieving the sustained release of basic fibroblast growth factor. *J Biomater Appl* 2015;29:882-893.
28. Yao AH, Li XD, Xiong L, Zeng JH, Xu J, Wang DP. Hollow hydroxyapatite microspheres/chitosan composite as a sustained delivery vehicle for rhBMP-2 in the treatment of bone defects. *J Mater Sci Mater Med* 2015; 26:5336.
29. Wu Y, Hou J, Yin M, Wang J, Liu C. Enhanced healing of rabbit segmental radius defects with surface-coated calcium phosphate cement/bone morphogenetic protein-2 scaffolds. *Mater Sci Eng C Mater Biol Appl* 2014;44:326-335.
30. Gao L, Gan H, Meng Z, Gu R, Wu Z, Zhang L, et al. Effects of genipin cross-linking of chitosan hydrogels on cellular adhesion and viability. *Colloids Surf B Biointerfaces* 2014;117:398-405.
31. Moroi A, Ueki K, Okabe K, Marukawa K, Sotobori M, Mukozawa A, et al. Comparison between unsintered hydroxyapatite/poly-L-lactic acid mesh and titanium mesh in bone regeneration of rabbit mandible. *Implant Dent* 2013;22:255-262.
32. Huh JY, Choi BH, Kim BY, Lee SH, Zhu SJ, Jung JH. Critical size defect in the canine mandible. *Oral Surg Oral Med Oral Pathol Oral Radiol Endod* 2005;100:296-301.
33. Alfotawei R, Naudi KB, Lappin D, Barbenel J, Di Silvio L, Hunter K, et al. The use of TriCalcium Phosphate (TCP) and stem cells for the regeneration of osteoperiosteal critical-size mandibular bony defects, an in vitro and preclinical study. *J Craniomaxillofac Surg* 2014;42:863-869.
34. Wikesjö UM, Guglielmoni P, Promsudthi A, Cho KS, Trombelli L, Selvig KA, et al. Periodontal repair in dogs: effect of rhBMP-2 concentration on regeneration of alveolar bone and periodontal attachment. *J Clin Periodontol* 1999;26:392-400.
35. Wikesjö UM, Susin C, Qahash M, Polimeni G, Leknes KN, Shanaman RH, et al. The critical-size supraalveolar peri-implant defect model: characteristics and use. *J Clin Periodontol* 2006;33:846-854.