

# The role of protein p16<sup>INK4a</sup> in non-oropharyngeal head and neck squamous cell carcinoma in Southern China

HANG YANG<sup>1,2\*</sup>, YE CAO<sup>1,3\*</sup>, ZHI-MING LI<sup>1,2</sup>, YA-JUN LI<sup>4,5</sup>, WEN-QI JIANG<sup>1,2\*</sup> and YAN-XIA SHI<sup>1,2\*</sup>

<sup>1</sup>Collaborative Innovation Center for Cancer Medicine, State Key Laboratory of Oncology in South China; <sup>2</sup>Department of Medical Oncology; <sup>3</sup>Clinical Trial Center, Sun Yat-sen University Cancer Center, Guangzhou, Guangdong 510060; <sup>4</sup>Department of Lymphoma and Hematology, Hunan Cancer Hospital; <sup>5</sup>Department of Lymphoma and Hematology, The Affiliated Cancer Hospital of Xiangya School of Medicine, Central South University, Changsha, Hunan 410013, P.R. China

Received May 5, 2016; Accepted August 3, 2018

DOI: 10.3892/ol.2018.9353

**Abstract.** Cyclin-dependent kinase inhibitor 2A (p16<sup>INK4a</sup>) protein is a surrogate immunohistochemical marker of human papillomavirus infection in oropharynx squamous cell carcinoma (OPSCC). However, the effects of p16<sup>INK4a</sup> in non-OPSCC require additional analysis. In addition, major gaps remain in the literature, including small volumes of data for China. Therefore, the present study evaluated the frequency of p16<sup>INK4a</sup> positivity in patients with non-OPSCC in Southern China, and assessed its prognostic value. p16<sup>INK4a</sup> expression status in patients with non-OPSCC was determined by immunohistochemistry. p16<sup>INK4a</sup>-positive expression was defined as a strong and diffuse staining in  $\geq 70\%$  of the tumor cells. Then, the diagnostic value of p16<sup>INK4a</sup> in predicting overall survival (OS) and disease-free survival (DFS) rate was determined. The positive rate of p16<sup>INK4a</sup> was 26.3% in larynx cancer and 24.8% in oral cavity cancer. Multivariate analysis revealed that the protein status independently predicted improved OS rate, but not DFS rate ( $P=0.096$ ). Comparing different disease stages, patients at an early stage with p16<sup>INK4a</sup>-positive non-OPSCC exhibited improved DFS and OS rates compared with those exhibited by patients who were negative. The p16<sup>INK4a</sup>-positive rate in patients with non-OPSCC was 25.1% [26.3% in Laryngeal squamous cell carcinoma (LSCC) and 24.8% in Oropharyngeal squamous cell carcinomas (OSCC)] in the present cohort from South China. The present study suggested

that p16<sup>INK4a</sup> expression in non-OPSCC predicts favorable clinical outcomes, particularly in early stage non-OPSCC and oral cancer.

## Introduction

Head and neck squamous cell carcinoma (HNSCC) is the sixth most common type of cancer globally, with ~600,000 incident cases diagnosed per year (1-3). It is well known that this carcinoma is primarily a loco-regional disease. Improved local control of HNSCC has been achieved over previous decades due to recent advances in multidisciplinary treatments, including the surgical approach, reconstruction techniques and adjuvant treatment modalities (2,3). However, HNSCC is characterized by high rates of recurrence or metastasis following initial treatment, with rates of 40-60% (4). In consequence, the quality of life and life expectancy of patients with advanced HNSCC have not markedly improved over previous decades (2).

Human papillomavirus (HPV) infection is one of the major risk factors for HNSCC (5). Oropharynx squamous cell carcinoma (OPSCC) is most markedly associated with high-risk HPV infection (6-8). HNSCCs of other sites, including the oral cavity (9-11) and larynx (12-15), also have been demonstrated to harbor the virus. HPV status in tumors may be determined by numerous assays, including HPV E6/E7 RNA expression detected by reverse transcription-quantitative polymerase chain reaction (RT-qPCR) and HPV DNA detection by *in situ* hybridization or PCR. Cyclin-dependent kinase inhibitor 2A (p16<sup>INK4a</sup>), a tumor-suppressor protein that is overexpressed in cells, is a surrogate immunohistochemical marker of oncogenic subtypes of HPV infection in the oropharynx (6,16-18). However, the immunohistochemical studies of p16<sup>INK4a</sup> in non-oropharyngeal HNSCC have demonstrated variable results (13-15,19-23); thus, the validity of p16<sup>INK4a</sup> protein as a marker of HPV infection in non-OPSCC requires additional validation. Furthermore, patients who are positive for p16<sup>INK4a</sup> have improved outcomes compared with those of patients with OPSCC who are negative for p16<sup>INK4a</sup> (6,17). Compared with the significance of the data regarding HPV and OPSCC, the significance of HPV in HNSCC sites outside the oropharynx

*Correspondence to:* Dr Wen-Qi Jiang and Dr Yan-Xia Shi, Collaborative Innovation Center for Cancer Medicine, State Key Laboratory of Oncology in South China, Sun Yat-sen University Cancer Center, 651 Dongfeng East Road, Guangzhou, Guangdong 510060, P.R. China

E-mail: jiangwq\_sysuucc@163.com

E-mail: 18825136065@sina.cn

\*Contributed equally

**Key words:** human papillomavirus infection, immunohistochemical marker, prognosis, cyclin-dependent kinase inhibitor 2A expression, non-oropharynx squamous cell carcinoma

has not been established. Major gaps in the literature remain, including very little data for Asia, particularly China. Additionally, to the best of our knowledge, with the exception of a small number of studies investigating laryngeal cancer in Eastern China (24,25), there has been no analysis of p16<sup>INK4a</sup> expression in Chinese patients in oral cavity cancer. The aim of the present study was to evaluate the frequency of p16<sup>INK4a</sup> protein positive expression in patients with non-OPSCC in Southern China, and to assess its prognostic value.

## Patients and methods

*Patients and specimens.* Patients with non-oro-pharyngeal HNSCC were treated at the Department of Head and Neck Surgery of Sun Yat-sen University Cancer Center (SYSUCC; Guangzhou, China) between January 2001 and December 2008, and were selected randomly and retrospectively by stratified sampling. The present study was approved by the Ethics Review Board of SYSUCC and written informed consent was provided by all patients. All activities were in accord with the 1964 Declaration of Helsinki. The oral cavity, glottis and supraglottic larynx cancer were defined as non-OPSCC. The inclusion criteria were as follows: i) Patients had undergone complete excision, with or without unilateral or bilateral neck dissection; ii) the diagnosis was confirmed by pathology; iii) pathologic samples and complete follow-up data were available. Patients with other concomitant organ disorders or malignant tumor types were excluded. A total of 183 eligible patients with non-OPSCC with a mean age of 54.3 years (range, 26-86 years) were included in the present study. Among these, females comprised 24.6% of the patients. No patients exhibited metastasis at the time of diagnosis (stage IVc), nor had they undergone chemotherapy and/or radiotherapy prior to surgery.

All patients had follow-up data through December 2015. Detailed information of the patients selected for analysis was reviewed. The tumors were restaged in accordance with the 2010 American Joint Committee on Cancer TNM Staging Manual (26). To verify the histological diagnosis of non-OPSCC and adequacy of the tissue for analysis, the haematoxylin and eosin-stained (H&E) slides were reviewed by a pathologist. Sections were stained by a standard H&E staining method as follows: Sections were incubated for 60 sec at room temperature in filtered Mayer's haematoxylin solution, which is diluted by distilled water (1:20). Subsequently, the sections were washed under running water for 10 min. Following incubation in 1% eosin solution for 15 sec at room temperature, the sections were washed quickly (5-10 sec) in water and dehydrated in ascending concentrations of ethanol (75, 85, 95 and 100%). Subsequently, xylene was used to clear and covered with slips. The representative formalin-fixed, paraffin-embedded block for each patient was obtained from the Pathology Department of SYSUCC.

*Staining and evaluation.* The 4-mm thick paraffin-embedded slices were dewaxed and rehydrated, and endogenous peroxidase activity was blocked with 0.3% H<sub>2</sub>O<sub>2</sub>. The slides were boiled in sodium citrate for 5 min at 95°C and 20 min at 60°C in a microwave for antigen retrieval. The primary mouse monoclonal antibody against human p16<sup>INK4a</sup> (CINtec<sup>®</sup> p16<sup>INK4a</sup>

Histology kit; clone E6H4, prediluted, MTM-Laboratories; Roche Diagnostics, Basel, Switzerland) was used for the detection of the protein p16<sup>INK4a</sup>. Subsequently, the slides were incubated with a horseradish peroxidase-conjugated goat anti-mouse IgG secondary antibody (cat. no. 7076s; 1:2,000; Cell Signaling Technology, Inc., Danvers, MA, USA) at 37°C for 30 min. Finally, stained slides were counterstained with 5% Mayer's haematoxylin solution at room temperature for 60 sec. All slides were interpreted by two pathologists in a double-blinded manner. Positive p16<sup>INK4a</sup> expression was defined as a strong and diffuse nuclear and cytoplasmic staining in ≥70% of the tumor cells, as described previously (6,21,27).

*Statistical analysis.* All data were analyzed with the SPSS 19.0 statistical software package (IBM Corp., Armonk, NY, USA). The results of analysis were presented as the mean ± standard error of the mean. The  $\chi^2$  test was used to assess the associations between p16<sup>INK4a</sup> expression and other characteristics of patients. The disease-free survival (DFS) time was defined as the time between diagnosis and loco-regional recurrence or progression, distant metastasis. The overall survival (OS) time was calculated from the time of diagnosis to the date of mortality or the last follow-up visit. Survival was analyzed with Kaplan-Meier survival curves and univariate analysis. Multivariable hazard ratios were estimated using the Cox proportional hazards model. A two-sided P<0.05 was considered to indicate a statistically significant difference.

## Results

*Patient characteristics.* The clinicopathological characteristics of the patients are summarized in Table I. The 183 eligible patients with stages I-IVb non-oro-pharyngeal cancer had a median age of 53 years (range, 26-86 years), and males comprised 75.4% of the patients, with 58.5% of all patients being current or former smokers. Of the 183 patients, 145 exhibited oral cancer types, 28 exhibited glottis and 10 were supraglottic larynx cancer types. Adjuvant treatment involving radiotherapy was administered to 45 (24.6%) patients. The median follow-up time was 95 months (range, 3-184 months). As of the last follow-up visit, 113 (61.7%) patients exhibited local or distant relapse events. Only 5 (2.7%) patients were lost to follow-up. The disease-specific mortality was 44.8% (82/183).

Overall, 46 patients (25.1%) were scored as p16<sup>INK4a</sup>-positive, as defined by moderate or strong intensity staining in ≥70% of tumor cells (Fig. 1). The group of patients with larynx cancer exhibited the highest rate of p16<sup>INK4a</sup>-positive staining (26.3%), followed by the oral cavity (24.8%). Negative p16<sup>INK4a</sup> expression was significantly associated with recurrence or metastasis (66.4% vs. 47.8%; P=0.025). No other significant clinicopathological differences were observed between the two groups (Table I).

*Survival outcomes based on p16<sup>INK4a</sup> status.* Survival outcomes based on p16<sup>INK4a</sup> status in patients with non-OPSCC were examined. In the p16<sup>INK4a</sup>-negative group, the 5-year OS and DFS rates were 57.7% and 38.6%, respectively. The p16<sup>INK4a</sup>-positive expression group exhibited markedly improved survival rates: The 5-year OS and DFS rates were

Table I. Associations between p16<sup>INK4a</sup> expression and clinicopathological characteristics of patients with oral cavity and larynx squamous cell carcinoma (n=183).

Characteristic	p16 <sup>INK4a</sup> expression <sup>a</sup>		P-value
	Negative, n (%)	Positive, n (%)	
Total	137 (74.9)	46 (25.1)	
Age at diagnosis, years			0.560
<50	50 (36.5)	19 (41.3)	
≥50	87 (63.5)	27 (58.7)	
Sex			0.360
Male	101 (73.7)	37 (80.4)	
Female	36 (26.3)	9 (19.6)	
Smoking history			0.156
No	61 (44.5)	15 (32.6)	
Yes	76 (55.5)	31 (67.4)	
Alcohol consumption			0.467
No	103 (75.2)	37 (80.4)	
Yes	34 (24.8)	9 (19.6)	
Tumor position			0.633
Oral cavity	109 (79.6)	36 (78.3)	
Buccal mucosa	8	2	
Floor of mouth	12	1	
Anterior tongue	71	28	
Alveolar ridge	18	5	
Larynx	28 (20.4)	10 (21.7)	
Supraglottic	8	2	
Glottic	20	8	
Histological differentiation			0.325
Well	74 (54.0)	30 (65.2)	
Moderate	49 (35.8)	11 (23.9)	
Poor	14 (10.2)	5 (10.9)	
Clinical stage			0.405
I/II	86 (62.8)	32 (69.6)	
III/IV	51 (37.2)	14 (30.4)	
Disease recurrence			0.025
No	46 (33.6)	24 (52.5)	
Yes	91 (66.4)	22 (47.8)	
Recurrent tumor sites			0.143
Local	36 (39.6)	7 (30.4)	
Lymph node metastasis	49 (53.8)	16 (69.6)	
Distant metastasis	6 (6.6)	0 (0)	

p16<sup>INK4a</sup>, Cyclin-dependent kinase inhibitor 2A. <sup>a</sup>p16<sup>INK4a</sup> positive expression was defined as a strong and diffuse nuclear and cytoplasmic staining in ≥70% of the tumor cells.

78.1% and 56.4%, respectively. Patients with p16<sup>INK4a</sup>-positive expression exhibited improved DFS and OS rates compared with those with negative expression (Fig. 2). Furthermore, male patients (P=0.037), who smoked tobacco (P=0.016) and alcohol (P=0.020), with poorly differentiated tumor types (P=0.018) and stage III or IV disease (P<0.001) exhibited a reduced OS rate, and patients with poorly differentiated tumor

types (P=0.004) and advanced disease (P=0.002) exhibited a reduced DFS rate, compared with their counterparts (Table II). Cox proportional hazards analysis revealed that p16<sup>INK4a</sup>-negative independently predicted low OS rate (Table III; P=0.020) but not DFS rate (P=0.096).

The survival outcomes of p16<sup>INK4a</sup> based on reclassifying by primary site (oral cavity or larynx) and stage (stage I/II

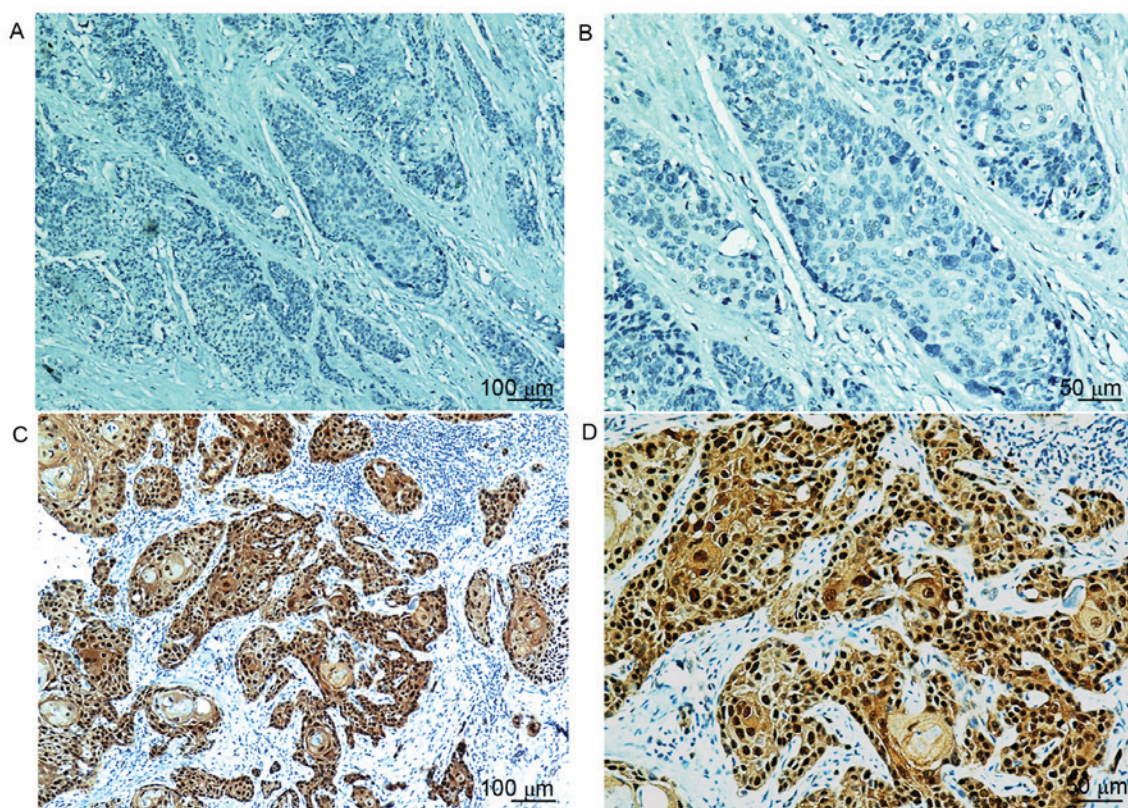


Figure 1. Representative p16<sup>INK4a</sup> immunohistochemistry results. Lack of brown staining in p16<sup>INK4a</sup> negative carcinoma at a magnification of (A) x100 and (B) x200. p16<sup>INK4a</sup> exhibiting diffuse nuclear and cytoplasmic brown staining in  $\geq 70\%$  of the tumor cells at (C) a magnification of x100 and (D) x200. p16<sup>INK4a</sup>, cyclin-dependent kinase inhibitor 2A.

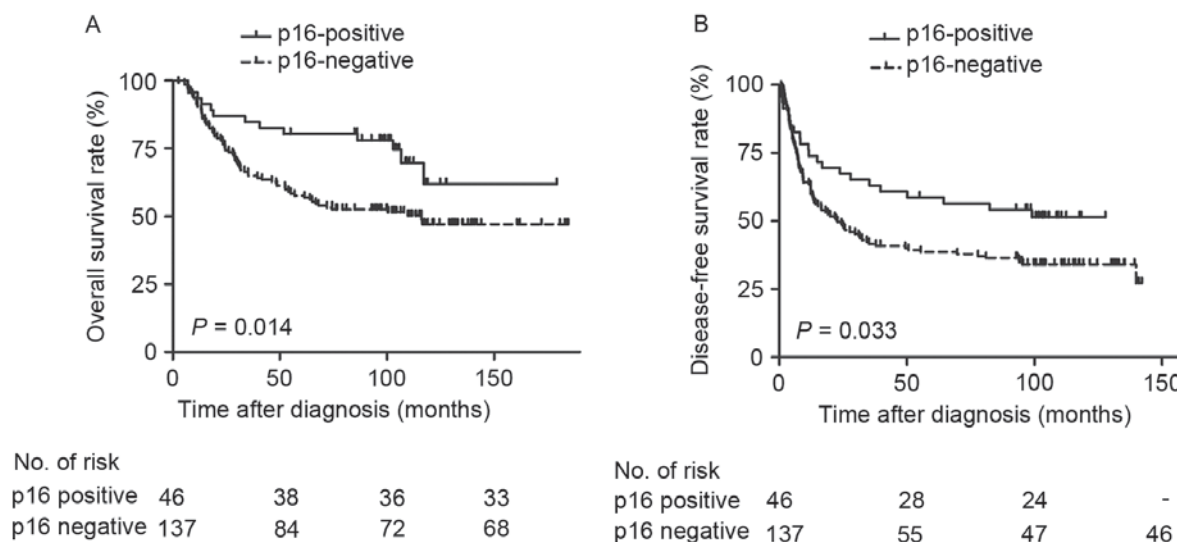


Figure 2. Survival curves of 183 patients with non-opharynx squamous cell carcinoma, stratified by p16<sup>INK4a</sup> expression status. (A) Overall survival rate. (B) Disease-free survival rate. p16<sup>INK4a</sup>, cyclin-dependent kinase inhibitor 2A.

or III/IV) were also examined. The patients with OSCC with p16<sup>INK4a</sup>-positive expression exhibited significantly improved OS (Fig. 3A;  $P=0.017$ ) and DFS (Fig. 3B;  $P=0.036$ ) rates, as determined by Kaplan-Meier survival curves. Additionally, patients with LSCC with positive p16<sup>INK4a</sup> expression exhibited no significant difference in OS rate (Fig. 3C;  $P=0.257$ ), but significantly increased DFS rate (Fig. 3D;  $P=0.029$ ). Furthermore, significantly improved OS (Fig. 4A;  $P=0.004$ )

and DFS rates (Fig. 4B;  $P=0.018$ ) were observed in patients with stage I/II tumor types with positive p16<sup>INK4a</sup> expression. However, there were no significant differences in stage III/IV tumor types (Fig. 4C and D;  $P>0.05$ ). Additional univariate analysis confirmed that positive p16<sup>INK4a</sup> status predicted favorable OS rate in oral cancer [Table IV; relative risk (RR)=0.42;  $P=0.017$ ] and in the stage I/II disease (RR=0.25;  $P=0.004$ ) subgroups. Although patients who were p16<sup>INK4a</sup>-positive

Table II. Univariate survival analysis of patients with oral cavity and larynx squamous cell carcinoma (n=183).

Variable	Overall survival rate		Disease-free survival rate	
	RR 95% CI	P-value	RR 95% CI	P-value
Male	1.88 (1.04-3.41)	0.037	1.53 (0.95-2.46)	0.081
Tobacco use	1.78 (1.11-2.86)	0.016	1.36 (0.93-2.00)	0.118
Alcohol use	1.74 (1.09-2.77)	0.020	1.25 (0.83-1.89)	0.291
Age <50 years	1.13 (0.72-1.77)	0.602	1.06 (0.72-1.55)	0.779
Poorer differentiation	1.69 (1.09-2.61)	0.018	1.71 (1.18-2.48)	0.004
Cyclin-dependent kinase inhibitor 2A -positive expression	0.48 (0.27-0.87)	0.014	0.61 (0.38-0.97)	0.033
Stage III/IV disease	2.26 (1.47-3.50)	<0.001	1.79 (1.23-2.60)	0.002

RR, relative risk; CI, confidence interval.

Table III. Multivariate survival analysis of patients with oral cavity and larynx squamous cell carcinoma (n=183).

Variable	Overall survival rate			Disease-free survival rate		
	RR	95% CI	P-value	RR	95% CI	P-value
Male	0.95	0.42-2.15	0.909	-	-	-
Tobacco use	1.75	0.92-3.32	0.088	-	-	-
Alcohol use	1.53	0.92-2.52	0.099	-	-	-
Poorer differentiation	1.28	0.81-2.04	0.294	1.47	1.00-2.17	0.051
Cyclin-dependent kinase inhibitor 2A -positive expression	0.49	0.27-0.89	0.020	0.67	0.42-1.07	0.096
Stage III/IV disease	2.01	1.25-3.23	0.004	1.53	1.03-2.27	0.034

RR, relative risk; CI, confidence interval.

exhibited increased DFS rates, compared with those who were p16<sup>INK4a</sup>-negative (Fig. 2B; P=0.033), the statistical difference calculated by multivariate analysis between groups was not significant (Table III; RR=0.67; P=0.096).

## Discussion

HPV E6/E7 RNA expression detected using RT-qPCR, the results of which indicate active viral gene transcription in a tumor, is considered to be the gold standard (16). Although p16<sup>INK4a</sup> protein is a reliable indicator of HPV infection in the oropharynx, the sensitivity and specificity of p16<sup>INK4a</sup> in OSCC and LSCC has not been conclusively determined (14,20,22,23,28-30). It was demonstrated that the incidence of p16<sup>INK4a</sup> positivity in southern Chinese patients with LSCC is 26.3%, and in patients with OSCC is 24.8% (14). Johns Hopkins University published a large-scale screening study that evaluated p16<sup>INK4a</sup> expression by immunohistochemistry, in which the patients with non-OPSCC were collected from Radiation Therapy Oncology Group (RTOG) 0129, 0234 and 0522 studies (21). A total of 19.3% (62/322) patients were p16<sup>INK4a</sup> positive, and the patients with OSCC exhibited the highest rate of p16<sup>INK4a</sup> positivity [21/80 (26.3%)], followed by the larynx [31/181 (17.1%)], which was similar to the present study. However, Xu *et al* (23) detected the

status in Chinese patients with laryngeal cancer, and revealed a positive rate of 7.57%. In general, previously identified rates of p16<sup>INK4a</sup> protein expression in patients with non-OPSCC are not concordant (20,22,23,25,30), and multiple factors contribute to this discrepancy, for example: Heterogeneous patient selection (geographical differences, tobacco and alcohol status of the patient or the number of cases); or the scoring system used for defining p16<sup>INK4a</sup> as positive.

A debate exists with respect to the prognostic role of p16<sup>INK4a</sup> in non-OPSCC. In the present study, the OS and DFS rates among all 183 patients with non-OPSCC were improved in p16<sup>INK4a</sup>-positive patients compared with negative expression patients, although the multivariate survival analysis suggested that the difference between DFS rate was not statistically significant. The data from patients with non-OPSCC collected from RTOG studies concluded that, similar to the results in patients with OPSCC (6,17,31,32), patients with p16<sup>INK4a</sup>-positive exhibit improved outcomes compared with those with p16<sup>INK4a</sup>-negative non-OPSCC (21). Nevertheless, other studies did not observe a significant correlation between p16<sup>INK4a</sup> expression and improved outcomes (14,22,33). These differences may be due to the small number of samples, different anatomic sites enrolled or tumor heterogeneity in each retrospective cohort.

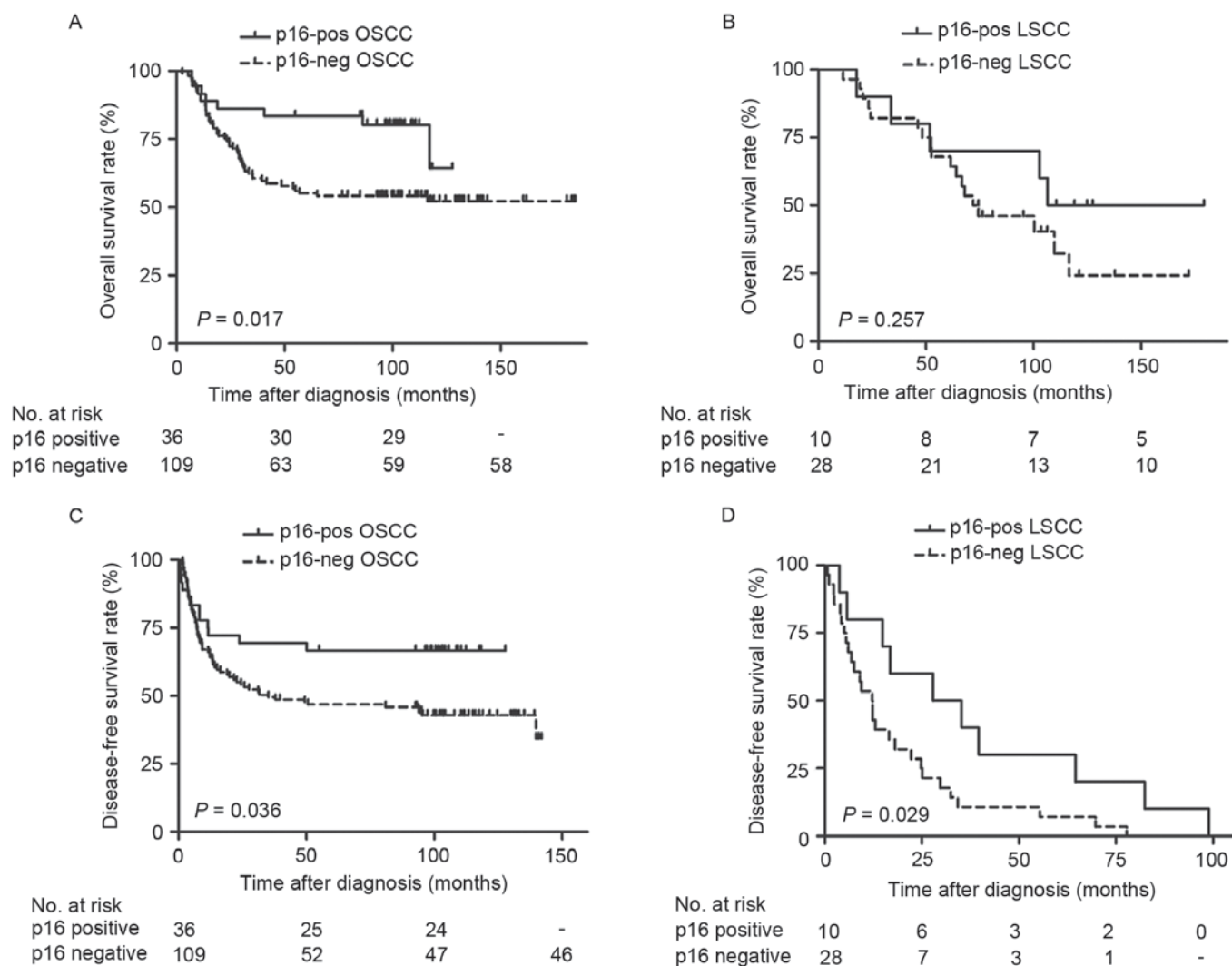


Figure 3. Survival curves of patients with OSCC and LSCC. Overall survival rates are presented according to the primary tumor site and p16<sup>INK4a</sup> status of (A) OSCC and (C) LSCC. Disease-free survival rates are presented according to the primary tumor site and p16<sup>INK4a</sup> status of (B) OSCC and (D) LSCC. OSCC, oral cavity squamous cell carcinoma; LSCC, larynx squamous cell carcinoma; p16<sup>INK4a</sup>, cyclin-dependent kinase inhibitor 2A.

Additional stratified analysis identified that patients who were p16<sup>INK4a</sup>-positive with stage I/II tumor types or tumor types in oral cavity sites demonstrated significantly improved OS rate compared with patients who were negative expression. Patients who were p16<sup>INK4a</sup>-positive in stage I/II or at larynx sites demonstrated markedly improved DFS rates compared with patients who were p16<sup>INK4a</sup>-negative; and this observation may be of clinical importance. The treatment of an early stage tumor consists of surgery combined with radiotherapy (34,35). Nevertheless, the toxicities of these treatments may result in organ dysfunction and potentially treatment-associated mortalities (36,37). It is necessary to decrease the intensity of treatment for patients with favorable prognosis. However, no specific indicator for this subgroup was identified. In the present study, negative p16<sup>INK4a</sup> status was considered as an indicator for a requirement for aggressive therapy in patients with stage I/II tumor types, to achieve survival benefit.

However, due to the small sample sizes (n=183), the prognostic role of p16<sup>INK4a</sup> in LSCC demonstrated in the present study should be interpreted with caution. The present study aimed to detect the level of HPV DNA in the same set of

samples, but the outcome was not conclusive as the DNA quality in the paraffin block was not adequate. Concomitantly, as a retrospective investigation, the present study is limited by the lack of large-scale screening.

The present study demonstrated an analysis of diagnostic tests, the diagnostic accuracy and prognostic relevance of p16<sup>INK4a</sup> in patients from South China. It was identified that the p16<sup>INK4a</sup> positive rate in patients with non-OPSCC was 25.1% (26.3% in LSCC and 24.8% in OSCC). It was suggested that p16<sup>INK4a</sup> expression in patients with non-OPSCC predicted favorable clinical outcomes, particularly in OSCC and early stage non-OPSCC. If so, these patients with p16<sup>INK4a</sup>-negative should receive more aggressive therapy and a closer follow-up. It is hoped that the design of forthcoming clinical trials in China, aimed at therapy in patients who are p16<sup>INK4a</sup>-positive with non-OPSCC and perhaps aggressive therapy for patients who are p16<sup>INK4a</sup>-negative, will be informed by these results.

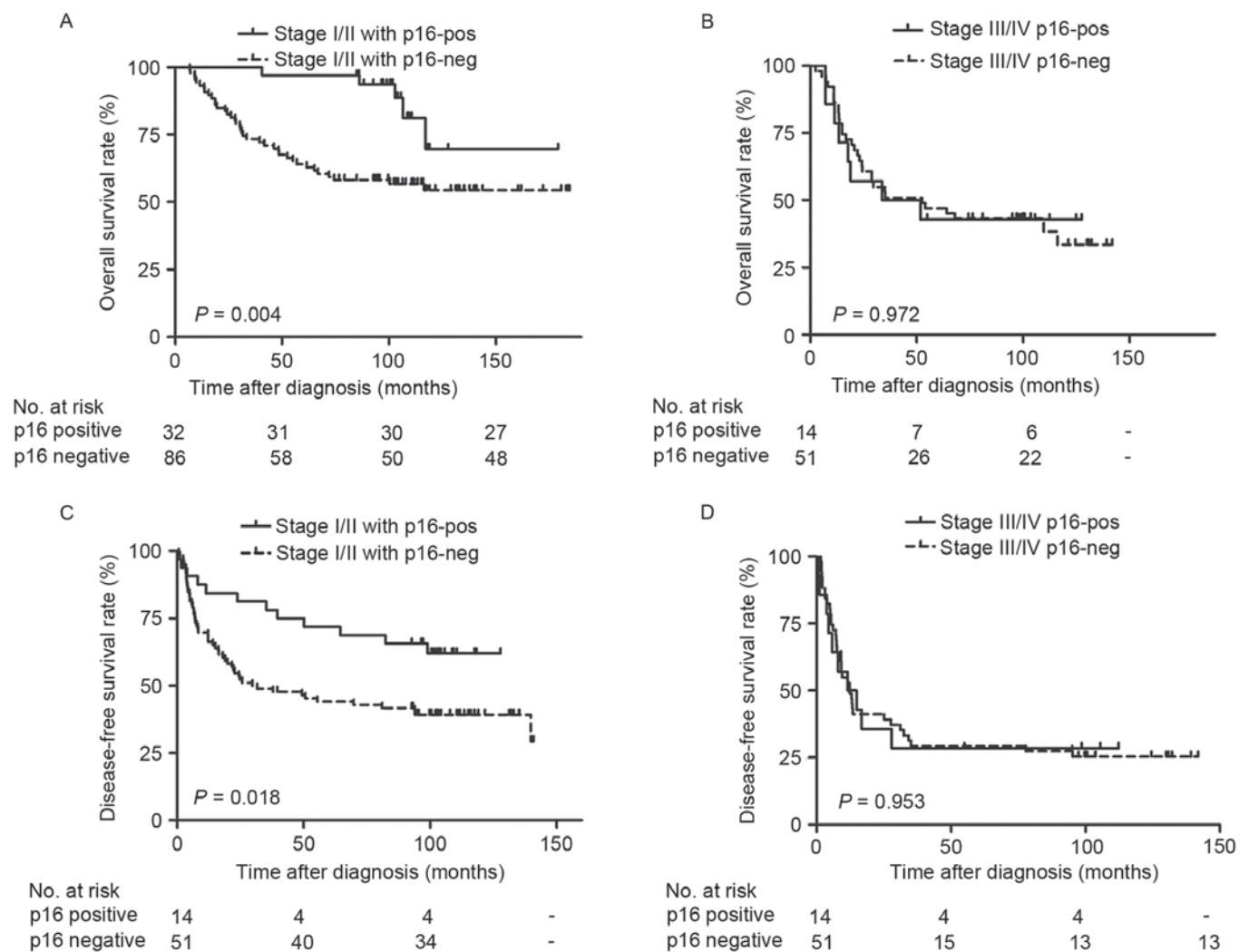
#### Acknowledgements

Not applicable.

Table IV. Univariate survival analysis of cyclin-dependent kinase inhibitor 2A in patients stratified by primary site and stage.

Stratification factors	Overall survival rate			Disease-free survival rate		
	RR	95% CI	P-value	RR	95% CI	P-value
Primary site	-	-	-	-	-	-
Oral cancer	0.42	0.20-0.88	0.017	0.52	0.28-0.97	0.036
Larynx cancer	0.56	0.20-1.54	0.257	0.42	0.19-0.93	0.029
Primary stage	-	-	-	-	-	-
I/II	0.25	0.10-0.65	0.004	0.48	0.25-0.90	0.018
III/IV	1.01	0.46-2.21	0.972	1.02	0.51-2.05	0.953

RR, relative risk; CI, confidence interval.

Figure 4. Survival curves of patients with different tumor stages. Overall survival rates are presented according to the disease stage and p16<sup>INK4a</sup> status in (A) stage I/II tumor types and (C) stage III/IV tumor types. Disease-free survival rates are presented according to the disease stage and p16<sup>INK4a</sup> status in (B) stage I/II tumor types and (D) stage III/IV tumor types. p16<sup>INK4a</sup>, cyclin-dependent kinase inhibitor 2A.

## Funding

The present study was supported by grants from the Natural Science Foundation of China (grant no. 81201716).

## Availability of data and materials

The datasets used and analyzed during the present study are available from the corresponding author on reasonable request.

### Authors' contributions

WQJ and YXS participated in the design of the research. HY and YC conducted the IHC studies, participated in the collection of cases and drafted the manuscript. ZML and YJL helped the statistical analysis and participated in the IHC studies. WQJ and YXS helped to revise the manuscript. All authors read and approved the final manuscript.

### Ethics approval and consent to participate

The current study was approved by the Ethics Review Board of Sun Yat-Sen University Cancer Center. All activities were in accord with the 1964 Declaration of Helsinki. Each patient signed informed consent for participate in the study and collect specimens.

### Patient consent for publication

The patients involved in the present study signed informed consent for the publication of any associated data and accompanying images.

### Competing interests

The authors declared that they have no competing interests.

### References

- Wong IC, Ng YK and Lui VW: Cancers of the lung, head and neck on the rise: Perspectives on the genotoxicity of air pollution. *Chin J Cancer* 33: 476-480, 2014.
- Siegel RL, Miller KD and Jemal A: Cancer statistics, 2015. *CA Cancer J Clin* 65: 5-29, 2015.
- Torre LA, Bray F, Siegel RL, Ferlay J, Lortet-Tieulent J and Jemal A: Global cancer statistics, 2012. *CA Cancer J Clin* 65: 87-108, 2015.
- Atienza JA and Dasanu CA: Incidence of second primary malignancies in patients with treated head and neck cancer: A comprehensive review of literature. *Curr Med Res Opin* 28: 1899-1909, 2012.
- Mork J, Lie AK, Glatte E, Hallmans G, Jellum E, Koskela P, Møller B, Pukkala E, Schiller JT, Youngman L, *et al*: Human papillomavirus infection as a risk factor for squamous-cell carcinoma of the head and neck. *N Engl J Med* 344: 1125-1131, 2001.
- Ang KK, Harris J, Wheeler R, Weber R, Rosenthal DI, Nguyen-Tân PF, Westra WH, Chung CH, Jordan RC, Lu C, *et al*: Human papillomavirus and survival of patients with oropharyngeal cancer. *N Engl J Med* 363: 24-35, 2010.
- Chaturvedi AK, Engels EA, Pfeiffer RM, Hernandez BY, Xiao W, Kim E, Jiang B, Goodman MT, Sibug-Saber M, Cozen W, *et al*: Human papillomavirus and rising oropharyngeal cancer incidence in the united states. *J Clin Oncol* 29: 4294-4301, 2011.
- Ndiaye C, Mena M, Alemany L, Arbyn M, Castellsagué X, Laporte L, Bosch FX, de Sanjosé S and Trottier H: HPV DNA, E6/E7 mRNA, and p16<sup>INK4a</sup> detection in head and neck cancers: A systematic review and meta-analysis. *Lancet Oncol* 15: 1319-1331, 2014.
- Bouda M, Gorgoulis VG, Kastrinakis NG, Giannoudis A, Tsoli E, Danassi-Afentaki D, Foukas P, Kyroudi A, Laskaris G, Herrington CS and Kittas C: 'High risk' HPV types are frequently detected in potentially malignant and malignant oral lesions, but not in normal oral mucosa. *Mod Pathol* 13: 644-653, 2000.
- Paradiso A, Ranieri G, Stea B, Zito A, Zehbe I, Tommasino M, Grammatica L and De Lena M: Altered p16<sup>INK4a</sup> and Fhit expression in carcinogenesis and progression of human oral cancer. *Int J Oncol* 24: 249-255, 2004.
- Bradley KT, Budnick SD and Logani S: Immunohistochemical detection of p16<sup>INK4a</sup> in dysplastic lesions of the oral cavity. *Mod Pathol* 19: 1310-1316, 2006.
- Baumann JL, Cohen S, Evjen AN, Law JH, Vadivelu S, Attia A, Schindler JS, Chung CH, Wirth PS, Meijer CJ, *et al*: Human papillomavirus in early laryngeal carcinoma. *Laryngoscope* 119: 1531-1537, 2009.
- Halec G, Holzinger D, Schmitt M, Flechtenmacher C, Dyckhoff G, Lloveras B, Höfler D, Bosch FX and Pawlita M: Biological evidence for a causal role of HPV16 in a small fraction of laryngeal squamous cell carcinoma. *Br J Cancer* 109: 172-183, 2013.
- Xu Y, Liu S, Yi H, Wang J, Dong P, Li X and Yin S: Human papillomavirus infection in 674 Chinese patients with laryngeal squamous cell carcinoma. *PLoS One* 9: e115914, 2014.
- Young RJ, Urban D, Angel C, Corry J, Lyons B, Vallance N, Kleid S, Iseli TA, Solomon B and Rischin D: Frequency and prognostic significance of p16(INK4A) protein overexpression and transcriptionally active human papillomavirus infection in laryngeal squamous cell carcinoma. *Br J Cancer* 112: 1098-1104, 2015.
- Shi W, Kato H, Perez-Ordóñez B, Pintilie M, Huang S, Hui A, O'Sullivan B, Waldron J, Cummings B, Kim J, *et al*: Comparative prognostic value of HPV16 E6 mRNA compared with in situ hybridization for human oropharyngeal squamous carcinoma. *J Clin Oncol* 27: 6213-6221, 2009.
- Rischin D, Young RJ, Fisher R, Fox SB, Le QT, Peters LJ, Solomon B, Choi J, O'Sullivan B, Kenny LM and McArthur GA: Prognostic significance of p16<sup>INK4A</sup> and human papillomavirus in patients with oropharyngeal cancer treated on TROG 02.02 phase III trial. *J Clin Oncol* 28: 4142-4148, 2010.
- Jordan RC, Lingen MW, Perez-Ordóñez B, He X, Pickard R, Koluder M, Jiang B, Wakely P, Xiao W and Gillison ML: Validation of methods for oropharyngeal cancer HPV status determination in US cooperative group trials. *Am J Surg Pathol* 36: 945-954, 2012.
- Buajeeb W, Poomsawat S, Punyasingh J and Sanguansin S: Expression of p16 in oral cancer and premalignant lesions. *J Oral Pathol Med* 38: 104-108, 2009.
- Bussu F, Sali M, Gallus R, Vellone VG, Zannoni GF, Autorino R, Dinapoli N, Santangelo R, Martucci R, Graziani C, *et al*: HPV infection in squamous cell carcinomas arising from different mucosal sites of the head and neck region. Is p16 immunohistochemistry a reliable surrogate marker? *Br J Cancer* 108: 1157-1162, 2013.
- Chung CH, Zhang Q, Kong CS, Harris J, Fertig EJ, Harari PM, Wang D, Redmond KP, Shenouda G, Trotti A, *et al*: p16 protein expression and human papillomavirus status as prognostic biomarkers of nonoropharyngeal head and neck squamous cell carcinoma. *J Clin Oncol* 32: 3930-3938, 2014.
- Lim AM, Do H, Young RJ, Wong SQ, Angel C, Collins M, Takano EA, Corry J, Wiesenfeld D, Kleid S, *et al*: Differential mechanisms of CDKN2A (p16) alteration in oral tongue squamous cell carcinomas and correlation with patient outcome. *Int J Cancer* 135: 887-895, 2014.
- Xu Y, Liu S, Yi H, Wang J, Luo Y and Yin S: Low prevalence of human papillomavirus in head and neck squamous cell carcinoma in chinese patients. *J Med Virol* 87: 281-286, 2015.
- Fu ZJ, Ma ZY, Wang QR, Lei DP, Wang R, Liu CX and Pan XL: Overexpression of cyclin1 and underexpression of p16 correlate with lymph node metastases in laryngeal squamous cell carcinoma in chinese patients. *Clin Exp Metastasis* 25: 887-892, 2008.
- Li D, Zhang Q and Zhang X: Expression and clinical significance of MDM2 and P16 in laryngeal squamous cell carcinoma. *Lin Chung Er Bi Yan Hou Tou Jing Wai Ke Za Zhi* 26: 802-805, 2012 (In Chinese).
- Edge SB and Compton CC: The american joint committee on cancer: The 7th edition of the AJCC cancer staging manual and the future of TNM. *Ann Surg Oncol* 17: 1471-1474, 2010.
- Schache AG, Liloglou T, Risk JM, Filia A, Jones TM, Sheard J, Woolgar JA, Helliwell TR, Triantafyllou A, Robinson M, *et al*: Evaluation of human papilloma virus diagnostic testing in oropharyngeal squamous cell carcinoma: Sensitivity, specificity, and prognostic discrimination. *Clin Cancer Res* 17: 6262-6271, 2011.
- Schlecht NF, Brandwein-Gensler M, Nuovo GJ, Li M, Dunne A, Kawachi N, Smith RV, Burk RD and Prystowsky MB: A comparison of clinically utilized human papillomavirus detection methods in head and neck cancer. *Mod Pathol* 24: 1295-1305, 2011.
- Doxtader EE and Katzenstein AL: The relationship between p16 expression and high-risk human papillomavirus infection in squamous cell carcinomas from sites other than uterine cervix: A study of 137 cases. *Hum Pathol* 43: 327-332, 2012.



30. van Monsjou HS, van Velthuysen ML, van den Brekel MW, Jordanova ES, Melief CJ and Balm AJ: Human papillomavirus status in young patients with head and neck squamous cell carcinoma. *Int J Cancer* 130: 1806-1812, 2012.
31. Posner MR, Lorch JH, Goloubeva O, Tan M, Schumaker LM, Sarlis NJ, Haddad RI and Cullen KJ: Survival and human papillomavirus in oropharynx cancer in TAX 324: A subset analysis from an international phase III trial. *Ann Oncol* 22: 1071-1077, 2011.
32. Rietbergen MM, Brakenhoff RH, Bloemena E, Witte BI, Snijders PJ, Heideman DA, Boon D, Koljenovic S, Baatenburg-de Jong RJ and Leemans CR: Human papillomavirus detection and comorbidity: Critical issues in selection of patients with oropharyngeal cancer for treatment De-escalation trials. *Ann Oncol* 24: 2740-2745, 2013.
33. Kalfert D, Celakovsky P, Laco J and Ludvikova M: The role of protein p16(INK4a) in glottic laryngeal squamous cell carcinoma. *Pathol Oncol Res* 20: 909-915, 2014.
34. Forastiere AA, Goepfert H, Maor M, Pajak TF, Weber R, Morrison W, Glisson B, Trotti A, Ridge JA, Chao C, *et al*: Concurrent chemotherapy and radiotherapy for organ preservation in advanced laryngeal cancer. *N Engl J Med* 349: 2091-2098, 2003.
35. Adelstein DJ, Saxton JP, Rybicki LA, Esclamado RM, Wood BG, Strome M, Lavertu P, Lorenz RR and Carroll MA: Multiagent concurrent chemoradiotherapy for locoregionally advanced squamous cell head and neck cancer: Mature results from a single institution. *J Clin Oncol* 24: 1064-1071, 2006.
36. Machtay M, Moughan J, Trotti A, Garden AS, Weber RS, Cooper JS, Forastiere A and Ang KK: Factors associated with severe late toxicity after concurrent chemoradiation for locally advanced head and neck cancer: An RTOG analysis. *J Clin Oncol* 26: 3582-3589, 2008.
37. Corry J, Peters LJ and Rischin D: Optimising the therapeutic ratio in head and neck cancer. *Lancet Oncol* 11: 287-291, 2010.