

# Characteristics of overlooked synchronous gastric epithelial neoplasia after endoscopic submucosal dissection

Hyeong Seok Nam, MD<sup>a</sup>, Hyung Wook Kim, PhD, MD<sup>a</sup>, Cheol Woong Choi, PhD, MD<sup>a,\*</sup>,  
Dae Hwan Kang, PhD, MD<sup>a</sup>, Su Bum Park, PhD, MD<sup>a</sup>, Su Jin Kim, MD<sup>a</sup>, Jung Sik Choi, PhD, MD<sup>b</sup>

## Abstract

Since endoscopic submucosal dissection (ESD) has been accepted as the treatment of choice for early gastric cancer (EGC) without risk of lymph node metastasis, synchronous gastric epithelial neoplasia is no longer rare in the clinical practice. Knowledge about the characteristics associated with synchronous gastric epithelial neoplasia is of great importance to prevent delayed diagnosis.

Between November 2008 and December 2014, a retrospective study was conducted in a single tertiary referral hospital. Consecutive patients who underwent ESD due to EGC or high-grade dysplasia were analyzed to evaluate the incidence of synchronous gastric epithelial neoplasia and the factors associated with synchronous and overlooked synchronous lesions.

A total of 488 patients were analyzed in this study. Synchronous lesions were found in 59 patients (12.1%) during the mean 37.7 months of follow-up. Among 77 synchronous lesions, 25 lesions (32.4%) were overlooked at the time of initial ESD. Age of  $\geq 65$  years, moderate to severe endoscopic atrophic gastritis, and elevated morphology of primary lesions were associated with synchronous gastric epithelial neoplasia. An important factor associated with overlooked lesions is the non-elevated morphology of lesions.

Careful endoscopic examination of the whole stomach is necessary in patients who are older and who have moderate to severe atrophic gastritis and elevated morphology of lesions to prevent delayed diagnosis of synchronous gastric epithelial neoplasia, especially non-elevated lesions.

**Abbreviations:** CI = confidence interval, EGC = early gastric cancer, ESD = endoscopic submucosal dissection, OR = odds ratio.

**Keywords:** atrophic gastritis, early gastric cancer, endoscopic submucosal dissection, neoplasia, synchronous

## 1. Introduction

Gastric adenocarcinoma is a common gastrointestinal malignancy worldwide. The prognosis of gastric cancer is dependent on the lymph nodes or distant metastasis. The prognosis of patients with early gastric cancer (EGC) who underwent surgical gastrectomy was good (stage IA over 95.1% and stage IB 88.4%).<sup>[1]</sup> According to the National Cancer Screening program of the Republic of Korea, adults over 40 years can have biennial gastric cancer screening free of charge. The screening

endoscopic rate for gastric cancer was reported as 70.8% in the Republic of Korea,<sup>[2]</sup> and the proportion of EGC had reached 57.6% of patients who underwent gastrectomy because of gastric cancer.<sup>[3]</sup>

Endoscopic submucosal dissection (ESD) has been accepted as a treatment modality for EGC without the risk of lymph node metastasis<sup>[4,5]</sup> because the survival outcomes following ESD have been found to be comparable to surgical resection.<sup>[6]</sup> The 5-year survival rates of endoscopic resection for EGCs that met the absolute and expanded indication were over 95%.<sup>[7,8]</sup> In contrast to surgical gastrectomy, ESD is capable of organ preservation and provides a better quality of life than gastrectomy. Gastric cancer is highly associated with *Helicobacter pylori* infection, and the prevalence of *H pylori* infection in Korea was reported to be 59.6% in 2005.<sup>[9]</sup> The prevalence of atrophic gastritis and intestinal metaplasia in Korea was 20.1% to 40.7% and 21.2% to 32.7%, respectively.<sup>[10]</sup> The prevalence of atrophic gastritis and intestinal metaplasia increases with age.<sup>[11]</sup> After organ-preserving treatment of EGC such as endoscopic resection, the premalignant gastric lesions (atrophic gastritis or intestinal metaplasia) remain. Therefore, multiple gastric epithelial neoplasia may be found before or after ESD. The reported rates of synchronous lesions after endoscopic resection and surgical gastrectomy for gastric cancer were 2% to 19.2% and 4.8% to 14.6%, respectively.<sup>[12]</sup>

The early detection of multiple gastric epithelial neoplasia is important to preserve the stomach after ESD. In the present study, the clinical characteristics of synchronous gastric epithelial neoplasia before or after ESD for EGCs or high-grade dysplasia were evaluated. Moreover, the factors associated with overlooked synchronous lesions were analyzed.

Editor: Bülent Kantarçeken.

HS Nam and HW Kim share first authorship.

The authors have no funding and conflicts of interest to disclose.

<sup>a</sup> Department of Internal Medicine, Pusan National University School of Medicine and Research Institute for Convergence of Biomedical Science and Technology, Pusan National University Yangsan Hospital, Yangsan, <sup>b</sup> Inje University College of Medicine, Busan Paik Hospital, Pusan, Korea.

\* Correspondence: Cheol Woong Choi, Department of Internal Medicine, Medical Research Institute, Pusan National University School of Medicine and Research Institute for Convergence of Biomedical Science and Technology, Pusan National University Yangsan Hospital, Beomeo-ri Mulgeum-eup, Yangsan-si, Gyeongsangnam-do 50612, Korea  
(e-mail: drluckyace@gmail.com, luckyace@hanmail.net).

Copyright © 2018 the Author(s). Published by Wolters Kluwer Health, Inc. This is an open access article distributed under the terms of the Creative Commons Attribution-Non Commercial-No Derivatives License 4.0 (CCBY-NC-ND), where it is permissible to download and share the work provided it is properly cited. The work cannot be changed in any way or used commercially without permission from the journal.

Medicine (2018) 97:39(e12536)

Received: 21 January 2018 / Accepted: 31 August 2018

<http://dx.doi.org/10.1097/MD.0000000000012536>

**2. Patients and methods**

**2.1. Patients**

The medical records of patients with EGC or high-grade dysplasia who were treated using ESD were retrospectively reviewed between November 2008 and December 2014 at the Pusan National University Yangsan Hospital in the Republic of Korea. During the study period, 596 consecutive patients were treated using ESD. The indications of the ESD for EGC are absolute or expanded indications.<sup>[4,5]</sup> Absolute indication was differentiated mucosal cancer of <20mm in size. Expanded indications were as follows:

- (1) differentiated mucosal cancer without ulcerations,
- (2) differentiated mucosal cancer with ulceration <30 mm in size,
- (3) differentiated submucosal cancer <30 mm (invasion depth <500 μm), and
- (4) undifferentiated mucosal cancer without ulceration <20 mm in size.

The exclusion criteria were as follows: beyond indications of endoscopic resection (n=49), piecemeal resection or resection margin positive (n=30), lesions in the remnant stomach after surgical resection (n=2), and absence of follow-up endoscopic examination after ESD (n=27). After exclusions, a total of 488 patients with high-grade dysplasia or EGCs were enrolled and analyzed (Fig. 1). Written informed consents were obtained from all patients before performing ESD. The study was approved by the Ethics Committee that belongs to our Institutional Review Board.

**2.2. Clinicopathological characteristics and definitions**

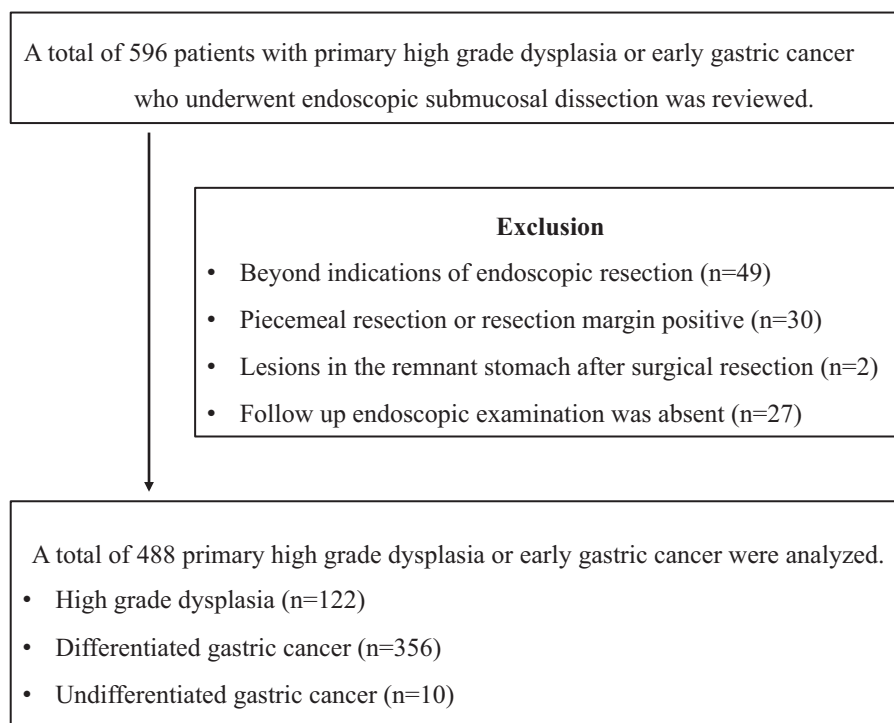
All endoscopic photographs and data were retrospectively reviewed by an endoscopist (CW Choi MD, PhD). The procedure

time was defined as the time from marking around the lesion to complete removal of the lesion, including the time required for hemostasis. The macroscopic appearances of lesions were defined by the Paris classification, based on the characteristics of the endoscopic findings (elevated, flat, and depressed).<sup>[13]</sup> The location of the lesions was described as the lower third, mid-third, or upper third of the stomach using the Japanese classification of gastric cancer.<sup>[14]</sup> The lesion size was measured using the pathological examination (maximal diameter). Surface redness and whitish discoloration were defined as discoloration on the mucosal surface of the lesion compared to the surrounding mucosa. Surface nodularity was defined as the presence of irregularly raised or nodular mucosa. A lesion with an ulceration or scar secondary to previous ulceration was regarded as an ulcer. If visible fibrosis was identified during ESD, the presence of submucosal fibrosis was recorded. The extent of atrophic gastritis was classified according to the Kimura and Takemoto classification:<sup>[15]</sup> mild (normal to closed type 2), moderate (closed type 3 to open type 1), and severe (open type 2 to open type 3).

Synchronous lesions were defined as gastric epithelial neoplastic lesions (adenomatous lesions and EGCs) that have already been detected before the initial ESD or found endoscopically and confirmed pathologically with endoscopic forceps biopsy within 1 year of ESD. If multifocal lesions were found during endoscopic examinations, the larger or advanced pathologic lesions were selected as the primary lesions, and the others were termed as synchronous lesions. For each synchronous lesion, endoscopic findings were recorded.

**2.3. Statistical analysis**

Univariate analysis using chi-square test or Fisher exact test for categorical variables and Student *t* test for continuous variables were performed. Multivariate analysis with multiple logistic



**Figure 1.** Study flow.

regression models was performed with associated factors for synchronous or overlooked synchronous lesions.  $P < .05$  was considered statistically significant. Statistical calculations were performed using the Statistical Package for the Social Sciences (SPSS) version 21.0 for Windows (IBM Corp., Armonk, NY).

### 3. Results

#### 3.1. Baseline characteristics of patients who underwent ESD for EGC or high-grade dysplasia

In this study, 488 patients were enrolled (122, 356, and 10 patients with high-grade dysplasia, differentiated cancer, and undifferentiated cancer, respectively). The patient population was predominantly male (78.7%, 384/488), with a mean age of  $69.2 \pm 9.2$  years. The predominant location of the primary lesions was the lower third of the stomach (72.7%, 355/488), and the mean lesion size was  $12.8 \pm 7.9$  mm. The most common gross type was depressed type (57.8%, 282/488) (Table 1). *H pylori* was detected in 58% of patients (283/488), and moderate extent of atrophic gastritis was common (47.7%, 233/488) (Table 1).

#### 3.2. Characteristics of synchronous lesions

The synchronous lesions were termed as “overlooked” if

- (1) endoscopic photos of the lesions were absent before or during ESD;
- (2) endoscopic photos showed lesions before or during ESD, but not endoscopic biopsy; and

**Table 1**  
Baseline clinical characteristics of patients with primary high grade dysplasia or early gastric cancers.

	Total (n=488)
Age, years, mean (SD)	69.2 (9.2)
Gender, male, n (%)	384 (78.7)
Lesion size, mm, mean (SD)	12.8 (7.9)
Presence of synchronous lesion, n (%)	59 (12.1)
Procedure time, min, mean (SD)	25.0 (14.5)
Follow up, month, mean (SD)	37.7 (25.2)
Locations of lesions, n (%)	
Lower third	355 (72.7)
Middle third	104 (21.3)
Upper third	29 (5.9)
Pathologic results of primary lesions, n (%)	
High grade dysplasia	122 (25.0)
Differentiated carcinoma	356 (73.0)
Undifferentiated carcinoma	10 (2.0)
Atrophic gastritis according to the endoscopic examinations, n (%)	
Mild	130 (26.6)
Moderate	233 (47.7)
Severe	125 (25.6)
Morphology of lesions, n (%)	
Elevated	155 (31.8)
Flat	51 (10.5)
Depressed	282 (57.8)
Depth of invasion, n, (%)	
Mucosa	465 (95.3)
Submucosa	23 (4.7)
Presence of <i>Helicobacter pylori</i> infection, n (%)	283 (58.0)

SD=standard deviation.

- (3) pathological analysis following endoscopic forceps biopsy did not reveal neoplastic lesions.

Data were analyzed for patients with and without synchronous lesions (Table 2) and then analyzed for synchronous lesions themselves (Table 4).

#### 3.3. Comparison between patients with and without synchronous lesions

Synchronous lesions were detected in 12.1% (59/488) of patients (Table 2). From univariate analysis, older age, lesion size of  $\geq 16$  mm, extent of atrophic gastritis, morphology of primary lesions, and nodular surface appearance were significant risk factors (Table 2). After multivariate analysis, age of  $\geq 65$  years (odds ratio [OR] 2.192, 95% confidence interval [CI] 1.030–4.666,  $P = .042$ ), moderate to severe atrophic gastritis (OR 2.232, 95% CI 1.012–4.926,  $P = .047$ ), and elevated morphology of primary lesions were significant (OR 2.199, 95% CI 1.191–4.060,  $P = .012$ ) (Table 3).

#### 3.4. Characteristics of the synchronous lesions and risk factor analysis associated with overlooked synchronous lesions

A total of 77 synchronous lesions were found. The patient population was predominantly male (83.1%, 64/77), with a mean age of  $72.9 \pm 8.2$  years. The predominant location of the primary lesions was the lower third of the stomach (72.7%, 56/77), and the mean lesion size was  $12.0 \pm 7.0$  mm. The pathologic diagnoses of synchronous lesions were low-grade dysplasia, differentiated carcinoma, high-grade dysplasia, and undifferentiated carcinoma in 52, 17, 7, and 1 of the cases, respectively. The most common gross type was elevated type (58.4%, 45/77). A total of 25 lesions (32.4%) were diagnosed after initial ESD (overlooked lesions). The reasons for overlooked lesions were as follows: absence of endoscopic photos (32%, 8/25), presence of endoscopic photos without biopsy (56%, 14/25), and non-diagnostic endoscopic forceps biopsy results (12%, 3/25) (Table 4).

The characteristics associated with overlooked synchronous lesions were analyzed. From the univariate analysis, the morphology of synchronous lesions, whitish discoloration, redness, and erosive changes were significant (Table 5). After multivariate analysis, flat or depressed morphology was the only significant risk factor (OR 4.329, 95% CI 1.219–15.384,  $P = .023$ ) (Table 6). Among the synchronous lesions, most of the lesions could be resected with ESD (85.7%, 66/77). Surgical resection was performed in 3 patients (2 differentiated EGC and 1 undifferentiated EGC). Because of patients’ refusal of treatment, 8 lesions resectable with ESD was not resected (6 low-grade dysplasia and 2 differentiated EGC) (Fig. 2). During follow-up examinations, gastric cancer-related mortality was absent.

### 4. Discussion

In the present study, synchronous gastric epithelial neoplasia was detected in 12.1% of patients. Other studies reported about approx 6.8% to 8.1% incidence of synchronous gastric cancers after endoscopic resection of EGC.<sup>[12,16]</sup> Because we included the adenomatous lesions as synchronous lesions, the incidence of synchronous lesions may be higher than previous reported studies. After exclusion of low-grade dysplasia as synchronous

**Table 2**

**Clinicopathologic differences between patients with synchronous and without synchronous lesions.**

	Patients without synchronous lesions (n = 429)	Patients with synchronous lesions (n = 59)	Total (n = 488)	P value
Age, years, mean (SD)	68.7 (9.1)	72.7 (9.0)	69.2 (9.2)	.002
Age ≥ 65 years, n (%)	289 (67.4)	50 (84.7)	339 (69.5)	.007
Sex, male, n (%)	337 (78.6)	47 (79.7)	384 (78.7)	.843
Lesion size, mm, mean (SD)	12.522 (7.536)	15.627 (9.832)	12.898 (7.903)	.005
Lesion size ≥ 16 mm, n (%)	118 (27.5)	24 (40.7)	142 (29.1)	.037
Procedure time, min, mean (SD)	25.329 (15.087)	23.034 (9.303)	25.051 (14.522)	.256
Follow up, month, mean (SD)	38.22 (25.763)	34.19 (20.911)	37.74 (25.240)	.250
Locations of primary lesions, n (%)				.324
Lower third	311 (72.5)	44 (74.6)	355 (72.7)	
Middle third	90 (21.0)	14 (23.7)	104 (21.3)	
Upper third	28 (6.5)	1 (1.7)	29 (5.9)	
Pathologic results of primary lesions, n (%)				.067
High grade dysplasia	100 (23.3)	22 (37.3)	122 (25.0)	
Differentiated carcinoma	320 (74.6)	36 (61.0)	356 (73.0)	
Undifferentiated carcinoma	9 (2.1)	1 (1.7)	10 (2.0)	
Atrophic gastritis according to the endoscopic examinations, n (%)				.006
Mild	122 (28.4)	8 (13.6)	130 (26.6)	
Moderate	206 (48.0)	27 (45.8)	233 (47.7)	
Severe	101 (23.5)	24 (40.7)	125 (25.6)	
Morphology of primary lesions, n (%)				<.001
Elevated	124 (28.9)	31 (52.5)	155 (31.8)	
Flat	43 (10.0)	8 (13.6)	51 (10.5)	
Depressed	262 (61.1)	20 (33.9)	282 (57.8)	
Elevated lesion, n (%)	124 (28.9)	31 (52.5)	155 (31.8)	<.001
Depressed lesion, n (%)	262 (61.1)	20 (33.9)	282 (57.8)	<.001
Changes of surface appearance				
Ulcer, n (%)	35 (8.2)	4 (6.8)	39 (8.0)	.714
Fibrosis, n (%)	112 (26.1)	13 (22.0)	125 (25.6)	.502
Whitish, n (%)	280 (65.3)	40 (67.8)	320 (65.6)	.702
Redness, n (%)	413 (96.3)	54 (91.5)	467 (95.7)	.092
Nodularity, n (%)	111 (25.9)	23 (39.0)	134 (27.5)	.034
Depression, n (%)	182 (42.4)	22 (37.3)	204 (41.8)	.453
Erosion, n (%)	187 (43.6)	21 (35.6)	208 (42.6)	.244
Depth of invasion, n (%)				.886
Mucosa	409 (95.3)	56 (94.9)	465 (95.3)	
Submucosa	20 (4.7)	3 (5.1)	23 (4.7)	
Presence of Helicobacter pylori infection, n (%)	251 (58.5)	32 (54.2)	283 (58.0)	.533

SD = standard deviation.

lesions (n = 52), the incidence of synchronous lesions was 5.1%. The benefit of ESD compared with surgical gastrectomy is the preservation of the stomach and the significant improvement in the quality of life. If synchronous lesions are found within 12 months after initial ESD, the lesions might be overlooked or missed before or during initial ESD. If the synchronous lesions have high risk of lymph node metastasis, additive surgical

resection should be considered. In the present study, additive surgical gastrectomies were performed in 3 patients after diagnosis of deep submucosal cancer after ESD. During the follow-up period, gastric cancer-related mortality was absent.

The associated clinical factors with the occurrence of multiple synchronous gastric epithelial neoplasia were age of ≥65 years, moderate to severe atrophic gastritis, and elevated morphology of primary lesions. Gastric cancer is a common gastrointestinal malignancy in the Republic of Korea. The prevalence of *H pylori* infection in adults was reported as 59.6% in 2005.<sup>19</sup> There was no statistically significant difference according to *H pylori* infection in this study. *H pylori* eradication may induce regression in pre-existing adenomatous lesions or delay the occurrence of metachronous lesions rather than curing synchronous lesions. The effect of the eradication is likely to inhibit the progression or remain stable rather than histological recovery of synchronous lesions.<sup>17–20</sup> The mean age of the present study was 69.2 ± 9.2 years. The reported prevalence of atrophic gastritis over 60 years in Korea

**Table 3**

**Risk factor analysis associated with synchronous lesions: multivariate analysis.**

Characteristic	Adjusted OR (95% CI)	P value
Age ≥ 65 years	2.192 (1.030–4.666)	.042
Lesion size ≥ 16 mm	1.443 (0.791–2.631)	.231
Moderate to severe atrophic gastritis	2.232 (1.012–4.926)	.047
Elevated morphology of primary lesions	2.199 (1.191–4.060)	.012
Nodular surface appearance	1.158 (0.607–2.207)	.654

CI = confidence interval, OR = odd ratio.

**Table 4**  
**Primary characteristics of synchronous lesions.**

	Total (n=77)
Age, years, mean (SD)	72.9 (8.2)
Gender, male, n (%)	64 (83.1)
Lesion size, mm, mean (SD)	12.0 (7.0)
Primary lesion size, mm, mean (SD)	16.1 (9.3)
Follow up, month, mean (SD)	29.5 (20.4)
Locations of synchronous lesions, n (%)	
Lower third	56 (72.7)
Middle third	16 (20.8)
Upper third	5 (6.5)
Pathologic diagnosis of synchronous lesions, n (%)	
Low grade dysplasia	52 (67.5)
High grade dysplasia	7 (9.7)
Differentiated carcinoma	17 (22.1)
Undifferentiated carcinoma	1 (1.3)
Pathologic diagnosis of primary lesion, n (%)	
High grade dysplasia	29 (37.7)
Differentiated carcinoma	46 (59.7)
Undifferentiated carcinoma	2 (2.6)
Atrophic gastritis according to the endoscopic examinations, n (%)	
Mild	7 (9.1)
Moderate	33 (42.9)
Severe	37 (48.1)
Morphologic of synchronous lesions, n (%)	
Elevated	45 (58.4)
Flat	12 (15.6)
Depressed	20 (26.0)
Invasion depth of synchronous lesions, n (%)	
Mucosa	75 (97.4)
Submucosa	2 (2.6)
Reasons of overlooked lesions, n (%)	25 (32.4)
Absence of endoscopic photos, n (%)	8 (32)
Presence of endoscopic photos, absent biopsy, n (%)	14 (56)
Not diagnostic endoscopic forceps biopsy results, n (%)	3 (12)
Presence of <i>Helicobacter pylori</i> infection, n (%)	39 (50.6)

SD=standard deviation.

was 66.9% to 69.5% in the antrum and 43.7% to 44.5% in the body.<sup>[11]</sup> Previous studies reported that the cumulative incidence of gastric cancer was highly associated with the extent of atrophic gastritis.<sup>[21]</sup> Gastric cancer may occur in 10% of severe atrophic gastritis (open type 2–3 according to the Kimura–Takemoto classification).<sup>[15,21]</sup> The reason of elevated morphologic lesions as associated occurrence of synchronous lesions remains unclear.

Among the synchronous lesions, 32.4% of the lesions were not detected before or during initial ESD. Among the 25 overlooked or missed lesions, 22 lesions had no endoscopic photo or absent endoscopic forceps biopsy. Even if the synchronous lesions were captured on images, endoscopists were not recognized as a lesion and inappropriate targeting biopsy or poor biopsy tissue also could increase the incidence of synchronous lesions. Endoscopists require much effort to increase the diagnostic rate of EGC already present. High-definition white light endoscopy may detect minute EGC. Narrow band imaging (NBI) may be helpful in finding the lesion after the white light endoscopic evaluation in characterizing and distinguishing EGC and margins. However NBI is not used to evaluate the whole stomach as to replace conventional endoscopy. Standardized endoscopic examinations, such as adequate air insufflation to separate the gastric folds, irrigation

to remove mucous, and mapping the stomach with photo documentation, are important.<sup>[22]</sup> Nevertheless, evaluating these parameters may be difficult and no useful index has been developed. Key endoscopic characteristics of EGC such as changes in the surface (elevated or depressed lesions), changes in color (whitish or reddish), and spontaneous bleeding should be paid more attention during endoscopic examinations.<sup>[23]</sup> The most important endoscopic factor associated with overlooked synchronous lesions was a flat or depressed morphology. To decrease the miss rate of these lesions, adequate time of endoscopic examination may be important. Previous studies reported that examination time is a possible indicator of quality of upper gastrointestinal endoscopy for asymptomatic patients.<sup>[24,25]</sup> Endoscopists who do not use adequate time may overlook neoplastic lesions. Endoscopists' experience might be a possible important factor. A previous study reported that the miss rate was associated with the endoscopist's inexperience (<500 endoscopic cases).<sup>[26]</sup> To increase the rate of finding the lesion, endoscopist with more than a year of experience have carried out diagnostic exams and confirming the lesions by experienced endoscopist before finishing the exams in our study.

Among the overlooked lesions, nondiagnostic endoscopic forceps biopsy results were found in 3 lesions. Although endoscopic forceps biopsy was the most important diagnostic tool before resection, diagnostic discrepant results between endoscopic forceps biopsy and resected specimen may be present. We previously reported the follow-up results of nondiagnostic endoscopic forceps biopsy. Among gastric indefinite neoplasia from endoscopic forceps biopsy, 21.8% of the lesions were diagnosed as EGC during follow-up.<sup>[27]</sup> Therefore, follow-up endoscopic examinations and repeated endoscopic forceps biopsy are necessary for suspicious neoplastic lesions. Regular surveillance examination is important to detect overlooked synchronous lesions before progressing to invasive cancers. In the present study, the scheduled endoscopic examinations were performed 3 months after the initial ESD, and regular endoscopic examinations were recommended every 6 months for 2 years and annually thereafter. The cancer-related mortality was absent. Another previous study reported advanced gastric cancer detected more than 1 year after ESD in 0.12% cases. Based on these findings, follow-up endoscopic examinations within 1 year after initial ESD are strongly recommended.

The present study has several limitations. First, it was conducted in a single center, and the sample size might be small to generalize the results. Also, there were potential information biases due to the retrospective design of this study. However, the results of the present and other studies, so far, are informative and recommend the use of caution during endoscopic treatment before or after of ESD. Second, although intestinal metaplasia is an important premalignant factor, the severity of intestinal metaplasia could not be examined because biopsy was not routinely performed in Korea to diagnose atrophic gastritis or intestinal metaplasia. Secondary change due to intestinal metaplasia would mask the pre-existing lesions. The procedure time which is 1 of the important factors of diagnosing the lesion also could not be measured because of the retrospective study design. Third, there was heterogeneity in the experience of the endoscopist performing the procedures. Diagnostic rate would be increased in case of an expert, however as this cannot be generalized and this could be 1 of limitations.

**Table 5**

**Comparisons between detected and overlooked synchronous lesions: univariate analysis.**

	Detected during before ESD of primary lesions (n=52)	Detected after ESD of primary lesions (n=25)	Total (n=77)	P value
Age, years, mean (SD)	73.2 (7.8)	72.2 (9.3)	72.9 (8.2)	.606
Age ≥ 65 years, n (%)	46 (88.5)	21 (84.0)	67 (87.0)	.586
Gender, male, n (%)	42 (80.8)	22 (88.0)	64 (83.1)	.428
Lesion size, mm, mean (SD)	11.9 (6.7)	12.0 (7.9)	12.0 (7.0)	.955
Primary lesion size, mm, mean (SD)	16.5 (9.3)	15.2 (9.5)	16.1 (9.3)	.579
Lesion size ≥ 16 mm, n (%)	12 (23.1)	7 (28.0)	19 (24.7)	.639
Follow up, month, mean (SD)	30.1 (20.4)	28.3 (20.6)	29.5 (20.4)	.709
Locations of synchronous lesions, n (%)				.811
Lower third	37 (71.2)	19 (76.0)	56 (72.7)	
Middle third	11 (21.2)	5 (20.0)	16 (20.8)	
Upper third	4 (7.7)	1 (4.0)	5 (6.5)	
Different locations between primary and synchronous lesions, n (%)	22 (42.3)	10 (40.0)	32 (41.6)	.847
Pathologic diagnosis of synchronous lesions, n (%)				.065
Low grade dysplasia	39 (75.0)	13 (52.0)	52 (67.5)	
High grade dysplasia	5 (9.6)	2 (8.0)	7 (9.7)	
Differentiated carcinoma	7 (13.5)	10 (40.0)	17 (22.1)	
Undifferentiated carcinoma	1 (1.9)	0 (0)	1 (1.3)	
Pathologic diagnosis of primary lesion, n (%)				.486
High grade dysplasia	18 (34.6)	11 (44.0)	29 (37.7)	
Differentiated carcinoma	32 (61.5)	14 (56.0)	46 (59.7)	
Undifferentiated carcinoma	2 (3.8)	0 (0)	2 (2.6)	
Atrophic gastritis according to the endoscopic examinations, n (%)				.098
Mild	3 (5.8)	4 (16.0)	7 (9.1)	
Moderate	20 (38.5)	13 (52.0)	33 (42.9)	
Severe	29 (55.8)	8 (32.0)	37 (48.1)	
Morphology of lesions, n (%)				.001
Elevated	38 (73.1)	7 (28.0)	45 (58.4)	
Flat	4 (7.7)	8 (32.0)	12 (15.6)	
Depressed	10 (19.2)	10 (40.0)	20 (26.0)	
Changes of surface appearance				
Ulcer, n (%)	2 (3.8)	2 (8.0)	4 (5.2)	.442
Fibrosis, n (%)	6 (11.5)	6 (24.0)	12 (15.6)	.158
Whitish, n (%)	48 (92.3)	18 (72.0)	66 (85.7)	.017
Redness, n (%)	27 (51.9)	20 (80.0)	47 (61.0)	.018
Nodularity, n (%)	13 (25.0)	4 (16.0)	17 (22.1)	.373
Depression, n (%)	10 (19.2)	7 (28.0)	17 (22.1)	.385
Erosion, n (%)	5 (9.6)	8 (32.0)	13 (16.9)	.014
Depth of invasion, n, (%)				.32
Mucosa	50 (96.2)	25 (100)	75 (97.4)	
Submucosa	2 (3.8)	0 (0)	2 (2.6)	
Presence of Helicobacter pylori infection, n (%)	24 (46.2)	15 (60.0)	39 (50.6)	.255

ESD=endoscopic submucosal dissection, SD=standard deviation.

In summary, synchronous gastric epithelial neoplasia was found in 12.1% of patients, and 32.4% of synchronous lesions were not diagnosed adequately before or during initial ESD. Patients' age of ≥65 years, moderate to severe atrophic gastritis, and elevated morphology of primary lesions were found to be

high-risk factors associated with the presence of synchronous lesions. A flat or depressed morphology of lesions might be overlooked during evaluation. Regular follow-up endoscopic examination within 1 year of ESD should be considered to detect overlooked lesions before they progress to invasive cancer.

**Table 6**

**Risk factor analysis associated with overlooked synchronous lesions: multivariate analysis.**

Characteristic	OR (95% CI)	P value
Flat or depressed morphology	4.329 (1.219–15.384)	0.023
White discoloration	0.615 (0.129–2.923)	0.542
Redness	2.150 (0.607–7.633)	0.235
Erosion	1.694 (0.401–7.142)	0.472

CI=confidence interval, OR=odd ratio.

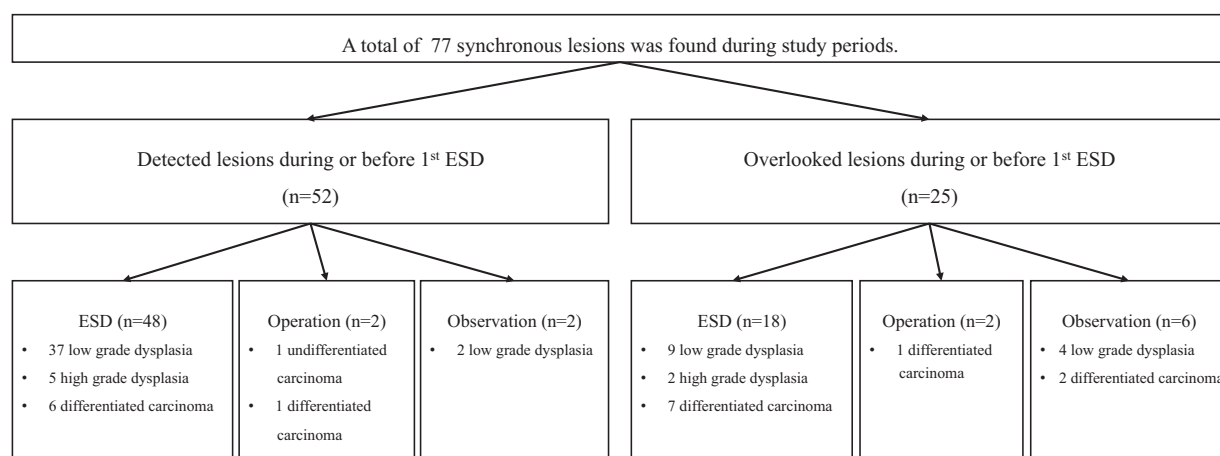


Figure 2. Clinical outcomes of synchronous lesions. ESD=endoscopic submucosal dissection.

**Author contributions**

**Conceptualization:** Cheol Woong Choi.

**Formal analysis:** Cheol Woong Choi.

**Investigation:** Hyung Wook Kim, Cheol Woong Choi, Dae Hwan Kang, Su Bum Park, Su Jin Kim, Hyeong Seok Nam.

**Supervision:** Cheol Woong Choi.

**Validation:** Jung Sik Choi.

**Writing – original draft:** Hyeong Seok Nam, Hyung Wook Kim, Cheol Woong Choi.

**Writing – review & editing:** Cheol Woong Choi, Hyeong Seok Nam.

Cheol Woong Choi orcid: 0000-0001-8867-3039

**References**

- [1] Ahn HS, Lee HJ, Hahn S, et al. Evaluation of the seventh american joint committee on cancer/international union against cancer classification of gastric adenocarcinoma in comparison with the sixth classification. *Cancer* 2010;116:5592–8.
- [2] Suh M, Choi KS, Lee YY, et al. Cancer screening in Korea, 2012: results from the Korean National Cancer Screening Survey. *Asian Pac J Cancer Prev* 2013;14:6459–63.
- [3] Jeong O, Park YK. Clinicopathological features and surgical treatment of gastric cancer in South Korea: the results of 2009 nationwide survey on surgically treated gastric cancer patients. *J Gastric Cancer* 2011;11: 69–77.
- [4] Japanese Gastric Cancer A. Japanese gastric cancer treatment guidelines 2014 (ver. 4). *Gastric Cancer* 2017;20:1–9.
- [5] Lee JH, Kim JG, Jung HK, et al. Clinical practice guidelines for gastric cancer in Korea: an evidence-based approach. *J Gastric Cancer* 2014;14:87–104.
- [6] Kim YI, Kim YW, Choi IJ, et al. Long-term survival after endoscopic resection versus surgery in early gastric cancers. *Endoscopy* 2015;47: 293–301.
- [7] Min BH, Kim ER, Kim KM, et al. Surveillance strategy based on the incidence and patterns of recurrence after curative endoscopic submucosal dissection for early gastric cancer. *Endoscopy* 2015;47: 784–93.
- [8] Ahn JY, Jung HY, Choi KD, et al. Endoscopic and oncologic outcomes after endoscopic resection for early gastric cancer: 1370 cases of absolute and extended indications. *Gastrointest Endosc* 2011;74:485–93.
- [9] Lim SH, Kwon JW, Kim N, et al. Prevalence and risk factors of *Helicobacter pylori* infection in Korea: nationwide multicenter study over 13 years. *BMC Gastroenterol* 2013;13:104.
- [10] Park YH, Kim N. Review of atrophic gastritis and intestinal metaplasia as a premalignant lesion of gastric cancer. *J Cancer Prev* 2015;20:25–40.

- [11] Eshmuratov A, Nah JC, Kim N, et al. The correlation of endoscopic and histological diagnosis of gastric atrophy. *Dig Dis Sci* 2010;55:1364–75.
- [12] Nishida T, Tsujii M, Kato M, et al. Endoscopic surveillance strategy after endoscopic resection for early gastric cancer. *World J Gastrointest Pathophysiol* 2014;5:100–6.
- [13] The paris endoscopic classification of superficial neoplastic lesions: esophagus, stomach, and colon: November 30 to December 1, 2002. *Gastrointest Endosc*. 2003; 58:S3–43.
- [14] Japanese Gastric Cancer Association Japanese classification of gastric carcinoma: 3rd English edition. *Gastric Cancer* 2011;14:101–12.
- [15] Mihara M, Haruma K, Kamada T, et al. The role of endoscopic findings for the diagnosis of *Helicobacter pylori* infection: evaluation in a country with high prevalence of atrophic gastritis. *Helicobacter* 1999;4:40–8.
- [16] Lee HJ, Lee YJ, Lee JY, et al. Characteristics of synchronous and metachronous multiple gastric tumors after endoscopic submucosal dissection of early gastric neoplasm. *Clin Endosc* 2018;51:266–73.
- [17] Hwang YJ, Kim N, Lee HS, et al. Reversibility of atrophic gastritis and intestinal metaplasia after *Helicobacter pylori* eradication—a prospective study for up to 10 years. *Aliment Pharmacol Ther* 2018;47:380–90.
- [18] Nam SY, Park BJ, Ryu KH, et al. Effect of *Helicobacter pylori* infection and its eradication on the fate of gastric polyps. *Eur J Gastroenterol Hepatol* 2016;28:449–54.
- [19] Suzuki S, Gotoda T, Suzuki H, et al. Morphologic and histologic changes in gastric adenomas after helicobacter pylori eradication: a long-term prospective analysis. *Helicobacter* 2015;20:431–7.
- [20] Mera RM, Bravo LE, Camargo MC, et al. Dynamics of *Helicobacter pylori* infection as determinant of progression of gastric precancerous lesions: 16-year follow-up of an eradication trial. *Gut* 2018;67:1239–46.
- [21] Shichijo S, Hirata Y, Niikura R, et al. Histologic intestinal metaplasia and endoscopic atrophy are predictors of gastric cancer development after *Helicobacter pylori* eradication. *Gastrointest Endosc* 2016;84: 618–24.
- [22] Yao K. The endoscopic diagnosis of early gastric cancer. *Ann Gastroenterol* 2013;26:11–22.
- [23] Uedo N, Yao K, Ishihara R. Screening and treating intermediate lesions to prevent gastric cancer. *Gastroenterol Clin North Am* 2013;42: 317–35.
- [24] Kawamura T, Wada H, Sakiyama N, et al. Examination time as a quality indicator of screening upper gastrointestinal endoscopy for asymptomatic examinees. *Dig Endosc* 2017;29:569–75.
- [25] Park JM, Huo SM, Lee HH, et al. Longer observation time increases proportion of neoplasms detected by esophagogastroduodenoscopy. *Gastroenterology* 2017;153:460–9 e461.
- [26] Kato M, Nishida T, Yamamoto K, et al. Scheduled endoscopic surveillance controls secondary cancer after curative endoscopic resection for early gastric cancer: a multicentre retrospective cohort study by Osaka University ESD study group. *Gut* 2013;62:1425–32.
- [27] Goo JJ, Choi CW, Kang DH, et al. Risk factors associated with diagnostic discrepancy of gastric indefinite neoplasia: who need en bloc resection. *Surg Endosc* 2015;29:3761–7.