

## Case Report

# Gliosarcoma with long progression free survival: A case report and literature review

Alireza Tabibkhouei, Arash Fattahi, Feizollah Ebrahimnia

Department of Neurosurgery, Iran University of Medical Sciences, Tehran, Iran

E-mail: Alireza Tabibkhouei - [alireza.tabibkhouei@gmail.com](mailto:alireza.tabibkhouei@gmail.com); \*Arash Fattahi - [arashmedicine@gmail.com](mailto:arashmedicine@gmail.com); Feizollah Ebrahimnia - [feize23@gmail.com](mailto:feize23@gmail.com)

\*Corresponding author

Received: 11 July 18 Accepted: 24 September 18 Published: 05 November 18

## Abstract

**Background:** Gliosarcoma (GS) is a primary rare malignant brain tumor that accounts 4% of all high-grade glial tumor of the brain.

**Case Description:** We present a 45-year-old female admitted to our center with progressive headache since 1 month ago concomitant with nausea and emesis and generalized weakness. Imaging revealed a large solid mass with well-defined margin and some cystic portions that enhanced brightly with contrast. We decided to operate the patient via right parietal craniotomy and we totally resected all visible portions of the mass, as en bloc resection. The histopathological report of the mass was GS. We are following the patient up to now, for about 50 months, and she is good without any compliant or neurologic deficit. All follow-up magnetic resonance imaging (MRI) did not show any tumor recurrence.

**Conclusion:** Aiming to achieve longer progression-free survival in cases of GS, we recommend resecting all portions of the mass as much as possible, so named en bloc resection, and then refer the patients for appropriate and timely chemoradiotherapy.

**Key Words:** En bloc resection, gliosarcoma, overall survival, progression-free survival

### Access this article online

**Website:**[www.surgicalneurologyint.com](http://www.surgicalneurologyint.com)**DOI:**

10.4103/sni.sni\_225\_18

**Quick Response Code:**

## BACKGROUND

Gliosarcoma (GS) is a primary rare malignant brain tumor that contains both gliomatous and sarcomatous (mesenchymal) components and accounts 4% of all high-grade glial tumor of the brain.<sup>[6]</sup> Based on the 2007 World Health Organization (WHO) classification, GS is a Grade 4 tumor same as glioblastoma multiform (GBM).<sup>[8]</sup> In the literature, mean overall survival (OS) of GS in untreated patients is 4 months and with multidisciplinary tri-modal therapy, the mean OS is about 15 months.<sup>[10]</sup> We present a patient with GS that we treated her and she has 50 months disease-free survival up to now.

## CASE DESCRIPTION

We present a 45-year-old female admitted to our center with progressive headache since 1 month ago concomitant

with nausea, emesis, and generalized weakness. She had minimal headache since 2 years ago and, on admission clinical examination, we did not find any neurologic deficits. Also, the patient had bilateral pupillary edema on fundoscopy. She had bilateral positive Hoffmann's sign. On first brain computed tomography (CT), we saw a large heterogeneous mass with some vasogenic edema

This is an open access journal, and articles are distributed under the terms of the Creative Commons Attribution-NonCommercial-ShareAlike 4.0 License, which allows others to remix, tweak, and build upon the work non-commercially, as long as appropriate credit is given and the new creations are licensed under the identical terms.

**For reprints contact:** [reprints@medknow.com](mailto:reprints@medknow.com)

**How to cite this article:** Tabibkhouei A, Fattahi A, Ebrahimnia F. Gliosarcoma with long progression free survival: A case report and literature review. *Surg Neurol Int* 2018;9:227.

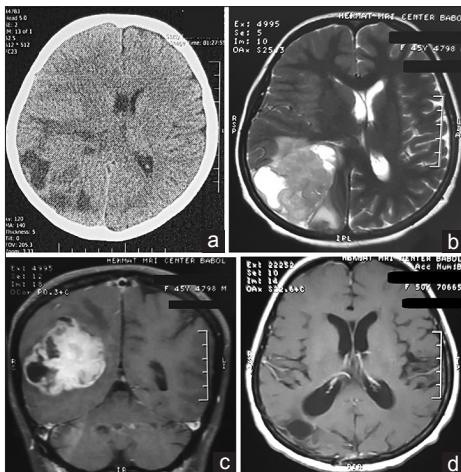
<http://surgicalneurologyint.com/Gliosarcoma-with-long-progression-free-survival-A-case-report-and-literature-review/>

at right parieto-occipital region with 0.5 cm midline shift that compressed right occipital horn of lateral ventricle [Figure 1a]. The brain magnetic resonance imaging (MRI) with and without gadolinium (Gd) revealed a large solid mass with well-defined margin and some cystic portions that enhanced brightly with Gd [Figure 1b and c]. The vasogenic edema was less than our expectation.

According to very large mass effect, we decided to operate the patient via right parietal craniotomy. The tumor had a more firm consistency compared with adjacent normal brain tissue and it was well demarcated and we totally resected all visible portions of the mass, as en bloc resection. The histopathological report of the mass was GS [Figure 2a–d]. After surgical treatment, the patient's treatment continued by chemotherapy with temozolamide and a course of radiotherapy. We are following the patient up to now, for about 50 months, and she is good without any compliant or neurologic deficit. All follow-up MRI did not show any tumor recurrence [Figure 1d].

## DISCUSSION

The GS, as known Feigin tumor, is a rare and malignant glioma.<sup>[3]</sup> With best existing tri-modal therapy, contained surgical gross total resection and then chemoradiotherapy, this tumor has very poor prognosis.<sup>[10]</sup> For GS, histopathological exam shows both gliomatous and sarcomatous components. At the surgery compared with GBM, the borders of tumor are more distinct because of presence of sarcomatous component, but on the other hand, the patients have less response to adjuvant treatment contained chemotherapy and radiotherapy during postoperative period.



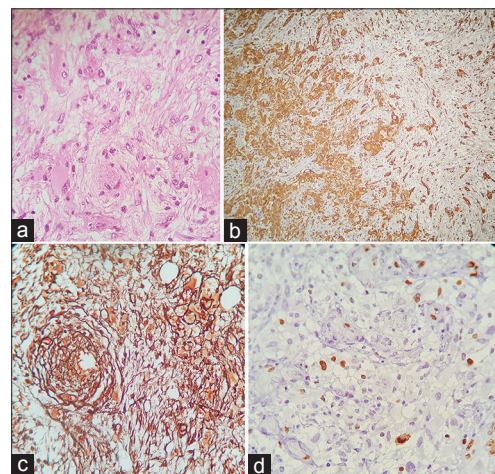
**Figure 1:** Preoperative brain computed tomography scan (a) of the patient revealed a large heterogeneous mass at right parieto-occipital region with some vasogenic edema that produces a 0.5 cm midline shift of the brain. On the brain magnetic resonance imaging, we found a solid-cystic hyper-intense mass on T2 sequences (b) that it is brightly enhanced after injection of gadolinium (c). Follow-up brain magnetic resonance imaging with gadolinium revealed no remnant of tumor (d)

In the literature, we found only eight reports of GS with OS >2 years [Table 1]. Considering the term of survival, we have to pay attention to this subject that the “overall survival” is different with “progression-free survival” (PFS). The patients with longer OS have not necessarily longer PFS and they may have multiple recurrence period needed complete treatment courses that patients suffered from them. Longer PSF can predict more excellent quality of life (QOL). Compared with our case, only four reports of GS had a longer OS concomitant with long PFS.<sup>[1,4,9,10]</sup>

Although in almost all cases, infiltrative nature of gliomatous tumors hinder to remove all portions of them, because of sarcomatous components of GS, differences in consistency of tumoral tissue compared with brain tissue assist to define a relatively well-demarcated plane between them during surgery. In addition, en bloc resection with preservation of tissue planes during dissection prevents missing any tumor component intermingled with brain parenchyma at the time of dissection. Finally, location of the lesion in non-eloquent area of brain lets intraoperative manipulations and more feasible en bloc tumor removal. We think all these factors together in association with appropriate and timely adjuvant therapy helps surgeon to give the most chance of PFS to the patient with GS.

## CONCLUSION

We present a patient with GS that has a long PFS after surgical treatment. Aiming to achieve longer PFS in cases of GS and regarding to more distinct consistency, we recommend resecting all portions of the mass, as much as possible, to reach en bloc resection and then refer the patients for appropriate and timely chemoradiotherapy.



**Figure 2:** Histopathologic finding revealed a biphasic tumor with alternating between glial and mesenchymal differentiation (a, H and E × 400). Immunohistochemically (IHC), we see G-FAP positive portions (negative for reticulin, b × 100) and in concomitant with reticulin-rich portions (negative for G-FAP, c × 400) in other sites. Also, we can see positive staining for Ki-67 (d × 400)

**Table 1: A literature review for all reported cases with GS and longer OS**

Author/year	Patient's age (years old)/sex	Presenting signs and symptoms	Site of tumor	OS	PFS	Number of recurrences	Presence of metastasis
Winkler <i>et al.</i> <sup>[10]</sup>	61/female	Headache	Left parietal	22 years	20 years	1	No
Chen <i>et al.</i> <sup>[2]</sup>	31/female	Dizziness, headache, vomiting	Right temporal	92 months	46 months	2	Yes
Linhares <i>et al.</i> <sup>[7]</sup>	51/female	N/A	Left hemi-body paresthesia, seizure, dysarthria	36 months	21 months	1	No
Huo <i>et al.</i> <sup>[4]</sup>	47/male	Headache, right leg weakness	Left lateral ventricle (frontal horn), corpus callosum	N/A	130 months	No	No
Huo <i>et al.</i> <sup>[4]</sup>	63/female	Headache, nausea	Right temporal	N/A	48 months	No	No
Burzynski <i>et al.</i> <sup>[1]</sup>	9/male	Seizure, vomiting	Right temporal, pons	N/A	13 years	1	Yes
Kalita <i>et al.</i> <sup>[5]</sup>	23/female	Headache, nausea, vomiting, left arm weakness	Right frontal, right lateral ventricle	31 months (alive until the time of article publication)	28 months	1	No
Wang <i>et al.</i> <sup>[9]</sup>	21/male	Headache	Right frontal	Alive until the time of article publication	111 months	1 as a meningeal sarcoma	No
Tabibkhouei <i>et al.</i> (2018) current study	45/female	Headache, nausea, vomiting, generalized weakness	Right parieto-occipital	Alive until the time of article publication	50 months	No	No

N/A=Not available

### Declaration of patient consent

The authors certify that they have obtained all appropriate patient consent forms. In the form the patient(s) has/have given his/her/their consent for his/her/their images and other clinical information to be reported in the journal. The patients understand that their names and initials will not be published and due efforts will be made to conceal their identity, but anonymity cannot be guaranteed.

### Financial support and sponsorship

Nil.

### Conflicts of interest

There are no conflicts of interest.

### REFERENCES

- Burzynski SR, Janicki TJ, Burzynski GS, Marszalek A. Long-term survival (>13 years) in a child with recurrent diffuse pontine gliosarcoma: A case report. *J Pediatr Hematol Oncol* 2014;36:e433-9.
- Chen L, Xiao H, Xu L, Zou Y, Zhang Y, Xu M. A case study of a patient with gliosarcoma with an extended survival and spinal cord metastases. *Cell Biochem Biophys* 2012;62:391-5.
- Feigin IH, Gross SW. Sarcoma arising in glioblastoma of the brain. *Am J Pathol* 1955;31:633-53.
- Huo Z, Yang D, Shen J, Li Y, Wu H, Meng Y, *et al.* Primary gliosarcoma with long-survival: Report of two cases and review of literature. *Int J Clin Exp Pathol* 2014;7:6323-32.
- Kalita O, Zlevorova M, Megova M, Vaverka M, Trojanec R, Tuckova L. A patient with primary intraventricular gliosarcoma and long-term survival-A case report. *Klin Onkol* 2016;29:454-9.
- Karsy M, Gelbman M, Shah P, Balumbu O, Moy F, Arslan E. Established and emerging variants of glioblastoma multiforme: Review of morphological and molecular features. *Folia Neuropathol* 2012;50:301-21.
- Linhares P, Martinho O, Carvalho B, Castro L, Lopes JM, Vaz R, *et al.* Analysis of a synchronous gliosarcoma and meningioma with long survival: A case report and review of the literature. *Surg Neurol Int* 2013;4:151.
- Louis DN, Ohgaki H, Wiestler OD, Cavenee WK, Burger PC, Jouvet A, *et al.* The 2007 WHO classification of tumours of the central nervous system. *Acta Neuropathol* 2007;114:97-109.
- Wang Z, Kong QT, Wu XH, Zhu XX. Long-term survival in gliosarcoma with radiation-induced meningeal sarcomas: Case report and molecular features. *J Cancer Res Ther* 2015;11:651.
- Winkler PA, Buttner A, Tomezzoli A, Weis S. Histologically repeatedly confirmed gliosarcoma with long survival: Review of the literature and report of a case. *Acta Neurochir (Wien)* 2000;142:91-5.