

# Unilateral Pulsatile Tinnitus Associated with an Internal Carotid Artery–Eustachian Tube Dehiscence

Maaïke Rathé, MD<sup>1</sup>, Fabienne Govaere, MD<sup>2</sup>, and Glen E. J. Forton, MD, PhD<sup>1,3</sup>

No sponsorships or competing interests have been disclosed for this article.

## Keywords

pulsatile tinnitus, internal carotid artery, eustachian tube, dehiscence, middle ear

Received October 23, 2017; revised October 23, 2017; accepted December 22, 2017.

A dehiscence of the petrous segment of the internal carotid artery (ICA) is an anatomic variation in which the bony covering of the ICA is partially absent. It has a prevalence in temporal bones of 7.7%<sup>1</sup> and can be associated with pulsatile tinnitus,<sup>2</sup> which, in our experience, is a complaint with increasing incidence in the daily practice.

## Case Report

A 59-year-old female patient with no relevant antecedents, except for cervical complaints, presented with an intermittent right-sided loud low-frequency tinnitus that had been present about 1 month. A pulsatile component, synchronous with her pulse, progressively became apparent during the morning and could also be influenced by cervical movements. Otomicroscopy revealed no abnormalities on either side. Cervical examination showed a bilaterally limited range of motion and pain at the level of the facet joints of C4 to C5. Ophthalmological, vestibular, and neurological clinical examinations were not performed, nor was auscultation. A symmetric mild high-frequency sensorineural hearing loss was found on conventional 125- to 8000-Hz audiometric evaluation, suggestive of a mild presbycusis. Tympanometry bilaterally showed a type A curve and normal stapedius muscle reflexes. Tinnitus analysis revealed that it was predominantly present on the right side and partially maskable by a 60-dB tone with residual inhibition over 5 minutes.

A symptomatic treatment comprising counseling about the tinnitus, cinnarizine 25 mg 3 tid, piracetam 1200 mg 3 tid, alprazolam 0.5 mg qd, and a combination of 10 mg

melitracen and flupentixol 0.5 mg qd was prescribed. Computed tomography (CT) of the cervical spine clearly demonstrated cervical arthrosis of the facet joints at the level of C4 to C5 and a mild medial protrusion of the cervical discus at the level of C3 to C4. Therefore, a low-dose corticoid infiltration of the facet joints was performed, thus relieving the painful cervical complaints but with little or no effect on the pulsatile tinnitus.

Follow-up audiometry 5 weeks later showed a discrete improvement on high frequencies but no improvement of the pulsatile tinnitus whatsoever. When performing the stapedius reflex decay test without administering stimulation, a pulsatile movement of the baseline (about 72 bpm) could be observed. Magnetic resonance imaging (MRI) of the posterior cranial fossa and magnetic resonance angiography (MRA) of the circle of Willis could not demonstrate an obvious neurovascular conflict. No other vascular malformations, arteriovenous malformations, sinus thromboses, stenoses, signs of benign intracranial hypertension, or other abnormalities were seen on MRI. Consequently, a CT scan of the temporal bones was performed. This examination revealed a large dehiscence of the petrous segment of the ICA anteriorly to the cochlea, just at the level of the medial wall of the eustachian tube (ET) on the right side (**Figure 1**). Other possible causes of pulsatile tinnitus visible on CT, such as a dehiscence of the superior semicircular canal,<sup>3</sup> an ICA-cochlear dehiscence,<sup>4</sup> and a dehiscence of the ICA in the middle ear,<sup>2</sup> were excluded.

The patient was subsequently reassured regarding the benign character of this anatomical anomaly, but she was

<sup>1</sup>Department of Otorhinolaryngology, Head and Neck Surgery, AZ Delta, Roeselare, Belgium

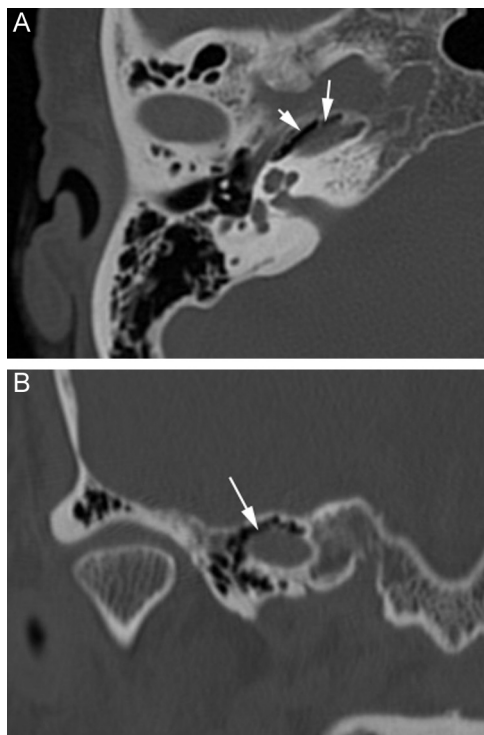
<sup>2</sup>Department of Radiology, AZ Delta, Roeselare, Belgium

<sup>3</sup>Department of Neurosciences, Faculty of Medicine, University of Antwerp, Belgium

## Corresponding Author:

Glen E. J. Forton, MD, PhD, Department of Otorhinolaryngology, Head and Neck Surgery, AZ Delta, Wilgenstraat 2, 8800 Roeselare, Belgium.  
 Email: glen.forton@azdelta.be





**Figure 1.** Dehiscence of the right internal carotid artery at the level of the eustachian tube on noncontrast computed tomography (CT) of the right temporal bone. (A) Axial CT images of the right temporal bone demonstrating dehiscence of the internal carotid artery (ICA) (arrows) at the level of the eustachian tube (ET). (B) Coronal CT images of the right temporal bone demonstrating dehiscence of the ICA (arrows) at the level of the ET.

also informed of the surgical inaccessibility of the established cause of her inconveniences.

## Discussion

This is, to our knowledge, the first case report in the literature that describes a dehiscence of the ICA at the level of the medial wall of the ET as the cause of pulsatile tinnitus. An earlier histologic temporal bone study showed that in normal temporal bones without cholesteatoma or chronic otitis media, most ICA dehiscences occur at the level of the middle ear (57.14%) and less often at the level of the ET (42.85%).<sup>5</sup> Other ICA dehiscences, such as an ICA-cochlear dehiscence<sup>4</sup> or a dehiscence of the ICA in the middle ear associated with pulsatile tinnitus,<sup>2</sup> have been reported and should be taken in account in the differential diagnosis.

Concerning the diagnostic workup of pulsatile tinnitus, every otologist should keep in mind the possibility of a

dehiscence of the ICA, which is difficult to visualize on MRI, usually performed as the first-step modality of imaging in patients with pulsatile tinnitus, and therefore should proceed to a CT scan of the temporal bone. The most important limitation of MRI in the diagnostics of pulsatile tinnitus is the fact that it does not show any bony dehiscences at the level of the middle or inner ear that can cause pulsatile tinnitus.

In the management of a symptomatic dehiscence of the ICA, a conservative attitude is generally adopted. Since the anatomical position of the dehiscence in our case was located at the level of the medial wall of the ET and thus was impossible to surgically approach without sacrificing hearing and/or ET function, the patient was informed of all these facts. She has been doing very well since and is coping with the pulsatile tinnitus in an exemplary fashion.

## Author Contributions

**Maaïke Rathé**, writing manuscript; **Fabienne Govaere**, reviewing and providing technical radiological information; **Glen E. J. Forton**, reviewing and correcting manuscript.

## Disclosures

**Competing interests:** None.

**Sponsorships:** None.

**Funding source:** None.

## References

- Moreano EH, Paparella MM, Zelterman D, Goycoolea MV. Prevalence of carotid canal dehiscence in the human middle ear: a report of 1000 temporal bones. *Laryngoscope*. 1994;104:612-618.
- Van Damme JP, Heylen G, Gilain C, Garin P. Pulsatile tinnitus associated with dehiscent internal carotid artery: an irremediable condition? *Auris Nasus Larynx*. 2017;44:612-615.
- Minor LB. Superior canal dehiscence syndrome. *Am J Otol*. 2000;21:9-19.
- Neyt P, Govaere F, Forton GE. Simultaneous true stapes fixation and bilateral bony dehiscence between the internal carotid artery and the apex of the cochlea: the ultimate pitfall. *Otol Neurotol*. 2011;32:909-913.
- Pauna HF, Monsanto RC, Schachern PA, et al. The surgical challenge of carotid artery and Fallopian canal dehiscence in chronic ear disease: a pitfall for endoscopic approach. *Clin Otolaryngol*. 2017;42:268-274.