

Received: 2018.03.29

Accepted: 2018.04.28

Published: 2018.08.28

# Catatonia After Liver Transplantation

Authors' Contribution:  
Study Design A  
Data Collection B  
Statistical Analysis C  
Data Interpretation D  
Manuscript Preparation E  
Literature Search F  
Funds Collection G

ABCDEF 1 **Jason R. Tatreau**  
ABCDEF 1 **Sarah L. Laughon**  
ABCDEF 2 **Tomasz Kozlowski**

1 Department of Psychiatry, University of North Carolina at Chapel Hill School of Medicine, Chapel Hill, NC, U.S.A.

2 Department of Surgery, Division of Abdominal Transplant, University of North Carolina at Chapel Hill School of Medicine, Chapel Hill, NC, U.S.A.

**Corresponding Author:** Tomasz Kozlowski, e-mail: tomasz\_kozlowski@med.unc.edu

**Source of support:** None

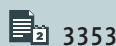
**Background:** Central nervous system complications after transplantation occur in up to 40% of recipients and these complications are associated with increased length of hospital stay and mortality. Catatonia is a neuropsychiatric clinical syndrome which has been described in case reports and in a small case series as occurring in the immediate post-solid organ transplantation (SOT) period, and it has been attributed to calcineurin inhibitor neurotoxicity, psychological vulnerability, and depression. Among transplant recipients, the incidence of catatonia is unknown; it may be under diagnosed in part due to a broad differential diagnosis in the post-transplantation setting, which includes hypoactive delirium, non-convulsive status epilepticus, drug toxicity, conversion disorder, and volitional uncooperativeness.

**Case Report:** We present 2 cases of catatonia diagnosed in liver allograft recipients. We also reviewed current literature for cases of catatonia among SOT recipients. We provide provisional evaluation and management strategies of recipients with clinical concern for catatonia.

**Conclusions:** Despite difficulties in establishing the diagnosis, catatonia after liver transplantation was rapidly responsive to intravenous lorazepam, indicating that changing immunosuppressants may be avoidable.

**MeSH Keywords:** **Catatonia • Delirium • GABA Agents • Liver Transplantation • Neurotoxicity Syndromes • Psychiatry**

**Full-text PDF:** <https://www.annalsoftransplantation.com/abstract/index/idArt/910298>



3353



1



—



28



## Background

Central nervous system complications after liver transplantation occur in up to 40% of recipients, and these complications are associated with increased length of hospital stay and mortality [1]. Catatonia is a neuropsychiatric syndrome with motor, speech, and behavioral abnormalities that has been described in several case reports of transplant recipients. However, among transplant recipients, the incidence of catatonia is unknown. Many potential transplant-related factors have been associated with catatonia syndromes in non-transplanted patients, including infection, posterior reversible encephalopathy syndrome [2,3], akinetic mutism [4], uremic encephalopathy [5], hyponatremia [6], and osmotic demyelination syndrome [7]. Immunosuppressants have specifically been implicated in catatonia among transplant recipients [8–10]. While the pathophysiology of catatonia remains unclear, proposed mechanisms involve neuronal decreases of GABA (gamma-aminobutyric acid) and dopamine and increases in glutamate [11].

Catatonia is challenging to diagnose due to varying severity, symptom fluctuation, and lack of objective diagnostic testing. Additional difficulty in diagnosis is related to its broad differential diagnosis in the post-transplantation setting, including hypoactive delirium, non-convulsive status epilepticus, drug toxicity, conversion disorder, and volitional uncooperativeness [9,10,12,13].

We present 2 cases of catatonia diagnosed in the early post-operative period among liver allograft recipients at our institution. That we identified 2 cases within a 6-month period prompted a literature review of all known cases of catatonia after solid organ transplantation (SOT), which has not been described before. In this paper, we also discuss provisional evaluation and management strategies of transplant recipients with clinical concern for catatonia. We believe this short series, literature review, and recommendations will increase awareness and management of catatonia among transplant recipients.

## Case Report

We present 2 case reports and a review of the literature for known cases of catatonia in transplant recipients. On March 7, 2017, we systematically reviewed PubMed, EMBASE, and PsylINFO by cross-referencing the search terms “catatoni\*” AND “transplant\*”. Abstracts from EMBASE (35), PubMed (18), and PsylINFO (12) were reviewed for cases of catatonia in the context of SOT. Individual articles were also reviewed for additional references. Symptoms of catatonia were variably described among the cases identified, and only 4 articles quantified the severity of catatonia with a rating scale: the Bush-Francis Catatonia Rating Scale (BFCRS) was used in

3 cases and the Northoff Catatonia scale was used in 1 case. We reviewed each article for mention of any of the symptoms described in the BFCRS screening questions 1–14 and noted them as present or absent.

### Case 1

A 52-year-old male with cirrhosis secondary to hepatitis C virus (HCV) infection and alcoholism (in remission greater than 1 year) with chronic ascites, hepatic encephalopathy, and a calculated MELD (Model for End-Stage Liver Disease) score of 16 received orthotopic ABO-compatible liver transplant (OLT) complicated by intra-operative large volume ascites loss and acute kidney injury on post-operative day (POD) 1, temporarily necessitating hemodialysis. The patient’s allograft function was good throughout the post-operative course. The immunosuppressive regimen consisted of tacrolimus (TAC), mycophenolate mofetil (MMF), and methylprednisolone. Psychiatric history consisted of bipolar disorder with multiple prior psychiatric hospitalizations in remission, with the patient on 20 mg nightly of olanzapine. Psychiatry was consulted on POD 1 for recommendations on restarting olanzapine. Psychiatry evaluation revealed no evidence of delirium, mania, psychosis, or other behavioral abnormalities, and given the absence of any recent mood symptoms and out of caution given his transplant, the recommendation was to restart olanzapine at a lower 5 mg dose with a plan to titrate to his prior home dose. He continued hemodialysis and physical therapy for the next 3 days without issue. On POD 4, he refused to get out of bed to work with Physical Therapy and didn’t answer questions asked by the surgical team, who became concerned that he was depressed. He was reassessed by Psychiatry on POD 6 and was noted to be alternating between staring blankly and looking around the room as though he was paranoid or confused, sometimes holding his head sideways for several seconds. He reported auditory hallucinations but would not discuss the nature of this. His speech alternated between periods of whispering, pausing for extended periods before answering, and not answering questions at all. His BFCRS score was 2. Neurological examination was remarkable for a mild bilateral upper extremity resting tremor. Electroencephalogram (EEG) was without epileptiform activity or diffuse background slowing. Blood work, including infectious workup, were all unremarkable. His TAC trough level was 1.4 ng/mL. Psychiatry was primarily concerned for psychosis or possible delirium and recommended increasing olanzapine to 10 mg nightly. The next day (POD 7), he had an episode of non-responsiveness and Neurology was consulted. His neurological examination was non-focal. The only signs of catatonia appreciated were mutism and head turning sideways at times, and the Neurology team was concerned for delirium and recommended a magnetic resonance imaging (MRI) to rule out intracranial pathology. Later that day (POD 7), he had another episode of unresponsiveness, including not moving

his extremities. Repeated blood work and a head computed tomography (CT) were normal. Neurology was concerned for non-convulsive seizures and he received 2 mg of intravenous (IV) lorazepam, shortly after which he began moving his extremities and became fully aroused. Hours later, he again became non-responsive, but also was hypotensive, hypoxic, and required transfer to the intensive care unit. Repeat EEG showed only diffuse background slowing. Serial neurological examinations revealed the onset of immobility, negativism, waxy flexibility, catalepsy, posturing, staring, and mutism; BFCRS score was 18. Psychiatry recommended, and Neurology agreed, with administration of another dose of IV lorazepam, though a lower dose of 0.5 mg given his prior poor tolerance of 2 mg. He did not respond to a 0.5 mg dose, but after another 0.5 mg dose, he began smiling, making eye contact, and answering questions within 30 minutes. Based on this clinical scenario and his response to lorazepam, catatonia was diagnosed. Lorazepam was scheduled at 1 mg IV twice daily. In an abundance of caution, TAC was changed to cyclosporine (CyA) on POD 8. Due to ongoing staring and immobility, lorazepam was titrated over 6 days to 4 mg IV every 4 hours. Sedation and low normal blood pressures precluded further dose increase, so memantine, an N-methyl-D-aspartate (NMDA) receptor antagonist, was added at 5 mg twice daily for catatonia. His catatonia gradually improved over several days. Lorazepam was converted to oral formulation. With lorazepam 4 mg 4 times daily and memantine 10 mg twice daily catatonia resolved by POD 22 (BFCRS score was 0). He was discharged home on this regimen, which was tapered over 3 months by his outpatient transplant psychiatrist. Catatonia symptoms did not return.

## Case 2

A 66-year-old female with cryptogenic cirrhosis and a calculated MELD score of 35 received an OLT without intra-operative complications. The immediate post-operative course was unremarkable, and her allograft functioning was good. The immunosuppressive regimen consisted of TAC, MMF, and methylprednisolone. She had no psychiatric history. On POD 3, she was seen for routine post-operative follow-up by the Transplant Psychologist, and was noted to be alert and fully oriented, but with new-onset communication difficulties including poor word-finding, speech latency, and dysarthria. She was fixated on her urine output to the exclusion of being able to hold a conversation. On POD 4, she began staring at the ceiling and reported visual hallucinations. Head CT and repeat blood work were non-contributory. Despite desired therapeutic levels, TAC was discontinued out of concern for neurotoxicity, and she was started on CyA. Her speech difficulties fluctuated over the next few days, and Neurology was consulted. Her brain MRI was without evidence of acute stroke and her 24-hour EEG was without epileptiform activity, diffuse background slowing, or other abnormalities, and routine non-pharmacologic delirium

precautions were recommended. On POD 10 she was noted by Physical Therapy to have “freezing episodes” where she would stop moving and appear “stuck”, would not talk, and had an episode of urinary incontinence while standing. She became paranoid that the “devil” was coming for her, refused her immunosuppressive medications, and exhibited verbigeration, repeating (over 40 times according to her nurse) “I don’t think I’m supposed to take this”. Psychiatry was consulted and noted that she was mute, continuously pointing towards the ceiling, staring upwards without blinking, and resisting attempts at moving her arms. She also demonstrated mitgehen, positive grasp reflex, and withdrawal. Her BFCRS was 21 and Psychiatry recommended a trial of lorazepam. Within 15 minutes of receiving 2 mg IV lorazepam she became interactive, conversed appropriately, and acted without abnormal behaviors. Catatonia was diagnosed, and she was started on scheduled IV lorazepam. After a second dose of lorazepam the next morning, she became sedated and was without any residual evidence of catatonia. In light of her improvement, lorazepam was stopped. She was without evidence of catatonia for 3 days when on POD 14 she became “frozen” again and refused her medications. At that time, her vitals were within normal limits. Labs including CBC, complete metabolic panel, and CyA levels were unremarkable. She was given a third dose of 2 mg IV lorazepam and again her catatonia symptoms completely resolved. To reduce the likelihood of catatonia symptoms returning while not over sedating her, she was started on standing lorazepam 1 mg by mouth 3 times daily on POD 16, which she tolerated well without sedation or return of catatonia. She was discharged on POD 17. Lorazepam was tapered over the next several weeks by Psychiatry, and her catatonia symptoms did not return.

## Discussion

Our literature search identified 11 additional cases of post-transplantation catatonia among liver (8), heart (1), kidney (1), and kidney/pancreas (1) recipients [9,10,13–20]. Including our 2 cases, a total of 13 cases of post-transplantation catatonia are now described in the literature. Mean age of all patients was 53 years, ranging from 21–66 years of age. Sixty-two percent of cases were male. Psychiatric histories were described for 12 recipients, of which 9 recipients had significant psychiatric histories (Table 1). Only 3 recipients were reported to be taking psychotropics at the time of transplantation, 2 for depression and 1 for bipolar disorder.

Overall, 10 out of 13 cases (77%) of post-SOT catatonia are among liver recipients; 9 received liver transplants and 1 received liver and kidney transplants. Liver recipients had a variety of primary hepatic diseases, including HCV cirrhosis (3 out of 10), alcoholic cirrhosis (2 out of 10), primary biliary cirrhosis

**Table 1.** Case reports of catatonia after solid organ transplantation.

	Age/ sex	Psychiatric history	Trans- plant	Onset (post- operative day)	Immuno- suppressants	Changes to immuno- suppressants	Initial treatment	Response	Agents used to lyse catatonia	Neuroleptic	Proposed etiology
UNC Case 1	52/M	Bipolar	Liver	4	Tac, MMF, Pred	Tac to CyA (after positive Ativan challenge)	Ativan 2 mg IV	60'	Ativan 4 mg IV every 4 h + Namenda 10 mg BID	Zyprexa (bipolar)	GABA deficiency
UNC Case 2	66/F	none	Liver	3	Tac, MMF, Pred	Tac to CyA (8 days before Ativan)	Ativan 2 mg IV	15'	Single dose, then Ativan 1 mg PO TID	None	GABA deficiency
Cotteincin et al. [15]	50/F	none	Liver	3	?	No	Ambien 10 mg PO	30'	Serax 40 mg daily	None	Psycho-logical vulnerability
Huang et al. [16]	50/M	?	Liver	3	?	?	Ativan 1 mg IV	60'	Ativan 1 mg IV	Seroquel	Psycho-logical vulnerability
Seetheram et al. [17]	49/M	AUD (remission)	Liver	3	CyA, MMF, Pred	Stopped CyA (before oxazepam)	Zyprexa	none	Serax + Ambien	None	GABA deficiency
O'Donnell et al. [9]	54/M	none	Liver	7	Tac, MMF, Pred	No	Ativan 1 mg IV	60'	Ativan 0.5 mg IV BID	Haldol	Tac neurotoxicity (akinetetic mutism)
Kalivas et al. [18]	52/M	AUD (remission)	Liver + kidney	2	?	?	Ativan 1 mg IV	24 h	Ativan 0.5 mg IV QID	Zyprexa	none
Corchs et al. [19]	55/M	?	Heart	11	?	?	Zoloft + Ritalin	4 d	Ritalin	None	Catatonic depression
Chopra et al. [10]	57/F	AUD (remission)	Kidney + pancreas	?	Tac, MMF, Pred	No	Ativan 1 mg PO	None	No meds	None	Tac neurotoxicity
Chopra et al. [10]	60/M	PTSD	Liver	8	Tac, MMF, Pred	Tac to CyA (after Ativan challenge)	Ativan 0.5 mg IV	None	No meds	None	Tac neurotoxicity
Chung et al. [14]	59/F	MDD	Liver	2	MMF, Pred	No	Ativan 1 mg IV	30'	Ativan 1 mg IV QID	None	Steroid – induced psychosis w/catatonic features
Kusztal et al. [20]	21/F	none	Kidney	9	Tac, MMF, Pred	Tac to CyA (before Valium)	Valium 2.5 mg IV	None	ECT	Zyprexa (psychosis)	Anti-LG1 Antibody encephalitis + Tac neurotoxicity
Brown et al. [13]	59/M	MDD	Liver	89	Tac, MMF, Pred	Tac to Sirolimus (Tac 30.4)	Remeron	None	Namenda 10 mg BID	None	Tac neurotoxicity (PRES)

UNC – University of North Carolina Hospitals; AUD – alcohol use disorder; Tac – tacrolimus; MMF – mycophenolate mofetil; CyA – cyclosporine A; Pred – prednisolone/prednisone; Neurotox – neurotoxicity; PRES – posterior reversible encephalopathy syndrome; GABA – gamma-aminobutyric acid.

(1 out of 10), non-alcoholic steatohepatitis (1 out of 10), and non-alcoholic fatty liver disease (1 out of 10). Underlying hepatic diseases were not reported in 2 cases. A minority of recipients (2 out of 10) developed transient complications in the early post-transplantation period, and there were no deaths.

The onset of catatonia was specified in 12 of the published cases. In 58% of cases (7 out of 12), catatonia was noted within 4

days of transplantation, and 6 of these 7 were among liver recipients. None of the non-liver recipients developed catatonia within the first week after transplantation (Table 1). The most common symptoms of catatonia among all cases were immobility (77%), staring (77%), withdrawal (77%), mutism (69%), negativism (61%), posturing (46%), echolalia (38%), and stereotypy (38%). The average number of catatonia symptoms was 6 (range 2–8). Concurrent psychiatric or neurologic symptoms

were observed in all 13 cases, most commonly paranoia (46%), agitation (23%), hallucinations (23%), myoclonus (23%), and tremor (23%). For all 13 cases, once symptoms were recognized, early psychiatric consultation was requested, resulting in a diagnosis of catatonia.

Of the 11 cases in which blood work was discussed, there were no blood work abnormalities described with any regularity. Hypomagnesemia was noted in only 4 cases (31%), and no patients had a magnesium level less than 1.5 mg/dL. Brain imaging was performed in 62% of cases, and none showed acute pathology. EEG was obtained in 54% of cases, and 5 EEGs showed diffuse slowing or generalized dysrhythmias. None showed epileptiform activity.

Immunosuppressive regimens were reported in 10 patients. Immunosuppressive regimens were adjusted following the onset of catatonic symptoms in 7 cases despite therapeutic trough levels in 6 patients, of which 3 were before benzodiazepines were given. For our 2 cases, this reflected a reactive response of the medical team before we were able to reach a comfort level in taking care of these patients with suspicion of catatonia. In Brown et al. [13], a supratherapeutic TAC level (30.4 ng/mL) and MRI consistent with atypical posterior reversible encephalopathy syndrome (PRES), not the management of catatonia, triggered modification of immunosuppressive regimen [13]. In UNC Case 2, TAC was changed to CyA 8 days prior to catatonia treatment.

Benzodiazepines were the most common initial treatment (9 cases), followed by zolpidem (1 case), sertraline plus methylphenidate (1 case), olanzapine (1 case), and mirtazapine (1 case). Seven cases showed significant reduction in catatonia symptoms within 60 minutes of the first treatment dose, and another 2 cases improved within 24 hours. In each of these 9 cases with rapid resolution of catatonia, benzodiazepines were used at the equivalent of at least 1 mg IV lorazepam. Dosing of lorazepam was increased in 2 cases due to incomplete resolution of catatonia: in 1 case to a total of 24 mg daily, and in another case from 0.5 mg every 6 hours, which gave a modest response after 24 hours, to 1 mg every 6 hours, which improved the response. Lorazepam dosing was decreased after the initial dose in 2 cases, both out of concern for over-sedation. Neuroleptics were used at some point in 38% of cases, and no cases of conversion to malignant catatonia or neuroleptic malignant syndrome occurred. Catatonia was successfully and completely treated in all 13 cases. Notably, psychopharmacologic agents started during catatonia were continued for at least 2 weeks in 77% of cases, including benzodiazepines (6 cases), antipsychotics (5 cases), memantine (1 case), methylphenidate (1 case), and mirtazapine (1 case).

Catatonia in the early post-transplantation setting generally presents as a clinical syndrome of behavioral, motor, and speech abnormalities. Behavioral disturbances can include not working with physical and occupational therapists (immobility), poor oral intake or refusing medications (withdrawal), not making eye contact, or staring. Motor abnormalities vary but may be most noticeable during assessment of range of motion of upper extremities, when resistance to movement (negativism or waxy flexibility), exaggerated movements, or posturing may be evident. Speech abnormalities may include delayed or slowed responses, copy-cattling (echolalia), repeating phrases (verbigeration), returning to the same topic (perseveration), or complete mutism. Without further investigation, these symptoms could potentially be attributed to hypoactive delirium, medication sedation, depression, volitional uncooperativeness, non-convulsive status epilepticus, or conversion disorder. While the majority had a positive psychiatric or substance abuse history, only a minority (3 out of 13 patients) were taking psychotropics for active psychiatric symptoms at the time of transplantation, and active psychiatric symptoms, such as anxiety, paranoia, and hallucinations, do not preclude a diagnosis of catatonia.

Similar to catatonia associated with other medical and psychiatric etiologies, post-transplantation catatonia is rapidly responsive to benzodiazepines, most commonly IV lorazepam. Effective dosing generally ameliorates catatonia symptoms within 60 minutes, though symptoms commonly reemerge, and repeated dosing is often necessary. Dosing intervals should be frequent enough to prevent symptom reemergence. Initial dosing of 1–2 mg given 3 to 4 times daily is reasonable. IV lorazepam was the initial treatment in 8 recipients and was successful in all 7 cases where the dose was at least equivalent to 1 mg lorazepam. Paradoxical agitation was reported in 1 case after a single 0.5 mg IV dose [17]. This could arguably represent a positive response that unmasked an underlying agitated delirium. Some patients may be susceptible to sedation, hypotension, or worsening underlying delirium, and augmentation with non-benzodiazepines should be considered. Initial treatment with zolpidem was used successfully in 1 case and then switched to oxazepam [15]; memantine was used in 2 cases successfully (in 1 case to avoid benzodiazepine in order to avoid exacerbation of an underlying delirium [13], and in our Case 2 to augment lorazepam when dose increases were precluded by sedation and hypotension. IV dosing may be converted to oral dosing after symptoms have been effectively treated for 1 to 2 days.

Neuroleptics used post-operatively for delirium and agitation are generally avoided in catatonia. While dopamine-blocking neuroleptics, generally high potency typical antipsychotics, have been linked to malignant catatonia or neuroleptic malignant syndrome [21,22], these cases showed that atypical

antipsychotics may be prudently considered for concurrent symptoms of delirium (paranoia, hallucinations, agitation).

That the majority of cases did not involve changing immunosuppressive regimens indicates that changing regimens is potentially avoidable in post-transplantation catatonia, and based on these cases, switching to a non-calcineurin inhibitor agent such as sirolimus may be avoidable. For the 6 patients in whom immunosuppressants were changed, 5 were continued on a calcineurin inhibitor (from TAC to cyclosporine) and 1 was switched to sirolimus, suggesting that if either TAC or cyclosporine does contribute to catatonia, the mechanism is not through a class effect. Importantly, immunosuppressant serum levels were only supratherapeutic in 1 case, in which atypical PRES was also diagnosed. Therefore, it cannot be said that a therapeutic immunosuppressant level precludes a diagnosis of catatonia.

Catatonia in the post-transplantation setting is surprisingly common among liver recipients and occurs early in the post-operative setting. While precise mechanisms for the development of catatonia are poorly understood, neuronal deficiencies in GABA are likely involved as evidenced by the efficacy of GABA agonists, such as benzodiazepines, in treating catatonia regardless of its etiology [12]. That the onset of catatonia is generally abrupt, within days after transplantation, supports the hypothesis that abrupt changes in neurotransmitter balance may occur in patients with newly transplanted livers and may be contributing to post-transplantation catatonia. Several lines of evidence implicate a relative deficiency in GABA-dependent signaling after liver transplantation specifically. Chronic liver failure is linked to neurochemical adaptations, including upregulation of GABA signaling [23–25]. Lack of effective hepatic metabolism of endogenous GABA-ergic neurotransmitters may lead to their accumulation and enhanced neuronal activity. Ammonia has been shown to modulate GABA receptors, further increasing GABA-ergic signaling in liver failure [26]. Reversal of this condition by liver allograft may lead to an acute state of relative GABA deficiency in the early post-operative period. TAC and CyA [27] are postulated to inhibit GABA activity as well as potentiate NMDA receptor activity, another mechanism implicated in the causality of catatonia [8,28]. Increasing GABA-ergic signaling with GABA agonists, such as benzodiazepines, may correct rapid changes in GABA signaling brought about by liver exchange, whereas memantine may treat catatonia through NMDA-receptor antagonism.

Given the variable presentation, symptom overlap, and effectiveness of early treatment, a low index of suspicion for catatonia in the early post-transplant liver recipient should be considered. Pre-transplantation ammonia levels have not been described among liver allograft recipients that develop catatonia, but it would be of clinical interest to determine whether pre-transplantation hyperammonemia is associated with catatonia after liver transplantation. Increased awareness and understanding of catatonia in the early post-transplantation period may shorten the length of hospital stay and decrease mortality. Early involvement of consult-liaison psychiatry can aid with diagnosis, treatment, and outpatient psychiatric care that may be indicated following hospital discharge.

## Conclusions

Catatonia in the early post-transplantation setting is a clinical syndrome of behavioral, motor, and speech abnormalities that with careful consideration could potentially be attributed to hypoaffective delirium, medication sedation, depression, volitional uncooperativeness, non-convulsive status epilepticus, or conversion disorder. Post-transplantation catatonia is rapidly responsive to IV lorazepam, and neuroleptics may be prudently considered for concurrent symptoms of delirium. Changing immunosuppressive regimens is potentially avoidable in a post-transplantation catatonia. Catatonia in the post-transplantation setting is surprisingly common among liver recipients and occurs early in the post-operative setting. We hypothesize that it may be related to an acute state of relative GABA deficiency in the early post-operative period induced by liver explantation rapidly correcting a state of elevated GABA-ergic neurotransmission in chronic liver failure. Increased awareness and understanding of catatonia in the early post-transplantation period may shorten the length of hospital stay and decrease mortality. Early involvement of consult-liaison Psychiatry can aid with diagnosis, treatment, and outpatient psychiatric care that may be indicated following hospital discharge.

## Acknowledgments

Authors thank Dr. Kenneth Andreoni, University of Florida for the critical review of the manuscript.

## Conflicts of interest.

None.

## References:

- Bernhardt M, Pfugrad H, Goldbecker A et al: Central nervous system complications after liver transplantation: Common but mostly transient phenomena. *Liver Transpl*, 2007; 13: 465–66
- Spiegel DR, Varnell C Jr.: A case of catatonia due to posterior reversible encephalopathy syndrome treated successfully with antihypertensives and adjunctive olanzapine. *Gen Hosp Psychiatry*, 2011; 33(3): 302.e3-5.
- Kitabayashi Y, Hamamoto Y, Hirosawa R et al: Postpartum catatonia associated with atypical posterior reversible encephalopathy syndrome. *J Neuropsychiatry Clin Neurosci*, 2007; 19(1): 91–92
- Najera JE, Alousi A, De Lima M, Ciurea SO: Akinetic mutism-a serious complication to tacrolimus-based GVHD prophylaxis. *Bone Marrow Transplant*, 2013; 48(1): 157–58
- Desai NG, Patil NM, Gangadhar BN et al: Catatonia associated with uraemic encephalopathy. *Indian J Psychiatry*, 1984; 26(1): 95–96
- Jaimes-Albornoz W, Serra-Mestres J: Prevalence and clinical correlations of catatonia in older adults referred to a liaison psychiatry service in a general hospital. *Gen Hosp Psychiatry*, 2013; 35(5): 512–16
- Koussa S, Nasnas R: Catatonia and parkinsonism due to extrapontine myelinolysis following rapid correction of hyponatremia: A case report. *J Neurol*, 2003; 250: 103–5
- Bernstein L, Levin R: Catatonia responsive to intravenous lorazepam in a patient with cyclosporine neurotoxicity and hypomagnesemia. *Psychosomatics*, 1994; 34(1): 102–3
- O'Donnell MM, Williams JP, Weinrieb R, Denysenko L: Catatonic mutism after liver transplant rapidly reversed with lorazepam. *Gen Hosp Psychiatry*, 2007; 29: 280–81
- Chopra A, Das P, Rai A et al: Catatonia as a manifestation of tacrolimus-induced neurotoxicity in organ transplant patients: A case series. *Gen Hosp Psychiatry*, 2012; 34: 209.e9-11
- Northoff G: What catatonia can tell us about “top-down modulation”: A neuropsychiatric hypothesis. *Behav Brain Sci*, 2002; 25: 555–604
- Denysenko L, Freudenreich O, Philbrick K et al: Clinical monograph: Catatonia in medically ill patients an evidence-based medicine (EBM). *Monograph for Psychosomatic Medicine Practice*, 2015
- Brown GD, Muzyk AJ, Preud'homme XA: Prolonged delirium with catatonia following orthotopic liver transplant responsive to memantine. *J Psychiatr Pract*, 2016; 22: 128–32
- Chung I, Weber GM, Cuffy MC et al: A 59-year-old woman who is awake yet unresponsive and stuporous after liver transplantation. *Chest*, 2013; 143: 1163–65
- Cottencin O, Debien C, Vaiva G et al: Catatonia and liver transplant. *Psychosomatics*, 2002; 43: 338–39
- Huang AS, Schwartz EH, Travis TS, Bourgeois JA: Catatonia after liver transplantation. *Psychosomatics*, 2006; 47: 451–52
- Seetheram P, Akerman RR: Postoperative echolalia and catatonia responsive to gamma aminobutyric acid receptor agonists in a liver transplant patient. *Anesth Analg*, 2006; 103: 785–86
- Kalivas KK, Bourgeois JA: Catatonia after liver and kidney transplantation. *Gen Hosp Psychiatry*, 2009; 31: 196–98
- Corchs F, Teng CT: Amphetamine, catatonic depression, and heart transplant: A case report. *Rev Bras Psiquiatr*, 2010; 32: 324–26
- Kusztal M, Piotrowski P, Mazanowska O et al: Catatonic episode after kidney transplantation. *Gen Hosp Psychiatry*, 2014; 36: 5–7
- Cremona-Barbaro A: Neuroleptic-induced catatonic symptoms. *Br J Psychiatry*, 1983; 142: 98–99
- Johnson GC, Manning DE: Neuroleptic-induced catatonia: Case report. *J Clin Psychiatry*, 1983; 44: 310–12
- Ahboucha S, Gamrani H, Baker G: GABAergic neurosteroids: The “endogenous benzodiazepines” of acute liver failure. *Neurochem Int*, 201; 60: 707–14
- Frederick RT: Extent of reversibility of hepatic encephalopathy following liver transplantation. *Clin Liver Dis*, 2012; 16: 147–58
- Jones EA, Schafer DF, Ferenci P, Pappas SC: The GABA hypothesis of the pathogenesis of hepatic encephalopathy: Current status. *Yale J Biol Med*, 1984; 57: 301–16
- Jones EA: Ammonia, the GABA neurotransmitter system, and hepatic encephalopathy. *Metab Brain Dis*, 2002; 17: 275–81
- Shuto H, Kataoka Y, Fujisaki K et al: Inhibition of GABA system involved in cyclosporine-induced convulsions. *Life Sci*, 1999; 65: 879–87
- Chen S-R, Hu Y-M, Chen H, Pan H-L: Calcineurin inhibitor induces pain hypersensitivity by potentiating pre- and postsynaptic NMDA receptor activity in spinal cords. *J Physiol*, 2014; 592: 215–27