

# Diagnostic accuracy of magnetic resonance angiography for Budd-Chiari syndrome: A meta-analysis

PENG XU<sup>1\*</sup>, LULU LYU<sup>2,3\*</sup>, MUHAMMAD UMAIR SAMI<sup>1</sup>, XIN LU<sup>1,3</sup>, HAITAO GE<sup>1</sup>,  
YUTAO RONG<sup>1</sup>, CHUNFENG HU<sup>1</sup> and KAI XU<sup>1,3</sup>

<sup>1</sup>Department of Radiology, Affiliated Hospital of Xuzhou Medical University, Xuzhou, Jiangsu 221002;

<sup>2</sup>Department of CT and MRI, Xuzhou Central Hospital, Xuzhou, Jiangsu 221009;

<sup>3</sup>The First School of Clinical Medicine, Nanjing Medical University, Nanjing, Jiangsu 211100, P.R. China

Received March 20, 2018; Accepted July 26, 2018

DOI: 10.3892/etm.2018.6764

**Abstract.** In recent years, the role of magnetic resonance angiography (MRA) in the diagnosis of Budd-Chiari Syndrome (BCS) has been the focus of various clinical studies. The purpose of the present study was to perform a meta-analysis of the diagnostic performance of MRA in patients with BCS by using digital subtraction angiography as a reference method. The search strategy for relevant research articles was based on the Cochrane Handbook for Systematic Reviews, and literature databases (including PubMed, Medline and China National Knowledge Infrastructure) and reference lists of retrieved studies published from 2000 to 2016 were searched. The Quality Assessment of Diagnostic Accuracy Studies tool was used to assess the methodological quality of these research studies by two reviewers independently. Summary estimates of the sensitivity, specificity, positive/negative likelihood ratio (LR+/-), diagnostic odds ratio (DOR) and the summary receiver operating characteristic (SROC) curve of MRA in identifying BCS were obtained. The pooled MRA estimates had a sensitivity of 97.6% [95% confidence interval (CI), 95.1-99.0%], a specificity of 70.7% (95% CI, 54.5-83.9%), an LR+ of 3.163 (95% CI, 2.03-4.94) and an LR- of 0.045 (95% CI, 0.02-0.09). The overall DOR was 94.053 (95% CI, 32.71-270.41). The area under the SROC curve was 0.972. In conclusion, MRA is an accurate modality for evaluating BCS.

## Introduction

Budd-Chiari syndrome (BCS) is characterized by the blockage of the hepatic veins (HVs) and/or the inferior vena cava (IVC) (1). Myeloproliferative disorders are the most common causes of BCS (1). Men and women are equally affected, with patients mostly being diagnosed in the third or fourth decade of life (2). Clinical manifestations include: Abdominal pain, liver dysfunction and intractable ascites, which is the most common clinical feature of BCS (3). Conventional management for BCS patients includes the treatment of complications of portal hypertension, surgery and endovascular intervention (4). The prevention of disease progression by medical treatment alone is limited. However, endovascular intervention has proven to be more effective than medical treatment and exhibits a lower mortality rate than open surgery (5).

Doppler ultrasonography is the technique of choice for initial investigation when BCS is suspected (1). Contrast-enhanced computed tomographic (CT) scanning may be recommended to delineate venous anatomy and to determine the configuration of the liver when a transjugular intrahepatic portosystemic shunt is being considered (1). Digital subtraction angiography (DSA) examination is considered as the 'golden standard' for the diagnosis of BCS. However, it is an invasive examination, which includes exposure to radiation and the injection of a contrast agent (6). Magnetic resonance (MR) angiography (MRA) has been suggested to be a suitable alternative modality for diagnosing BCS (7). However, to the best of our knowledge, no meta-analysis has been performed for previous studies on MRA to fully elucidate the qualities of this methodology for the diagnosis of BCS.

The aim of the present study was therefore to perform a systematic review to obtain the best available estimates of the diagnostic performance of MRA in patients with BCS.

## Materials and methods

**Publication search.** The PubMed (<https://www.ncbi.nlm.nih.gov/pubmed/>), MEDLINE (<https://www.nlm.nih.gov/bsd/pmresources.html>), SCOPUS (<https://www.scopus.com/home.uri>), EMBASE (<https://www.elsevier.com/solutions/embase-biomedical-research>), Cochrane Library

---

*Correspondence to:* Dr Kai Xu, Department of Radiology, Affiliated Hospital of Xuzhou Medical University, 99 Huaihai West Road, Xuzhou, Jiangsu 221002, P.R. China  
E-mail: xuk\_xuzhou@126.com

\*Contributed equally

**Key words:** magnetic resonance angiography, Budd-Chiari syndrome, meta-analysis, hepatic vein, diagnostic accuracy

(<https://www.cochranelibrary.com/>) and China National Knowledge Infrastructure databases (<http://oversea.cnki.net/>) were all searched for relevant studies published until November 2017. The following terms were used for the search: ('Budd-Chiari syndrome' OR 'hepatic venous thrombosis' OR 'hepatic outflow obstruction') and ('magnetic resonance angiography' OR 'MR angiography' OR 'MRA'). All of the studies identified were retrieved, and their references were also checked for other relevant publications.

**Inclusion and exclusion criteria.** Studies meeting the following selection criteria were included in the present meta-analysis: i) Evaluation of the diagnostic performance of MRA for detecting BCS, ii) true-positive (TP), false-positive (FP), true-negative (TN) and false-negative (FN) detection rate are contained in or may be calculated from the data of the original published study, iii) articles were published in English or Chinese and iv) DSA or surgery as the gold standard.

The exclusion criteria were as follows: i) Review articles, ii) animal studies, iii) studies with insufficient data, and iv) case reports and small case series (number of patients, <5). If the 2 reviewers disagreed on whether to include an article, it was resolved by consensus with a third reviewer.

**Data extraction and quality assessment.** Relevant studies were examined by two blinded observers independently (PX and LL) with the Quality Assessment of Diagnostic Studies (QUADAS) tool to assess the methodological quality of each study included in the meta-analysis (8). A third reviewer (XL) served as a blinded expert in cases of disagreement. The following data were extracted: i) Characteristics of study participants (number of patients, age, gender), ii) methodological details for MRA and iii) relevant data (TP, FP, TN and FN).

**Meta-analysis.** The use of the random-effects or fixed-effects model depends on the presence of statistical heterogeneity. Heterogeneity was assessed by the  $\chi^2$  test and the inconsistency index ( $I^2$ ) (9). One of the major causes of heterogeneity in test accuracy studies is the threshold effect (10). A threshold effect is indicated if assessment by computing the Spearman correlation between the logarithm (logit) of sensitivity and logit of (1-specificity) reveals a positive correlation between sensitivity and 1-specificity. A positive correlation ( $P < 0.05$ ) suggests a threshold effect. If heterogeneity is present due to a threshold effect, accurate data should be pooled by fitting a summary receiver operating characteristic curve and calculating the area under the curve (AUC). Subgroup analysis and regression meta-analysis were performed if there was no threshold effect but significant heterogeneity. All statistical analyses were performed using Meta-Disc software version 1.4 (11).

## Results

**Eligible studies.** The initial search for studies that evaluated the diagnostic accuracy of MRA for BCS yielded a total of 118 manuscripts. Manual searching of the reference lists of relevant research studies did not yield any additional relevant studies. In total, only 6 of these research studies contained the appropriate data [sample size, sensitivity, specificity, positive

predictive value and negative predictive value] for inclusion in the statistical calculations (12-17). The major reasons for exclusion were as follows: i) No relevance regarding the use of MRA for detecting or evaluating stenosis; ii) insufficient data for creating a 2x2 table; iii) QUADAS score of <9. The characteristics of each study included are presented in Table I. The 6 research studies that were finally included in the meta-analysis had been published between 2007 and 2015, and comprised a total of 285 patients. The mean number of patients per study was 47.5 (range, 35-108).

**Threshold effect analysis.** The Spearman correlation coefficient was determined to be 0.600 ( $P = 0.208$ ), which suggested no threshold effect among the individual studies that may have caused any variations in accuracy estimates.

**Data synthesis.** The overall AUC was 0.972, which suggested good diagnostic accuracy (Fig. 1). Pooled summary statistics for sensitivity (Fig. 2), specificity (Fig. 3), positive likelihood ratio, negative likelihood ratio, diagnostic odds ratios (DOR),  $P$ -value for heterogeneity and  $I^2$ -value are summarized in Table II. No significant heterogeneity was identified within these studies. None of the 95% confidence intervals of the ORs included 1, which confirms a significant diagnostic value of all modalities.

**Summary of scan modalities and misdiagnosis analysis.** Scan modalities (equipment, protocol, reconstruction mode, contrast agent) and reasons for misdiagnosis were summarized in Tables III and IV, respectively. In general, 54% of patients used 1.5 T MRI equipment and 46% used 3.0 T. The maximum intensity projection was the most common way to reconstruct images. Patients with a heart rate of >100 bpm, uneven breathing, massive ascites and membrane obstruction were more likely to be misdiagnosed.

## Discussion

Budd-Chiari syndrome is an uncommon condition induced by thrombotic or non-thrombotic obstruction of HV outflow (18). DSA is considered as the 'gold standard' for this disease, but it is an invasive examination involving exposure to radiation and injection of contrast agent. Various of other imaging modalities are available for diagnosing BCS in the clinic, including ultrasound (US), computed tomography (CT) and MR imaging.

US should be performed as the first imaging method of choice in patients with suspected BCS due to its high diagnostic sensitivity (75-90%) and non-invasive nature (19), but this approach is operator-dependent and maybe affected by excessive ascites and intestinal gas (20). CT has also been widely used for the diagnosis of BCS in the clinical setting as a non-invasive diagnostic tool (21,22). Certain studies have used CT to evaluate liver parenchyma, the status of the HVs and IVC, as well as extrahepatic and intrahepatic collaterals (23,24). With the development of CT technology, the effectiveness of BCS diagnosis has markedly improved (25). Although CT is a good modality for evaluating BCS, it has various disadvantages, including possible allergic reactions and nephrotoxicity due to the use of contrast agent (26).

Table I. Baseline characteristics of included studies on Budd-Chiari syndrome.

Author, year	Patients (n)	Male (%)	Age (years)	Reference standard	TP	FP	FN	TN	(Refs.)
Lu <i>et al.</i> , 2011	44	26	46 (19-78)	DSA	37 (84.1)	3 (6.8)	0 (0)	4 (9.1)	(12)
Pu <i>et al.</i> , 2015	51	28	NA (19-61)	DSA	41 (80.4)	4 (7.8)	1 (2.0)	5 (9.8)	(13)
Qin <i>et al.</i> , 2015	45	33	46.5 (27-71)	DSA/surgery	40 (88.9)	0 (0)	1 (2.2)	4 (8.9)	(14)
Ren <i>et al.</i> , 2007	50	38	48.6 (NA)	DSA	38 (76.0)	1 (2.0)	3 (6.0)	8 (16.0)	(15)
Shen <i>et al.</i> , 2013	108	57	46.5 (18-73)	DSA	97 (89.8)	3 (2.8)	2 (1.9)	6 (5.5)	(16)
Wu <i>et al.</i> , 2014	35	23	43.9 (24-69)	DSA	32 (91.4)	1 (2.9)	0 (0)	2 (5.7)	(17)

Age is expressed as the mean (range); data as n (%). NA, not available; DSA, digital subtraction angiography; TP, true positives; FP, false positives; FN, false negatives; TN, true negatives.

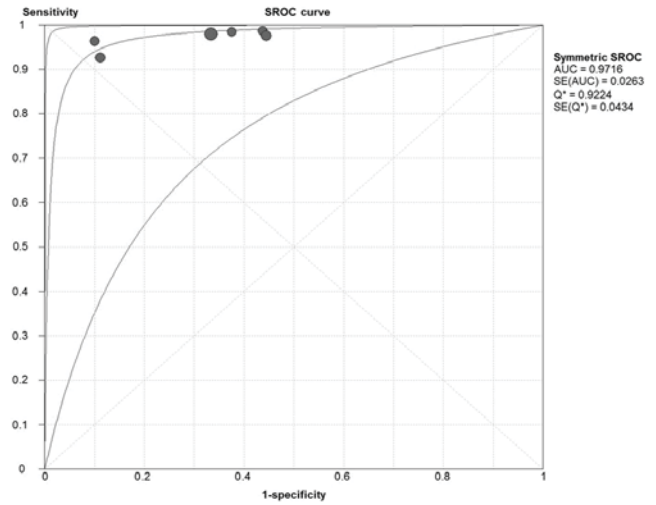


Figure 1. SROC curve for meta-analysis of studies assessing magnetic resonance angiography for diagnosing Budd-Chiari syndrome. Each circle represents an individual research study. The size of the circle is proportional to the sample size of the study. The best-fitting curve lies between the other 2 curves demarcating its 95% confidence interval. SROC, summary receiver operating characteristic; AUC, area under the curve; SE, standard error.

MRA has been increasingly used as an alternative technology for assessing BCS. However, the quality of this methodology has not been assessed in previous studies. In the present study, a systematic review was performed to obtain the best available estimate of the diagnostic performance of MRA in patients with BCS. The meta-analysis revealed that, compared with the reference standard DSA, MRA is an accurate diagnostic tool for diagnosing BCS with a pooled sensitivity of 97.6%, a specificity of 70.7% and a DOR of 94.1%. MRA is a useful method for the diagnosis of BCS regardless of the use of contrast agent. Therefore, MRA protocols without the use of contrast agent, e.g. fresh blood imaging or in-flow inversion recovery, may become increasingly important, particularly for patients who cannot receive any contrast agent for various reasons. Time-spatial labeling inversion pulse is another non-contrast-enhanced MRA technology with a high success rate, high accuracy rate and fine image quality for the diagnosis of BCS (27). This technique based on true steady-state free-precession is a type of spin labeling that yields the quantitative plus selective inflow of information and suppressing the background (28-30).

In the present study, it was revealed that certain factors may lead to misdiagnosis by MRA, including a heart rate of >100 bpm, uneven breathing and massive ascites. All of these factors may increase the misdiagnosis rate. At present, maximum intensity projection is the most commonly used image reconstruction method, which may facilitate an accurate diagnosis. Furthermore, multiplanar reconstruction and volume rendering may be added as a supplement. MRA may not only be used to diagnose BCS effectively, but also provide more useful information on the classification of BCS patients, the shape of the IVC obstruction, as well as the position and direction of accessory HVs (AHVs), and this information has a high degree of consistency with DSA. In 2016, Xu *et al.* (31) reported that liver accelerated volume acquisition (LAVA) sequence had a high sensitivity and specificity in detecting

Table II. Weighted summary for each modality.

Value	Sensitivity	Specificity	LR+	LR-	DOR
Pooled	0.976	0.707	3.163	0.045	94.053
95% CI	0.95-0.99	0.55-0.84	2.03-4.94	0.02-0.09	32.71-270.41
Chi-squared	6.18	6.09	3.52	1.83	0.57
P-value	0.289	0.297	0.621	0.873	0.989
I <sup>2</sup> value (%)	19.1	17.9	0.0	0.0	0.0

NA, not available; DSA, digital subtraction angiography; TP, true positive; FP, false positive; FN, false negative; TN, true negative; CI, confidence interval; LR+/-, positive/negative likelihood ratio; DOR, diagnostic odds ratio.

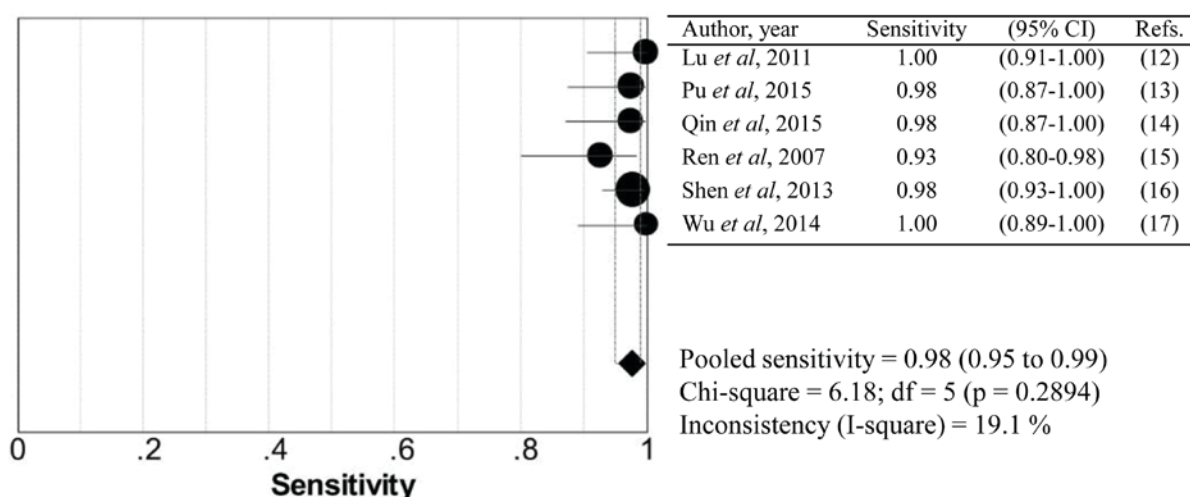


Figure 2. Forest plot of sensitivity. The sensitivity for each research study is represented by circles. The 95% CI is represented by the horizontal lines through each circle. The pooled sensitivity is represented by the diamond symbol. CI, confidence interval; df, degrees of freedom.

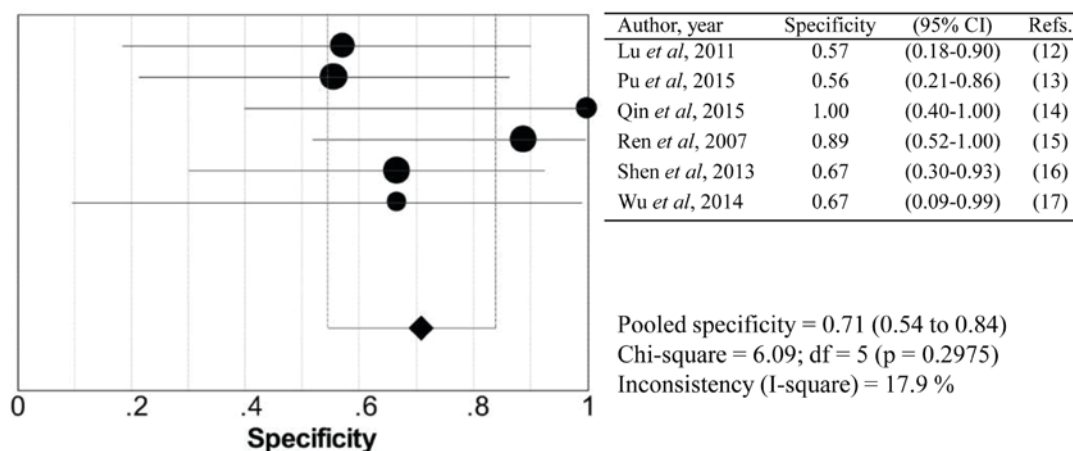


Figure 3. Forest plot of specificity. The specificity for each research study is represented by circles. The 95% CI is represented by the horizontal lines through each circle. The pooled specificity is represented by the diamond symbol. CI, confidence interval; df, degrees of freedom.

AHV in BCS patients as indicated by a retrospective analysis. Lu *et al* (32) suggested that LAVA sequence is able to detect more AHVs than DSA. In addition, MRA clearly reveals the opening direction of AHV and the angle between AHV and distal vena cava, which have practical value for interventional therapy (33).

The present study has several limitations. One limitation is that the number of studies included was low and the sample size was small. The second limitation is that there were differences in the equipment and protocols among the studies, among which two studies used 3.0T magnetic resonance imaging equipment and four studies used 1.5T equipment. In

Table III. Summary of scan modalities for each study.

Author, year	Equipment	Protocol	Reconstruction mode	Contrast medium	(Refs.)
Lu <i>et al</i> , 2011	3.0T GE Signa EXCITE	FIESTA & LAVA	MIP	Yes	(12)
Pu <i>et al</i> , 2015	1.5T GE Signa HDxt	FIESTA & LAVA	MIP & MPR & VR	Yes	(13)
Qin <i>et al</i> , 2015	1.5T GE Signa HDxt	IFIR	MIP	No	(14)
Ren <i>et al</i> , 2007	1.5T Toshiba Visart	FBI	MIP	No	(15)
Shen <i>et al</i> , 2013	3.0T GE Signa EXCITE	LAVA	NA	Yes	(16)
Wu <i>et al</i> , 2014	1.5T GE Signa HDxt	IFIR & FIESTA	MIP & MPR & VR	No	(17)

FBI, fresh blood imaging; FIESTA, fast imaging employing steady-state acquisition; LAVA, liver accelerated volume acquisition; IFIR, in-flow inversion recovery; MIP, maximum intensity projection; MPR, multiplanar reconstruction; VR, volume rendering; NA, not available.

Table IV. Analysis of misdiagnoses in the studies included.

Author, year	n (%)	Presentation	Misdiagnosis	(Refs.)
Lu <i>et al</i> , 2011	2 (4.5)	Segmental stenosis of IVC	Segmental obstruction	(12)
	1 (2.3)	Membranous obstruction with hole and thrombus	Complete obstruction	(12)
Pu <i>et al</i> , 2015	5 (9.8)	IVC compressed by massive ascites	IVC stenosis	(13)
Qin <i>et al</i> , 2015	1 (2.2)	NA	NA	(14)
Ren <i>et al</i> , 2007	3 (6.0)	Heart rate >100 bpm and breathing uneven (disappearance of the signal from the proximal part of the IVC)	IVC obstruction	(15)
	3 (6.0)	Only one or two hepatic vein stenoses (partial and gentle narrow)	No stenosis of the hepatic vein	(15)
Shen <i>et al</i> , 2013	5 (4.6)	NA	NA	(16)
Wu <i>et al</i> , 2014	1 (2.9)	Membrane obstruction	Membrane stenosis	(17)

NA, not available; IVC, inferior vena cava.

addition, BCS may be categorized into three types depending on the type of venous occlusion (2). The present study did not analyze each type separately due to the small number of cases. The third limitation is that only studies that were written in English and Chinese were included for reasons of practicality. Publication bias was not assessed due to the inclusion of a limited number of studies (<10).

In conclusion, the high diagnostic accuracy of MRA determined in the present meta-analysis suggests that this modality has potential for improving the diagnosis and evaluation Budd-Chiari syndrome. These results provide a larger-scale reference for clinicians and it is recommended that MRA is implemented in the clinic for diagnosing Budd-Chiari syndrome.

#### Acknowledgements

The authors would like to thank Mr Muhammad Bilal (Department of Neurology, Affiliated Hospital of Xuzhou Medical University, Xuzhou, China) for language editing of the manuscript.

#### Funding

This study was supported by grants from the Clinical Medical Science and Technology Project of Jiangsu Province (grant no. BE2017637) and the Medical Innovation Team (leading talent) of Jiangsu Province (grant no. CXTDA2017028).

#### Availability of data and materials

The datasets used and analyzed in the present study are available from the corresponding author on reasonable request.

#### Authors' contributions

PX and LL analyzed the patient data, and were the major contributors in the preparation of the manuscript, HG and YR analyzed part of the patient data, MUS and XL collected the original data, and CH and KX made substantial contributions to the conception of the study and drafted the manuscript. All authors read and approved the final manuscript.

### Ethical approval and consent to participate

Not applicable.

### Patient consent for publication

Not applicable.

### Competing interests

The authors declare that they have no competing interests.

### References

- Menon KN, Shah V and Kamath PS: The Budd-Chiari syndrome. *N Engl J Med* 350: 578-585, 2004.
- Lupescu IG, Dobromir C, Popa GA, Gheorghe L and Georgescu SA: Spiral computed tomography and magnetic resonance angiography evaluation in Budd-Chiari syndrome. *J Gastrointest Liver Dis* 17: 223-226, 2008.
- Orloff MJ, Daily PO, Orloff SL, Girard B and Orloff MS: A 27-year experience with surgical treatment of Budd-Chiari syndrome. *Ann Surg* 232: 340-352, 2000.
- Huang Q, Shen B, Zhang Q, Xu H, Zu M, Gu Y, Wei N, Cui Y and Huang R: Comparison of long-term outcomes of endovascular management for membranous and segmental inferior vena cava obstruction in patients with primary Budd-Chiari syndrome. *Circ Cardiovasc Interv* 9: e003104, 2016.
- Meng QY, Sun NF, Wang JX, Wang RH and Liu ZX: Endovascular treatment of Budd-Chiari syndrome. *Chin Med J (Engl)* 124: 3289-3292, 2011.
- Kubo T, Shibata T, Itoh K, Maetani Y, Isoda H, Hiraoka M, Egawa H, Tanaka K and Togashi K: Outcome of percutaneous transhepatic venoplasty for hepatic venous outflow obstruction after living donor liver transplantation. *Radiology* 239: 285-290, 2006.
- Wang L, Lu J, Wang F, Liu Q and Wang J: Diagnosis of Budd-Chiari syndrome: Three-dimensional dynamic contrast enhanced magnetic resonance angiography. *Abdom Imaging* 36: 399-406, 2011.
- Whiting P, Rutjes AW, Reitsma JB, Bossuyt PM and Kleijnen J: The development of QUADAS: A tool for the quality assessment of studies of diagnostic accuracy included in systematic reviews. *BMC Med Res Methodol* 3: 25, 2003.
- Satoh S, Kitazume Y, Ohdama S, Kimura Y, Taura S and Endo Y: Can malignant and benign pulmonary nodules be differentiated with diffusion-weighted MRI? *AJR Am J Roentgenol* 191: 464-470, 2008.
- Li B, Li Q, Chen C, Guan Y and Liu S: Diagnostic accuracy of computer tomography angiography and magnetic resonance angiography in the stenosis detection of autologous hemodialysis access: A meta-analysis. *PLoS One* 8: e78409, 2013.
- Zamora J, Abaira V, Muriel A, Khan K and Coomarasamy A: Meta-DiSc: A software for meta-analysis of test accuracy data. *BMC Med Res Methodol* 6: 31, 2006.
- Lu X, Xu K, Zhang QQ, Yang C, Li SD, Li JS, Rong YT and Zu MH: Study on between magnetic resonance venography and digital subtraction angiography on the inferior vena cava obstructive interface morphology of Budd-Chiari syndrome. *Zhonghua Gan Zang Bing Za Zhi* 19: 923-926, 2011 (In Chinese).
- Pu HB, You J, Chen HP, Zhang FZ and Xie Y: The value of FIESTA sequence in the diagnosis of inferior vena cava lesions with Budd-Chiari syndrome. *Chin J Magn Reson Imaging* 6: 422-466, 2015 (In Chinese).
- Qin D, Shi D, Dou S, Lian JM and Yan FS: Value of in-flow inversion recovery sequence in diagnosis of Budd-Chiari syndrome. *J Pract Radiol* 1: 136-139, 2015 (In Chinese).
- Ren K, Xu K, Sun WG, Chen YS, Qi XX, Li RL and Jin AY: Preliminary evaluation of magnetic resonance fresh blood imaging for diagnosis of Budd-Chiari syndrome. *Chin Med J (Engl)* 120: 95-99, 2007.
- Shen PP and Wang XT: The comparison of the imaging diagnostic value in Budd-Chiari syndrome. *Acta Acad Med Xuzhou* 33: 111-113, 2013 (In Chinese).
- Wu M, Xu J, Shi D, Shen H, Wang M, Li Y, Han X and Zhai S: Evaluations of non-contrast enhanced MR venography with inflow inversion recovery sequence in diagnosing Budd-Chiari syndrome. *Clin Imaging* 38: 627-632, 2014.
- Ferral H, Behrens G and Lopera J: Budd-Chiari syndrome. *AJR Am J Roentgenol* 199: 737-745, 2012.
- Chawla Y, Kumar S, Dhiman RK, Suri S and Dilawari JB: Duplex Doppler sonography in patients with Budd-Chiari syndrome. *J Gastroenterol Hepatol* 14: 904-907, 1999.
- Erden A: Budd-Chiari syndrome: A review of imaging findings. *Eur J Radiol* 61: 44-56, 2007.
- Camera L, Mainenti PP, Di Giacomo A, Romano M, Rispo A, Alfinito F, Imbriaco M, Soscia E and Salvatore M: Triphasic helical CT in Budd-Chiari syndrome: Patterns of enhancement in acute, subacute and chronic disease. *Clin Radiol* 61: 331-337, 2006.
- Virmani V, Khandelwal N, Kang M, Gulati M and Chawla Y: MDCT venography in the evaluation of inferior vena cava in Budd-Chiari syndrome. *Indian J Gastroenterol* 28: 17-23, 2009.
- Cho OK, Koo JH, Kim YS, Rhim HC, Koh BH and Seo HS: Collateral pathways in Budd-Chiari syndrome: CT and venographic correlation. *AJR Am J Roentgenol* 167: 1163-1167, 1996.
- Cai SF, Gai YH and Liu QW: Computed tomography angiography manifestations of collateral circulations in Budd-Chiari syndrome. *Exp Ther Med* 9: 399-404, 2015.
- Zhang LM, Zhang GY, Liu YL, Wu J, Cheng J and Wang Y: Ultrasonography and computed tomography diagnostic evaluation of Budd-Chiari syndrome based on radical resection exploration results. *Ultrasound Q* 31: 124-129, 2015.
- Liu SY, Xiao P, Cao HC, Jiang HS and Li TX: Accuracy of computed tomographic angiography in the diagnosis of patients with inferior vena cava partial obstruction in Budd-Chiari syndrome. *J Gastroenterol Hepatol* 31: 1933-1939, 2016.
- Yang C, Li C, Zeng M, Lu X, Li JJ, Wang JL, Sami MU and Xu K: Non-contrast-enhanced MR angiography in the diagnosis of Budd-Chiari syndrome (BCS) compared with digital subtraction angiography (DSA): Preliminary results. *Magn Reson Imaging* 36: 7-11, 2017.
- Shimada K, Isoda H, Okada T, Kamae T, Arizono S, Hirokawa Y, Shibata T and Togashi K: Non-contrast-enhanced hepatic MR angiography: Do two-dimensional parallel imaging and short tau inversion recovery methods shorten acquisition time without image quality deterioration? *Eur J Radiol* 77: 137-142, 2011.
- Shimada T, Amanuma M, Takahashi A and Tsushima Y: Non-contrast renal MR angiography: Value of subtraction of tagging and non-tagging technique. *Ann Vasc Dis* 5: 161-165, 2012.
- Shimada K, Isoda H, Okada T, Maetani Y, Arizono S, Hirokawa Y, Kamae T and Togashi K: Non-contrast-enhanced hepatic MR angiography with true steady-state free-precession and time spatial labeling inversion pulse: Optimization of the technique and preliminary results. *Eur J Radiol* 70: 111-117, 2009.
- Xu HT, Xu K, He P, Zhang QQ, Dai Y, Lu L, Li C and Sun JM: Value of three-dimensional liver acceleration volume acquisition multiphase dynamic contrast-enhanced magnetic resonance imaging in detection of accessory hepatic veins in Budd-Chiari syndrome. *Zhonghua Gan Zang Bing Za Zhi* 24: 585-589, 2016 (In Chinese).
- Lu L, Xu K, Han C, Xu C, Xu H, Dai Y, Rong Y, Li S and Xie L: Comparison of 3.0T MRI with 3D LAVA sequence and digital subtraction angiography for the assessment of accessory hepatic veins in Budd-Chiari syndrome. *J Magn Reson Imaging* 45: 401-409, 2017.
- Xu H, Xu K, He P, Zhang QQ, Dai Y, Lu L, Li C and Sun JM: CE-MRA in detecting the opening direction and measuring the angle of accessory hepatic vein with the inferior vena cava in Budd-Chiari syndrome. *Chin J Hepatobiliary Surg* 21: 596-599, 2015 (In Chinese).