

Open surgical treatment of choledochocoele: A case report and review of literature

Jie Yang, Guang-Fa Xiao, Yi-Xiong Li

Jie Yang, Guang-Fa Xiao, Yi-Xiong Li, Department of Biliopancreatic Surgery, Xiangya Hospital, Central South University, Changsha 410008, Hunan Province, China

ORCID number: Jie Yang (0000-0001-9352-162X); Guang-Fa Xiao (0000-0001-7105-8283); Yi-Xiong Li (0000-0002-8215-426X).

Author contributions: Li YX designed the report; Yang J and Xiao GF collected the patient's clinical data and wrote the paper.

Informed consent statement: Consent was obtained from the patient's relatives for publication of this report and any accompanying images.

Conflict-of-interest statement: The authors declare that they have no conflicts of interest.

CARE Checklist (2016) statement: The authors have read the CARE Checklist (2016), and the manuscript was prepared and revised according to the CARE Checklist (2016).

Open-Access: This article is an open-access article which was selected by an in-house editor and fully peer-reviewed by external reviewers. It is distributed in accordance with the Creative Commons Attribution Non Commercial (CC BY-NC 4.0) license, which permits others to distribute, remix, adapt, build upon this work non-commercially, and license their derivative works on different terms, provided the original work is properly cited and the use is non-commercial. See: <http://creativecommons.org/licenses/by-nc/4.0/>

Manuscript source: Unsolicited manuscript

Corresponding author to: Yi-Xiong Li, MD, Chief Doctor, Department of Biliopancreatic Surgery, Xiangya Hospital, Central South University, 87 Xiangya Road, Changsha 410008, Hunan Province, China. lyx2011@csu.edu.cn
Telephone: +86-731-89753009
Fax: +86-731-84327332

Received: September 10, 2018
Peer-review started: September 10, 2018
First decision: October 11, 2018
Revised: October 16, 2018

Accepted: October 23, 2018

Article in press: October 23, 2018

Published online: November 26, 2018

Abstract

Choledochocoele (also known as type III choledochal cyst according to Todani's classification) is a cystic dilation of the distal segment of the common bile duct protruding into the duodenal lumen. Cases are rare and the etiology remains unclear. It is usually misdiagnosed as peptic ulcer, as in the patient whose case is described here. Multislice spiral computed tomography and magnetic resonance cholangiopancreatography may be comparable to endoscopic retrograde cholangiography for diagnosis of choledochocoele. Both endoscopic therapy and open surgical management are safe options, and size of the cyst plays a role in the decision-making for which approach to apply. A 50-year-old woman admitted to our hospital with upper abdominal pain caused by choledochocoele with large size was successfully treated by open surgical management. We present the details of her case in this case report and discuss the recent literature on such cases and their therapeutic management.

Key words: Choledochal cyst; Endoscopic retrograde cholangiopancreatography; Choledochocoele; Operative surgical procedure; Case report

© **The Author(s) 2018.** Published by Baishideng Publishing Group Inc. All rights reserved.

Core tip: Choledochocoele, also known as the type III choledochal cyst according to Todani's classification, is a rare disease. We present the case of an adult female with a large-size choledochocoele that was successfully treated by open surgery. We also provide a detailed discussion of the recent literature on such cases and their therapeutic management.

Yang J, Xiao GF, Li YX. Open surgical treatment of choledochoceles: A case report and review of literature. *World J Clin Cases* 2018; 6(14): 842-846 Available from: URL: <http://www.wjgnet.com/2307-8960/full/v6/i14/842.htm> DOI: <http://dx.doi.org/10.12998/wjcc.v6.i14.842>

INTRODUCTION

Choledochocoele (also known as type III choledochal cyst according to Todani's classification^[1]), is a cystic dilation of the distal segment of the common bile duct protruding into the duodenal lumen. Considered rare, these cases comprise less than 2% of all reported cases of choledochal cyst^[2]. The rarity of the disease serves to obscure its diagnosis and treatment.

The case described herein, accompanied by a review of the current literature, will help to increase our knowledge about this rare disease.

CASE REPORT

A 50-year-old woman was admitted to our department with an > 10-year history of repeated upper abdominal pain, but without vomiting, jaundice, chills and fever. During that period, she had been admitted to the gastroenterology outpatient clinic several times, where she was diagnosed with and treated for chronic nonatrophic gastritis; yet, her symptom was never alleviated.

Physical examination produced no positive findings, except a mild tenderness on the upper abdomen. Routine blood panel, liver function markers, blood amylase and tumor marker test results were normal. Abdominal ultrasound showed gallstones and nondilated intrahepatic and extrahepatic bile ducts. As such, the cause of the patient's presenting symptom remained undetermined.

Multislice spiral computed tomography showed a 3.0 cm-long, 1.5 cm-wide cystic lesion at the junction of the descending and horizontal portion of the duodenum (Figure 1). Duodenoscopy was performed and showed a huge submucosal mass connected to the major duodenal papilla; the distal segment of the common bile duct was not evident in endoscopic retrograde cholangiopancreatography (ERCP) (Figure 2). We considered these findings to indicate a choledochocoele, and we decided to treat with open surgical management.

The cystic lesion became grossly visible when the descending part of the duodenum was incised longitudinally, and complete cystectomy was performed (Figure 3). Then, the orifices of the common bile duct and pancreatic duct were found and each marked with 6-Fr silicon tube. Sphincteroplasty was performed under the guidance of the silicon tube. Cholecystectomy was also carried out to address the gallstones. An abdominal cavity drainage tube and a duodenostomy tube were placed. A T-tube was also placed, to facilitate external

drainage of bile. Lastly, a nasojejunal nutrition tube was placed perioperatively, and enteral nutrition support was started on the 3rd day after surgery. The operation time was 4 h and intraoperative blood loss was 120 mL. Postoperative pathological examination of the resected tissue showed duodenal mucosa with regional low-grade intraepithelial neoplasia inside the choledochocoele.

At 1 wk postoperation, the nasojejunal nutrition tube was removed and the duodenostomy tube was occluded; at this time, oral feeding was initiated and tolerated without event. The postoperative period remained uneventful, and the patient was discharged at 10 d after the operation. At 45 d postoperation, the T-tube and duodenostomy tube were removed. At the 1-year follow-up, the patient had survived and was asymptomatic.

DISCUSSION

The first case of choledochocoele was reported by Wheeler^[3] in 1915. The report described the anomaly as a small, tense cyst occupying a position in or about the orifice of the common bile duct^[3]. Since then, with the development of medical techniques like endoscopy and imaging, the number of publications on choledochocoele has steadily increased.

In 1993, Masetti *et al*^[4] reviewed 116 cases of choledochocoele reported in the literature to date. In 2015, Lobeck *et al*^[5] reviewed 71 individual case reports as well as 42 institutional reviews, totaling 254 cases of choledochocoele; unfortunately, the authors did not affirm whether or not there were duplications between the included cases. A single case series of choledochocoele including 28 patients was reported by Ziegler *et al*^[6] in 2009, representing the largest institution-based collection of case data. In this article, we summarized 22 case report studies of adult choledochocoele patients receiving treatment between 1995 and 2015 in PubMed database (Table 1).

In Japan, choledochocoele has been regarded as the type III choledochal cyst (according to Todani's classification^[1]) and reportedly accounts for the lowest proportion of choledochal cyst case series^[2]. However, both Ziegler *et al*^[6] and Dong *et al*^[7] considered that the choledochal cysts should not include the choledochocoele because patients with choledochocoele differ from those with choledochal cyst in age, sex, presentation, pancreatic ductal anatomy, and their management. Choledochocoeles were classified as type A and type B based on the anatomic appearance by Sarris and Tsang, and the type A Choledochocoeles were further divided into 3 subtypes (intraluminal with common opening for the common bile duct and pancreatic duct, intraluminal with separate openings for the common bile duct and pancreatic duct and completely intramural)^[8]. Other classifications had also been proposed like Kagiya^[9] and Horaguchi^[10], however none has been widely accepted.

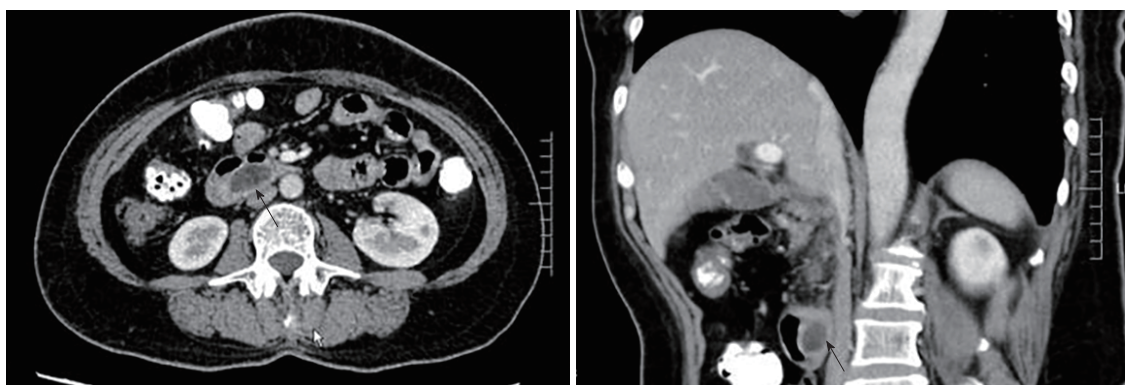


Figure 1 Multislice spiral computed tomography indicating a cystic lesion at the duodenum. Black arrows indicate the cystic lesion.

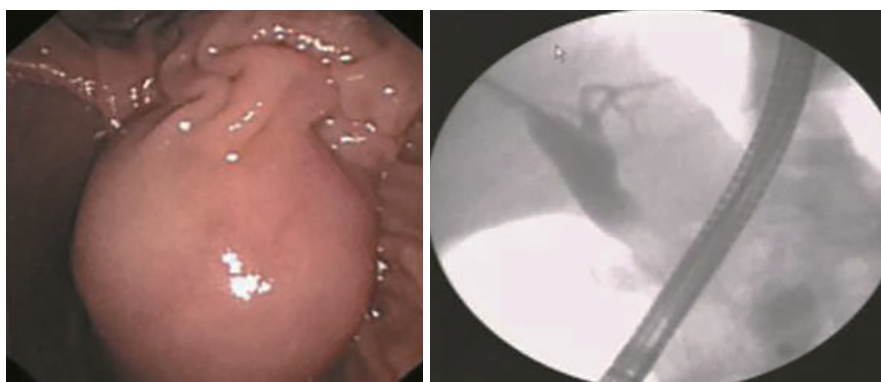


Figure 2 Duodenoscopy showing a huge submucosal mass connected to the major duodenal papilla. The distal segment of the common bile duct was not evident.

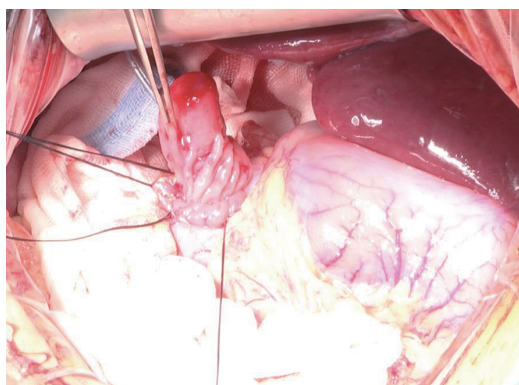


Figure 3 The cyst lesion was found to be attached to the duodenal papilla during the surgery.

The etiology of the choledochocele remains unclear. Tanaka^[11] suggested that the mechanism for formation was failed regression of a bile duct during embryogenesis. However, Sterling^[12] considered that some choledochocele appear to be acquired and proposed that papillary stenosis or sphincter of Oddi dysfunction may cause obstruction to bile flow, resulting in increased pressure within the distal bile duct, which could then evaginate into the duodenum. Sarris and Tsang^[8], in the review of 24 patients, reported that the epithelium inside the choledochocele was duodenal

mucosa in 63% of the cases and biliary tract epithelium or unclassifiable glandular epithelium in 37% of the cases.

In histopathology, the presence of intestinal mucosa creates controversy as to whether choledochocele is a type of duodenal duplication cyst or a unique entity. Congenital intraluminal duodenal diverticulum has been suggested in relation to the pathogenesis of choledochocele in young children, because most cases describe duodenal mucosa. However, unlike congenital forms, in older patients a papillary stenosis may cause dilatation of the ampulla by way of an inflammatory process induced by stasis of bile and pancreatic juice. Thus, biliary tract epithelium and undifferentiated epithelium are predominant later on^[13].

Abdominal pain is the most common symptom of choledochocele, others include nausea, vomiting and jaundice. Image examination plays an important role in the diagnosis. Noninvasive B-ultrasound examination can detect cystic mass in the duodenal cavity; however, the image could be disturbed by intestinal gas. Usually, there are no specific findings, as in our case. Endoscopic ultrasound could show the wall layers of the cyst as well as the connection with the pancreaticobiliary tree, it also might guide both classification of the lesion and treatment decisions^[14]. Some think the confirmation of a choledochocele appears to be best made by ERCP.

Table 1 Case report studies of adult choledochocoele patients receiving treatment, 1995-2015

Author	Clinical presentation	Treatment	Malignancy	Symptom relief
Eisenman 1995	Abdominal pain	ET	Not noted	Yes
Tajiri 1996	Abdominal pain	OST	No	Yes
Tanno 1996	Jaundice, fever	ET	Not noted	Yes
Krepel 1997	Anaemia, Abdominal pain	OST	No	Yes
Iwata 1998	Abdominal pain, fever	OST	No	Not noted
Chatila 1999	Abdominal pain	ET	No	Yes
Adamek 2000	Nausea, abdominal pain	ET	Not noted	Yes
Groebli 2000	Abdominal pain	OST	Not noted	Not noted
Can 2006	Abdominal pain	OST	Not noted	Yes
Moparty 2006	Abdominal pain	OST	Not noted	Not noted
Berger 2007	Abdominal pain, nausea	ET	No	Yes
Hackert 2007	Abdominal pain	OST	No	Not noted
Izumiyama 2007	Abdominal pain	ET	Not noted	Yes
Kawakami 2007	None	ET	No	-
Lakhtakia 2007	Abdominal pain, vomit	ET	No	Yes
Kaye 2008	Abdominal pain	OST	Not noted	Yes
Park 2009	Abdominal pain	ET	No	Yes
Amezaga 2010	Jaundice, anorexia	ET	Not noted	Yes
Cakmakci 2012	Abdominal pain	OST	Not noted	Yes
Darji 2012	Abdominal pain, vomit	ET	Not noted	Not noted
Zhu 2014	Abdominal pain, vomit	ET	Not noted	Yes
Villa 2015	Abdominal pain	ET	Not noted	Yes

OST: Open surgical treatment; ET: Endoscopic treatment.

In the literature, ERCP has been performed in 67% of the reported cases, and this method holds the benefit of simultaneous treatment implementation. Multislice spiral computed tomography and magnetic resonance cholangiopancreatography are considered to have comparable specificity and sensitivity, and may replace ERCP for diagnosis^[15,16]. In our patient, both endoscopic and radiologic techniques were used to obtain an optimal image.

Open surgical management, like transduodenal complete cyst excision with sphincteroplasty, was performed by Wheeler on the original choledochocoele case (a 65-year-old male patient) with success, and is still frequently performed. In 1974, endoscopic sphincterotomy treatment was implemented for the first time by Mane *et al*^[17], on a 21-year-old female patient. Since then, endoscopy has been recognized as a feasible alternative treatment with satisfactory results. Both therapies have been applied successfully in pediatric patients^[18,19].

The choice of treatment method is still uncertain, however, and size of the cyst plays a role in the clinical decision-making process. Three centimeters in diameter may be the cut-off value, above which transduodenal cyst resection should be performed^[5]. However, the fundamental purpose of choledochocoele treatment should be to maintain normal outflow of bile and pancreatic juice, with the additional objective of minimizing risk of malignancy. The large diameter of the cyst lesion in our patient led us to decide to perform open surgery. Almost all of the patients have relieved after treatment either by endoscopy or surgery. Malignant transformation of a choledochocoele has been rarely reported^[20], and wasn't happened in

the case reports we reviewed in the table. However, choledochocoele might be accompanied or caused by pancreaticobiliary maljunction, in such a condition, biliary tract malignancy was more frequent according to Horaguchi's report^[10]. Nonetheless, sustaining follow-up could be beneficial for patients who are asymptomatic or accidentally discovered.

In conclusion, choledochocoele is a rare disease and the choice of treatment method is still controversial. For choledochocoele with large-size (*i.e.*, > 3 cm in diameter), we suggest treatment with open surgical management, according to our case's successful outcome.

ARTICLE HIGHLIGHTS

Case characteristics

A 50-year-old woman with upper abdominal pain lasting for more than 10 year.

Clinical diagnosis

Choledochocoele.

Laboratory diagnosis

No positive laboratory test results were found.

Imaging diagnosis

A 3.0 cm-long, 1.5 cm-wide cystic lesion at the junction of the descending and horizontal portion of the duodenum.

Pathological diagnosis

Duodenal mucosa with regional low-grade intraepithelial neoplasia inside the choledochocoele.

Treatment

Open surgical management involving cyst excision with sphincteroplasty.

Related reports

Choledochocele is considered a rare disease, and cases are seldom reported.

Term explanation

Choledochocele, also known as the type III choledochal cyst according to Todani's classification, is a cystic dilation of the distal segment of the common bile duct protruding into the duodenal lumen, and accounts for < 2% of all reported cases of choledochal cyst.

Experiences and lessons

Choledochocele is a rare disease and usually misdiagnosed as peptic ulcer. For the choledochocele with large size (*i.e.*, > 3 cm in diameter), we suggest treatment with open surgical management, according to our case's successful outcome.

REFERENCES

- 1 **Todani T**, Watanabe Y, Narusue M, Tabuchi K, Okajima K. Congenital bile duct cysts: Classification, operative procedures, and review of thirty-seven cases including cancer arising from choledochal cyst. *Am J Surg* 1977; **134**: 263-269 [PMID: 889044 DOI: 10.1016/0002-9610(77)90359-2]
- 2 **Yamaguchi M**. Congenital choledochal cyst. Analysis of 1,433 patients in the Japanese literature. *Am J Surg* 1980; **140**: 653-657 [PMID: 6776832 DOI: 10.1016/0002-9610(80)90051-3]
- 3 **Wheeler W**. An unusual case of obstruction to the common bile duct (choledochocele?). *Brit J Surg* 1940; **27**: 446-448 [DOI: 10.1002/bjs.18002710705]
- 4 **Masetti R**, Antinori A, Coppola R, Coco C, Mattana C, Crucitti A, La Greca A, Fadda G, Magistrelli P, Picciocchi A. Choledochocele: changing trends in diagnosis and management. *Surg Today* 1996; **26**: 281-285 [PMID: 8727951 DOI: 10.1007/BF00311589]
- 5 **Lobeck IN**, Dupree P, Falcone RA Jr, Lin TK, Trout AT, Nathan JD, Tiao GM. The presentation and management of choledochocele (type III choledochal cyst): A 40-year systematic review of the literature. *J Pediatr Surg* 2017; **52**: 644-649 [PMID: 27829523 DOI: 10.1016/j.jpedsurg.2016.10.008]
- 6 **Ziegler KM**, Pitt HA, Zyromski NJ, Chauhan A, Sherman S, Moffatt D, Lehman GA, Lillemoe KD, Rescorla FJ, West KW, Grosfeld JL. Choledochoceles: are they choledochal cysts? *Ann Surg* 2010; **252**: 683-690 [PMID: 20881775 DOI: 10.1097/SLA.0b013e3181f6931f]
- 7 **Dong JH**, Zheng XH, Xia HT, Zhao XQ, Liang B, Yang T, Zeng JP, Huang ZQ. Cystic dilation of bile duct: new clinical classification and treatment strategy. *Zhonghua Xiaohuawaike* Zazhi 2013; **12**: 370-377 [DOI: 10.3760/cma.j.issn.1673-9752.2013.05.012]
- 8 **Sarris GE**, Tsang D. Choledochocele: case report, literature review, and a proposed classification. *Surgery* 1989; **105**: 408-414 [PMID: 2646745]
- 9 **Kagiyama S**, Okazaki K, Yamamoto Y, Yamamoto Y. Anatomic variants of choledochocele and manometric measurements of pressure in the cele and the orifice zone. *Am J Gastroenterol* 1987; **82**: 641-649 [PMID: 3605025]
- 10 **Horaguchi J**, Fujita N, Kobayashi G, Noda Y, Ito K, Takasawa O. Clinical study of choledochocele: is it a risk factor for biliary malignancies? *J Gastroenterol* 2005; **40**: 396-401 [PMID: 15868371 DOI: 10.1007/s00535-005-1554-7]
- 11 **Tanaka T**. Pathogenesis of choledochocele. *Am J Gastroenterol* 1993; **88**: 1140 [PMID: 8317430]
- 12 **Sterling JA**. Diverticula in the terminal portion of the common bile duct. *Am J Pathol* 1949; **25**: 325-337 [PMID: 18113087]
- 13 **Schimpl G**, Sauer H, Goriupp U, Becker H. Choledochocele: importance of histological evaluation. *J Pediatr Surg* 1993; **28**: 1562-1565 [PMID: 8301491 DOI: 10.1016/0022-3468(93)90097-5]
- 14 **Law R**, Topazian M. Diagnosis and treatment of choledochoceles. *Clin Gastroenterol Hepatol* 2014; **12**: 196-203 [PMID: 23660418 DOI: 10.1016/j.cgh.2013.04.037]
- 15 **Groebli Y**, Meyer JL, Tschantz P. Choledochocele demonstrated by computed tomographic cholangiography: report of a case. *Surg Today* 2000; **30**: 272-276 [PMID: 10752782 DOI: 10.1007/s005950050058]
- 16 **Park DH**, Kim MH, Lee SK, Lee SS, Choi JS, Lee YS, Seo DW, Won HJ, Kim MY. Can MRCP replace the diagnostic role of ERCP for patients with choledochal cysts? *Gastrointest Endosc* 2005; **62**: 360-366 [PMID: 16111952 DOI: 10.1016/j.gie.2005.04.026]
- 17 **Deyhle P**, Schnaars P, Meyer HJ, Nüesch HJ, Akovbiantz A. Electrosurgical removal of a choledochocele through an endoscope introduced by mouth (author's transl). *Dtsch Med Wochenschr* 1974; **99**: 71-72 [PMID: 4812785 DOI: 10.1055/s-0028-1107714]
- 18 **Mane S**, Arlikar J, Dhende N. Choledochocele: An unusual presentation in a premature neonate. *J Indian Assoc Pediatr Surg* 2012; **17**: 28-30 [PMID: 22279362 DOI: 10.4103/0971-9261.91084]
- 19 **Saeki I**, Takahashi Y, Matsuura T, Takahata S, Tanaka M, Taguchi T. Successful endoscopic unroofing for a pediatric choledochocele. *J Pediatr Surg* 2009; **44**: 1643-1645 [PMID: 19635320 DOI: 10.1016/j.jpedsurg.2009.03.042]
- 20 **Ladas SD**, Katsogridakis I, Tassios P, Tastemiroglou T, Vrachliotis T, Raptis SA. Choledochocele, an overlooked diagnosis: report of 15 cases and review of 56 published reports from 1984 to 1992. *Endoscopy* 1995; **27**: 233-239 [PMID: 7664701 DOI: 10.1055/s-2007-1005677]

P- Reviewer: Hashimoto R, Sandhu DS, Tsolakis AV
S- Editor: Dou Y **L- Editor:** A **E- Editor:** Song H





Published by **Baishideng Publishing Group Inc**
7901 Stoneridge Drive, Suite 501, Pleasanton, CA 94588, USA
Telephone: +1-925-223-8242
Fax: +1-925-223-8243
E-mail: bpgoffice@wjgnet.com
Help Desk: <http://www.f6publishing.com/helpdesk>
<http://www.wjgnet.com>

