

Confirming the pathogenicity of *NECAPI* in early onset epileptic encephalopathy

*†‡Saud Alsahli , *†‡Waleed Al-Twajiri, and †‡§Fuad Al Mutairi

Epilepsia Open, 3(4):524–527, 2018
doi: 10.1002/epi4.12263



Dr. Saud Alsahli, MD is a PGY-1 Child Neurology resident and a junior researcher.

SUMMARY

Early onset epileptic encephalopathy (EOEE) has been used to encompass Ohtahara syndrome (early infantile epileptic encephalopathy [EIEE]), early myoclonic epilepsy, and many others. Multiple genes have been established to cause epileptic encephalopathy in the immature brain, and next-generation sequencing has accelerated the process of novel gene discovery. Many of the previously published candidate genes are still pending confirmatory reports or functional studies. Although most of the genes involved are ion channels (channelopathies), multiple other pathways have been implicated as well. *NECAPI* is a key element in clathrin-mediated endocytosis and has been reported previously to cause EOEE in a Saudi family. We report another family with the same variant confirming the pathogenicity of this variant as a Saudi founder mutation, further delineate its phenotype, and propose that it causes EOEE instead of EIEE.

KEY WORDS: Encephalopathy, Early onset encephalopathy, Early onset epileptic encephalopathy, Epilepsy, *NECAPI*, Early infantile epileptic encephalopathy, Clathrin-mediated endocytosis.

SHORT COMMUNICATION

Epileptic encephalopathy has been defined by the International League Against Epilepsy (ILAE) as when the epileptic activity itself may lead to severe cognitive and behavioral impairments above and beyond what might be expected from the underlying pathology alone.¹ Early onset epileptic encephalopathies (EOEEs), on the other hand, are severe disorders that affect the development of the young

brain with onset in early infancy. Myriad of novel genes were discovered in recent years after the introduction of next-generation sequencing.² Yet, many of these proposed candidate genes are awaiting confirmation.^{3,4} Identification of the pathways involved in epileptic encephalopathy is important to guide novel drug discovery and epilepsy management in the future. Alazami et al.⁵ has previously reported that the *NECAPI* gene variant in a multiplex Saudi family resulted in early infantile epileptic encephalopathy (EIEE). This gene has been proposed because it is highly expressed in the brain and plays a crucial role in clathrin-mediated endocytosis (CME). CME is a major cellular mechanism in eukaryotic cells for the internalization of nutrients, receptors, and other substances that are important for homeostasis.⁶ Multiple proteins work in synchrony to deform the bilayer plasma membrane and lead to vesicle formation. It was previously shown that *NECAPI* through its WxxF motif at its C-terminus interacts with adaptor protein 2 (AP-2) and works as a negative regulator of AP-2 to control the vesicle number, size, and content.^{7,8} As far as we know, neither confirmatory functional studies nor a second family has been reported. We identified a second Saudi simplex family that is not related to the previous family, albeit with the same variant. The index is a 41-month-old girl who

Accepted August 18, 2018.

*Division of Pediatric Neurology, Department of Pediatrics, King Abdulaziz Medical City, Ministry of National Guard-Health Affairs (MNGHA), Riyadh, Saudi Arabia; †King Abdullah International Medical Research Center (KAIMRC), Riyadh, Saudi Arabia; ‡College of Medicine, King Saud bin Abdulaziz University for Health Sciences, Riyadh, Saudi Arabia; and §Division of Genetics, Department of Pediatrics, King Abdulaziz Medical City, Ministry of National Guard-Health Affairs (MNGHA), Riyadh, Saudi Arabia

Address correspondence to Fuad Al Mutairi, King Abdullah International Medical Research Center (KAIMRC), Mail Code 1940, P. O. Box 22490, Riyadh, 11426, Saudi Arabia. E-mail: almutairifu@ngha.med.sa

© 2018 The Authors. *Epilepsia Open* published by Wiley Periodicals Inc. on behalf of International League Against Epilepsy.

This is an open access article under the terms of the Creative Commons Attribution-NonCommercial-NoDerivs License, which permits use and distribution in any medium, provided the original work is properly cited, the use is non-commercial and no modifications or adaptations are made.

was born at full term via normal spontaneous vaginal delivery to a healthy 29-year-old G3P2 mother following an uneventful pregnancy. The parents are a first-degree consanguineous couple with 2 other healthy daughters, and there is no family history of a similar condition. However, there is a history of an abortion at 5 weeks of gestation and a stillbirth at 37 weeks in 2 succeeding pregnancies. The perinatal course was unremarkable apart from mild desaturation that resolved spontaneously, and she was discharged on the second day after delivery. Nevertheless, the mother noticed that since birth the child had a weak cry, and was not following, fixating, or able to support her neck. She was also noted to have increased respiratory secretions, asthma, congenital exotropia, and a premature closure of the anterior fontanelle. At the age of 3 months, she started to have uprolling of the eyes without any other abnormal movements, which was brought to medical attention only a few months later when her generalized tonic seizures commenced. She was started on phenytoin, and her seizures decreased in frequency. She was then referred to our institution at the age of 8 months when she had her first electroencephalography (EEG) study. The first reading of her EEG was reported as normal. She was then weaned from phenytoin and started on levetiracetam, and she became seizure free for 3 months. At the age of 12 months, she started to have flexor hemispasms in her right side with a frequency of 4–5 per day, so EEG was repeated and showed generalized slow waves at a frequency of 2–3 delta activity without evidence of hypsarrhythmia or epileptiform discharges. She was then started on vigabatrin while levetiracetam was decreased gradually, but her seizures worsened, and she had generalized tonic-clonic seizures. Vigabatrin was subsequently stopped, and she was started on clobazam. Her generalized seizures ceased, but she continued to have hemispasms. Her parents refused adrenocorticotropic hormone (ACTH) treatment,

and she was started on topiramate and the frequency of her spasms decreased. She has been on physiotherapy since the age of 8 months that helped decrease her contractures. At the age of 3 years, she was found to have gastroesophageal reflux, and she underwent laparoscopic fundoplication. She continued to have breakthrough generalized tonic-clonic seizures and occasional hemispasms. In terms of her development, she is nonverbal and has a profound global developmental delay. At the age of 41 months, she could not follow, fixate, support her neck, rollover, say baba and mama, or recognize her parents. Her growth parameters at 41 months of age were weight 9.9 kg (−3.22 standard deviation [SD]), height 90 cm (−1.72 SD), and head circumference 43 cm (−3.78 SD). Physical examination revealed axial hypotonia, appendicular hypertonia, hyperreflexia, scaphocephaly, and exotropia. She had unpurposeful movements of all limbs, and she was not following or fixating. She did not have any stigmata of a neurocutaneous syndrome. The examination of other systems was within normal limits. Brain magnetic resonance imaging (MRI) at 15 months of age showed delayed myelination for the patient's age, benign enlargement of the subarachnoid spaces, moderate supratentorial ventriculomegaly, and thinning of the corpus callosum (Fig. 1). A renal ultrasound at 3 years of age showed bilateral echogenic kidney with bilateral grade 1 hydronephrosis that is more prominent on the right side. An ascending urethrogram showed left grade III vesicoureteral reflex. Routine laboratory workup as well as plasma amino acids, urine organic acids, serum ammonia, newborn screening, blood creatine kinase, serum homocysteine, serum carbohydrate deficient transferrin, urine creatinine, blood lactic acid, serum very long chain fatty acids, urine mucopolysaccharides, urine oligosaccharides, serum biotinidase, karyotyping, microarray comparative genomic hybridization, visual evoked potential, electroretinogram,

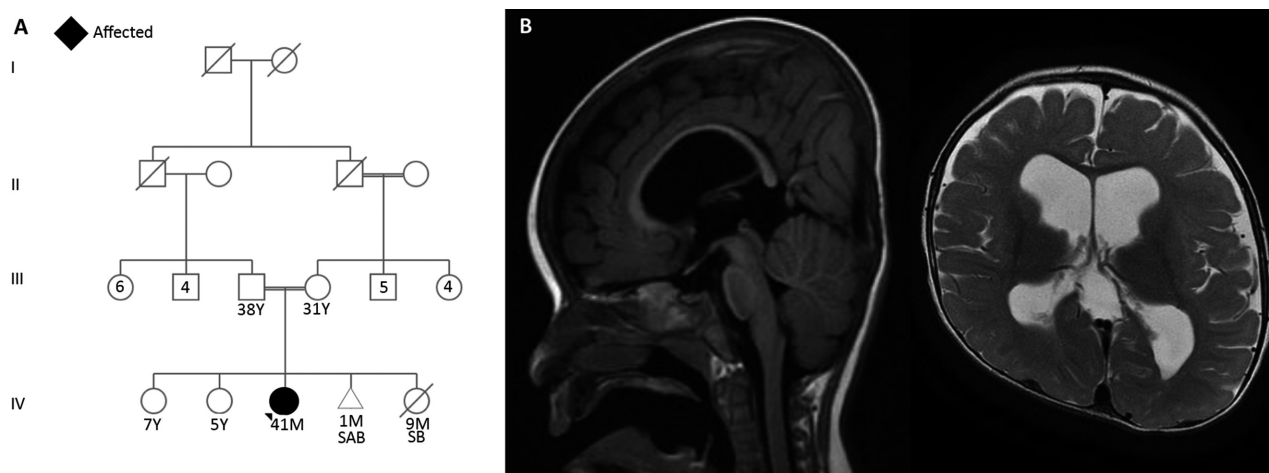


Figure 1. (A) Family pedigree of the current cohort. (B) Sagittal and axial brain MRI showing delayed myelination for the patient's age, benign enlargement of the subarachnoid spaces, moderate supratentorial ventriculomegaly, and thinning of the corpus callosum.

Epilepsia Open © ILAE

and brainstem auditory potentials were all within normal limits.

After obtaining signed consent from the parents, trio whole-exome sequencing (WES) was carried out. We did not find any suspicious variant in known epilepsy genes or intellectual disability (ID); however, it revealed a

homozygous nonsense truncating pathogenic variant in the *NECAP1* gene [NM_015509.3: c.142C>T (p.Arg48Ter)] in the index, with both parents being heterozygous carriers. This variant was absent in our 1200 ethnically matched exome database (Majeen), publicly available genomic catalogs, Centogene database, and Saudi Human Genome

Table 1. Comparison between *NECAP1* patients and *DNM1* patients

	Current report and Alazami et al.	PMID: 29427836; 29588952; 23934111; 26648591; 25262651; 25533962; 27806796; 27476654; 26611353; 28667181
Gene	<i>NECAP1</i>	<i>DNM1</i>
Inheritance	AR	AD
Number of patients	7	29
Seizure type at onset	Generalized tonic and clonic, generalized tonic, hemispasms	Infantile spasms, absence seizures, myoclonic, generalized tonic and clonic, head dropping
Age of onset	3 months, NA	0–13 months, 4.5 years
Antiepileptic drug response	+	+
EEG	Generalized slowing and frequent generalized epileptiform discharges	Slow background, multifocal discharges, hypsarrhythmia, modified hypsarrhythmia
GDD	100%	100%
Hypotonia	+	+
MRI	<ul style="list-style-type: none"> • Thinning of the corpus callosum • Delayed myelination for the patient's age • Moderate supratentorial ventriculomegaly • Generalized brain atrophy 	<ul style="list-style-type: none"> • Normal • Generalized cerebral atrophy • Delayed myelination for the patient's age • Frontal lobe hypoplasia • Mega cisterna magna • Posterior skull flattening

AR, autosomal recessive; AD, autosomal dominant; EEG, electroencephalography; GDD, global developmental delay; MRI, magnetic resonance imaging; NA, not available.

Table 2. Comparison between reported cases and the current cohort

Case	Current study	Published PMID: 24399846
Variant	c.142C>T	c.142C>T
Number of affected	1	6
Gender	F	F and M
Consanguinity	+	+
Growth parameters at birth	Normal	Normal
GDD	+	+
Seizure age of onset	3 months	NA
Seizures' semiology	Generalized tonic Hemispasms	Generalized tonic and clonic
Pharmacoresistant seizures	+	+
Height	−1.72 SD	NA
Weight	−3.22 SD	NA
Head Circumference	−3.78 SD	NA
Axial hypotonia	+	+
Appendicular Hypertonia	+	+
Brain MRI	<ul style="list-style-type: none"> • Delayed myelination for the patient's age • Benign enlargement of the subarachnoid spaces • Moderate supratentorial ventriculomegaly • Thinning of the corpus callosum • Thinning of the corpus callosum • Generalized slowing 	<ul style="list-style-type: none"> • Non-specific generalized brain atrophy
EEG	<ul style="list-style-type: none"> • Generalized slowing 	<ul style="list-style-type: none"> • Generalized slowing • Frequent generalized epileptiform discharges

EEG, electroencephalography; F, female; GDD, global developmental delay; M, male; MRI, magnetic resonance imaging; NA, not available.

Program database (2,000 exomes). Further segregation analysis of other siblings supported the pathogenicity of this variant. Although the seizure semiology reported by Alazami et al. was different from that of the current report, there is a significant phenotypic overlap.

Of interest, *DNM1*, which is another gene involved in the CME pathway, has been reported to cause epileptic encephalopathy by multiple cohort studies.^{4,9–18} *DNM1* gene encodes for dynamin-1 protein, which is essential for the scission of newly formed CME vesicles.¹⁹ Patients with *DNM1* mutation have severe ID and early onset intractable seizures (Table 1).

Early infantile epileptic encephalopathy (or EIEE) is an age-dependent syndrome with the age at onset confined to the neonatal period or very early in infancy; more than 75% manifests before the first month of life. It also has the characteristic EEG pattern of suppression-burst.²⁰ Although the previously reported *NECAP1* phenotype was similar to the current index (Table 2), we here show that our patient's course along with previously published information is not enough to label this syndrome as one of the EIEE causes. Thus, we suggest classifying it as one of the early onset epileptic encephalopathy syndromes until more reports delineate the phenotype.

Our institution's standardized consent was obtained from the parents of the index to participate in this study. The study received ethical approval from King Abdullah International Medical Research Center (KAIMRC), Riyadh, Saudi Arabia.

DISCLOSURE

The authors declare no conflicts of interest. We confirm that we have read the Journal's position on issues involved in ethical publication and affirm that this report is consistent with those guidelines.

REFERENCES

- Berg AT, Berkovic SF, Brodie MJ, et al. Revised terminology and concepts for organization of seizures and epilepsies: report of the ILAE Commission on Classification and Terminology, 2005–2009. *Epilepsia* 2010;51:676–685.
- McTague A, Howell KB, Cross JH, et al. The genetic landscape of the epileptic encephalopathies of infancy and childhood. *Lancet Neurol* 2016;15:304–316.
- de Kovel CG, Brilstra EH, van Kempen MJ, et al. Targeted sequencing of 351 candidate genes for epileptic encephalopathy in a large cohort of patients. *Mol Genet Genomic Med* 2016;4:568–580.
- EuroEPINOMICS-RES Consortium, Epilepsy Phenome/Genome Project, Epi4K Consortium. De novo mutations in synaptic transmission genes including *DNM1* cause epileptic encephalopathies. *Am J Hum Genet* 2014;95:360–370.
- Alazami AM, Hijazi H, Kentab AY, et al. *NECAP1* loss of function leads to a severe infantile epileptic encephalopathy. *J Med Genet* 2014;51:224–228.
- Murshid A, Srivastava A, Kumar R, et al. Characterization of the localization and function of *NECAP 1* in neurons. *J Neurochem* 2006;98:1746–1762.
- Ritter B, Murphy S, Dokainish H, et al. *NECAP 1* regulates AP-2 interactions to control vesicle size, number, and cargo during clathrin-mediated endocytosis. *PLoS Biol* 2013;11:e1001670.
- Beacham GM, Partlow EA, Lange JJ, et al. *NECAPs* are negative regulators of the AP2 clathrin adaptor complex. *Elife* 2018;7:e32242.
- Asinof SK, Sukoff Rizzo SJ, Buckley AR, et al. Independent neuronal origin of seizures and behavioral comorbidities in an animal model of a severe childhood genetic epileptic encephalopathy. *PLoS Genet* 2015;11:e1005347.
- von Spiczak S, Helbig KL, Shinde DN, et al. *DNM1* encephalopathy: a new disease of vesicle fission. *Neurology* 2017;89:385–394.
- Nakashima M, Kouga T, Lourenco CM, et al. De novo *DNM1* mutations in two cases of epileptic encephalopathy. *Epilepsia* 2016;57:e18–e23.
- Fung CW, Kwong AK, Wong VC. Gene panel analysis for nonsyndromic cryptogenic neonatal/infantile epileptic encephalopathy. *Epilepsia Open* 2017;2:236–243.
- Kolnikova M, Skopkova M, Ilencikova D, et al. *DNM1* encephalopathy – atypical phenotype with hypomyelination due to a novel de novo variant in the *DNM1* gene. *Seizure* 2018;56:31–33.
- Epi4K Consortium, Epilepsy Phenome/Genome Project, Allen AS, et al. De novo mutations in epileptic encephalopathies. *Nature* 2013;501:217–221.
- Allen NM, Conroy J, Shahwan A, et al. Unexplained early onset epileptic encephalopathy: exome screening and phenotype expansion. *Epilepsia* 2016;57:e12–e17.
- Deciphering Developmental Disorders Study. Large-scale discovery of novel genetic causes of developmental disorders. *Nature* 2015;519:223–228.
- Deng XL, Yin F, Zhang CL, et al. [Dynamin-1-related infantile spasms: a case report and review of literature]. *Zhonghua Er Ke Za Zhi* 2016;54:856–859.
- Epi KC. De novo mutations in *SLC1A2* and *CACNA1A* are important causes of epileptic encephalopathies. *Am J Hum Genet* 2016;99:287–298.
- Marks B, Stowell MH, Vallis Y, et al. GTPase activity of dynamin and resulting conformation change are essential for endocytosis. *Nature* 2001;410:231–235.
- Ohtahara S, Yamatogi Y. Ohtahara syndrome: with special reference to its developmental aspects for differentiating from early myoclonic encephalopathy. *Epilepsy Res* 2006;70(Suppl 1):S58–S67.