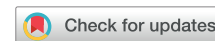

# Pink Urine Syndrome: A Combination of Insulin Resistance and Propofol



Bryan M. Tucker<sup>1</sup> and Mark A. Perazella<sup>2</sup>

<sup>1</sup>Wake Forest School of Medicine, Department of Internal Medicine, Section of Nephrology, Winston-Salem, North Carolina, USA; and <sup>2</sup>Yale University School of Medicine, Section of Nephrology, New Haven, Connecticut, USA

Pink urine syndrome is mostly seen in patients treated with propofol anesthesia. The pink color is attributed to the presence of large concentrations of uric acid (and pigment), which is excreted in large amounts when propofol is given. We describe a case of propofol-induced pink urine syndrome and perform a comprehensive, evidence-based review. We discuss prior case studies already published in the literature as we speculate on the pathophysiology and how it translates to a clinically relevant entity.

*Kidney Int Rep* (2019) 4, 30–39; <https://doi.org/10.1016/j.ekir.2018.10.009>

KEYWORDS: acid-base equilibrium; biological; insulin resistance; oxidative stress; pigments; propofol; uric acid

© 2018 International Society of Nephrology. Published by Elsevier Inc. This is an open access article under the CC BY-NC-ND license (<http://creativecommons.org/licenses/by-nc-nd/4.0/>).

In 1491 a German physician, Dr. Johannes de Ketham, published one of the first medical textbooks *Fasciculus medicinae*, where he describes using the urine to help diagnose disease.<sup>1</sup> Although our technology has improved, from the matula to the urine dipstick, discolored urine continues to intrigue us. Pink urine is most commonly from free heme pigment, which can be seen in hematuria, hemolytic anemia, myoglobinuria (rhabdomyolysis), and porphyria. Another major cause of pink urine is from food, most commonly from beets, rhubarb, and blackberries. A non-heme/non-food pink urine and/or sediment is referred to as pink urine syndrome and has generated interest and discussion for decades. We describe a case of pink urine syndrome in a patient treated with propofol (2,6-diisopropylphenol) anesthesia; and provide a comprehensive evidence-based review as we speculate on the many pathophysiological processes occurring.

## Case Presentation

A 21-year-old, white male (body mass index 28.2; 91.1kg) with no previous medical history, was admitted to the intensive care unit with acute hypoxic/hypercapnic respiratory failure, acute kidney injury (AKI), and septic shock in the setting of heroin use. The patient was diagnosed with methicillin-susceptible *Staphylococcus aureus* pneumonia. Due to worsening hypoxia and respiratory acidosis, he was intubated, using propofol for induction.


The following morning his creatinine increased to 1.8 mg/dl (from a baseline of 1.1 mg/dl). Urine sediment evaluation revealed a bright pink (Figure 1) pellet upon gross inspection, and light microscopy showed many amorphous crystals (Figure 2). To identify the crystal type, the patient's urine was acidified and alkalized and reassessed under light microscopy (Figure 3a). On acidification, polychromatic birefringence rhomboid uric acid crystallization became prominent (Figure 3b), whereas when we alkalized the urine, amorphous urate crystals were present (Figure 3c). The patient was given i.v. fluids and the serum creatinine returned to baseline within 2 days. He was extubated 3 days later and discharged shortly after on oral antibiotics.

## A Brief History of Pink Urine Syndrome

Pink urine syndrome refers to either pink urine and/or pink urine sediment that occurs in the absence of a heme-, medication-, or food-based pigment but typically seen in the presence of urinary uric acid and propofol. This entity first appeared in the literature in the 1800s by Louis Proust, where it was described as “*substance rosacée*” or “*acide rosacique*.”<sup>2</sup> The first clinical evaluation of pink urine syndrome in modern times, was in 1984 in a surgical cohort undergoing gastric partitioning.<sup>3</sup> In this obese cohort, one-half of the patients postoperatively had gross pink urine and 100% ( $n = 187$ ) demonstrated a pink urine sediment on centrifugation. This finding was “rarely” seen in the preoperative period and not seen in the nonobese population. Pink urine syndrome was associated with propofol 10 years later, in 1996, when a milky-pink urine was seen in 9 Japanese surgical patients after propofol anesthesia.<sup>4</sup> Before this, propofol was

**Correspondence:** Bryan M. Tucker, Wake Forest Baptist Medical Center, Section of Nephrology, Medical Center Boulevard, Winston-Salem, North Carolina 27157-0001, USA. E-mail: [bmtucker@wakehealth.edu](mailto:bmtucker@wakehealth.edu)

**Received 6 September 2018; accepted 8 October 2018; published online 13 October 2018**



**Figure 1.** Pink urine sediment after centrifugation in a patient who received propofol.

associated with white urine, which has been attributed to its grossly white, oil-in-water emulsion vehicle.<sup>5-7</sup> Propofol has also been associated with green urine and historically blamed on the water-soluble quinol derivatives,<sup>8</sup> but this has been challenged recently.<sup>9,10</sup>

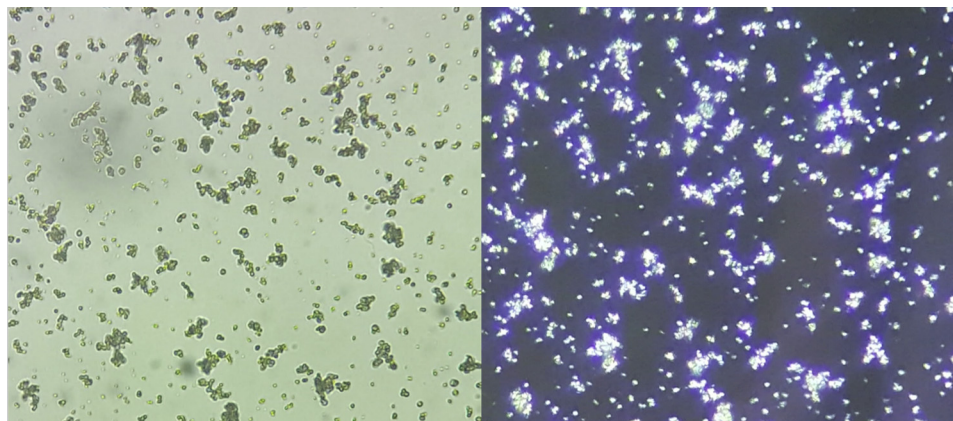
### Patient Characteristics

Case studies with pink urine syndrome have been published throughout the literature (Table 1), and

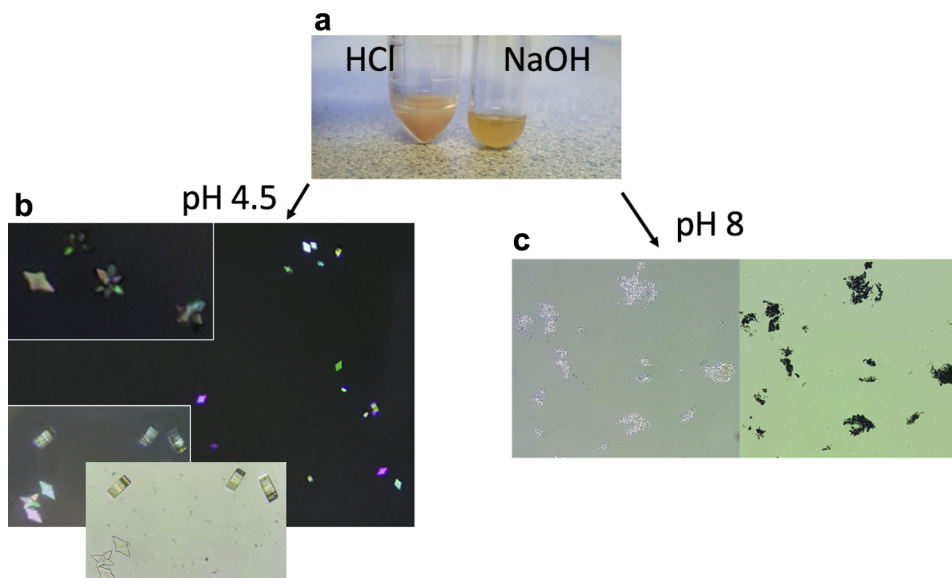
when these cases are evaluated together, similarities emerge. Most patients are obese males, have undergone surgery, were given propofol, have a low urine pH, and present without AKI or prerenal AKI. The association of these factors and their relationship to urinary uric acid are examined.

Upon closer inspection, specific characteristics (body mass index, male gender, low urinary pH) are also independent risk factors for uric acid crystallization and/or nephrolithiasis.<sup>11-14</sup> A pink urine syndrome cohort confirmed these risk factors for pink urine syndrome.<sup>15</sup> These characteristics, commonly seen with insulin resistance, are also more prevalent in males.<sup>12,16-18</sup> Of the preceding factors, a low urinary pH shows 100% prevalence in our cohort (Table 1), and is an independent risk factor in all the studies discussed, therefore deserves further evaluation.

Urine pH has a large influence on uric acid physiology. Specifically, a low pH will shift uric acid toward its protonated, neutral uric acid form and will increase the likelihood of precipitation. In an alkali solution, the shift is toward the negatively charged, water-soluble, urate, which exists in humans mostly as a salt, monosodium urate.<sup>19</sup> Urate has a pKa of approximately 5.4, therefore at a physiological pH of 7.4 (and 37°C), 98% of the urate is in its monovalent form, the urate anion.<sup>19</sup> When urinary acidification occurs, less urate is excreted, resulting in higher levels of urate in the blood. If the acidic urine is chronic, the total body urate pool would continue to increase, leading to hyperuricemia. A major determinant of urinary pH is the quantity of ammonia that is present. As a buffer, ammonia will bind free hydrogen ions ( $H^+$ ) forming ammonium ( $NH_4^+$ ), thereby decreasing free  $H^+$  and increasing urine pH. In the setting of reduced ammoniogenesis, more free  $H^+$  will be present because less ammonia is around to bind it, thereby resulting in a more acidic urine. This effect is visualized in Figure 3,



**Figure 2.** Amorphous crystals. Urine sediment examination demonstrating amorphous crystals. The left is  $\times 40$  light microscopy and the right is the same image but polarized.



**Figure 3.** The effect of pH on uric acid crystallization. One drop of 1 N HCl solution (1 normal = 36.5 g hydrochloric acid/1 liter) was mixed with 2 ml of patient's urine resulting in a reduction of pH, pinkish hue (a, left test tube) on gross inspection, and polychromatic birefringence uric acid crystallization with light microscopy (b). In a similar fashion, 1 drop of 1 N NaOH solution (1 N = 40 g sodium hydroxide/1 liter) was mixed with 2 ml of urine to serve as a negative-treatment response control. On NaOH addition, urine color became a dirty yellow (a, right test tube), urine pH increased, and amorphous crystals were present when analyzed with light microscopy (c).

where adding acid caused uric acid crystals to form, whereas adding base created amorphous urates.

A low urinary pH, which is a requirement for uric acid crystallization, commonly occurs in the setting of insulin resistance.<sup>20</sup> Patients with type 2 diabetes, in whom insulin resistance is present, compared with nondiabetic controls, are observed to have significantly reduced urinary pH in a multivariate analysis controlling for body weight, diet (via urinary sulfate), age, and creatinine clearance.<sup>21</sup> This non-diet cause of acidic urine seen in this insulin-resistant population can be attributed to a defect in ammoniogenesis. Specifically, insulin resistance can lead to a reduction in ammonia production, resulting in defective buffering capacity, more free  $H^+$  and low urine pH.<sup>22,23</sup> Insulin stimulates the renal tubular sodium-hydrogen exchanger (NHE3) in the proximal tubule via PI3K-SGK1 (phosphatidylinositol 3-kinase–serum and glucocorticoid-dependent kinase), which increases ammoniogenesis.<sup>24</sup> Chronic hyperinsulinemia, which is seen during insulin resistance, ineffectively stimulates ammoniogenesis via reduction of the intracellular signal strength.<sup>24,25</sup> The reduced intracellular signal strength in the proximal tubule is attributed to renal tubular epithelial lipid accumulation, or renal steatosis, and is not specific for attenuating insulin signal, but can also delay a glucocorticoid-mediated activation of NHE3 as well.<sup>26</sup> Another hypothesis for reduced ammonia excretion in the setting of insulin resistance involves the nuclear factor-erythroid 2 related factor 2 (Nrf2). This regulating transcription factor is upregulated in the setting of

oxidative stress, resulting in many more downstream antioxidant enzymes to be active as well. Through Nrf2 activation, we can see upregulation of the pentose phosphate pathway, oxaloacetate to  $\alpha$ -ketoglutarate synthesis, and glutamate to glutathione conversion.<sup>27</sup> Ogawa *et al.*<sup>27</sup> associates the reduction of urine pH to a relative glutamate deficiency as it is diverted to glutathione synthesis. With a reduction in the available glutamate, ammoniogenesis is reduced and less ammonium is present, resulting in a lower urinary pH.<sup>27</sup> This hypothesis is also supported by a significantly lower urinary glutamate seen in patients with pink urine syndrome.<sup>27</sup>

In general, insulin resistance and hypertriglyceridemia are present before the development of type 2 diabetes mellitus or metabolic syndrome.<sup>28</sup> An insulin-resistant state requires a relative increase in endogenous insulin production/release to sustain metabolic activity, and a state of relative hyperinsulinemia occurs. There is a strong independent positive correlation between insulin and insulin resistance with serum urate concentration in a variety of cohorts.<sup>29–31</sup> Insulin resistance reduces renal clearance of urate by increasing its absorption transporter, *URATI*, and decreasing urate excretion through downregulation of the *ABCG2* transporter.<sup>32–36</sup> Healthy non-insulin-resistant male individuals given a 2- or 4-hour infusion of insulin develop a temporal and graded reduction of urinary uric acid clearance.<sup>37,38</sup> Insulin resistance treated with diet or medications, without body mass index and/or blood pressure improvement, significantly reduces serum uric acid.<sup>39</sup>



**Table 1.** Pink urine syndrome case studies published in the literature

Author, year, location [reference]	Age - gender	Body mass index (kg/m <sup>2</sup> )	Urine pH	Serum uric acid (mg/dl)	Propofol given	AKI etiology	Presenting diagnosis-comorbid conditions
Thamcharoen N, <i>et al.</i> 2015 Thailand [92]	25 - Male	45	6	9.3	Yes	Prerenal, 24-hour correction with IVF	Mediastinal lymphoma, morbid obesity
Potton L, <i>et al.</i> 2013 France [93]	38 - Male	–	5	–	–	–	Liver transplant
Saran R, <i>et al.</i> 1998 USA [94]	42 - Female	70	–	9.8	–	–	Admitted for gastric bypass. PMHx: Morbid obesity, HTN, non-insulin dependent diabetes, hypercholesterolemia, OSA, CHF, depression, carpal-tunnel syndrome
Okubo K, <i>et al.</i> 2011 Japan [95]	44 - Male	–	6	–	–	No AKI	Liver hepatoma removal
Stern AB, <i>et al.</i> 2010 USA [96]	53 - Female	–	5	5.5 (postoperative)	Yes	No AKI	Admitted for debulking surgery for ovarian serous adenocarcinoma; HTN, unspecified nephrolithiasis
Schmitt R, <i>et al.</i> 2004 Germany [97]	69 - Male	–	5	6.44	No	No AKI	Positional vertigo, HTN
Hou JD, <i>et al.</i> 2016 Taiwan [98]	69 - Male	–	5.5	–	Yes	No AKI	Open fracture of the right femoral shaft
Verhoeven E, <i>et al.</i> 2014 Belgium [99]	55 - Male	–	5	–	Yes	–	Alcohol abuse with valerian extract overdose
Kato N and Ogawa R. 1999 Japan [100]	32 - Male	–	–	7	Yes	No AKI	Admitted for ulnar nerve injury; alcoholic, hypercholesterolemia
Tan CK and Lai CC 2012 Taiwan [101]	67 - Female	27	5.5	3.6	No	–	Admitted with spontaneous bacterial peritonitis and hepatic encephalopathy from upper gastrointestinal bleeding; overweight, diabetes mellitus, liver cirrhosis
Sinnollareddy M, <i>et al.</i> 2014 Australia [102]	29 - Male	–	–	–	Yes	–	Respiratory distress syndrome with acute alcohol toxicity
	61 - Male	95kg (no height given)	–	–	Yes	–	

AKI, acute kidney injury; CHF, congestive heart failure; HTN, hypertension; IVF, i.v. fluids; OSA, obstructive sleep apnea; PMHx, past medical history. This table demonstrates the important characteristics for the development of pink urine syndrome. The dashes represent unpublished/absent data.

## External/Environmental Factors

The external conditions and medications given are of equal importance to the development of pink urine syndrome. Most of these patients have undergone surgery, and even though propofol was given, surgery itself can predispose to urate excretion. Operative patients have more antidiuretic hormone (ADH) release due to stress, hemodynamics, and other factors.<sup>40–42</sup> ADH binds to the V1 receptor in the kidney and enhances urate excretion by downregulating the *GLUT9* transporter that reabsorbs urate and upregulating transporters that secrete urate (*ABCG2* and *NPT1*).<sup>43,44</sup> An ADH-dependent urate excretion effect has been demonstrated in hyponatremic patients,<sup>45</sup> although no study has evaluated the role of ADH in pink urine syndrome. Patients with pink urine syndrome have a higher postoperative urinary osmolality and reduced urine output as compared with obese, non-pink urine syndrome controls.<sup>3</sup> Using urinary osmolality as a surrogate for ADH, one can surmise that increased ADH levels were present. However, surgery is not required for pink urine syndrome to occur, as specific

cases in Table 1 did not have surgery and still developed pink urine syndrome. In fact, the prevalence of pink urine syndrome in a nonsurgical Japanese cohort is approximately 4%.<sup>15</sup> The data support a role for ADH in the development of pink urine syndrome, but a stronger factor in its development is propofol.

Propofol is a common anesthetic given for induction or maintenance sedation for mechanically ventilated patients in surgery or the intensive care unit. Because of its high lipophilicity, it is given in a lipid emulsion containing soybean oil, egg yolk lecithin, glycerol, sodium hydroxide, and EDTA.<sup>46</sup> Propofol has been demonstrated to increase urate excretion in the urine.<sup>47</sup> Compared with sevoflurane, propofol cleared significantly more urate (mean 22.9 ml/min vs. 5.9 ml/min) during elective surgery in patients with an American Society of Anesthesiologists physical status I or II (these classifications include healthy patients and mild systemic disease, such as well-controlled diabetes mellitus or hypertension).<sup>47</sup> There was no significant difference between urinary pH, creatinine clearance, or urine volume.<sup>47</sup> The total

urate clearance of propofol is significantly more than other situations that result in increased urate clearance, such as artificially induced hyperuricemia (14.4 ml/min)<sup>47,48</sup> or hypoxanthine-guanine phosphoribosyltransferase deficiency: 11.7 ml/min (range 4.2–20.8 ml/min).<sup>49</sup> The only other condition with urate clearance greater, is familial renal hypouricemia, in which urate clearance can be >30 ml/min. This occurs with a genetic mutation in *SLC22A12* (encodes URAT1) or *SLC2A9* (encodes GLUT9), both are proximal tubule urate reabsorption transporters.<sup>50,51</sup> The total body clearance of propofol is between 20 and 30 ml/min per kg, and when infusing, produces urate excretion at a similar clearance. Clinically, pink urine syndrome presents as a quick onset and abrupt cessation of urate clearance in the presence and absence of propofol, respectively. The exact mechanism is unknown, but there are other variables present that influence urate excretion that deserve mention. Diabetic patients can also produce glomerular hyperfiltration (estimated glomerular filtration rate [GFR] >141 ml/min per 1.73 m<sup>2</sup>), which increases intraglomerular pressure and flow.<sup>52</sup> Hyperfiltration, or increased urinary flow, directly increases urinary urate excretion.<sup>52–54</sup> Diabetic patients may also have glycosuria, which also increases urate excretion.<sup>55</sup> Propofol may secondarily increase urate efflux transporter in the proximal tubule (*ABCG2*) through the upregulation of Nrf2.<sup>56</sup> Regardless of the etiology, the ability to excrete urate in large amounts is dependent on the GFR.<sup>57</sup>

### Connecting Internal and External Variables

Having an adequate GFR with intact tubular function is one of the requirements for pink urine syndrome. Because acute prerenal AKI maintains tubular function, it is the only type of AKI that is seen with pink urine syndrome. Propofol exhibits many renoprotective benefits, such as improved creatinine clearance, reduced incidence of AKI, prevention of acute tubular necrosis, decreased need for renal replacement therapy, and reduced mortality.<sup>58,59</sup> The mechanism behind these findings is attributed to the antioxidant ability of propofol where it reacts with a free radical turning into a phenoxyl radical and can scavenge harmful radical species.<sup>58,60,61</sup> The antioxidant ability of propofol is similar to a phenol-based compound: it scavenges reactive species, induces endogenous antioxidant enzymes, and has anti-inflammatory effects.<sup>62</sup>

Environmental temperature plays a large role in urate physiology, thereby making it important for pink urine syndrome. Propofol administration in the clinical setting typically is seen in the operating room and critical care bed; both locations are considered to be

cold. As temperature decreases, the likelihood of uric acid precipitating increases.<sup>63</sup> Operating rooms are typically kept below 23 °C (73.4 °F).<sup>64</sup> At a normal physiological temperature (37 °C or 98.6 °F), precipitation starts to occur at uric acid of 6.8 mg/dl. When the temperature drops to 30 °C (86 °F), urate precipitation occurs at 4.5 mg/dl. The vehicle propofol is given with, a lipid emulsion, can attenuate this hypothermic effect, which may help maintain urate solubility in the body.<sup>65</sup> Once excreted and exposed to the external environment, the significantly reduced temperature would increase the risk of uric acid precipitation. In the presence of both, an acidic urine and reduced external temperatures, the lower the concentration of uric acid needs to be to precipitate.<sup>63,66</sup>

### The Pink Pigment

The pink hue of the urine in pink urine syndrome is from a pink urinary pigment. Many pink/reddish pigments exist: urobilin, urohematoporphyrin, uroporphyrin, coproporphyrin, urohemin, urocytin, indirubin, indigotin, uroerythrin, purpurin, skatol red, nephrochrome, urochrome, and uric acid (of which some may be even the same compound).<sup>67</sup> Uric acid-associated pigments include uric acid, urochrome, and biotripyrrin (previously called uroerythrin).<sup>67–69</sup> Of these, uric acid is the most likely to be the primary pigment responsible for pink urine syndrome. One of the first descriptions of uric acid was described by Dr. Kleeberg in 1974, where he observes: “its pink color in an acid medium and its amber yellow in an alkaline.”<sup>70</sup> (See our patient’s urine colors, [Figure 3a](#)). Uric acid is a pH-dependent, water-soluble, 2-pyrrole compound.<sup>71</sup> Like other endogenous pigments, uric acid is considered to originate from bilirubin metabolism. Uric acid has the strongest attachment to uric acid at an acidic pH, in which the rate-limiting reaction is dependent on uric acid concentration.<sup>71</sup> Using the raw data provided in the publication, we performed our own calculations on relationships that were not evaluated in the original article (see [Supplementary Table S1](#), for our statistical methods and full analysis). Excretion of uric acid did not correlate with urate excretion, although there was significantly more uric acid excretion in uric acid stone-formers (mean 836 mg/24 hours) as compared with non-gouty, non-stone-former controls (242 mg/24 hours) or patients with gout (321 mg/24 hours) (see [Supplementary Table S1](#) for all calculations and data).<sup>71</sup> Due to the paucity of clinically oriented data on any of the pink pigments, the exact clinical characterization of uric acid excretors cannot be done. The production of color relies on a redox reaction with a metal ion-complex. Therefore, any changes in specific

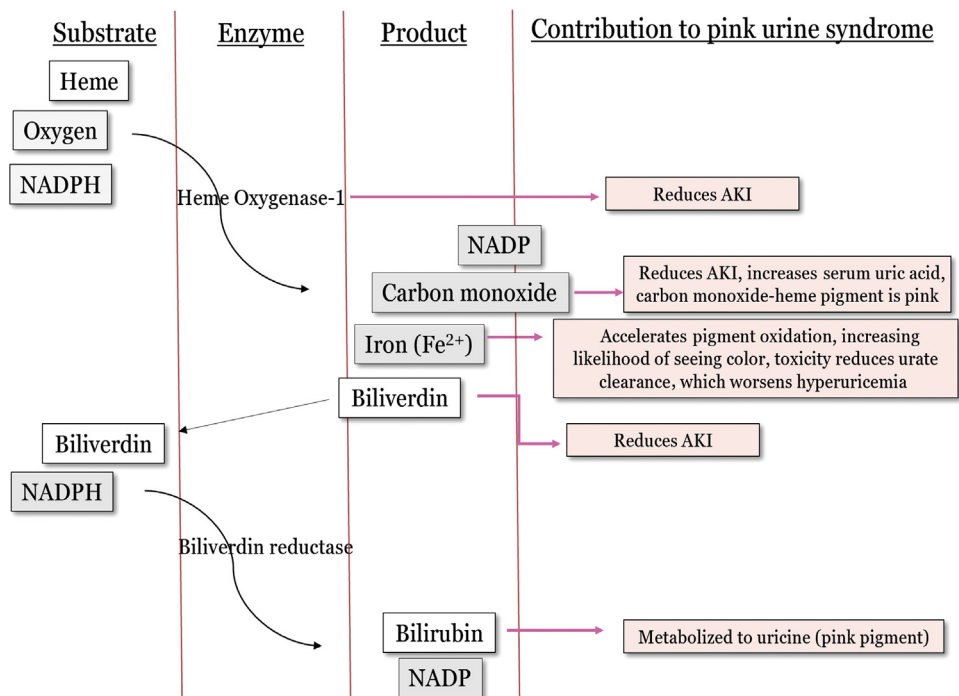
variables that influence this reaction may also influence the color change. Urine pH, being the most important, can directly determine the action of urate as a reducing agent or a metal ion's structure and optical activity.<sup>72-74</sup>

### Putting It All Together With a Common Pathway

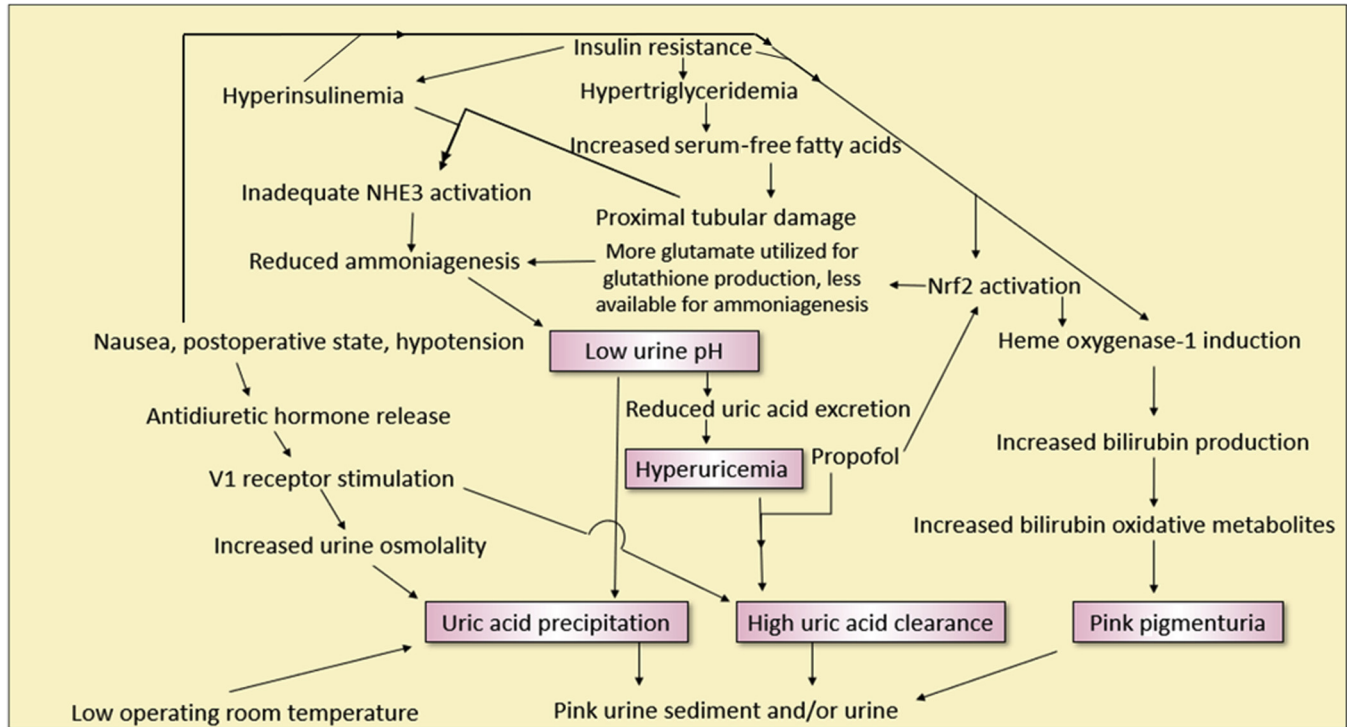
Although no specific studies have evaluated the specific pathway(s) involved in pink urine syndrome, we speculate its overlying mechanism. A specific oxidative stress pathway that includes the enzyme, heme oxygenase-1, is involved with nearly all the requirements to develop pink urine syndrome (Figure 4). Heme oxygenase-1 is found in most cells in the body and is induced by oxidative stress. Its function is to metabolize the toxic, pro-oxidant substrate heme to an antioxidant, bilirubin (this occurs through a biliverdin intermediate), and is a critical cytoprotective factor in the setting of oxidative stress.<sup>75,76</sup> The substrates are heme, oxygen, and reduced NAD phosphate and products are bilirubin, carbon monoxide, and iron (Figure 4). In any inflammatory environment there is an expected degree of heme oxygenase-1 induction to protect against oxidative damage. In the setting of insulin resistance, heme oxygenase-1 induction is overwhelmed, resulting in a suboptimal clinical response to the current oxidative load. A vicious cycle ensues between inflammation and macrophage adipose infiltration contributing to

worsening insulin resistance, sustaining an active heme oxygenase-1 pathway.<sup>77</sup> This is supported by a strong correlation between heme oxygenase-1 activity and insulin resistance.<sup>78</sup>

The products of this reaction seemingly contribute to some of the clinical variables seen in pink urine syndrome. Figure 4 demonstrates how heme oxygenase interacts with pink urine syndrome. Thus, being chronically active, the products slowly build up, and when propofol is given, a significant increase of heme oxygenase-1 activity is seen acutely. Free iron produced from heme oxygenase-1 is usually quickly sequestered by ferritin. With a chronically active heme oxygenase-1 pathway, more free iron will be present, resulting in more iron seen in the urine.<sup>79,80</sup> Serum urate, at physiological pH, has also been shown to sequester free iron.<sup>81</sup> This explains the free iron seen in the urine of some patients with pink urine syndrome, and one should also note that free metal in the urine can accelerate the oxidation of urinary pigments, thereby making it more likely to produce color.<sup>82</sup> Bilirubin is also produced and displays strong antioxidant properties, resulting in more of its oxidative metabolites being excreted in the setting of oxidative stress, which include the stress of surgery and intubation.<sup>83</sup> Urinary uric acid would be expected to increase in the setting of an active heme oxygenase-1 pathway because it is likely a product of bilirubin metabolism.<sup>84</sup> Heme oxygenase-1



**Figure 4.** The heme oxygenase-1 pathway. This enzymatic pathway is activated by oxidative stress and is chronically active during a state of insulin resistance. This pathway becomes overwhelmed and unable to become active enough to completely prevent the increasing amount of oxidative damage. Propofol can further activate this enzyme, which reduces oxidative damage and protects the cell. AKI, acute kidney injury; NADPH, nicotinamide adenine dinucleotide phosphate hydrogen.



**Figure 5.** Flow diagram demonstrating the complex interactions involved in pink urine syndrome. NHE3, renal tubular sodium-hydrogen exchanger; Nrf2, nuclear factor-erythroid 2 related factor 2.

activity has also been shown to protect against AKI, which is attributed to the removal of a toxins (heme and free iron) and production of cytoprotectants (bilirubin, carbon monoxide, ferritin).<sup>85</sup> Specific genetic polymorphisms that make heme oxygenase-1 less active result in significantly higher risk of AKI.<sup>86</sup>

Propofol reverses many of the effects seen during insulin resistance, which has been attributed to its superior antioxidant and anti-inflammatory activity.<sup>62,87</sup> Specifically, propofol activates the upstream Nrf2, which then activates many different antioxidant enzymes, including heme oxygenase-I.<sup>88</sup> The inherent antioxidant activity of propofol and its ability to increase endogenous antioxidant pathways (Nrf2/Heme oxygenase-1) delivers the complete antidiabetic, anti-inflammatory, and antioxidant response to an insulin-resistant, pro-oxidant environment.<sup>89,90</sup>

In summary, **Figure 5** shows the multiple interactions seen during pink urine syndrome. We created 5 pink boxes in **Figure 5**, identifying the minimum requirements needed for pink urine syndrome to occur, and they are as follows:

- (i) *Chronic hyperuricemia*: for large amounts of uric acid to appear in the urine, a larger urate pool is required to draw from.
- (ii) *Clearance of uric acid is acutely increased*: seen in the presence of propofol, and to a lesser extent, ADH.

- (iii) *Acidic urine*: required for uric acid precipitation.
- (iv) *An adequate GFR*: required for uric acid clearance.
- (v) *Chronic oxidative stress*: will increase pink pigment production through bilirubin metabolism. Oxidative stress increases bilirubin production, through the upregulation of heme oxygenase-1.

### CONCLUSION

A postulated explanation for the role of insulin resistance and propofol as the most common factors leading to pink urine syndrome is presented in **Figure 5**. Insulin resistance covers requirements 1, 3, and 5, whereas propofol administration covers requirements 2 and 4. Another scenario would be chronic alcohol use, which may explain some of the cases in **Table 1**. Alcohol reduces urate excretion and increases serum urate levels.<sup>91</sup> The other 4 requirements, a low urinary pH, intact GFR, oxidative stress, and some event/agent to acutely increase urate excretion, would need to be present as well for pink urine syndrome to occur. Using Occam’s razor, or developing a hypothesis with the fewest assumptions, the combination of insulin resistance and propofol would be the quickest pathway to pink urine syndrome.

### DISCLOSURE

All the authors declared no competing interests.



## ACKNOWLEDGMENTS

BMT received funding from Section of Nephrology, Wake Forest School of Medicine, Winston-Salem, NC.

## SUPPLEMENTARY MATERIAL

**Table S1.** Used raw data from Pinto B, Rocha E, Ruiz Marcellan FJ. Urinary excretion of uric acid. In: Muller MM, Kaiser E, Seegmiller JE, eds. *Purine Metabolism in Man—II*. Boston: Springer; 1977:86–89. Performed extra calculations, specifically means of urinary uric acid and urinary uric acid excretion, Mann-Whitney *U* Test for comparison groups, and the Pearson correlation coefficient in the evaluation of whether urinary uric acid excretion correlates with urinary uric acid excretion. Significance was defined as 2-tailed  $P < 0.05$ .

Supplementary material is linked to the online version of the paper at <http://www.kireports.org/>.

## REFERENCES

1. Diskin CJ. de Ketham revisited: a modern-day urine wheel. *Med J Aust*. 2008;189:658–659.
2. Garrod AE. A contribution to the study of uroerythrin. *J Physiol*. 1895;17:432–450.
3. Deitel M, Thompson DA, Saldanha CF, et al. “Pink urine” in morbidly obese patients following gastric partitioning. *Can Med Assoc J*. 1984;130:1007–1011.
4. Masuda A, Hirota K, Satone T, Ito Y. Pink urine during propofol anesthesia. *Anesth Analg*. 1996;83:666–667.
5. Nates J, Avidan A, Gozal Y, Gertel M. Appearance of white urine during propofol anesthesia. *Anesth Analg*. 1995;81:210.
6. Bodenham A, Culank LS, Park GR. Propofol infusion and green urine. *Lancet*. 1987;2:740.
7. Pedersen AB, Kobborg TK, Larsen JR. Grass-green urine from propofol infusion. *Acta Anaesthesiol Scand*. 2015;59:265–267.
8. Shioya N, Ishibe Y, Shibata S, et al. Green urine discoloration due to propofol infusion: a case report. *Case Rep Emerg Med*. 2011;2011:242514.
9. Kuiper M. Green urine. *Netherlands Journal of Critical Care*. 2015;19:30.
10. Fujii-Abe K, Kawahara H, Fukayama H. An analysis of green discoloration of urine caused by propofol infusion. *J Clin Anesth*. 2016;35:358–360.
11. Daudon M, Lacour B, Jungers P. Influence of body size on urinary stone composition in men and women. *Urol Res*. 2006;34:193–199.
12. Worcester EM, Bergsland KJ, Gillen DL, Coe FL. Mechanism for higher urine pH in normal women compared to men. *Am J Physiol Renal Physiol*. 2018;314:F623–F629.
13. Taylor EN, Curhan GC. Body size and 24-hour urine composition. *Am J Kidney Dis*. 2006;48:905–915.
14. Maalouf NM, Sakhaee K, Parks JH, et al. Association of urinary pH with body weight in nephrolithiasis. *Kidney Int*. 2004;65:1422–1425.
15. Ogawa S, Takiguchi J, Nako K, et al. Elucidation of the etiology and characteristics of pink urine in young healthy subjects. *Clin Exp Nephrol*. 2015;19:822–829.
16. Carnevale Schianca GP, Fra GP, Colli E, et al. Sex differences in lipid profiles in relation to the progression of glucose abnormalities. *J Diabetes*. 2012;4:95–101.
17. Marangella M. Uric acid elimination in the urine. Pathophysiological implications. *Contrib Nephrol*. 2005;147:132–148.
18. Chen HW, Chen YC, Yang FM, et al. Mediators of the effects of gender on uric acid nephrolithiasis: a novel application of structural equation modeling. *Sci Rep*. 2018;8:6077.
19. Murea M, Tucker BM. The physiology of uric acid and the impact of end-stage kidney disease and dialysis [e-pub ahead of print]. *Semin Dial*. doi: 10.1111/sdi.12735. Accessed July 10, 2018.
20. Maalouf NM, Cameron MA, Moe OW, et al. Low urine pH: a novel feature of the metabolic syndrome. *Clin J Am Soc Nephrol*. 2007;2:883–888.
21. Cameron MA, Maalouf NM, Adams-Huet B, et al. Urine composition in type 2 diabetes: predisposition to uric acid nephrolithiasis. *J Am Soc Nephrol*. 2006;17:1422–1428.
22. Abate N, Chandalia M, Cabo-Chan AV Jr, et al. The metabolic syndrome and uric acid nephrolithiasis: novel features of renal manifestation of insulin resistance. *Kidney Int*. 2004;65:386–392.
23. Maalouf NM, Cameron MA, Moe OW, Sakhaee K. Metabolic basis for low urine pH in type 2 diabetes. *Clin J Am Soc Nephrol*. 2010;5:1277–1281.
24. Fuster DG, Bobulescu IA, Zhang J, et al. Characterization of the regulation of renal Na<sup>+</sup>/H<sup>+</sup> exchanger NHE3 by insulin. *Am J Physiol Renal Physiol*. 2007;292:F577–F585.
25. Rocchini AP, Katch V, Kveselis D, et al. Insulin and renal sodium retention in obese adolescents. *Hypertension*. 1989;14:367–374.
26. Bobulescu IA, Dubree M, Zhang J, et al. Effect of renal lipid accumulation on proximal tubule Na<sup>+</sup>/H<sup>+</sup> exchange and ammonium secretion. *Am J Physiol Renal Physiol*. 2008;294:F1315–F1322.
27. Ogawa S, Takiguchi J, Shimizu M, et al. The reduction in urinary glutamate excretion is responsible for lowering urinary pH in pink urine syndrome. *Tohoku J Exp Med*. 2016;239:103–110.
28. Moors CC, van der Zijl NJ, Diamant M, et al. Impaired insulin sensitivity is accompanied by disturbances in skeletal muscle fatty acid handling in subjects with impaired glucose metabolism. *Int J Obes (Lond)*. 2012;36:709–717.
29. Bo S, Cavallo-Perin P, Gentile L, et al. Hypouricemia and hyperuricemia in type 2 diabetes: two different phenotypes. *Eur J Clin Invest*. 2001;31:318–321.
30. Bonora E, Capaldo B, Perin PC, et al. Hyperinsulinemia and insulin resistance are independently associated with plasma lipids, uric acid and blood pressure in non-diabetic subjects. The GISIR database. *Nutr Metab Cardiovasc Dis*. 2008;18:624–631.
31. Facchini F, Chen YD, Hollenbeck CB, Reaven GM. Relationship between resistance to insulin-mediated glucose uptake,



- urinary uric acid clearance, and plasma uric acid concentration. *JAMA*. 1991;266:3008–3011.
32. Miao Z, Yan S, Wang J, et al. Insulin resistance acts as an independent risk factor exacerbating high-purine diet induced renal injury and knee joint gouty lesions. *Inflamm Res*. 2009;58:659–668.
  33. Perez-Ruiz F, Aniel-Quiroga MA, Herrero-Beites AM, et al. Renal clearance of uric acid is linked to insulin resistance and lower excretion of sodium in gout patients. *Rheumatol Int*. 2015;35:1519–1524.
  34. Fraile JM, Puig JG, Torres RJ, et al. Uric acid metabolism in patients with primary gout and the metabolic syndrome. *Nucleosides Nucleotides Nucleic Acids*. 2010;29:330–334.
  35. Muscelli E, Natali A, Bianchi S, et al. Effect of insulin on renal sodium and uric acid handling in essential hypertension. *Am J Hypertens*. 1996;9:746–752.
  36. Toyoki D, Shibata S, Kuribayashi-Okuma E, et al. Insulin stimulates uric acid reabsorption via regulating urate transporter 1 and ATP-binding cassette subfamily G member 2. *Am J Physiol Renal Physiol*. 2017;313:F826–F834.
  37. Ter Maaten JC, Voorburg A, Heine RJ, et al. Renal handling of urate and sodium during acute physiological hyperinsulinaemia in healthy subjects. *Clin Sci (Lond)*. 1997;92:51–58.
  38. Quinones Galvan A, Natali A, Baldi S, et al. Effect of insulin on uric acid excretion in humans. *Am J Physiol*. 1995;268:E1–E5.
  39. Tsunoda S, Kamide K, Minami J, Kawano Y. Decreases in serum uric acid by amelioration of insulin resistance in overweight hypertensive patients: effect of a low-energy diet and an insulin-sensitizing agent. *Am J Hypertens*. 2002;15:697–701.
  40. Hazebroek EJ, de Vos tot Nederveen Cappel R, Gommers D, et al. Antidiuretic hormone release during laparoscopic donor nephrectomy. *Arch Surg*. 2002;137:600–604. discussion 605.
  41. Oka Y, Wakayama S, Oyama T, et al. Cortisol and antidiuretic hormone responses to stress in cardiac surgical patients. *Can Anaesth Soc J*. 1981;28:334–338.
  42. Amano J, Suzuki A, Sunamori M. Antidiuretic hormone and cardiovascular responses during and after coronary artery bypass surgery. *Thorac Cardiovasc Surg*. 1993;41:297–300.
  43. Decaux G, Namias B, Gulbis B, Soupart A. Evidence in hyponatremia related to inappropriate secretion of ADH that V1 receptor stimulation contributes to the increase in renal uric acid clearance. *J Am Soc Nephrol*. 1996;7:805–810.
  44. Taniguchi K, Tamura Y, Kumagai T, et al. Stimulation of V1a receptor increases renal uric acid clearance via urate transporters: insight into pathogenesis of hypouricemia in SIADH. *Clin Exp Nephrol*. 2016;20:845–852.
  45. Decaux G, Prospert F, Namias B, Soupart A. Hyperuricemia as a clue for central diabetes insipidus (lack of V1 effect) in the differential diagnosis of polydipsia. *Am J Med*. 1997;103:376–382.
  46. Baker MT, Naguib M. Propofol: the challenges of formulation. *Anesthesiology*. 2005;103:860–876.
  47. Masuda A, Asahi T, Sakamaki M, et al. Uric acid excretion increases during propofol anesthesia. *Anesth Analg*. 1997;85:144–148.
  48. Puig JG, Torres RJ, de Miguel E, et al. Uric acid excretion in healthy subjects: a nomogram to assess the mechanisms underlying purine metabolic disorders. *Metabolism*. 2012;61:512–518.
  49. Emmerson BT, Gordon RB, Johnson LA. Urate kinetics in hypoxanthine-guanine phosphoribosyltransferase deficiency: their significance for the understanding of gout. *Q J Med*. 1976;45:49–61.
  50. Benjamin D, Sperling O, Weinberger A, et al. Familial renal hypouricemia due to isolated tubular defect. *Adv Exp Med Biol*. 1977;76B:72–76.
  51. Claverie-Martin F, Trujillo-Suarez J, Gonzalez-Acosta H, et al. URAT1 and GLUT9 mutations in Spanish patients with renal hypouricemia. *Clin Chim Acta*. 2018;481:83–89.
  52. Bjornstad P, Roncal C, Milagres T, et al. Hyperfiltration and uricosuria in adolescents with type 1 diabetes. *Pediatr Nephrol*. 2016;31:787–793.
  53. Emmerson BT, Ravenscroft PJ, Williams G. The effect of urine flow rate on urate clearance. *Adv Exp Med Biol*. 1977;76B:23–29.
  54. Diamond HS, Lazarus R, Kaplan D, Halberstam D. Effect of urine flow rate on uric acid excretion in man. *Arthritis Rheum*. 1972;15:338–346.
  55. Lytvyn Y, Skrtic M, Yang GK, et al. Glycosuria-mediated urinary uric acid excretion in patients with uncomplicated type 1 diabetes mellitus. *Am J Physiol Renal Physiol*. 2015;308:F77–F83.
  56. Adachi T, Nakagawa H, Chung I, et al. Nrf2-dependent and -independent induction of ABC transporters ABCC1, ABCC2, and ABCG2 in HepG2 cells under oxidative stress. *J Exp Ther Oncol*. 2007;6:335–348.
  57. Aksenov S, Peck CC, Eriksson UG, Stanski DR. Individualized treatment strategies for hyperuricemia informed by a semi-mechanistic exposure-response model of uric acid dynamics. *Physiol Rep*. 2018;6(5).
  58. Li Y, Zhong D, Lei L, et al. Propofol prevents renal ischemia-reperfusion injury via inhibiting the oxidative stress pathways. *Cell Physiol Biochem*. 2015;37:14–26.
  59. Chen H, Busse LW. Novel therapies for acute kidney injury. *Kidney Int Rep*. 2017;2:785–799.
  60. Xu JJ, Wang YL. Propofol attenuation of hydrogen peroxide-mediated oxidative stress and apoptosis in cultured cardiomyocytes involves haeme oxygenase-1. *Eur J Anaesthesiol*. 2008;25:395–402.
  61. Murphy PG, Myers DS, Davies MJ, et al. The antioxidant potential of propofol (2,6-diisopropylphenol). *Br J Anaesth*. 1992;68:613–618.
  62. Marik PE. Propofol: therapeutic indications and side-effects. *Curr Pharm Des*. 2004;10:3639–3649.
  63. Loeb JN. The influence of temperature on the solubility of monosodium urate. *Arthritis Rheum*. 1972;15:189–192.
  64. Hart SR, Bordes B, Hart J, et al. Unintended perioperative hypothermia. *Ochsner J*. 2011;11:259–270.
  65. Jeong CW, Ju J, Lee DW, et al. Lipid-emulsion propofol less attenuates the regulation of body temperature than micro-emulsion propofol or sevoflurane in the elderly. *Yonsei Med J*. 2012;53:198–203.
  66. Teotia M, Sutor DJ. Crystallisation of ammonium acid urate and other uric acid derivatives from urine. *Br J Urol*. 1971;43:381–386.

67. Hall VM, Cox KA, Sours RE, Swift JA. Urochrome pigment in uric acid crystals. *Chemistry of Materials*. 2016;28:3862–3869.
68. Beruter J, Colombo JP, Schlunegger UP. Isolation and identification of the urinary pigment uroerythrin. *Eur J Biochem*. 1975;56:239–244.
69. Pinto B, Rocha E. Isolation and characterization of uricine. In: Muller MM, Kaiser E, Seegmiller JE, eds. *Purine Metabolism in Man—II*. Boston: Springer; 1977:77–80.
70. Kleeberg J. A hitherto undescribed pigment found in human urinary uric acid stones. *Experientia*. 1974;30:455–456.
71. Pinto B, Rocha E. Uricine—uric acid interactions. In: Muller MM, Kaiser E, Seegmiller JE, eds. *Purine Metabolism in Man—II*. Boston: Springer; 1977:81–85.
72. de Zawadzki A, Cardoso DR, Skibsted LH. Proton-coupled electron transfer promotes the reduction of ferrylmyoglobin by uric acid under physiological conditions. *Rsc Advances*. 2017;7:17824–17831.
73. Unnikrishnan AG, Rajaratnam S, John GT, Stephen C. Boy with 'rainbow' urine. *Nephrol Dial Transplant*. 2001;16:2097–2099.
74. Cole WJ, Gray CH, Nicholson DC, Norman M. The chemistry of the bile pigments. VI. The effect of metal complex formation upon optical activity and spectral absorption of urobilins. *J Chem Soc Perkin 1*. 1966;15:1321–1326.
75. Tenhunen R, Marver HS, Schmid R. Microsomal heme oxygenase. Characterization of the enzyme. *J Biol Chem*. 1969;244:6388–6394.
76. Takeda TA, Mu A, Tai TT, et al. Continuous de novo biosynthesis of haem and its rapid turnover to bilirubin are necessary for cytoprotection against cell damage. *Sci Rep*. 2015;5:10488.
77. Olefsky JM, Glass CK. Macrophages, inflammation, and insulin resistance. *Annu Rev Physiol*. 2010;72:219–246.
78. Bruce CR, Carey AL, Hawley JA, Febbraio MA. Intramuscular heat shock protein 72 and heme oxygenase-1 mRNA are reduced in patients with type 2 diabetes: evidence that insulin resistance is associated with a disturbed antioxidant defense mechanism. *Diabetes*. 2003;52:2338–2345.
79. Kohgo Y, Ikuta K, Ohtake T, et al. Body iron metabolism and pathophysiology of iron overload. *Int J Hematol*. 2008;88:7–15.
80. Moreno-Navarrete JM, Ortega F, Rodriguez A, et al. HMOX1 as a marker of iron excess-induced adipose tissue dysfunction, affecting glucose uptake and respiratory capacity in human adipocytes. *Diabetologia*. 2017;60:915–926.
81. Sevanian A, Davies KJ, Hochstein P. Serum urate as an antioxidant for ascorbic acid. *Am J Clin Nutr*. 1991;54(6 Suppl):1129S–1134S.
82. Garrod AE. On the pigmentation of uric acid crystals deposited from urine. *The Journal of Pathology and Bacteriology*. 1896;3:100–106.
83. Novio S, Nunez MJ, Ponte CM, Freire-Garabal M. Urinary biopyrrins: potential biomarker for monitoring of the response to treatment with anxiolytics. *Basic Clin Pharmacol Toxicol*. 2012;111:206–210.
84. Pinto B, Rocha E, Ruiz-Marcellan FJ. Isolation and characterization of uricine from uric acid stones. *Kidney Int*. 1976;10:437–443.
85. Nath KA. Heme oxygenase-1 and acute kidney injury. *Curr Opin Nephrol Hypertens*. 2014;23:17–24.
86. Leaf DE, Body SC, Muehlschlegel JD, et al. Length polymorphisms in heme oxygenase-1 and AKI after cardiac surgery. *J Am Soc Nephrol*. 2016;27:3291–3297.
87. Han C, Ding W, Jiang W, et al. A comparison of the effects of midazolam, propofol and dexmedetomidine on the antioxidant system: a randomized trial. *Exp Ther Med*. 2015;9:2293–2298.
88. Yao W, Luo G, Zhu G, et al. Propofol activation of the Nrf2 pathway is associated with amelioration of acute lung injury in a rat liver transplantation model. *Oxid Med Cell Longev*. 2014;2014:258567.
89. Shrivah J, Wang B, Pavlovic M, et al. Propofol mediates signal transducer and activator of transcription 3 activation and crosstalk with phosphoinositide 3-kinase/AKT. *JAK-STAT*. 2014;3:e29554.
90. Xie CL, Pan YB, Hu LQ, Qian YN. Propofol attenuates hydrogenperoxide-induced apoptosis in human umbilical vein endothelial cells via multiple signaling pathways. *Korean J Anesthesiol*. 2015;68:488–495.
91. Lieber CS, Jones DP, Losowsky MS, Davidson CS. Interrelation of uric acid and ethanol metabolism in man. *J Clin Invest*. 1962;41:1863–1870.
92. Thamcharoen N, Leeaphorn N, Sanguankeo A. A pretty clue in pink: pink urine in a morbidly obese patient with lymphoma. *Clin Nephrol*. 2015;84:116–117.
93. Potton L, Bonadona A, Minet C, Timsit JF. Pink urine. *Intensive Care Med*. 2013;39(3):389–390.
94. Saran R, Abdullah S, Goel S, et al. An unusual cause of pink urine. *Nephrol Dial Transplant*. 1998;13:1579–1580.
95. Okubo K, Okubo H, Kamijo Y, Higuchi M. Pink urine syndrome. *Intern Med*. 2011;50:2057.
96. Stern AB, Stewart HD, Singh HK, Kshirsagar AV. Pink urine after propofol anesthesia. *Kidney Int*. 2010;78:1193.
97. Schmitt R, Hampich F, Luft FC. Apricot urine in autumn. *Nephrol Dial Transplant*. 2004;19:2147–2148.
98. Hou J-D, Peng C-Z. Pink urine following propofol anesthesia. *Int J Gerontol*. 2016;10:245.
99. Verhoeven E, Capron A, Hantson P. Pink urine. *Clin Toxicol (Phila)*. 2014;52:980–981.
100. Kato N, Ogawa R. Does use of propofol in heavy alcohol drinkers tend to discolor their urine? *Acta Anaesthesiol Scand*. 1999;43:868–869.
101. Tan CK, Lai CC. Pink urine in an elderly woman. *Geriatr Gerontol Int*. 2012;12:358–359.
102. Sinnollareddy M, Marotti SB. Propofol-associated urine discoloration in critically ill patients—case reports. *Anaesth Intensive Care*. 2014;42:268–269.