

Müllerian inhibiting substance/anti-Müllerian hormone type II receptor protein and mRNA expression in the healthy and cancerous endometria

SU MI KIM, YUN OH KIM, MIN KYOUNG LEE, YOUN JEE CHUNG,
IN CHEUL JEUNG, MEE RAN KIM and JANG HEUB KIM

Department of Obstetrics and Gynecology, Seoul St. Mary's Hospital, College of Medicine,
Catholic University of Korea, Seocho, Seoul 06591, Republic of Korea

Received December 21, 2017; Accepted May 31, 2018

DOI: 10.3892/ol.2018.9565

Abstract. Müllerian inhibiting substance/anti-Müllerian hormone (MIS/AMH) is a regulator of the female reproductive system, an indicator of ovarian reserve and a growth inhibitor of Müllerian duct-derived tumors *in vivo* and *in vitro*. The objective of the present study was to analyze MIS/AMH type II receptor (MIS/AMHR II) protein and mRNA expression in healthy human endometria compared with patients with endometrial hyperplasia and endometrial cancer, providing a foundation for MIS/AMH as a biological modifier for treatment of endometrial hyperplasia and endometrial cancer. The present study included healthy endometrial tissues (n=20), simple endometrial hyperplasia tissues without atypia (n=17), complex endometrial hyperplasia tissues without atypia (n=24) and endometrial cancer tissues (n=8). The location and variation of MIS/AMHR II protein expression was observed by immunohistochemistry. The expression was graded by two pathologists and was categorized as follows: Negative, weakly positive, moderately positive or strongly positive. Reverse transcription-quantitative polymerase chain reaction was used to quantify MIS/AMHR II mRNA expression. The expression of MIS/AMHR II protein was observed in the cytoplasm of healthy human endometria, endometrial hyperplasia and endometrial cancer cells. The frequency of MIS/AMHR II protein expression was 20.22±10.35% in the proliferative phase of the healthy endometrium and 24.09±11.73% in the secretory phase of the healthy endometrium. However, no differences were observed in the menstrual cycle phases. The

frequency was 54.50±16.59% in endometrial hyperplasia without atypia, 55.10±15.87% in endometrial hyperplasia with atypia and 73.88±15.70% in endometrial cancer, indicating that expression was enhanced as the disease progressed from healthy to malignant status. In endometrial hyperplasia, MIS/AMHR II protein expression was significantly associated with histological complexity compared with atypia status. The present study demonstrated that MIS/AMHR II is present in healthy endometria, endometrial hyperplasia and endometrial cancer. The low expression frequency of MIS/AMHR II was not significantly different among normal endometrial tissues, however, the protein expression was elevated in endometrial hyperplasia and endometrial cancer. These findings indicated that the study of bioactive MIS/AMH, as a possible treatment for tumors expressing the MIS/AMH receptor, is essential.

Introduction

Endometrial hyperplasia is defined as proliferation of irregularly-shaped glands, resulting from an increased ratio of gland to matrix cells. Its pathologically hyperplastic status is stimulated by estrogen, without an antagonistic reaction of progesterone (1). According to histology, endometrial hyperplasia is divided into simple and complex types, and further divided according to the presence of cellular atypia. Complex hyperplasia with atypia has been reported to increase endometrial cancer risk (2).

Histologically, endometrial cancer is divided into two types: Type I estrogen-dependent endometrioid adenocarcinoma and type II, serous and all other forms of endometrial cancer (3). The former has been reported to occur in perimenopausal patients of a relatively young age (4). It is followed or accompanied by atypical complex endometrial hyperplasia, accounting for 75% of all types of endometrial cancer (4). **Type II endometrial cancer** has been indicated to occur in patients of older age, accounting for 25% of all types of endometrial cancer, with a decreased 5-year survival rate compared with type I endometrial cancer (5). Estrogen serves an important role in type I endometrial cancer. Therefore, hormone therapy is used in addition to radical dissection, radiation therapy and chemotherapy. However, the discovery of a novel therapy is

Correspondence to: Professor Jang Heub Kim, Department of Obstetrics and Gynecology, Seoul St. Mary's Hospital, College of Medicine, Catholic University of Korea, 222 Banpo-daero, Seocho, Seoul 06591, Republic of Korea
E-mail: janghkim@catholic.ac.kr

Key words: Müllerian inhibiting substance, anti-Müllerian hormone, Müllerian inhibiting substance/anti-Müllerian hormone type II receptor, endometrium, endometrial hyperplasia, endometrial cancer

required to conserve fertility and enhance efficacy of cancer treatment (6).

The term müllerian inhibiting substance (MIS), was coined by Alfred Jost, who discovered the non-testosterone material in rabbit fetal testis (7). MIS has been reported to degenerate the Müllerian duct (8). MIS, also known as anti-Müllerian hormone (AMH), is a 140 kDa glycoprotein composed of 545 amino acids, and is a member of the transforming growth factor (TGF)- β multigene family (9). The Müllerian duct is formed from coelomic epithelium and develops into the female salpinx, uterus, uterine cervix, proximal vagina and ovarian epithelium (10). MIS/AMH serves an important role in genital development by inhibiting female genital organ development in the male fetus. MIS is not detectable in the fetal ovary, however, following puberty, it is secreted into the follicular fluid and the serum from the ovarian granular tissue (11). The MIS/AMH protein expression level is used to check the ovarian reserve based on the condition that the concentration does not significantly vary in males (2-5 ng/ml), and that MIS/AMH is not detectable after menopause (11-13). There have been numerous reports of MIS/AMH function as a tumor biomarker and as a treatment for Müllerian duct-originated tumors (14,15). Numerous studies have reported that the suppressive effect of MIS on ovarian cancer cells increases with the concentration of MIS/AMH (15-20). There have been numerous reports of the anti-cancer effect of MIS/AMH on MIS/AMH receptor-presenting cervical cancer (21,22), breast cancer tissues and cells (23), and endometrial cancer (24,25).

The present study was designed to reveal the protein expression level of MIS/AMH type II receptor (MIS/AMHR II) in healthy endometria, endometrial hyperplasia and endometrial cancer tissue. Furthermore, the study aimed to evaluate the potential clinical use of MIS/AMH as a biological modifier for MIS/AMHR II-expressing endometrial tumors.

Materials and methods

Collection of endometrial tissue. The present study included 69 premenopausal female patients (median age, 46 years; interquartile range, 42-51 years), who underwent endometrial curettage for endometrial hyperplasia or total hysterectomy for endometrial cancer, between July 2011 and December 2014 at Seoul St. Mary's Hospital (Seoul, South Korea). The exclusion criteria included post-menopause, history and/or co-existing cancer and other endometrial disease, including endometrial polyp and submucosal myoma. Healthy endometrial tissues (n=20), simple endometrial hyperplasia tissues without atypia (n=17), complex endometrial hyperplasia tissues without atypia (n=24) and endometrial cancer tissues (n=8) were collected from the patients. Written informed consent was obtained from all patients prior to enrollment in the present study. The present study was approved by the Institutional Review Board-Human Research Committee at Seoul St. Mary's Hospital (Seoul, South Korea; approval nos. KC14SIS10546 and KC11TISI0491).

Immunohistochemistry. Paraffin-embedded tissues were sectioned into 4- μ m slices and attached to ProbeOn Plus microscope slides (Thermo Fisher Scientific, Inc., Waltham, MA, USA). The immunostaining procedure was as follows:

The tissue was embedded in 40% formalin at room temperature immediately following tissue sampling and stored for 10 min. The slides were deparaffinized in xylene and rehydrated in 100, 95, 80 and 70% graded ethanol at room temperature. In order to retrieve antigenic sites, the slides were autoclaved at 121°C for 10 min in 0.01 M sodium citrate (Thermo Fisher Scientific, Inc.) and cooled for 20 min at room temperature. Tissue samples were subsequently washed 4 times with 0.1% Tween-20 Tris-buffered saline (T-TBS; Lab Vision Corporation, Fremont, CA, USA). The slides were immunostained using a CAP-PLUS detection kit (Thermo Fisher Scientific, Inc.), according to the manufacturer's protocol. Following treatment with 3% peroxidase for 10 min at room temperature to block non-specific protein binding and washing with PBS, 5% goat serum (Thermo Fisher Scientific, Inc.), was added for 1 h at room temperature. The slides were incubated with rabbit polyclonal anti-human MIS/AMHR II antiserum (provided by Professor Patricia K. Donahoe, Massachusetts General Hospital, Boston, MA, USA; dilution, 1:100) as a primary antiserum at 4°C overnight. The slides were rinsed in PBS and incubated with biotinylated anti-rabbit IgG (CAP-PLUS detection kit) as a secondary antibody at room temperature for 1 h. Following rinsing with PBS, a streptavidin horseradish peroxidase detection system (CAP-PLUS detection kit) was applied to the slides for 30 min to induce the biotin-avidin binding reaction. Following washing in T-TBS (Lab Vision Corporation) for 5 min, the slides were treated with 3-amino-9-ethylcarbazole for 10 min at room temperature, counterstained with undiluted hematoxylin (YD Diagnostics Co., Ltd., Yongin, Kyunggio, Korea) for 1 min at room temperature and then mounted with aqueous mount solution (Lab Vision Corporation). The expression of MIS/AMHR II was observed at magnification, x200 and x400 using a light microscope (BX53; Olympus Corporation, Tokyo, Japan) and images were captured with a microscopic camera (DP20-5; Olympus Corporation).

Expression scoring system and statistical analysis. Immunohistochemistry was assessed independently by two pathologists. Staining intensity was classified as positive when the intensity level exceeded that of normal follicular granulosa cells. The frequencies of positively stained cells in 5 fields of view under x200 magnification were counted. Frequency <30% was classified as weakly positive, 30-60% as moderately positive and >60% as strongly positive. Negative staining was scored as 0, weakly positive as 1, moderately positive as 2 and strongly positive as 3.

RNA extraction and reverse transcription-quantitative polymerase chain reaction (RT-qPCR). RT-qPCR was performed on healthy endometrial tissues, endometrial hyperplasia and endometrial cancer tissues, in order to determine MIS/AMHR II mRNA expression. Total RNA was extracted from patient tissues by TRIzol™ LS Reagent (Thermo Fisher Scientific, Inc.).

The first reverse transcription was performed to synthesize cDNA from RNA using a cDNA Synthesis kit (Takara Bio, Inc., Otsu, Japan). The PCR mixture consisted of 5XPCR buffer (4 μ l), MMLV reverse transcription (1 μ l), dNTP mix (1 μ l), random primer (2 μ l), RNase inhibitor (1 μ l), 2 μ g RNA

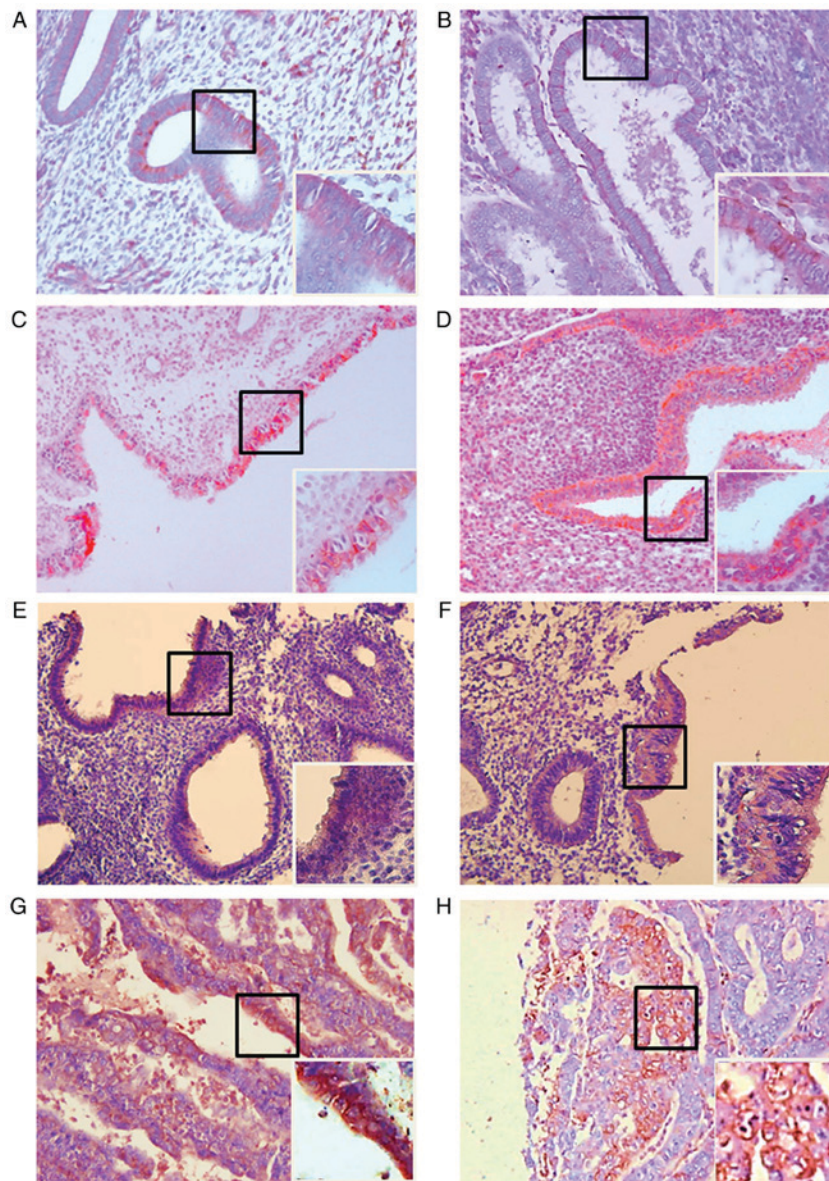


Figure 1. Light photomicrographs of human healthy endometrium, endometrial hyperplasia and endometrial cancer tissue. Expression of Müllerian inhibiting substance/anti-Müllerian hormone type II receptor in the cell membrane. (A) Proliferative human healthy endometrium. (B) Secretory human healthy endometrium. (C) Simple endometrial hyperplasia without atypia. (D) Complex endometrial hyperplasia without atypia. (E) Simple endometrial hyperplasia with atypia. (F) Complex hyperplasia with atypia. (G) Endometrial cancer (H) Endometrial cancer. In each panel, the right main image is at magnification, x200, and the lower boxed area is at magnification, x400.

and diethyl pyrocarbonate water to a total volume of 20 μ l. Thermocycling conditions were: 25°C for 10 min, 42°C for 60 min and 70°C for 10 min. The PCR products were stored at -20°C.

To compare the amount of cDNA, a second PCR was performed. The cDNA products were amplified using Premix Taq (Takara Ex Taq version; Takara Korea Biomedical Inc.). The PCR mixture consisted of PCR premix (10 μ l), downstream primer (10 pmol, 1 μ l), upstream primer (10 pmol, 1 μ l), cDNA (1 μ l) and RNase-free sterile water for a total volume of 20 μ l. Amplification started with denaturation at 94°C for 5 min followed by 30 cycles of 94°C for 40 sec, 57°C for 40 sec and 72°C for 25 sec and the final reaction was performed at 72°C for 10 min. The sequences of the PCR primers were as follows: Sense primer, 5'-CCCTGCTACAGCGAAAGAAC-3' (MIS/AMHR II cDNA; Gene Bank, accession no. AF172932;

sequence 581-600) and anti-sense primer, 5'-TGGGTCAAGTAGTGGCACAG-3' (sequence 921-941); and GAPDH sense, 5'-CGGGAAGCTTGTCATCAATGG-3' and anti-sense, 5'-GGCAGTGATGGCATGGACTG-3' (322 bp). PCR products (10 μ l) were separated by electrophoresis on a 1.5% agarose gel and the band size (361 bp) was compared to a DNA Molecular Weight Markers 100 bp DNA ladder (cat. no. D-1030; Bioneer Corporation, Daejeon, Korea).

To compare the amount of cDNA quantitatively, a third PCR was performed. Quantitative PCR (qPCR) was performed to quantify mRNA expression levels of MIS/AMHR II and GAPDH. mRNA expression levels were measured using Bio-Rad CFX96 Real-Time PCR system (Bio-Rad Laboratories, Inc., Hercules, CA, USA), according to the manufacturer's protocol. PCR reactions were performed in a 20 μ l total reaction volume comprised of 10 μ l iTaq™ Universal

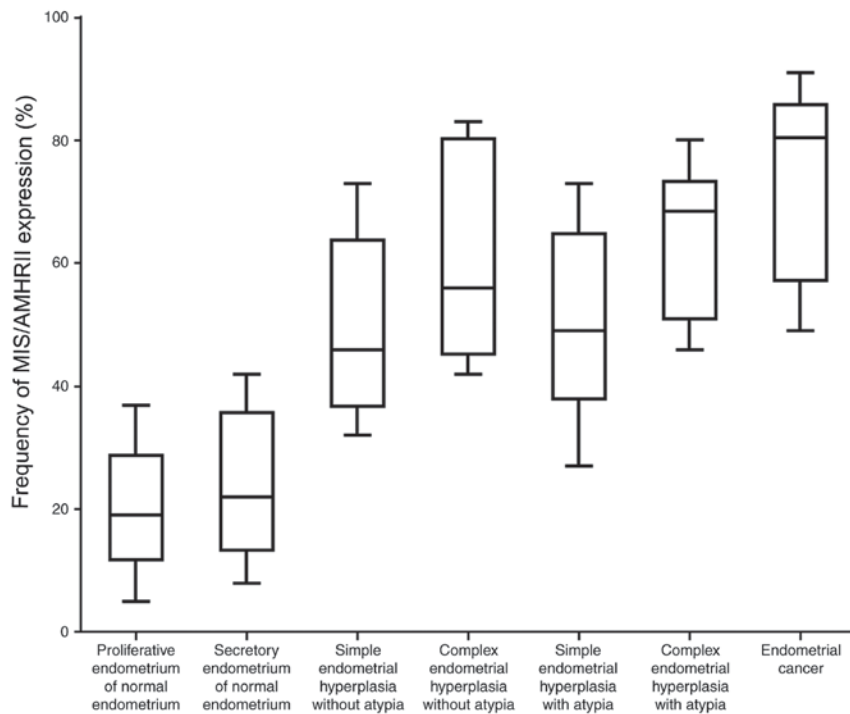


Figure 2. The frequency of MIS/AMHR II expression in proliferative healthy human endometria, secretory healthy human endometria, simple endometrial hyperplasia without atypia, complex endometrial hyperplasia without atypia, simple endometrial hyperplasia with atypia, complex endometrial hyperplasia with atypia and endometrial cancer. MIS/AMHR II, Mullerian inhibiting substance/anti-Müllerian hormone type II receptor.

SYBR[®]-Green Supermix (2X) (Bio-Rad Laboratories, Inc.), 1 μ l of each gene-specific primer (10 μ M), 2 μ l of cDNA templates and 6 μ l of H₂O. qPCR was performed at 94°C for 2 min followed by 40 cycles at 94°C for 10 sec, 57°C for 1 min and 30 sec at 72°C for each gene. GAPDH was used as a loading control. Each reaction was performed in triplicate. Relative quantification of gene expression levels was expressed as fold change, normalized against loaded controls, using the $2^{-\Delta\Delta C_q}$ method (26). Each sample was detected in triplicate.

Statistical analysis. Data were analyzed using one-way analysis of variance, followed by least-significant difference and Duncan's multiple range tests. All analyses were performed using SPSS 20.0 (for Windows; IBM Co., Armonk, NY, USA). $P < 0.05$ was considered to indicate a statistically significant difference.

Results

Expression of MIS/AMHR II protein. All 20 healthy endometrial tissues expressed MIS/AMHR II protein. Among the 9 normal proliferative phase endometrial tissues, 7 cases (78%) were classified as weakly positive and 2 cases (22%) as moderately positive (Fig. 1A). In the 11 normal secretory phase tissues, 8 cases (73%) were weakly positive and 3 cases (27%) were moderately positive (Fig. 1B). Among the 41 endometrial hyperplasia cases, 12 cases were determined to exhibit simple hyperplasia without atypia and 7 (58%) were moderately positive, while 5 (42%) were strongly positive (Fig. 1C). In the 5 cases of complex hyperplasia without atypia, 3 cases (60%) were moderately positive and 2 cases (40%) were strongly positive (Fig. 1D). In the 12 cases of simple hyperplasia with atypia,

2 cases (17%) were weakly positive, 5 (42%) were moderately positive and 5 (42%) were strongly positive (Fig. 1E). In the 12 cases of complex hyperplasia with atypia, 6 cases (50%) were moderately positive and 6 cases (50%) were strongly positive (Fig. 1F). In the 8 endometrial cancer cases, 2 cases (25%) were classified as moderately positive and 6 cases (75%) were strongly positive (Fig. 1G and H).

Quantification of MIS/AMHR II protein expression. The frequency of MIS/AMHR II protein expression was $20.22 \pm 10.35\%$ in normal proliferative phase endometrial tissues and $24.09 \pm 11.73\%$ in normal secretory phase endometrial tissues. Cases of simple hyperplasia without atypia indicated a frequency of MIS/AMHR II protein expression of $49.92 \pm 14.9\%$, while complex hyperplasia without atypia indicated a frequency of $61.40 \pm 18.22\%$. Simple hyperplasia with atypia demonstrated a frequency of MIS/AMHR II protein expression of $50.44 \pm 15.49\%$, while complex hyperplasia with atypia indicated a frequency of $64.32 \pm 12.40\%$. Endometrial cancer cases indicated a frequency of $73.88 \pm 15.70\%$ (Fig. 2). The frequency of MIS/AMHR II protein expression was 1.22 ± 0.44 in normal phase endometrial tissues, 1.27 ± 0.47 in normal secretory phase endometrial tissues, 2.42 ± 0.51 in simple hyperplasia without atypia, 2.40 ± 0.55 in complex hyperplasia without atypia, 2.25 ± 0.75 in simple hyperplasia with atypia, 2.60 ± 0.52 in complex hyperplasia with atypia and 2.75 ± 0.46 in endometrial cancer. The protein expression of MIS/AMHR II significantly increased with advancement of pathological status ($P < 0.05$). The frequency of MIS/AMHR II expression was $54.50 \pm 16.59\%$ in endometrial hyperplasia without atypia and $55.10 \pm 15.87\%$ in endometrial hyperplasia

Table I. The frequency of MIS/AMHR II protein expression in endometrial hyperplasia, according to atypia status and histological complexity.

| Pathology | Frequency (median \pm standard deviation) | Staining intensity score |
|--|---|------------------------------|
| Endometrial hyperplasia without atypia | 54.50 \pm 16.59 | 2.44 \pm 0.51 |
| Endometrial hyperplasia with atypia | 55.10 \pm 15.87 | 2.38 \pm 0.65 |
| Simple endometrial hyperplasia | 50.55 \pm 15.19 ^a | 2.29 \pm 0.67 ^a |
| Complex endometrial hyperplasia | 60.25 \pm 15.29 ^a | 2.47 \pm 0.50 ^a |

^aP<0.05 compared with endometrial hyperplasia without atypia.

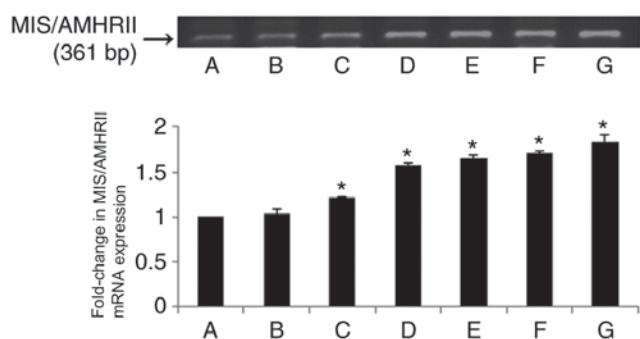


Figure 3. The upper panel indicates reverse transcription-quantitative polymerase chain reaction results of human MIS/AMHR II mRNA. The lower panel indicates fold-changes in mRNA levels of MIS/AMHR II relative to normal endometria, normalized to the mRNA expression level of GAPDH. Vertical bars indicate relative fold-change \pm standard error of the mean. A, proliferative human healthy endometria; B, secretory human normal endometria; C, simple endometrial hyperplasia without atypia; D, complex endometrial hyperplasia without atypia; E, simple endometrial hyperplasia with atypia; F, complex hyperplasia with atypia; G, endometrial cancer. MIS/AMHR II, Müllerian inhibiting substance/anti-Müllerian hormone type II receptor. MIS/AMHR II, Mullerian inhibiting substance/anti-Müllerian hormone type II receptor. *P<0.05 compared with proliferative healthy endometria.

with atypia. However, a significant difference was identified between simple endometrial hyperplasia (50.55 \pm 15.19%) and complex endometrial hyperplasia (60.25 \pm 15.29%) regardless of atypia (P<0.05; Table I).

MIS/AMHR II mRNA expression levels. RT-qPCR analysis was performed to verify the mRNA expression of MIS/AMHR II and a 361-bp-sized band identical to part of the human MIS/AMHR II cDNA sequence (sequence581-941; Gene Bank Accession no. AF172932) was expressed by all healthy endometrial tissues (Fig. 3A and B), endometrial hyperplasia tissues (Fig. 3C-F) and endometrial cancer tissues (Fig. 3G).

Quantification of MIS/AMHR II mRNA expression. The mRNA expression levels of MIS/AMHR II were not significantly different between normal endometrial tissues in the proliferative and secretory phases (fold-change, 1.03 \pm 0.05; Fig. 3A and B). The levels of MIS/AMHR II mRNA expression in simple and complex endometrial hyperplasia without atypia were increased compared with normal endometrial tissues

(P<0.05; Fig. 3C and D). The levels of MIS/AMHR II mRNA expression in simple and complex endometrial hyperplasia with atypia were increased compared with normal endometrial tissues (P<0.05; Fig. 3E and F). In endometrial cancer, the level of MIS/AMHR II expression was also increased compared with normal endometrial tissues (P<0.05; Fig. 3G). The RT-qPCR results demonstrated that MIS/AMHR II mRNA expression is increased in endometrial hyperplasia and cancer tissues compared with normal endometrial tissues.

Discussion

MIS is a member of the TGF- β multigene family, which includes TGF- β , actinin, inhibin, Vg1, bone morphogenetic protein, decapentaplegia and growth and differentiation factor (27). Signals mediated by MIS/AMH are transported via the heteromeric complex MIS/AMH receptor composed of tissue-specific type I and II transmembrane serine/threonine kinase receptors (28). Following the binding of the proteolyzed 25-kDa carboxyl ends of MIS to MIS/AMHR II, MIS/AMH activates the signal transporting system by phosphorylating MIS/AMHR I (28,29). There have been prior attempts to use MIS/AMH as a diagnostic tool for sexual division disorder, to estimate the ovarian reserve and for the diagnosis and prognosis of MIS/AMH-secreting sex cord tumors (11-13). Furthermore, studies have investigated the MIS/AMH receptor and MIS/AMH receptor-presenting tumors, and the potential of MIS/AMH as a biological modulator for clinical medicine (15-22). Song *et al* (30) compared the differences in MIS/AMHR II mRNA expression among patients with ovarian cancer and determined that non-epithelial tumors exhibited increased expression of MIS/AMHR II compared with epithelial tumors. However, no significant difference was observed in mRNA expression levels among benign, borderline and malignant tumors. In cervical tissues, MIS/AMHR II was indicated to be present in healthy cervical and cervical carcinoma tissues. The expression levels of MIS/AMHR II protein and mRNA expression were not significantly different according to cell type or differentiation in cervical cancer (31). In the present study, increased expression of MIS/AMHR II with disease advancement was demonstrated. This may be due to the fact that the endometrial changes during the menstrual cycle result from proliferation of endometrial glandular cells (32), not histologically hyperplastic change. Bakkum-Gamez *et al* (33) reported that only 28% (39/139) of the healthy endometrium samples expressed MIS/AMHR II. A limitation of the present study was the use of only immunohistochemistry for analysis of

protein expression. By using RT-PCR analysis, Renaud *et al* (24) reported that MIS/AMHR II mRNA is expressed in healthy endometrium and endometrial cancer. However, as confirmed by the present study, no difference regarding menstrual cycle stage was evident.

There is high clinical interest regarding endometrial cancer as it is the 4th most common type of cancer following breast, lung and colorectal cancer (34). It has been reported that in South Korea, the prevalence of endometrial cancer has increased from 1999 to 2010, indicating that the malignancy distribution is becoming more similar to that of Western nations (35). Type I endometrial cancer often antecedes or co-exists with endometrial hyperplasia (3). In the present study, although no difference was observed in MIS/AMHR II expression between the secretory and proliferative phases of the endometrium, the expression level was significantly increased in endometrial hyperplasia and endometrial cancer, compared with healthy endometria ($P < 0.05$). Among the endometrial hyperplasia tissues, **no difference was observed in MIS/AMHR II expression** between the tissues with or without atypia. However, the MIS/AMHR II mRNA expression level was significantly increased in complex endometrial hyperplasia compared with simple endometrial hyperplasia tissues, regardless of atypia ($P < 0.05$). In South Korea, the frequency of complex endometrial hyperplasia is 9.5-43.9% and is 5.0-8.7% for endometrial hyperplasia with atypia, which is a relatively low prevalence (36). As indicated in Figs. 2 and 3, the MIS/AMHR II expression was highest and strongest in endometrial cancer. However, the frequency of MIS/AMHR II protein expression in tissues with complex hyperplasia and **atypia was not significantly different** compared with endometrial cancer ($P > 0.05$). As Kurman *et al* (37) reported, 29% of complex endometrial hyperplasia with atypia cases advance to endometrial cancer. Therefore, it may be inferred that the protein expression of MIS/AMHR II is associated with histological complexity in endometrial hyperplasia.

Wang *et al* (38) reported that MIS/AMHR II protein expression is increased in mitotic cells. In addition, increased histological complexity and hyperplastic status has been indicated to result in an increased proportion of cells in mitosis and has been hypothesized to be associated with increased MIS/AMHR II mRNA and protein expression. Therefore, high MIS/AMHR II expression in hyperplasia tissue may be a risk factor of endometrial cancer. As there was no significant difference of MIS/AMHR II expression in terms of atypia among endometrial hyperplasia tissues, MIS/AMHR II expression may reflect histological complexity more than atypia status; therefore, collecting data of MIS/AMHR II expression level in each disease status will be beneficial for follow-up care of the patients with endometrial hyperplasia. This may help to achieve patient-specific treatment. Song *et al* (31) reported that healthy uterine cervical cells and cervical cancer cells express MIS/AMHR II protein and mRNA and that MIS/AMH has an anti-proliferative effect *in vitro* executed via the MIS/AMH receptor. Also in endometrial cancer, as it expresses MIS/AMHR II, investigation of a potential receptor-mediated anti-oncogenic effect of MIS/AMH is required.

In conclusion, the present study demonstrated that there was no change in MIS/AMHR II expression with menstrual cycle stage in healthy endometria. However, MIS/AMHR II

expression significantly increased with progression of disease from simple endometrial hyperplasia to endometrial cancer. This suggests that increased MIS/AMHR II mRNA and protein expression levels in the endometrium are associated with endometrial hyperplastic disease advancement. The present study suggested that MIS/AMH may serve as an inhibitor of MIS/AMH-mediated cell growth in endometrial hyperplasia and endometrial cancer. It would be beneficial in future studies to examine the immune-targeting of MIS/AMHR II-expressing endometrial hyperplasia and endometrial cancer *in vivo*, in addition to developing MIS/AMH as a biological treatment for MIS/AMH receptor-expressing endometrial tumors.

Acknowledgements

The authors would like to thank Mr Sang Ho Park (Clinical Research Laboratory, The Uijeongbu St. Mary's Hospital, The Catholic University of Korea, Uijeongbu, Gyeonggi, Korea) for his counseling experimental method and statistical analysis.

Funding

No funding was received.

Availability of data and materials

The datasets used and/or analyzed during the current study are available from the corresponding author on reasonable request.

Authors' contributions

YOK, MKL and YJC collected the endometrial tissues following sampling and analyzed the patient data regarding endometrial disease. ICJ and MRK were involved in the design of this study, drafting and revising this manuscript. SMK analyzed and interpreted the patient data and was a major contributor in writing the manuscript. JHK contributed to conception, design, acquisition and interpretation of data, revision and corresponding. All authors read and approved the final manuscript.

Ethics approval and consent to participate

The present study was approved by the Institutional Review Board-Human Research Committee at Seoul St. Mary's Hospital (Seoul, South Korea; approval nos. KC14SISI0546 and KC11TISI0491). Written informed consent was obtained from all patients prior to enrolment in the present study. No patient identifying information is included in this manuscript.

Patient consent for publication

Written informed consent was obtained from all patients prior to enrolment in the present study. No patient identifying information is included in this manuscript.

Competing interests

The authors declare that there is no competing interests.

References

- Ellenson L: Precursor lesions of endometrial carcinoma. Springer, New York, 2011.
- Trimble CL, Kauderer J, Zaino R, Silverberg S, Lim PC, Burke JJ II, Alberts D and Curtin J: Concurrent endometrial carcinoma in women with a biopsy diagnosis of atypical endometrial hyperplasia: A Gynecologic Oncology Group study. *Cancer* 106: 812-819, 2006.
- Bokhman JV: Two pathogenetic types of endometrial carcinoma. *Gynecol Oncol* 15: 10-17, 1983.
- Felix AS, Weissfeld JL, Stone RA, Bowser R, Chivukula M, Edwards RP and Linkov F: Factors associated with Type I and Type II endometrial cancer. *Cancer Causes Control* 21: 1851-1856, 2010.
- Dong P, Kaneuchi M, Konno Y, Watari H, Sudo S and Sakuragi N: Emerging therapeutic biomarkers in endometrial cancer. *Biomed Res Int* 2013: 130362, 2013.
- Suri V and Arora A: Management of endometrial cancer: A review. *Rev Recent Clin Trials* 10: 309-316, 2015.
- Josso N: Professor Alfred Jost: The builder of modern sex differentiation. *Sex Dev* 2: 55-63, 2008.
- Rey R, Lukas-Croisier C, Lasala C and Bedecarras P: AMH/MIS: What we know already about the gene, the protein and its regulation. *Mol Cell Endocrinol* 211: 21-31, 2003.
- He WW, Gustafson ML, Hirobe S and Donahoe PK: Developmental expression of four novel serine/threonine kinase receptors homologous to the activin/transforming growth factor-beta type II receptor family. *Dev Dyn* 196: 133-142, 1993.
- MacLaughlin DT, Teixeira J and Donahoe PK: Perspective: Reproductive tract development-new discoveries and future directions. *Endocrinology* 142: 2167-2172, 2001.
- Hudson PL, Douglas I, Donahoe PK, Cate RL, Epstein J, Pepinsky RB and MacLaughlin DT: An immunoassay to detect human müllerian inhibiting substance in males and females during normal development. *J Clin Endocrinol Metab* 70: 16-22, 1990.
- Lee MM, Donahoe PK, Hasegawa T, Silverman B, Crist GB, Best S, Hasegawa Y, Noto RA, Schoenfeld D and MacLaughlin DT: Müllerian inhibiting substance in humans: Normal levels from infancy to adulthood. *J Clin Endocrinol Metab* 81: 571-576, 1996.
- Fanchin R, Taieb J, Lozano DH, Ducot B, Frydman R and Bouyer J: High reproducibility of serum anti-Müllerian hormone measurements suggests a multi-staged follicular secretion and strengthens its role in the assessment of ovarian follicular status. *Hum Reprod* 20: 923-927, 2005.
- Chang HL, Pahlavan N, Halpern EF and MacLaughlin DT: Serum Müllerian inhibiting substance/anti-Müllerian hormone levels in patients with adult granulosa cell tumors directly correlate with aggregate tumor mass as determined by pathology or radiology. *Gynecol Oncol* 114: 57-60, 2009.
- Fuller AF Jr, Crane IM, Budzik GP and Donahoe PK: Müllerian inhibiting substance reduction of colony growth of human gynecologic cancers in a stem cell assay. *Gynecol Oncol* 22: 135-148, 1985.
- Chin TW, Parry RL and Donahoe PK: Human müllerian inhibiting substance inhibits tumor growth in vitro and in vivo. *Cancer Res* 51: 2101-2106, 1991.
- Masiakos PT, MacLaughlin DT, Maheswaran S, Teixeira J, Fuller AF Jr, Shah PC, Kehas DJ, Kenneally MK, Dombkowski DM, Ha TU, *et al*: Human ovarian cancer, cell lines, and primary ascites cells express the human Müllerian inhibiting substance (MIS) type II receptor, bind, and are responsive to MIS. *Clin Cancer Res* 5: 3488-3499, 1999.
- Stephen AE, Pearsall LA, Christian BP, Donahoe PK, Vacanti JP and MacLaughlin DT: Highly purified müllerian inhibiting substance inhibits human ovarian cancer in vivo. *Clin Cancer Res* 8: 2640-2646, 2002.
- Pieretti-Vanmarcke R, Donahoe PK, Szotek P, Manganaro T, Lorenzen MK, Lorenzen J, Connolly DC, Halpern EF and MacLaughlin DT: Recombinant human Müllerian inhibiting substance inhibits long-term growth of MIS type II receptor-directed transgenic mouse ovarian cancers in vivo. *Clin Cancer Res* 12: 1593-1598, 2006.
- Ha TU, Segev DL, Barbie D, Masiakos PT, Tran TT, Dombkowski D, Glander M, Clarke TR, Lorenzo HK, Donahoe PK and Maheswaran S: Müllerian inhibiting substance inhibits ovarian cell growth through an Rb-independent mechanism. *J Biol Chem* 275: 37101-37109, 2000.
- Wang JJ, Roffler SR, Chou HH, Yin FY and Yin CS: Characterization of müllerian inhibiting substance binding on cervical carcinoma cells demonstrated by immunocytochemistry. *Tissue Cell* 26: 467-476, 1994.
- Barbie TU, Barbie DA, MacLaughlin DT, Maheswaran S and Donahoe PK: Müllerian inhibiting substance inhibits cervical cancer cell growth via a pathway involving p130 and p107. *Proc Natl Acad Sci USA* 100: 15601-15606, 2003.
- Segev DL, Ha TU, Tran TT, Kenneally M, Harkin P, Jung M, MacLaughlin DT, Donahoe PK and Maheswaran S: Müllerian inhibiting substance inhibits breast cancer cell growth through an NFkappa B-mediated pathway. *J Biol Chem* 275: 28371-28379, 2000.
- Renaud EJ, MacLaughlin DT, Oliva E, Rueda BR and Donahoe PK: Endometrial cancer is a receptor-mediated target for Müllerian inhibiting substance. *Proc Natl Acad Sci USA* 102: 111-116, 2005.
- Chung YJ, Kim HJ, Park SH, Yoon JH, Kim MR, Nam SW, MacLaughlin DT, Donahoe PK and Kim JH: Transcriptome analysis reveals that Müllerian inhibiting substance regulates signaling pathways that contribute to endometrial carcinogenesis. *Int J Oncol* 46: 2039-2046, 2015.
- Livak KJ and Schmittgen TD: Analysis of relative gene expression data using real-time quantitative PCR and the 2(-Delta Delta C(T)) method. *Methods* 25: 402-408, 2001.
- Akhurst RJ, FitzPatrick DR, Gatherer D, Lehnert SA and Millan FA: Transforming growth factor betas in mammalian embryogenesis. *Prog Growth Factor Res* 2: 153-168, 1990.
- Baarends WM, van Helmond MJ, Post M, van der Schoot PJ, Hoogerbrugge JW, de Winter JP, Uilenbroek JT, Karels B, Wilming LG, Meijers JH, *et al*: A novel member of the transmembrane serine/threonine kinase receptor family is specifically expressed in the gonads and in mesenchymal cells adjacent to the müllerian duct. *Development* 120: 189-197, 1994.
- di Clemente N, Wilson C, Faure E, Boussin L, Carmillo P, Tizard R, Picard JY, Vigier B, Josso N and Cate R: Cloning, expression, and alternative splicing of the receptor for anti-Müllerian hormone. *Mol Endocrinol* 8: 1006-1020, 1994.
- Song JY, Chen KY, Kim SY, Kim MR, Ryu KS, Cha JH, Kang CS, MacLaughlin DT and Kim JH: The expression of Müllerian inhibiting substance/anti-Müllerian hormone type II receptor protein and mRNA in benign, borderline and malignant ovarian neoplasia. *Int J Oncol* 34: 1583-1591, 2009.
- Song JY, Jo HH, Kim MR, Lew YO, Ryu KS, Cha JH, Kang CS, Donahoe PK, MacLaughlin DT and Kim JH: Expression of Müllerian inhibiting substance type II receptor and antiproliferative effects of MIS on human cervical cancer. *Int J Oncol* 40: 2013-2021, 2012.
- Ferenczy A, Bertrand G and Gelfand MM: Proliferation kinetics of human endometrium during the normal menstrual cycle. *Am J Obstet Gynecol* 133: 859-867, 1979.
- Bakkum-Gamez JN, Aletti G, Lewis KA, Keeney GL, Thomas BM, Navarro-Teulon I and Cliby WA: Müllerian inhibiting substance type II receptor (MISIIR): A novel, tissue-specific target expressed by gynecologic cancers. *Gynecol Oncol* 108: 141-148, 2008.
- Nicolajje KA, Ezendam NP, Vos MC, Boll D, Pijnenborg JM, Kruitwagen RF, Lybeert ML and van de Poll-Franse LV: Follow-up practice in endometrial cancer and the association with patient and hospital characteristics: A study from the population-based PROFILES registry. *Gynecol Oncol* 129: 324-331, 2013.
- Lim MC, Moon EK, Shin A, Jung KW, Won YJ, Seo SS, Kang S, Kim JW, Kim JY and Park SY: Incidence of cervical, endometrial, and ovarian cancer in Korea, 1999-2010. *J Gynecol Oncol* 24: 298-302, 2013.
- Ko JK, Choi H, Kang WS, Kim MH, Park KH, Lee CM, Cho YK, Kim BL and Lee HK: Clinical and pathologic study of abnormal uterine bleeding in premenopausal Women-to evaluate the prognostic variables of endometrial hyperplasia. *Korean J Obstet Gynecol* 47: 139-145, 2004.
- Kurman RJ, Kaminski PF and Norris HJ: The behavior of endometrial hyperplasia. A long-term study of 'untreated' hyperplasia in 170 patients. *Cancer* 56: 403-412, 1985.
- Wang J, Dicken C, Lustbader JW and Tortoriello DV: Evidence for a Müllerian-inhibiting substance autocrine/paracrine system in adult human endometrium. *Fertil Steril* 91: 1195-1203, 2009.