



Case Report

Nonconvulsive status epilepticus secondary to acute porphyria crisis[☆]

Sara Dawit^a, Shubhang K. Bhatt^b, Devika M. Das^b, Andrew R. Pines^b, Harn J. Shiue^c, Brent P. Goodman^a, Joseph F. Drazkowski^d, Joseph I. Sirven^{d,*}

^a Department of Neurology, Mayo Clinic, 13400 East Shea Boulevard, Scottsdale, AZ 85259, USA

^b Mayo Clinic School of Medicine, Mayo Clinic, 13400 East Shea Boulevard, Scottsdale, AZ 85259, USA

^c Department of Pharmacy, Mayo Clinic, 5777 East Mayo Boulevard, Phoenix, AZ 85054, USA

^d Department of Neurology, Mayo Clinic, 5777 East Mayo Boulevard, Phoenix, AZ 85054, USA

ARTICLE INFO

Article history:

Received 10 September 2018

Received in revised form 30 October 2018

Accepted 20 November 2018

Available online 28 November 2018

Keywords:

Variagate porphyria

Non-convulsive status epilepticus

Electroencephalogram

Anticonvulsant medication

Acute porphyria crisis

ABSTRACT

Both variegate and acute intermittent porphyria can manifest with various neurological symptoms. Although acute symptomatic seizures have been previously described, they are typically tonic-clonic and focal impaired awareness seizures. Convulsive status epilepticus and epilepsy partialis continua are rare and have been described on a case report basis. To our knowledge, there are no previously reported cases describing non-convulsive status epilepticus (NCSE) with electroencephalogram (EEG) documentation in the setting of acute porphyria crisis. We report a unique presentation of NCSE, which resolved after administering levetiracetam in a patient with variegate porphyria, without a known seizure disorder.

© 2018 The Authors. Published by Elsevier Inc. This is an open access article under the CC BY-NC-ND license (<http://creativecommons.org/licenses/by-nc-nd/4.0/>).

1. Introduction

Variagate porphyria (VP) is an autosomal dominant disorder wherein heme biosynthesis is disrupted due to deficiency of protoporphyrinogen oxidase (PPOX) enzyme. The clinical presentation for VP is similar to acute intermittent porphyria (AIP), which typically presents with altered mentation and unexplained abdominal pain, chest, and back pain.

Neurological complications include peripheral neuropathy, acute encephalopathy, and acute symptomatic seizures. Seizures can affect 10–20% of patients with acute porphyria; the most commonly reported are tonic-clonic and focal seizures with impaired awareness [1–4]. Although rare, convulsive status epilepticus and epilepsy partialis continua have been described in case reports [1,4]. There are no cases previously describing non-convulsive status epilepticus (NCSE) with electroencephalogram (EEG) documentation to our knowledge. We report a unique presentation of NCSE, which resolved after administration of levetiracetam in a patient with nearly 50 years of VP and without a known, prior seizure disorder who presented in an acute porphyria crisis.

2. Methods

We reviewed a case of nonconvulsive status epilepticus secondary to variegate porphyria crisis presenting to a tertiary referral medical center

in the Southwest United States. A literature review was performed using PubMed.

3. Results

A 71-year-old woman, with a 50 year history of hereditary variegate porphyria and a history of end-stage renal disease on hemodialysis and coronary artery disease, presented to the emergency department with generalized weakness, lethargy, and confusion.

Upon admission, she was combative, moving all of her extremities, fluent speech, but intermittently confused. Infectious work-up was unrevealing. A chest radiograph, urine toxicology screen, urinalysis, comprehensive blood count, ammonia, and a head computed tomography (CT) were within normal limits. Her comprehensive metabolic profile showed evidence of her known chronic kidney disease. Her cerebrospinal fluid (CSF) analysis was within normal range excluding any infectious causative agent in the central nervous system. Her urine and blood cultures, HBsAg, thyroid stimulating hormone (TSH) and thiamine were unremarkable. Her urine porphobilinogen was elevated, 4.4 $\mu\text{mol/L}$ (reference value is $\leq 1.3 \mu\text{mol/L}$), which substantiated her acute porphyria crisis presentation. Interestingly, she had three previous admissions with no prior EEGs for unexplained encephalopathy, which were attributed to her acute porphyria crisis.

The following day her neurologic exam changed and she became stuporous, responding only to noxious stimuli. A neurology consultation was placed. Her physical examination demonstrated no spontaneous movement of her extremities as well as a lack of deep tendon reflexes.

[☆] Conflict of Interest: None of the authors have any conflict of interest to declare.

* Corresponding author.

E-mail address: sirven.joseph@mayo.edu (J.I. Sirven).

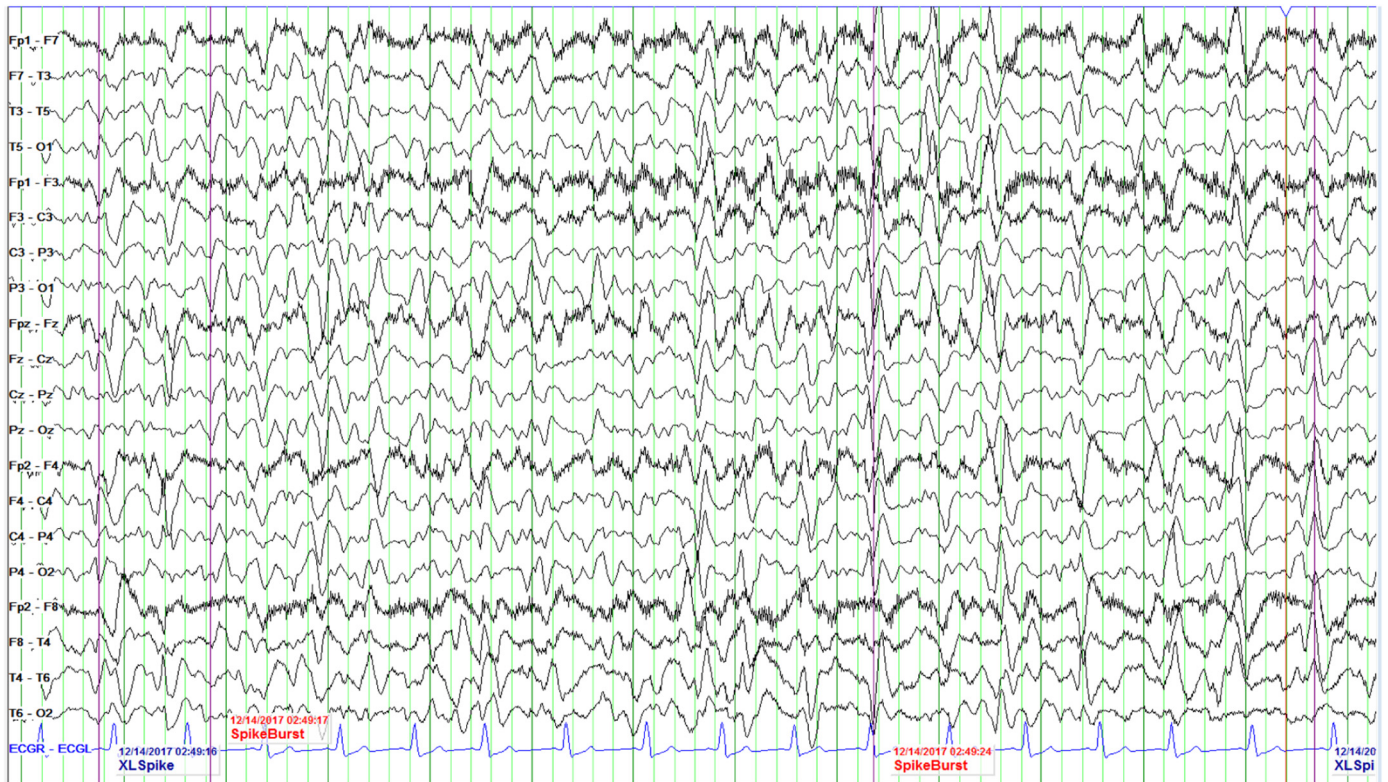

Fig. 1. Trend EEG revealed generalized 5–6 Hz theta with admixed 2–3 Hz delta frequency slowing. There was evidence of multifocal, independently occurring, sharp waves in the bilateral cerebral hemispheres occurring most prominently with stimulation. With stimulation, discharges occur with 1–2 Hz periodicity. Additionally, frequent generalized triphasic waves were seen. Triphasic waves were seen in addition to generalized slowing of the background activity. These collective findings in the setting of underlying diffuse cerebral dysfunction suggested the potential for seizures to arise.

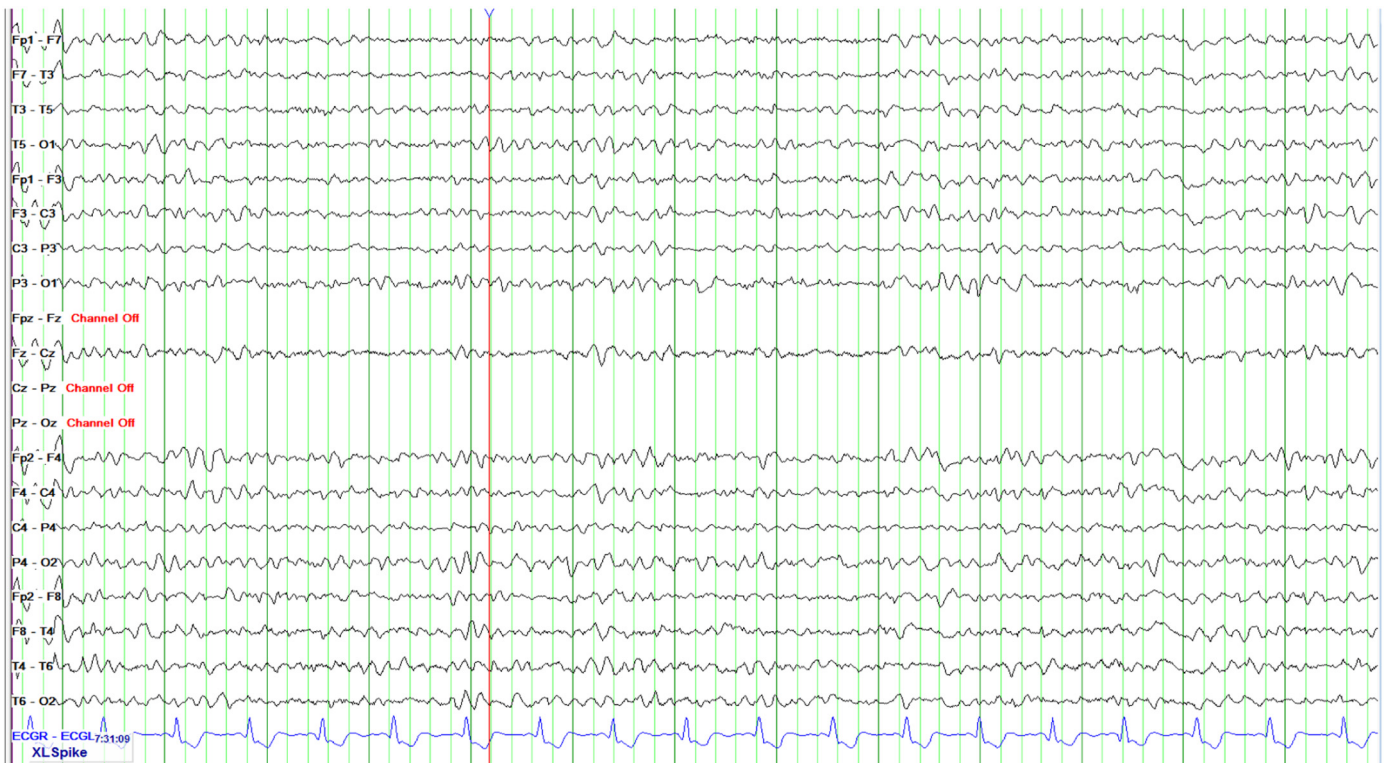

Fig. 2. Trend EEG shows dramatic improvement after levetiracetam administration.

She was nonverbal, and did not respond to verbal cues or follow commands. Her Glasgow Coma Scale was 9 (E3V2M4). An EEG was ordered which showed generalized triphasic waves and independent multifocal sharp waves, concerning for nonconvulsive status epilepticus (Fig. 1).

Her EEG pattern improved significantly upon a 2-gram loading dose of intravenous levetiracetam. She continued to receive maintenance levetiracetam doses and her mental status continued to improve (Fig. 2). Brain magnetic resonance imaging (MRI) was unremarkable (Fig. 3). Hemin was administered in the treatment of her acute porphyria. Ultimately, she was discharged home following return to her baseline.

Two months later, she followed up in epilepsy clinic with plans to repeat her EEG and continue levetiracetam in the interim. Her mental status and neurological exam were within normal limits.

4. Discussion

Porphyrias are a group of rare metabolic disorders caused by disruption in the heme synthesis pathway. There are eight enzymes involved in this pathway and VP is a type of porphyria caused by mutation in the PPOX gene. The estimated incidence of VP is 1 in 100,000 individuals in the general population of European decent [5].

Neurologic complications include peripheral neuropathy, acute encephalopathy, and acute symptomatic seizures. Although the data on lifetime prevalence of status epilepticus in VP patients is unknown, seven cases of status epilepticus associated with porphyria disorders have been reported [4]. Our patient presented with non-specific symptoms of porphyria crisis upon admission, but later had a distinct deterioration of her mental status, raising the clinical concern for non-convulsive status epilepticus.

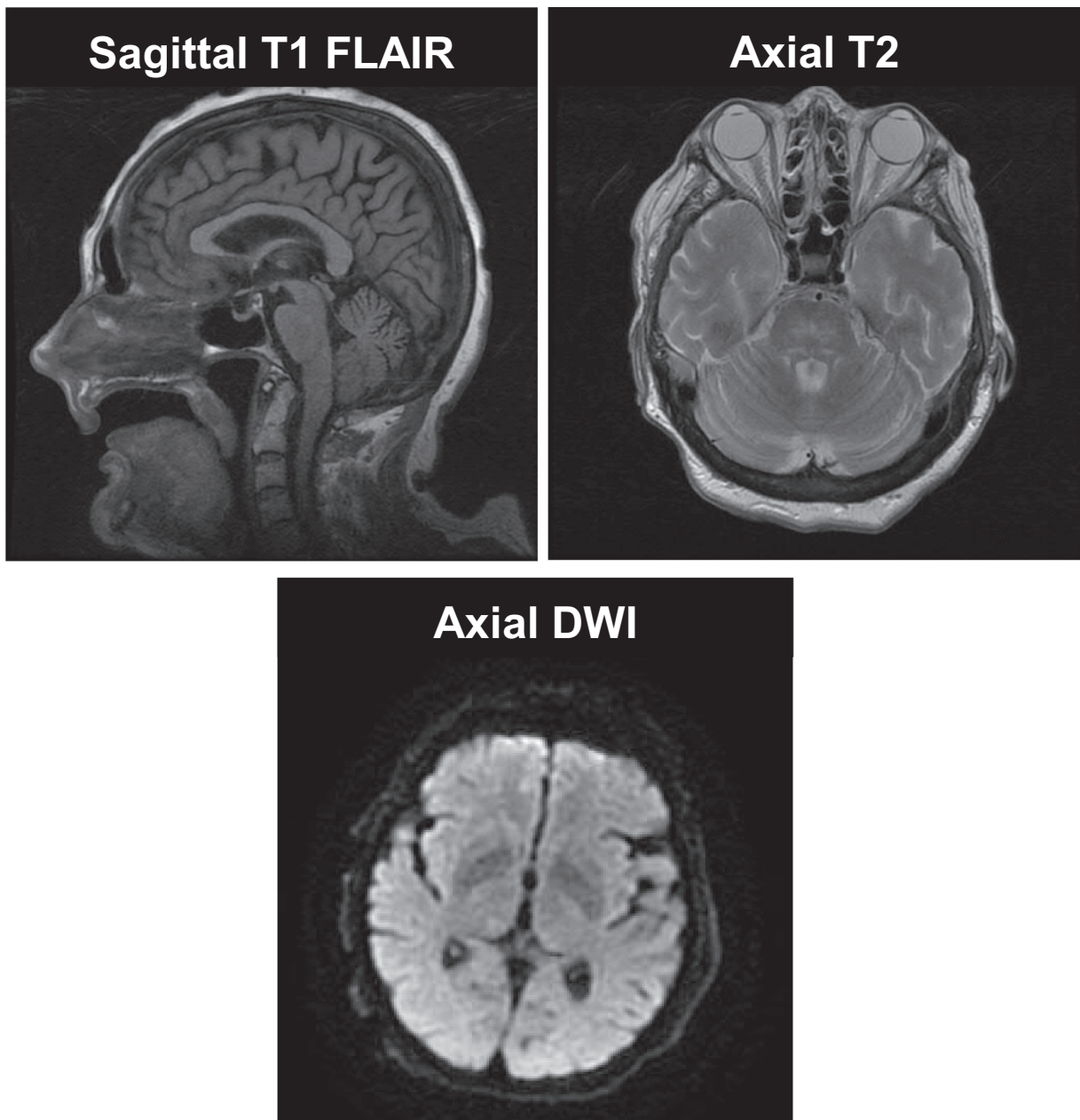


Fig. 3. Representative images of patient's brain MRI. There was no evidence of hemorrhage, infarct, or other acute intracranial abnormalities.

Table 1
Assessment of antiepileptic drug porphyrogenicity.

Non-porphyrinogenic antiepileptic drugs	Porphyrinogenic antiepileptic drugs
Clobazam	Carbamazepine
Clonazepam	Ethosuximide
Gabapentin	Felbamate
Lacosamide	Oxcarbazepine
Levetiracetam	Phenobarbital
	Phenytoin
	Lamotrigine
	Clonazepam
	Primidone
	Tiagabine
	Topiramate
	Valproate

Note: Rufinamide, eslicarbazepine, and perampanel are of uncertain porphyrogenicity. These agents are not yet classified and possibly porphyrogenic [1].

Her EEG revealed generalized triphasic and independent multifocal sharp waves which improved dramatically after levetiracetam treatment, suggesting NCSE as the culprit. She underwent initial and repeat serological and neurodiagnostic studies to rule out seizures and further evaluate her acute encephalopathy. Fortunately, her clinical status continued to improve with maintenance levetiracetam as well as administration of hemin in the treatment of her acute porphyria crisis.

Identification and treatment of seizures in patients with porphyrias can be challenging. Treatment of patients with porphyrias can be difficult due to the porphyrogenicity of many anti-seizure medications (Table 1). First line treatment options for seizures and status epilepticus include porphyria precipitating anti-seizure drugs such as phenytoin, valproate, benzodiazepines, and lacosamide [1,6,7]. These anti-seizure drugs are metabolized by heme containing cytochrome P450 enzymes in the liver, thereby leading to increased liver heme biosynthesis and deposition of porphyrin complexes [5,8]. Therefore, if an inappropriate anti-seizure medication is selected, a patient's acute porphyria crisis can be exacerbated. This is an important clinical distinction in treating patients with VP who develop epilepsy and present with drug-resistant seizures while in hospital.

Levetiracetam was effective in the treatment of this patient's NCSE. It has high oral bioavailability and reaches peak plasma concentration in approximately 1 h. More importantly, levetiracetam does not induce hepatic cytochrome P450 enzymes and, therefore, does not increase heme synthesis in VP patients. Approximately 66% of the drug is excreted unchanged in the urine and the remaining metabolites are excreted independent of hepatic enzymes [9].

There have been various mechanisms described; however, the underlying pathophysiology of seizures in patients with porphyria has not been fully elucidated. In one study, Tracy and colleagues report that patients with porphyria can also present with syndrome of inappropriate antidiuretic hormone (SIADH) which can be a possible contributing factor in seizures [11]. Solinas and colleagues report the trigger of these seizures is probably related to metabolic imbalance

and to the intrinsic epileptogenic role of some porphyrins [10]. Additional studies have reported that neural damage can follow a porphyric attack which may predispose to brain lesions that may be epileptogenic [10,11]. Furthermore, porphyria attacks are also exacerbated by environmental factors such as alcohol, drugs, hormonal, and dietary changes. These factors amplify the deficiency of PPOX enzyme which leads to deposition of porphyrin complexes [5]. We speculate that there could also be a role for protoporphyrinogen IX to have an epileptogenic role given its dysfunction in the role of VP.

5. Conclusions

This case highlights the importance of consideration of nonconvulsive status epilepticus in patients with known variegate porphyria and acute encephalopathy. Additionally, 10%–20% of patients with acute intermittent porphyria in relapse have been noted to manifest acute symptomatic seizures which warrant added caution while treating patients with anti-seizure medication in porphyria crisis [1]. Recognition of seizures is critical so that appropriate anti-seizure medications are selected so as to avoid exacerbation of porphyria. Levetiracetam could be a preferred choice of treatment for NCSE in patients with variegate porphyria. Hemin treatment should be started urgently to treat porphyria crisis and help reduce porphyrin complex deposition.

Acknowledgments

We thank Barbara J. Weisser for her assistance with manuscript formatting, and EEG technicians for preparation of the electroencephalogram image.

References

- [1] Balestrini S, Hart Y, Thunell S, Sisodiya SM. Safe use of perampanel in a carrier of variegate porphyria. *Pract Neurol* 2016;16(3):217–9. <https://doi.org/10.1136/practneurol-2015-001305>.
- [2] Bissell DM, Wang B. Acute hepatic porphyria. *J Clin Transl Hepatol* 2015;3(1):17–26. <https://doi.org/10.14218/JCTH.2014.00039>.
- [3] Bylesjo I, Forsgren L, Lithner F, Boman K. Epidemiology and clinical characteristics of seizures in patients with acute intermittent porphyria. *Epilepsia* 1996;37(3):230–5.
- [4] Tran TP, Leduc K, Savard M, Dupre N, Rivest D, Nguyen DK. Acute porphyria presenting as epilepsy partialis continua. *Case Rep Neurol* 2013;5(2):116–24. <https://doi.org/10.1159/000353279>.
- [5] American Porphyria Foundation. Variegate porphyria. <http://www.porphyrifoundation.com/about-porphyrin/types-of-porphyrin/VP/>; 2017, Accessed date: 24 June 2018.
- [6] Bonkowsky HL, Sinclair PR, Emery S, Sinclair JF. Seizure management in acute hepatic porphyria: risks of valproate and clonazepam. *Neurology* 1980;30(6):588–92.
- [7] Gaspard N, Jirsch J, Hirsch LJ. Nonconvulsive status epilepticus [UpToDate]; 2018.
- [8] Paul F, Meencke HJ. Levetiracetam in focal epilepsy and hepatic porphyria: a case report. *Epilepsia* 2004;45(5):559–60. <https://doi.org/10.1111/j.0013-9580.2004.00204.x>.
- [9] Patsalos PN. Pharmacokinetic profile of levetiracetam: toward ideal characteristics. *Pharmacol Ther* 2000;85(2):77–85.
- [10] Solinas C, Vajda FJ. Epilepsy and porphyria: new perspectives. *J Clin Neurosci* 2004; 11(4):356–61. <https://doi.org/10.1016/j.jocn.2003.08.007>.
- [11] Tracy JA, Dyck PJ. Porphyria and its neurologic manifestations. *Handb Clin Neurol* 2014;120:839–49. <https://doi.org/10.1016/B978-0-7020-4087-0.00056-5>.