

# Intralesional Injection of the Measles–Mumps–Rubella Vaccine into Resistant Palmoplantar Warts: A Randomized Controlled Trial

Mohammad Sadegh Rezaei<sup>1</sup>, MD;  
Hiva Ghasempouri<sup>2</sup>, MD; Ozra Asqary  
Marzidareh<sup>2</sup>, MD; Jamshid Yazdani  
Cherati<sup>3</sup>, MD; Ghasem Rahmatpour  
Rokni<sup>2,4</sup>, MD

<sup>1</sup>Pediatric Infectious Diseases  
Superspecialist, Infectious Diseases  
Research Center with focus on  
Nosocomial Infections, Mazandaran  
University of Medical Sciences, Sari, Iran;

<sup>2</sup>General physician, Mazandaran  
University of Medical Sciences, Sari,  
Iran;

<sup>3</sup>Epidemiologist, Department of  
Biostatistics, Health Sciences Research  
Center, Mazandaran University of  
Medical Sciences, Sari, Iran;

<sup>4</sup>Dermatologist, Clinical Research  
Development Unit of Bou-Ali Sina  
Hospital, Mazandaran University of  
Medical Sciences, Sari, Iran

## Correspondence:

Ghasem Rahmatpour Rokni, MD;  
BouAli Sina Hospital,  
Pasdaran Boulevard, Sari, Iran  
Tel: +98 912 5443956  
Fax: +98 11 33044306  
Email: dr.rokni@yahoo.com  
Received: 24 May 2017  
Revised: 20 August 2017  
Accepted: 24 September 2017

## What's Known

- Many destructive and immunotherapeutic treatment options are in use for warts, but no specific treatment has yet been fully effective.
- Intralesional immunotherapy with the measles–mumps–rubella (MMR) vaccine may confer a desirable therapeutic response and can be used as an effective and safe treatment option for palmoplantar warts, particularly persistent ones.

## What's New

- This is the first study to characterize warts as resistant to therapy in intralesional immunotherapy with the MMR vaccine.
- We defined resistant-to-therapy warts as those that persisted for more than 2 years despite the application of at least 2 therapeutic options.

## Abstract

**Background:** Common resistant-to-therapy warts pose a challenge to both clinicians and patients. Among many destructive and immunotherapeutic options, no single, fully effective treatment has been suggested yet. Many investigations, including those using intralesional antigen administrations, have demonstrated that cellular immunity plays a major role in the clearance of human papilloma virus (HPV) infection. The aim of the present study was to evaluate the effects of the intralesional injection of the measles–mumps–rubella (MMR) vaccine into resistant-to- treatment palmoplantar warts and its complications.

**Methods:** In this single-blind, randomized, controlled clinical trial, 60 cases with resistant-to-therapy palmoplantar warts referring to the Dermatology Clinic of Bou-Ali Sina Hospital of Sari between June 2015 and 2016 were randomly assigned to 2 equal groups: the MMR Group received intralesional MMR and the Placebo Group was given saline injection. The injections were administered at 2-week intervals until complete clearance was achieved or for a maximum of 5 injections (<5 injections at 2-week intervals). The study protocol was registered in the Iranian Registry of Randomised Clinical Trials (ID: IRCT2016101027636N3), and the statistical analyses were performed using SPSS, version 17.0. The  $\chi^2$  test and the F-test were used as appropriate, and a P value less than 0.05 was considered statistically significant.

**Results:** Complete clearance was observed in 65.2% (14/23) of the patients presenting with resistant-to-therapy palmoplantar warts in the MMR Group and 23.85% (5/21) in the Placebo Group (P=0.021). Recurrence was not observed in any of the completely cured patients at 6 months' follow-up.

**Conclusion:** Intralesional immunotherapy with the MMR vaccine may result in a desirable therapeutic response and can be used as an effective and safe treatment option for palmoplantar warts, particularly persistent ones.

**Trial Registration Number:** IRCT2016101027636N3

Please cite this article as: Rezaei MS, Ghasempouri H, Asqary Marzidareh O, Yazdani Cherati J, Rahmatpour Rokni Gh. Intralesional Injection of the Measles–Mumps–Rubella Vaccine into Resistant Palmoplantar Warts: A Randomized Controlled Trial. *Iran J Med Sci*. 2019;44(1):10-17.

**Keywords** • Injections • Intralesional • Measles–mumps–rubella vaccine • Warts

## Introduction

Human papilloma viruses (HPVs) are a large family of small,

nonenveloped, double-stranded DNA viruses that are the cause of benign epithelial proliferations or warts.<sup>1</sup> The most common clinical manifestations of these viruses are warts (verrucae). more than 180 individual types of HPVs have been sequenced and all infect epithelial cells, usually with a preference for either cutaneous or mucosal surfaces.<sup>2</sup>

The most common warts on hands and feet are caused by HPV types 1, 2, 4, 27, and 57.<sup>3</sup> Warts have various forms including common (verruca vulgaris), plane or flat, myrmecia, plantar, coalesced mosaic, filiform, periungual, anogenital (venereal or condyloma acuminata), oral, and respiratory papillomas.<sup>4</sup> Palmar and plantar warts are lesions described as rough papules on the palms, soles, and lateral sides of the hands and feet with slight central depression. Warts are self-limited in nature and can disappear after a few months. they can, however, stay for years and even recur.<sup>5-8</sup>

For all the destructive and immunotherapeutic treatment options that have been proposed for common warts, no specific treatment has yet been fully effective.<sup>4</sup> Many factors such as side effects, costs, pain related to treatment, patients' age, compliance, and immunity status, and wart location, size, form, and response to previous treatments can affect the choice of treatment.<sup>9</sup> Local immunotherapy consists of contact sensitizers such as diphencyprone, squaric acid dibutyl ester, intralesional injection of interferon, 5-fluorouracil, imiquimod, Bacillus Calmette–Guérin therapy, and intralesional injection of mumps, *Candida*, or *Trichophyton* antigen.<sup>4</sup>

Progression of HPV infection in patients with compromised cellular immunity has been shown in some studies, whereas there has been no indication of increased prevalence of warts in patients with impaired humoral immunity, which displays the main role of cell-mediated immune reactions in HPV-infected tissues.<sup>5</sup>

In a competent body immune system, T Helper 1 cells (CD4+) secrete many different types of cytokines, the most important of which are interferon gamma, interleukin-2 (IL-2), and IL-12. IL-2 stimulates the maturation of the killer T cell and enhances the cytotoxicity of natural killer cells. The critical function of the killer T cell is cytotoxicity, which means recognizing and destroying cells infected with viruses, but they also defend against intracellular bacteria and certain types of cancers.<sup>10</sup> Some observations have demonstrated that a CD4-dominant immune reaction in an HPV-infected tissue is associated with a high chance of clearing the HPV infection.<sup>11</sup>

One of the strategies involved in the

immunotherapy of warts is inducing delayed (cellular) hypersensitivity reactions at the wart tissue.<sup>12</sup> Previous studies have reported that intralesional injection of *Candida*, *Trichophyton*, and/or mump skin test antigens causes a great elimination rate in patients receiving intralesional antigens, as compared to the placebo group, because these injected antigens can induce a delayed-type hypersensitivity reaction amazingly to both antigen and HPV-infected cells. This reaction increases the probability of recognizing and clearing the wart virus.<sup>5, 13</sup>

Given that immunotherapy seems to be a rather safe way of wart treatment and, in addition, former studies have shown high rates of wart regression, we conducted the present study to evaluate the efficacy of the MMR vaccine injection in the treatment of resistant-to-therapy palmoplantar warts.

To our knowledge, this is the first study to characterize warts as resistant to therapy in intralesional immunotherapy with the MMR vaccine. The aim of the present study was to evaluate the effects of the intralesional injection of the measles–mumps–rubella (MMR) vaccine into resistant-to- treatment palmoplantar warts and its complications.

## Materials and Methods

### Study Design and Populations

In this single-blind, randomized, controlled clinical trial, 60 cases with resistant-to-therapy palmoplantar warts referring to the Dermatology Clinic of Bou-Ali Sina Hospital of Sari, Iran, between June 2015 and June 2016, were enrolled. Resistant-to-therapy warts were defined as warts persisting more than 2 years despite the application of at least 2 therapeutic options. A written informed consent was obtained from all the patients. The study population's baseline characteristics including age and gender; wart number, site, size, and duration of presence; and previous wart therapies were evaluated at the outset of the study and at each follow-up visit.

We defined resistant-to-therapy warts as those persisting for more than two years despite the application of at least two therapeutic options.<sup>13, 14</sup> The inclusion criterion was the presence of resistant-to-therapy palmoplantar warts, defined as warts persisting more than two years despite the application of at least two therapeutic methods or warts unresponsive to treatment, which were diagnosed by the expert dermatologist through history taking and physical examination. The exclusion criteria were comprised of acute febrile illness,

receiving any other treatment for warts in the month preceding the enrolment, past history of asthma, allergic skin disorders such as generalized eczema or urticaria, past history of meningitis or convulsion, pregnancy, lactation, iatrogenic or primary immunosuppression, and age less than 1 year.

Via the simple randomization method with a table of random numbers, the patients were randomly assigned to two groups. The first group comprised 30 patients who received the intralesional MMR vaccine (the MMR Group), and the second group consisted of 30 patients who received intralesional saline (the Placebo Group). All the patients in the MMR Group underwent an immunocompetence test via intradermal injection of 0.1 mL of the MMR vaccine in their forearm on one side. Desired immune response was defined as erythema and induration of at least 5 mm in diameter within 48 to 72 hours. Patients not reactive to the skin test were excluded from the study.

Intradermal injection of the MMR vaccine was administered to the responders, and saline was injected intradermally to the Placebo Group. The dose of saline was 0.3 mL in the Placebo Group, whereas the injection doses in the MMR Group were different according to the severity of their initial immune response in the immunocompetence test. Those with diameters of erythema and induration less than 20 mm, 20 to 40 mm, and more than 40 mm were injected 0.3, 0.2, and 0.1 mL of the MMR vaccine, respectively, into the same single wart or into the largest wart in case of multiple lesions. The injections were administered at 2-week intervals until complete clearance was achieved or for a maximum of 5 injections.<sup>15, 16</sup>

Response to treatment was investigated by the decrease in the wart size and photographic comparison. Complete response was defined as the disappearance of the wart(s) and the return of normal skin markings. Partial response was defined as the regression in the wart size by 50% to 99%, and no response was defined as a 0 to 49% decrease in the wart size. The immediate and late adverse effects of the MMR vaccine, including pain during injection, site edema, ecchymosis, fever, and flu-like symptoms, were evaluated after each treatment session. The subjects were followed up every month up to 6 months to detect any changes.

#### Statistical Analysis

The quantitative variables were expressed as means±standard deviations (SDs) and the qualitative variables were expressed as numbers and percentages. The statistical analyses were

performed using the  $\chi^2$  and the *t*-test with SPSS software, version 17.0. The  $\chi^2$  test and the *F*-test were used as appropriate, and a *P* value less than 0.05 was considered as statistically significant.

#### Ethics

The present study was approved by the Ethics Committee of Mazandaran University of Medical Sciences (#IR.MAZUMS.REC.95.1482), and the research followed the tenets of the Declaration of Helsinki. The patients were free to leave the study at any time. This clinical trial was registered in the Iranian Registry of Randomised Clinical Trials (ID: IRCT2016101027636N3).

## Results

At the beginning of the study, 30 patients were enrolled in each group. Seven patients in the MMR Group and nine patients in the Placebo Group did not complete the treatment course for different reasons such as failure to follow up or side effects (mostly pain related to treatment) (figure 1). Finally, 23 patients in the MMR Group and 21 patients in the Placebo Group were evaluated. The MMR Group consisted of 12 (40%) men and 18 (60%) women, whereas there were 11 (36.7%) males and 19 (63.3%) females in the control group, indicating no significant difference between the 2 groups (*P*=0.11). The mean age of the patients in both groups showed no statistically significant difference (*P*=0.35). Moreover, there were no significant differences between the groups regarding the demographic data (table 1).

The therapeutic response rates in the two groups according to the time elapsed after treatment are shown in table 2. A comparison of these rates showed a statistically non-significant difference between the two groups after the third intralesional MMR injection (*P*=0.512). Complete clearance was observed in 60.86% (14/23) (figures 2 and 3) of the patients presenting with resistant-to-therapy palmoplantar warts in contrast to the Placebo Group (23.85%; 5/21). The results revealed that the MMR Group had 4.6 times more response to treatment than the Placebo Group (regression test analysis). Recurrence was observed in none of the completely cured patients after the 6-month follow-up period. The incidence of side effects during and after injection consisted of mild immediate pain during injection, which occurred in all the patients (100%) and was the most common adverse effect. Other local reactions such as itching (3.4%), erythema (4%), and edema (1.5%) at the site of injection were observed, which were mild and transient.

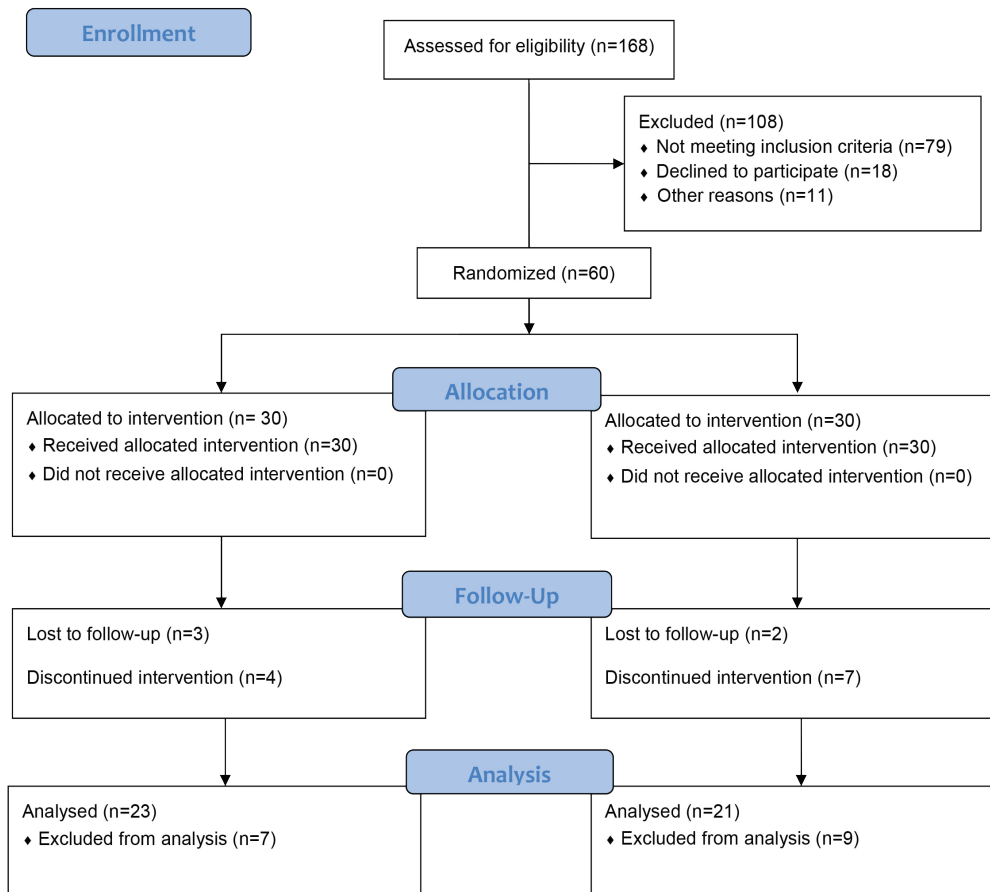


Figure 1: CONSORT diagram shows the flow of patients through each stage of a randomized trial.

Table 1: Demographic characteristics of the study population

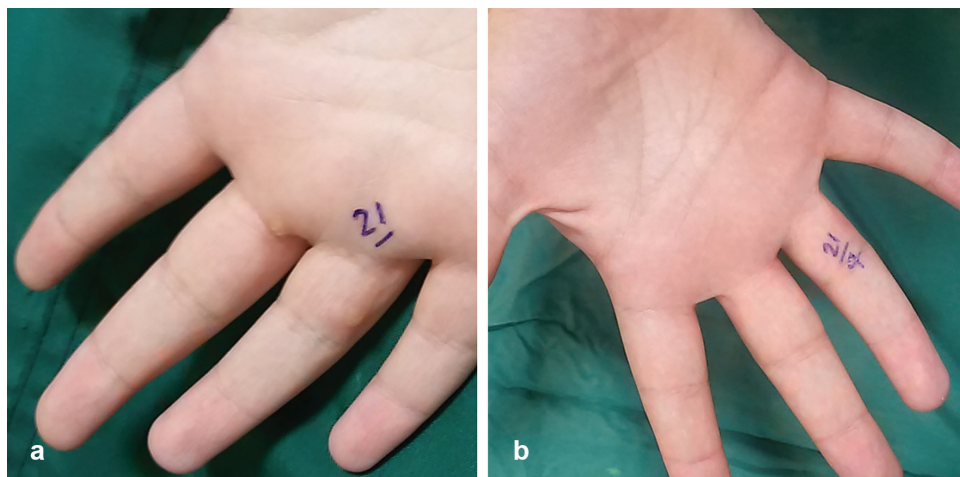
Demographic Feature	MMR Group	Placebo Group	P
Age	27.2±8.73	25.37±9.23	0.35
Sex			
Male	12 (40%)	11 (36.7%)	0.11
Female	18 (60%)	19 (63.3%)	
Number of warts	6.5±2	6.1±2.5	0.22
Location of warts			
Palmar	14 (46.7%)	20 (66.7%)	0.12
Plantar	14 (46.7%)	10 (33.3%)	
Both	2 (6.7%)	0 (0.0%)	
Size of warts (diameter)	2.3 cm	2.1 cm	0.26
Duration of the presence of warts (y)	2.26	2.3	0.81

MMR: Measles–mumps–rubella

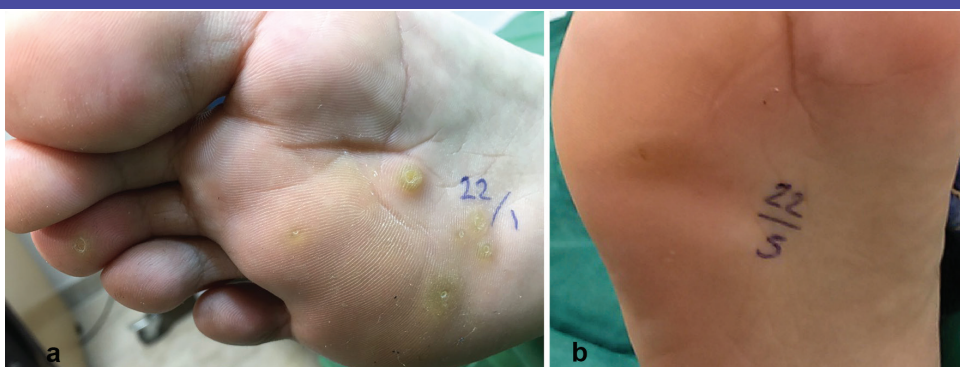Table 2: Clinical results of the intralesional MMR vaccine for the resistant-to-treatment palmoplantar warts

Injection Turn	MMR Group			Placebo Group			P
	No response	Partial response	Complete response	No response	Partial response	Complete response	
First injection	30 (100%)	0 (0%)	0 (0%)	30 (100%)	0 (0%)	0 (0%)	0.112
Second injection	26 (89.7%)	3 (10.3%)	0 (0%)	27 (100%)	0 (0%)	0 (0%)	0.312
Third injection	11 (45.8%)	11 (45.8%)	2 (8.3%)	16 (6.7%)	8 (33.3%)	0 (0%)	0.512
Fourth injection	5 (21.7%)	8 (34.8%)	10 (43.5%)	10 (47.6%)	9 (42.9%)	2 (9.5%)	0.012
Fifth injection	5 (21.7%)	4 (13.0%)	14 (65.2%)	10 (47.6%)	6 (28.6%)	5 (23.8%)	0.021

MMR: Measles–mumps–rubella



**Figure 2:** Multiple palmar warts (a) before treatment with the intralesional measles-mumps-rubella vaccine and (b) complete clearance after four sessions of treatment.



**Figure 3:** Multiple plantar warts (a) before treatment with the intralesional measles-mumps-rubella vaccine and (b) complete clearance after five sessions of treatment.

Flu-like symptoms, which occurred within 12 hours of injection and resolved within 24 hours spontaneously, were observed in 13% of the patients.

## Discussion

Common warts are a challenge to both patients and clinicians. They can cause embarrassment to patients by persistence or recurrence and affect patients' lives by making them feel uncomfortable in their social and leisure activities. We, therefore, sought to study new, safe, and efficient wart therapies.<sup>6</sup>

Evidence showing that cellular immune responses play a critical role in wart clearance has inspired the development of topical and intralesional immunotherapy regimens for patients with multiple and/or persistent warts.<sup>4</sup> The intralesional injection of *Candida*, *Trichophyton*, and/or mumps skin test antigens is another approach to immunotherapy for warts. This treatment modality showed a significantly higher clearance rate than a placebo for treated as well as untreated distant warts in a randomized, controlled, clinical trial on patients

receiving intralesional antigens.<sup>15</sup> The results of our study, which seems to be the first study on the intralesional injection of the MMR vaccine into resistant-to-therapy palmoplantar warts, demonstrated a highly significant difference between the therapeutic response of common warts to the MMR vaccine and saline. Similar findings were reported by other studies that applied the intralesional MMR vaccine into nongenital warts.<sup>16</sup>

The response rate in the present study (65.2% complete response) was higher than that reported by Kus et al.<sup>17</sup> (29.4%) and Clifton and others.<sup>18</sup> (47%), who used intralesional antigen immunotherapy (tuberculin and mumps or *Candida*, respectively) for the treatment of recalcitrant nongenital warts in open-label trials. The higher response rate in our study may have been caused by different antigens in MMR, which makes the probability of sensitivity to the injected antigen very high. In addition, live vaccines such as MMR are more immunogenic than skin test antigens such as mumps, *Candida*, and tuberculin. The response rate achieved in the present study was higher than that reported by Nofal and co-workers<sup>19</sup> (63%

complete response), which was an open label, nonrandomized, uncontrolled trial injecting the MMR vaccine into recalcitrant extragenital warts. The mean age of the patients in the study by Nofal and colleagues was 38.9 years, which was significantly higher than the mean age of our patients. Furthermore, we had significantly fewer males and significantly more females in our study than did Nofal et al. in their investigation.

One of the previous studies that was very close to our study in terms of design was that of Zamanian et al.,<sup>16</sup> who used the intralesional MMR vaccine injection for common warts. In their double-blind, randomized, controlled clinical trial, the mean ages of the male and female patients in the MMR and normal saline groups were significantly higher and lower than those in our study, respectively. The complete response rate reported in our study was higher. This difference may be due to the fact that our 5 times injection of the MMR vaccine might have led to higher stimulation of the immune system than the 3 times injection in the investigation by Zamanian and colleagues. On the other hand, the complete response rate achieved in the present study (65.2%) was less than that reported in the study by Nofal et al.<sup>20</sup> (81.4%). This might be related to differences in the population selected, number of the patients studied, number of the warts (multiple vs. single or multiple), and duration of their presence ( $\geq 2$  y).

Intralesional immunotherapy was shown to be associated with the release of important cytokines such as IL-2, IL-12, IFN- $\alpha$ , and TNF- $\alpha$ , which can potentiate the cytotoxicity of T killer cells and natural killer cells that play a role in the clearance of HPV-infected cells.<sup>10</sup> In the present study, we found no statistically significant association between the therapeutic response to the MMR vaccine and such different clinical variables as the age and sex of the patients and the number and duration of the warts. Our results demonstrated no recurrence of warts 6 months after treatment with the intralesional MMR vaccine. Chiming in with our findings, other related studies have also reported a similar low rate of recurrence.<sup>17, 18, 21</sup> This may be attributed to the long-term vigilance of the immune system against the HPV virus through the induction of cell-mediated immunity, which enables the body to recognize HPV by stimulating memory T cells against the virus.<sup>22, 23</sup>

Intralesional immunotherapy is often associated with mild inconsiderable side effects. Slight pain during injection was reported by 100% of the patients. Other local reactions such as erythema, edema, and itching at the site of injection were transient, as reported by similar

studies.<sup>16-23</sup> Flu-like symptoms were found in 13% of the patients and resolved spontaneously within 24 hours. This side effect is attributed to the release of inflammatory cytokines in response to the leakage of some antigens into the circulation.<sup>24</sup>

Severe adverse effects such as scarring and pigmentary changes that are found in destructive therapies were not observed in our study and other related studies. This fact confirms the safety of this new therapy.<sup>16-24</sup>

One of the positive points in our study is that in a case-control study, we compared our results with those in patients who had used traditional destructive therapy before enrollment in our study.

There are some limitations to our study, however. Firstly, we evaluated the efficacy of the treatment 1 month after a maximum of 5 treatments, while some previous studies have demonstrated that both the number and size of warts decrease in patients treated with continuous MMR injections with partial response. Secondly, if the total treatment number had been larger, the efficacy would have been higher. Thus, the number of injections for complete response should be revised.<sup>25</sup>

## Conclusion

In our study, we did not evaluate regression in distant warts as our study was particularly on palmoplantar warts. Furthermore, the small sample size may limit the external validity of our results. MMR seems to be less painful and much safer than traditional destructive methods for wart treatment and, thus, seems to be better accepted by patients. Future studies, including randomized controlled clinical trials, are required to investigate the clinical effects and factors affecting the efficacy of this treatment using larger sample sizes, in different sites of the body, and with higher numbers of injections. Determining the HPV type and the impact of the MMR injection in future investigations is suggested.

## Acknowledgement

The authors of this article have the utmost gratitude to the Vice-Chancellor for Research of Mazandaran University of Medical Sciences for providing financial support for this research project. This article is the result of Ozra Asqary Marzidareh's thesis for general medicine (grant No. 877). We would like to thank Mrs. Fatemeh Hosseinzadeh (Infectious Diseases Research Center with focus on Nosocomial Infections) for editing and submitting the manuscript.

**Conflict of Interest:** None declared.

## References

- 1 Stanley MA. Epithelial cell responses to infection with human papillomavirus. *Clin Microbiol Rev.* 2012;25:215-22. doi: 10.1128/CMR.05028-11. PubMed PMID: 22491770; PubMed Central PMCID: PMC3346303.
- 2 Groves IJ, Coleman N. Pathogenesis of human papillomavirus-associated mucosal disease. *J Pathol.* 2015;235:527-38. doi: 10.1002/path.4496. PubMed PMID: 25604863.
- 3 Gibbs S, Harvey I, Sterling JC, Stark R. Local treatments for cutaneous warts. *Cochrane Database Syst Rev.* 2003;CD001781. doi: 10.1002/14651858.CD001781. PubMed PMID: 12917913.
- 4 Lipke MM. An armamentarium of wart treatments. *Clin Med Res.* 2006;4:273-93. PubMed PMID: 17210977; PubMed Central PMCID: PMC1764803.
- 5 Bernard HU, Burk RD, Chen Z, van Doorslaer K, zur Hausen H, de Villiers EM. Classification of papillomaviruses (PVs) based on 189 PV types and proposal of taxonomic amendments. *Virology.* 2010;401:70-9. doi: 10.1016/j.virol.2010.02.002. PubMed PMID: 20206957; PubMed Central PMCID: PMC3400342.
- 6 Leman JA, Benton EC. Verrucas. Guidelines for management. *Am J Clin Dermatol.* 2000;1:143-9. PubMed PMID: 11702295.
- 7 Ciconte A, Campbell J, Tabrizi S, Garland S, Marks R. Warts are not merely blemishes on the skin: A study on the morbidity associated with having viral cutaneous warts. *Australas J Dermatol.* 2003;44:169-73. PubMed PMID: 12869040.
- 8 Gunter J. Genital and perianal warts: new treatment opportunities for human papillomavirus infection. *Am J Obstet Gynecol.* 2003;189:S3-11. PubMed PMID: 14532897.
- 9 Fox PA, Tung MY. Human papillomavirus: burden of illness and treatment cost considerations. *Am J Clin Dermatol.* 2005;6:365-81. PubMed PMID: 16343025.
- 10 Harro CD, Pang YY, Roden RB, Hildesheim A, Wang Z, Reynolds MJ, et al. Safety and immunogenicity trial in adult volunteers of a human papillomavirus 16 L1 virus-like particle vaccine. *J Natl Cancer Inst.* 2001;93:284-92. PubMed PMID: 11181775.
- 11 Goncalves MA, Donadi EA. Immune cellular response to HPV: current concepts. *Braz J Infect Dis.* 2004;8:1-9. PubMed PMID: 15137933.
- 12 Goihman-Yahr M, Goldblum OM. Immunotherapy and warts: a point of view. *Clin Dermatol.* 2008;26:223-5. doi: 10.1016/j.clindermatol.2007.10.011. PubMed PMID: 18472063.
- 13 Bacelieri R, Johnson SM. Cutaneous warts: an evidence-based approach to therapy. *Am Fam Physician.* 2005;72:647-52. PubMed PMID: 16127954.
- 14 Rivera A, Tyring SK. Therapy of cutaneous human Papillomavirus infections. *Dermatol Ther.* 2004;17:441-8. doi: 10.1111/j.1396-0296.2004.04047.x. PubMed PMID: 15571494.
- 15 Horn TD, Johnson SM, Helm RM, Roberson PK. Intralesional immunotherapy of warts with mumps, Candida, and Trichophyton skin test antigens: a single-blinded, randomized, and controlled trial. *Arch Dermatol.* 2005;141:589-94. doi: 10.1001/archderm.141.5.589. PubMed PMID: 15897380.
- 16 Zamanian A, Mobasher P, Jazi GA. Efficacy of intralesional injection of mumps-measles-rubella vaccine in patients with wart. *Adv Biomed Res.* 2014;3:107. doi: 10.4103/2277-9175.129701. PubMed PMID: 24804181; PubMed Central PMCID: PMC34009748.
- 17 Kus S, Ergun T, Gun D, Akin O. Intralesional tuberculin for treatment of refractory warts. *J Eur Acad Dermatol Venereol.* 2005;19:515-6. doi: 10.1111/j.1468-3083.2004.01176.x. PubMed PMID: 15987315.
- 18 Clifton MM, Johnson SM, Roberson PK, Kincannon J, Horn TD. Immunotherapy for recalcitrant warts in children using intralesional mumps or Candida antigens. *Pediatr Dermatol.* 2003;20:268-71. PubMed PMID: 12787281.
- 19 Nofal A, Nofal E, Yosef A, Nofal H. Treatment of recalcitrant warts with intralesional measles, mumps, and rubella vaccine: a promising approach. *Int J Dermatol.* 2015;54:667-71. doi: 10.1111/ijd.12480. PubMed PMID: 25070525.
- 20 Nofal A, Nofal E. Intralesional immunotherapy of common warts: successful treatment with mumps, measles and rubella vaccine. *J Eur Acad Dermatol Venereol.* 2010;24:1166-70. doi: 10.1111/j.1468-3083.2010.03611.x. PubMed PMID: 20202055.
- 21 Gupta S, Malhotra AK, Verma KK, Sharma VK. Intralesional immunotherapy with killed Mycobacterium w vaccine for the treatment of ano-genital warts: an open label pilot study. *J Eur Acad Dermatol Venereol.* 2008;22:1089-93. doi: 10.1111/j.1468-3083.2008.02719.x. PubMed PMID: 18484970.
- 22 Chandrashekar L. Intralesional immunotherapy for the management of warts. *Indian J*

- Dermatol Venereol Leprol. 2011;77:261-3. doi: 10.4103/0378-6323.79694. PubMed PMID: 21508563.
- 23 Horn TD, Johnson SM, Helm RM, Roberson PK. Intralesional immunotherapy of warts with mumps, Candida, and Trichophyton skin test antigens: a single-blinded, randomized, and controlled trial. Arch Dermatol. 2005;141:589-94. doi: 10.1001/archderm.141.5.589. PubMed PMID: 15897380.
- 24 Johnson SM, Roberson PK, Horn TD. Intralesional injection of mumps or Candida skin test antigens: a novel immunotherapy for warts. Arch Dermatol. 2001;137:451-5. PubMed PMID: 11295925.
- 25 Na CH, Choi H, Song SH, Kim MS, Shin BS. Two-year experience of using the measles, mumps and rubella vaccine as intralesional immunotherapy for warts. Clin Exp Dermatol. 2014;39:583-9. doi: 10.1111/ced.12369. PubMed PMID: 24934912.