

Original Article



Benefit of Four-Dimensional Computed Tomography Derived Ejection Fraction of the Left Atrial Appendage to Predict Thromboembolic Risk in the Patients with Valvular Heart Disease

In-Cheol Kim , MD, PhD^{1,2}, Hyuk-Jae Chang , MD, PhD¹, In-Jeong Cho, MD¹, Chi Young Shim , MD, PhD¹, Geu-Ru Hong , MD, PhD¹, Ji Hoe Heo , MD, PhD³, Hyo Suk Nam , MD, PhD³, Young-Jin Kim , MD, PhD⁴, Byoung-Wook Choi , MD, PhD⁴, and Namsik Chung, MD, PhD¹

¹Division of Cardiology, Severance Cardiovascular Hospital, Yonsei University College of Medicine, Seoul, Korea

²Division of Cardiology, Department of Internal Medicine, Dongsan Medical Center, Keimyung University College of Medicine, Daegu, Korea

³Department of Neurology, Yonsei University College of Medicine, Seoul, Korea

⁴Department of Radiology, Severance Hospital, Yonsei University College of Medicine, Seoul, Korea



Received: May 7, 2018

Revised: Aug 26, 2018

Accepted: Sep 18, 2018

Correspondence to

Hyuk-Jae Chang, MD, PhD

Division of Cardiology, Severance Cardiovascular Hospital, Yonsei University College of Medicine, Yonsei University Health System, 50-1, Yonsei-ro, Seodaemun-gu, Seoul 03722, Korea.
E-mail: HJCHANG@yuhs.ac

Copyright © 2019. The Korean Society of Cardiology

This is an Open Access article distributed under the terms of the Creative Commons Attribution Non-Commercial License (<https://creativecommons.org/licenses/by-nc/4.0>) which permits unrestricted noncommercial use, distribution, and reproduction in any medium, provided the original work is properly cited.

ORCID iDs

In-Cheol Kim
<https://orcid.org/0000-0002-5751-2328>
Hyuk-Jae Chang
<https://orcid.org/0000-0002-6139-7545>
Chi Young Shim
<https://orcid.org/0000-0002-6136-0136>
Geu-Ru Hong
<https://orcid.org/0000-0003-4981-3304>

<https://e-kcj.org>

ABSTRACT

Background and Objectives: Decreased left atrial appendage (LAA) emptying velocity in transesophageal echocardiography (TEE) is related with higher incidence of thrombus and increased risk of stroke. Patients with valve disease are at higher risk of thrombus formation before and after surgery. The aim of this study was to investigate the role of 4-dimensional cardiac computed tomography (4DCT) to predict the risk of thrombus formation.

Methods: Between March 2010 to March 2015, total of 62 patients (mean 60±15 years old, male: 53.2%) who underwent 4DCT and TEE for cardiac valve evaluation before surgery were retrospectively included in the current study. Fractional area change in TEE view and emptying velocity at left atrial appendage in TEE view ($V_{e\text{TEE}}$) were measured. Ejection fraction (EF) of left atrial appendage in computed tomography (EF_{CT}) was calculated by 4DCT with full volume analysis. The best cut-off value of EF_{CT} predicting presence of spontaneous echo contrast (SEC) or thrombus was evaluated, and correlation between the parameters were also estimated.


Results: SEC or thrombus was observed in 45.2%. EF_{CT} and $V_{e\text{TEE}}$ were significantly correlated ($r=0.452$, $p<0.001$). However, fractional area change measured by TEE showed no correlation with $V_{e\text{TEE}}$ ($r=0.085$, $p=0.512$). $EF_{\text{CT}} < 37.5\%$ best predicted SEC or thrombus in the patients with valve disease who underwent 4DCT and TEE (area under the curve, 0.654; $p=0.038$).

Conclusions: In the patients who underwent 4DCT for cardiac valve evaluation before surgery, EF_{CT} by volume analysis might have additional role to evaluate LAA function and estimate the risk of thrombus.


Keywords: Computed tomography; Atrial appendage; Thrombus

Ji Hoe Heo 

<https://orcid.org/0000-0001-9898-3321>

Hyo Suk Nam 

<https://orcid.org/0000-0002-4415-3995>

Young-Jin Kim 

<https://orcid.org/0000-0003-4126-016X>

Byoung-Wook Choi 

<https://orcid.org/0000-0002-8326-9675>

Conflict of Interest

The authors have no financial conflicts of interest.

Author Contributions

Conceptualization: Chang HJ, Kim IC, Hong GR, Heo JH, Kim YJ, Choi BW, Chung N; Data curation: Chang HJ, Kim IC, Shim CY, Hong GR, Heo JH, Nam HS, Kim YJ; Formal analysis: Kim IC; Investigation: Kim IC, Shim CY, Hong GR, Heo JH, Nam HS, Kim YJ; Methodology: Chang HJ, Kim IC, Cho IJ; Project administration: Chang HJ, Kim IC, Cho IJ, Hong GR, Choi BW, Chung N; Resources: Chang HJ, Kim IC, Shim CY; Software: Kim IC; Supervision: Chang HJ, Hong GR, Choi BW, Chung N; Validation: Chang HJ, Kim IC; Visualization: Chang HJ, Kim IC, Kim YJ; Writing - original draft: Kim IC; Writing - review & editing: Chang HJ, Kim IC, Cho IJ, Shim CY, Hong GR, Heo JH, Nam HS, Chung N.

INTRODUCTION

Spontaneous echo contrast (SEC) and thrombus in left atrium (LA) as well as left atrial appendage (LAA) detected in transesophageal echocardiography (TEE) were well known risk factors for cardioembolic stroke. Previous report revealed that decreased LAA emptying velocity (<55 cm/s) is an important contributor of thrombus and SEC.¹⁾

There has been increased use of 4-dimensional cardiac computed tomography (4DCT) for the evaluation of valve disease particularly before valve surgery or transcatheter aortic valve replacement (TAVR). In clinical field, 4DCT is utilized to evaluate native and prosthetic valve morphology and function, to measure ascending aorta, aortic root and aortic annulus related with TAVR procedure, and to evaluate subvalvular structures such as papillary muscles and chordae tendinae. In addition, volumetric data of cardiac chambers including LAA can be measured.²⁾³⁾

Patients with valve disease are at higher risk of thrombus formation before and after surgery.⁴⁾⁵⁾ Thus, predicting thromboembolic risk and adopting tailored anticoagulation might be important to avoid catastrophic complications in patients undergoing valve surgery. The aim of this study was to investigate the role of 4DCT performed for the evaluation of valve disease before surgery to predict the risk of thrombus formation.

MATERIALS AND METHODS

Patient population and data acquisition

Between March 2010 to March 2015, patients who underwent 4DCT and TEE for cardiac valve evaluation before surgery in Yonsei Cardiovascular Hospital were screened. Inclusion criteria was patients who underwent 4DCT and TEE with LAA velocity measurement within 3 months with maintained normal sinus rhythm during both exams. Exclusion criteria were patients with atrial fibrillation (AF) or flutter rhythm during any of the exam, more than moderate mitral regurgitation, prosthetic valve or intracardiac devices which generate artifact. Among 150 patients who were initially screened, 37 patients with prosthetic heart valve and 51 patients with AF or atrial flutter rhythm were excluded. Finally, 62 patients were included for the analysis in the current study.

Transesophageal echocardiography image acquisition and analysis

Standard TEE views were acquired as per recommendations of the American Society of Echocardiography guidelines using 5 MHz multi-plane probe with commercially available scanners (GE Vivid E9; Vingmed Ultrasound, Horten, Norway, Philips IE33 system; Phillips Medical Systems, Andover, MA, USA).⁶⁾ LAA was observed at best image between 45 to 90° including 2-dimensional, color Doppler images and pulsed-wave Doppler. Fractional area change (FAC_{TEE}) was calculated by dividing maximum area of LAA from the difference between maximum and minimum area of LAA (**Figure 1**). Peak end-diastolic emptying velocity at LAA in TEE view (V_{eTEE}) was the mean of 3 consecutive values by pulsed-wave Doppler at LAA ostium. SEC was defined as smoke-like swirling pattern observed in LA or LAA after adjustment of optimal gain setting.⁷⁾

Computed tomography image acquisition and analysis

Cardiac computed tomography (CT) scans were performed with a dual-source CT scanner (SOMATOM Definition Flash; Siemens Healthcare, Erlangen, Germany) or

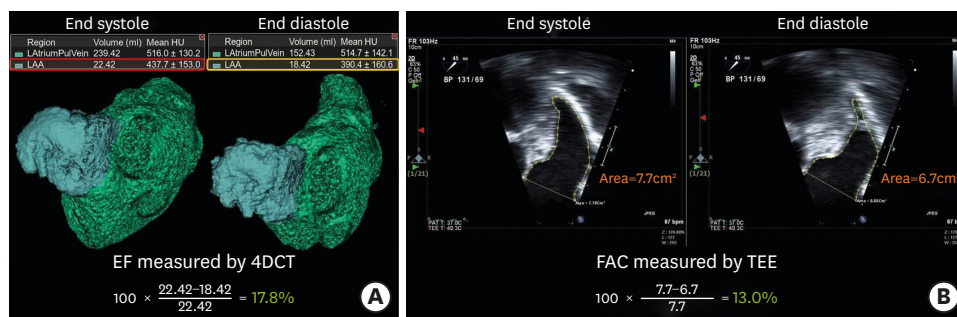


Figure 1. Representative image showing measurement of EF_{CT} (A) and FAC_{TEE} (B). BP = blood pressure; EF = ejection fraction; EF_{CT} = ejection fraction of left atrial appendage in computed tomography; FAC = fractional area change; FAC_{TEE} = fractional area change in transesophageal echocardiography view; LAA = left atrial appendage; TEE = transesophageal echocardiography; 4DCT = 4-dimensional cardiac computed tomography.

a 64-slice multidetector computed tomography (MDCT) (SOMATOM Sensation 64; Siemens Medical Solution, Erlangen, Germany). They were performed with retrospective electrocardiographically gated data acquisition (0–90% phase). The indication of the retrospective gating was to evaluate valvular function as well as coronary patency and adjacent thoracic structures according to the clinician's discretion. Vitrea 6.4 version workstation (Vital Images Inc., Minnetonka, MN, USA) was used for reconstruction and analyzing volume. After selecting LAA orifice at the level of left circumflex artery, LAA was separated from LA, and volume was measured during 10 cycles. Ejection fraction of left atrial appendage in computed tomography (EF_{CT}) was calculated by dividing maximum volume from the difference between maximum and minimum volume (Figure 1).

Statistical analysis

All analyses were conducted using SPSS version 23.0 (SPSS Inc., Chicago, IL, USA). Continuous variables were expressed as mean±standard deviation and were compared using the independent t-test and Pearson correlation coefficient. Variables which were not normally distributed were compared using the Mann-Whitney U test. Categorical variables were compared using the χ^2 test or Fisher's exact test, as appropriate. A p value of <0.05 was considered statistically significant. The best cut-off value of EF_{CT} to predict the presence of SEC or thrombus were measured using receiver operator characteristic curve. Correlation between the parameters were also estimated.

RESULTS

Baseline characteristics and transthoracic echocardiography results

Baseline characteristics are compared in SEC/thrombus (+) group and SEC/thrombus (-) group (Table 1). Baseline characteristics were not significantly different between the 2 groups. Transthoracic echocardiography results are shown in Table 2. Left atrial volume index was significantly higher in the SEC/thrombus (+) group when compared to SEC/thrombus (-) group.

Left atrial appendage parameter measurement by 4-dimensional cardiac computed tomography and transesophageal echocardiography

Volumetric assessment of EF_{CT} and functional assessment of Ve_{TEE} were significantly lower in SEC/thrombus (+) group. However, 2-dimensional area assessment by FAC_{TEE} was not significantly different between 2 groups (Table 3).

Table 1. Baseline characteristics

Total (n=62)	SEC/thrombus (+) (n=27)	SEC/thrombus (-) (n=35)	p value
Age (years)	58.7±11.9	60.9±17.7	0.560
Male sex (%)	14 (51.9)	19 (54.3)	0.849
Systolic BP (mmHg)	122.9±14.0	116.6±15.7	0.110
Diastolic BP (mmHg)	69.9±12.2	71.4±9.5	0.592
Heart rate (bpm)	75.2±13.7	75.4±12.3	0.962
Smoking (%)	10 (37.0)	10 (28.5)	0.779
HTN (%)	10 (37.0)	21 (60.0)	0.073
DM (%)	1 (3.7)	4 (11.4)	0.376
Dyslipidemia (%)	6 (22.2)	6 (17.1)	0.616
CKD (%)	0 (0)	2 (5.7)	0.500
HF (%)	5 (18.5)	6 (17.1)	0.888
CAD (%)	0 (0)	1 (2.9)	1.000
PAD (%)	0 (0)	1 (2.9)	1.000
Old CVA (%)	1 (3.7)	3 (8.6)	0.626
Hb (mg/dL)	13.4±1.9	12.5±2.0	0.078
NT-ProBNP (pg/mL)	2,367.1±3,698.4	2,181.8±3,431.3	0.890
Aspirin (%)	2 (7.4)	2 (5.7)	1.000
Anticoagulation (%)	2 (7.4)	0 (0)	0.186
Total radiation dose (mSV)	760.2±354.3	800.8±524.0	0.734

BP = blood pressure; CAD = coronary artery disease; CKD = chronic kidney disease; CVA = cerebrovascular accident; DM = diabetes mellitus; Hb = hemoglobin; HF = heart failure; HTN = hypertension; NT-ProBNP = N-terminal-prohormone of brain natriuretic peptide; PAD = peripheral artery disease; SEC = spontaneous echo contrast.

Table 2. Transthoracic echocardiography results

Total (n=62)	SEC/thrombus (+) (n=27)	SEC/thrombus (-) (n=35)	p value
EF (%)	60.7±11.6	61.9±11.7	0.687
LVEDD (mm)	56.6±10.8	51.8±10.6	0.090
LVESD (mm)	39.3±9.8	35.6±9.5	0.144
LAVI, mL/m ²	63.1±30.3	40.1±21.5	0.001
E (m/s)	1.00±0.50	0.89±0.42	0.434
A (m/s)	0.71±0.47	0.78±0.42	0.663
DT (ms)	169.5±46.6	202.0±54.9	0.060
E/e'	18.2±9.2	17.1±6.1	0.636

DT = deceleration time; EF = ejection fraction; LAVI = left atrial volume index; LVEDD = left ventricular end-diastolic dimension; LVESD = left ventricular end-systolic dimension; SEC = spontaneous echo contrast.

Table 3. LAA parameters measured by 4DCT and TEE

Total (n=62)	SEC/thrombus (+) (n=27)	SEC/thrombus (-) (n=35)	p value
CT measurement			
LAA diastolic volume (mL)	17.4±7.0	18.7±8.3	0.502
LAA systolic volume (mL)	11.0±5.1	10.5±5.3	0.707
EF _{CT} (%)	36.8±16.6	44.9±12.0	0.030
TEE measurement			
Ve _{TEE} (cm/s)	40.3±15.6	61.5±19.2	<0.001
LAA diastolic area (cm ²)	5.19±1.86	5.66±2.06	0.355
LAA systolic area (cm ²)	3.15±1.66	3.29±1.34	0.719
FAC _{TEE}	40.9±11.0	41.0±7.8	0.951

CT = computed tomography; EF_{CT} = ejection fraction of left atrial appendage in computed tomography; FAC_{TEE} = fractional area change in transesophageal echocardiography view; LAA = left atrial appendage; SEC = spontaneous echo contrast; TEE = transesophageal echocardiography; Ve_{TEE} = emptying velocity at left atrial appendage in transesophageal echocardiography view; 4DCT = 4-dimensional cardiac computed tomography.

Correlation between parameters

Correlation between EF_{CT} and FAC_{TEE}, EF_{CT} and Ve_{TEE} were compared. There was no significant correlation between FAC_{TEE} and EF_{CT} (r=-0.072, p=0.577). Nevertheless, there was significant correlation between Ve_{TEE} and EF_{CT} (r=0.431, p<0.001) (**Figure 2**). Additional Bland-Altman plot also showed relationship between measurements of EF_{CT} and FAC_{TEE}, and measurement of EF_{CT} and Ve_{TEE} (**Supplementary Figure 1**).

Best cut-off value of ejection fraction of left atrial appendage in computed tomography predicting thromboembolic risk

Best cut-off value of EF_{CT} predicting presence of SEC/thrombus was 37.5% (area under the curve [AUC], 0.654; sensitivity, 0.824; specificity, 0.536; $p=0.038$), and predicting $Ve_{TEE} < 55$ cm/s was also 37.5% (AUC, 0.704; sensitivity, 0.917; specificity, 0.500; $p=0.007$) by receiver operating curve (Figure 3).

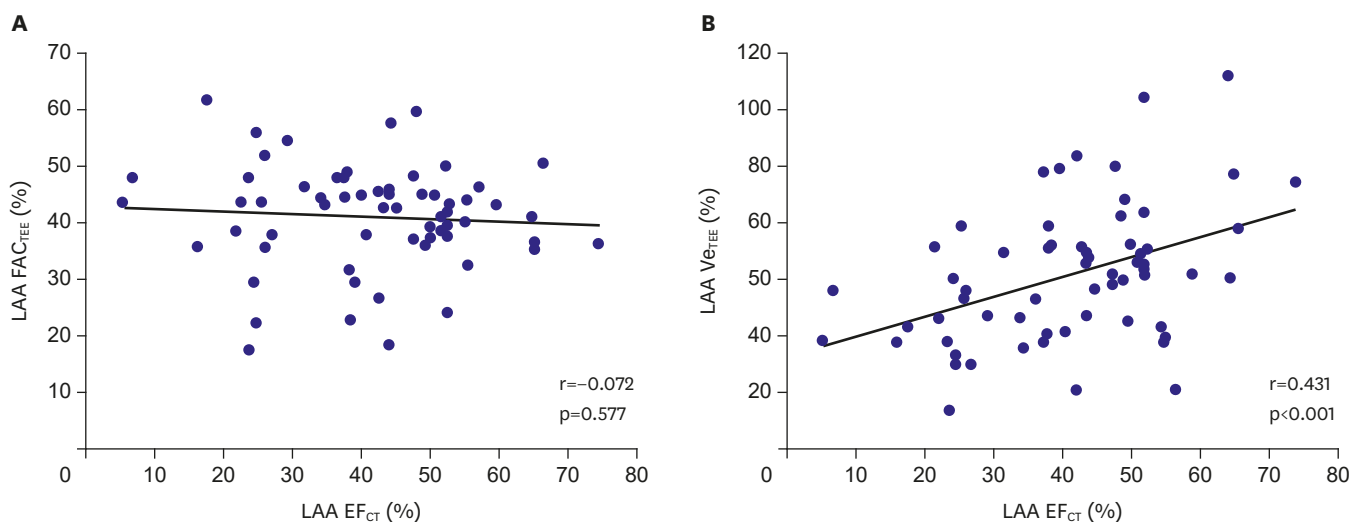


Figure 2. Correlation graph of EF_{CT} and FAC_{TEE} (A) and EF_{CT} and Ve_{TEE} (B). EF_{CT} = ejection fraction of left atrial appendage in computed tomography; FAC_{TEE} = fractional area change in transesophageal echocardiography view; LAA = left atrial appendage; Ve_{TEE} = emptying velocity at left atrial appendage in transesophageal echocardiography view.

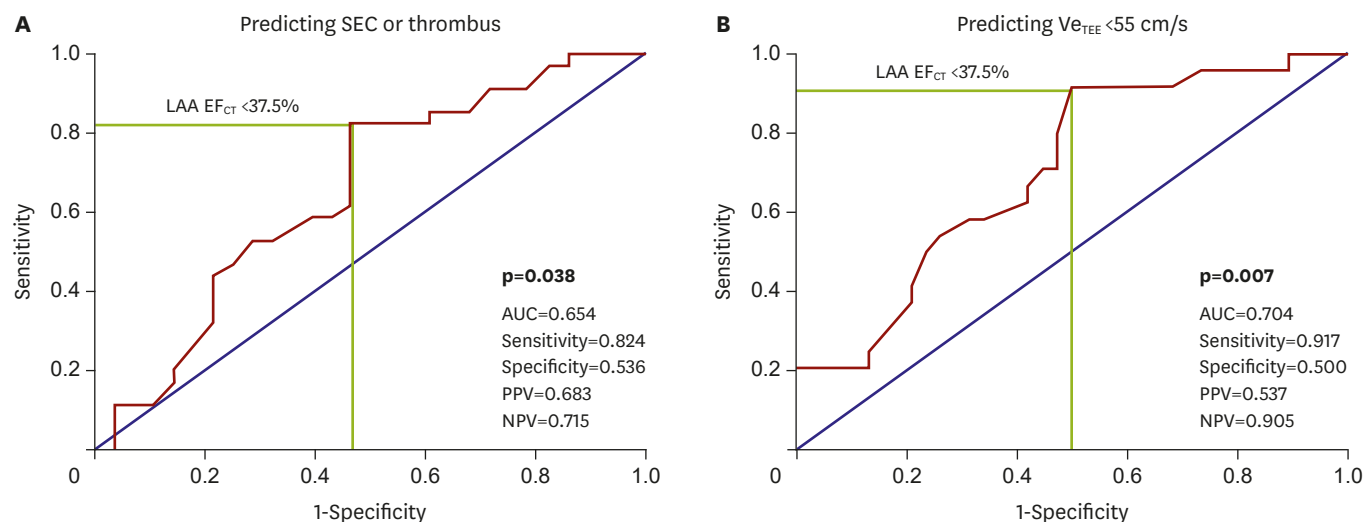


Figure 3. Receiver operator characteristics curve presenting best cut-off value of EF_{CT} predicting SEC or thrombus (A) and $Ve_{TEE} < 55$ cm/s (B). AUC = area under the curve; EF = ejection fraction; EF_{CT} = ejection fraction of left atrial appendage in computed tomography; LAA = left atrial appendage; NPV = negative predicative value; PPV = positive predicative value; SEC = spontaneous echo contrast; Ve_{TEE} = emptying velocity at left atrial appendage in transesophageal echocardiography view.

DISCUSSION

The main findings of this study are as follows: 1) EF_{CT} and Ve_{TEE} were significantly lower in SEC/thrombus (+) group. However, FAC_{TEE} showed no correlation in regards of the presence of SEC or thrombus. 2) Ve_{TEE} was also correlated with EF_{CT} , but FAC_{TEE} showed no correlation with EF_{CT} . 3) Best cut-off value of LAA EF by 4DCT predicting thromboembolic risk and LAA peak emptying velocity of <55 cm/s was 37.5%.

Cardiac CT is a useful alternative to TEE for the diagnosis of LAA thrombus. Comparing CT and TEE for the diagnosis of LAA thrombus, the overall sensitivity and specificity were 96% and 92% respectively. Negative predictive value was up to 99%.^{8,9)} Previous studies have shown that MDCT can find potential cardiac sources of cardioembolic stroke including LAA/LA thrombus, aortic atheroma, circulatory stasis and PFO.^{10,11)} However, previous studies with CT acquired delayed image to evaluate LAA thrombus which is not routinely performed in most laboratories.¹¹⁾ The benefit of the current method is that we can apply EF_{CT} in all CT scan with retrospective protocol. Further benefit of EF_{CT} in patients with AF or without valvular heart disease need to be investigated.

TEE has been a gold standard for the detection of cardioembolic source in stroke patients. However, there are several drawbacks to use TEE as a routine practice. First, it is a semi-invasive procedure which produces patient discomfort.¹⁰⁾ Patients with neurological dysfunction are more difficult to tolerate the discomfort during procedure. Second, TEE cannot detect extracardiac source of thrombus which is also an important source of embolic stroke.¹²⁾ Lastly, the ability of TEE for the detection of cardioembolic source is highly dependent by the physician and post-processing is impossible.

TEE has a superiority for temporal resolution than CT, however it can only visualize cross-sectional image of LAA with complex structure.¹³⁾ Moreover, there is a possibility to measure different cross-section during systole and diastole due to the beating effect. Functional measurements are less affected by beating effect since flow measurement is similar among whole LAA chamber regardless of the measurement site. We consider the most accurate measurement of anatomical EF_{CT} and it is closely related with functional parameters as well as thromboembolic risk.

In our study, LAA EF by 4DCT had benefit for the prediction of SEC or intracardiac thrombus. SEC and intracardiac thrombus are well known risk factors for cardioembolic stroke. It was also correlated with functional parameter of LAA by TEE (LAA emptying velocity <55 cm/s). Best cut-off value predicting SEC or thrombus and emptying velocity <55 cm/s was LAA EF $<37.5\%$.

4DCT can provide useful information for the evaluation of a patient with embolic stroke. Its utility for detecting intracardiac thrombus, patent foramen ovale, aortic atheroma, and coronary artery disease was previously reported.^{10,12,14)} By 4DCT, we can also acquire functional information which was previously provided only by TEE. Those parameters are frequently used for thromboembolic risk assessment.

The indication of TAVR has been expanded recently, and increasing number of patients are undergoing CT before surgery or procedures. In virtue of advancement in CT protocols, patients get less radiation and contrast. Although, TEE still stands for gold standard of evaluating thromboembolic risk, 4DCT might have an alternative role which provides excellent spatial resolution and additional functional information.

This study is retrospective cross-sectional single center study with small number of patients which might inherit limitations.

Patients with normal sinus rhythm were only enrolled to fairly compare the ability of LAA EF by 4DCT and LAA FAC by TEE with correlation to thromboembolic risk in this retrospective design study. AF is an important source of thromboembolism, but thromboembolic risk still exists in the patients with normal sinus rhythm undergoing valve surgery or procedures. Future study including AF patients might be an interesting topic.

In the present study, we evaluated composite of SEC and thrombus as study endpoint and outcome data (e.g., embolic stroke or death) was not available. However, both dense SEC and thrombus are strong risk factors for future thromboembolism.¹⁵⁻¹⁸⁾ They are also related with poor clinical outcome and further studies are needed to investigate whether EF_{CT} is related with hard outcomes such as stroke or death. It is worth to mention that how many actual patients would suffer from true thromboembolic events and we are expecting further prospective design study with larger population to evaluate the role of 4DCT predicting actual thromboembolic event.

In conclusion, the patients who undergo 4DCT before surgical correction of valvular heart disease, LAA EF by volume analysis using 4DCT has additional benefit to evaluate future thromboembolic risk.

SUPPLEMENTARY MATERIAL

Supplementary Figure 1

Bland-Altman plot showing relationship between measurements of EF_{CT} and FAC_{TEE}, and measurement of EF_{CT} and Ve_{TEE}.

[Click here to view](#)

REFERENCES

1. Handke M, Harloff A, Hetzel A, Olschewski M, Bode C, Geibel A. Left atrial appendage flow velocity as a quantitative surrogate parameter for thromboembolic risk: determinants and relationship to spontaneous echocontrast and thrombus formation--a transesophageal echocardiographic study in 500 patients with cerebral ischemia. *J Am Soc Echocardiogr* 2005;18:1366-72.
[PUBMED](#) | [CROSSREF](#)
2. Delgado V, Tops LF, Schuijf JD, et al. Assessment of mitral valve anatomy and geometry with multislice computed tomography. *JACC Cardiovasc Imaging* 2009;2:556-65.
[PUBMED](#) | [CROSSREF](#)
3. Jilaihawi H, Kashif M, Fontana G, et al. Cross-sectional computed tomographic assessment improves accuracy of aortic annular sizing for transcatheter aortic valve replacement and reduces the incidence of paravalvular aortic regurgitation. *J Am Coll Cardiol* 2012;59:1275-86.
[PUBMED](#) | [CROSSREF](#)
4. Messé SR, Acker MA, Kasner SE, et al. Stroke after aortic valve surgery: results from a prospective cohort. *Circulation* 2014;129:2253-61.
[PUBMED](#) | [CROSSREF](#)
5. Russo A, Grigioni F, Avierinos JF, et al. Thromboembolic complications after surgical correction of mitral regurgitation incidence, predictors, and clinical implications. *J Am Coll Cardiol* 2008;51:1203-11.
[PUBMED](#) | [CROSSREF](#)

6. Hahn RT, Abraham T, Adams MS, et al. Guidelines for performing a comprehensive transesophageal echocardiographic examination: recommendations from the American society of echocardiography and the society of cardiovascular anesthesiologists. *J Am Soc Echocardiogr* 2013;26:921-64.
[PUBMED](#) | [CROSSREF](#)
7. Fatkin D, Kelly RP, Feneley MP. Relations between left atrial appendage blood flow velocity, spontaneous echocardiographic contrast and thromboembolic risk in vivo. *J Am Coll Cardiol* 1994;23:961-9.
[PUBMED](#) | [CROSSREF](#)
8. Romero J, Husain SA, Kelesidis I, Sanz J, Medina HM, Garcia MJ. Detection of left atrial appendage thrombus by cardiac computed tomography in patients with atrial fibrillation: a meta-analysis. *Circ Cardiovasc Imaging* 2013;6:185-94.
[PUBMED](#) | [CROSSREF](#)
9. Palmer S, Child N, de Belder MA, Muir DF, Williams P. Left atrial appendage thrombus in transcatheter aortic valve replacement: incidence, clinical impact, and the role of cardiac computed tomography. *JACC Cardiovasc Interv* 2017;10:176-84.
[PUBMED](#) | [CROSSREF](#)
10. Iwasaki K, Matsumoto T, Kawada S. Potential utility of multidetector computed tomography to identify both cardiac embolic sources and coronary artery disease in patients with embolic stroke. *Cardiology* 2016;133:205-10.
[PUBMED](#) | [CROSSREF](#)
11. Hur J, Kim YJ, Lee HJ, et al. Cardiac computed tomographic angiography for detection of cardiac sources of embolism in stroke patients. *Stroke* 2009;40:2073-8.
[PUBMED](#) | [CROSSREF](#)
12. Ko SB, Choi SI, Chun EJ, et al. Role of cardiac multidetector computed tomography in acute ischemic stroke: a preliminary report. *Cerebrovasc Dis* 2010;29:313-20.
[PUBMED](#) | [CROSSREF](#)
13. Kim IC, Chang S, Hong GR, et al. Comparison of cardiac computed tomography with transesophageal echocardiography for identifying vegetation and intracardiac complications in patients with infective endocarditis in the era of 3-dimensional images. *Circ Cardiovasc Imaging* 2018;11:e006986.
[PUBMED](#) | [CROSSREF](#)
14. Takahashi K, Stanford W. Multidetector CT of the thoracic aorta. *Int J Cardiovasc Imaging* 2005;21:141-53.
[PUBMED](#) | [CROSSREF](#)
15. Yoo J, Song D, Baek JH, et al. Poor outcome of stroke patients with atrial fibrillation in the presence of coexisting spontaneous echo contrast. *Stroke* 2016;47:1920-2.
[PUBMED](#) | [CROSSREF](#)
16. Zhao Y, Ji L, Liu J, et al. Intensity of left atrial spontaneous echo contrast as a correlate for stroke risk stratification in patients with nonvalvular atrial fibrillation. *Sci Rep* 2016;6:27650.
[PUBMED](#) | [CROSSREF](#)
17. Daniel WG, Nellessen U, Schröder E, et al. Left atrial spontaneous echo contrast in mitral valve disease: an indicator for an increased thromboembolic risk. *J Am Coll Cardiol* 1988;11:1204-11.
[PUBMED](#) | [CROSSREF](#)
18. Kupczyńska K, Kasprzak JD, Michalski B, Lipiec P. Prognostic significance of spontaneous echocardiographic contrast detected by transthoracic and transesophageal echocardiography in the era of harmonic imaging. *Arch Med Sci* 2013;9:808-14.
[PUBMED](#) | [CROSSREF](#)