



Effects of Pyrroloquinoline Quinone (PQQ) on Ischemia-Reperfusion Injury in Rat Ovaries: Histological and Biochemical Assessments

Pegah Parhizkar¹, Rahim Mohammadi^{1*}, Rasoul Shahrooz², Vahid Mohammadi³

¹Department of Surgery and Diagnostic Imaging, Urmia University, Urmia, Iran

²Department of Basic Sciences, Urmia University, Urmia University, Urmia, Iran

³Department of Internal Medicine and Clinical Pathology, Urmia University, Urmia, Iran

*Corresponding author: Rahim Mohammadi

Address: Department of Surgery and Diagnostic Imaging, Faculty of Veterinary Medicine, Urmia University, Nazloo Road, Urmia, 57153 1177, Iran.

Tel: +98-441-2770508; Fax: +98-441-2771926

e-mail: r.mohammadi@urmia.ac.ir

Received: July 27, 2018

Revised: October 17, 2018

Accepted: October 20, 2018

ABSTRACT

Objective: To evaluate effects of pyrroloquinoline quinone (PQQ) on ischemia-reperfusion injury using a rat ovary model.

Method: Thirty healthy female Wistar rats with 250g were randomized into five experimental groups (n=6): Group SHAM: The rats underwent only laparotomy. Group Ischemia: A 3- hour ischemia only. Group I/R: A 3-hour ischemia and a 3-hour reperfusion. 30 min before termination of reperfusion 20 μ L soybean oil (Solvent of PQQ) was administered. Group I/PQQ: A 3-hour ischemia only and 20 μ L (10 mg/kg) intraperitoneal administration (IP) of PQQ 2.5 hours after induction of ischemia. Group I/R/PQQ: A 3-hour ischemia, a 3-hour reperfusion and 20 μ L (10 mg/kg) IP of PQQ 2.5 hours after induction of ischemia.

Results: Animals treated with PQQ showed significantly ameliorated development of ischemia and reperfusion tissue injury compared to those of other groups ($p=0.001$). The significant higher values of SOD, GPO and GST were observed in I/R/PQQ animals compared to those of other groups ($p=0.001$). Damage indicator (MDA) was significantly lower in I/R/PQQ animal compared to those of other groups ($p=0.001$).

Conclusion: Intraperitoneal administration of PQQ could be helpful in minimizing ischemia-reperfusion injury in ovarian tissue exposed to ischemia.

Keywords: Ischemia-reperfusion; Pyrroloquinoline quinone (PQQ); Intraperitoneal; Ovary.

Please cite this paper as:

Parhizkar P, Mohammadi R, Shahrooz R, Mohammadi V. Effects of Pyrroloquinoline Quinone (PQQ) on Ischemia-Reperfusion Injury in Rat Ovaries: Histological and Biochemical Assessments . *Bull Emerg Trauma*. 2019;7(1):35-40. doi: 10.29252/beat-070105.

Introduction

There are various conditions like long mesovarium and adnexal venous congestion that could result in torsion of ovary and subsequently obstruction of the ovarian vessels. This causes a life-threatening reduction in tissue blood flow and permanent tissue

damage [1]. Therefore, ovarian torsion must be diagnosed and treated as much early as possible to preserve ovarian functions and prevent future infertility [2]. Upon detection of ovarian torsion, detorsion of the twisted adnexa and evaluation the tissue reperfusion is proposed to prevent future infertility even in case of cyanotic tissues [2, 3].

This ovarian torsion-detorsion process is named as ischemia reperfusion injury [4].

Reperfusion of the ischemic tissue leads to much more serious damage to the tissue than the damage caused by ischemia [5]. Reperfusion-related damage in the cell is created by many factors, mostly including oxygen-derived free radicals, which are rapidly generated in the tissue as a result of reperfusion [6]. Due to physiological or pathological alterations, oxidative damage takes place with changes in favor of the oxidation process [7]. Prompt diagnosis to reduce ischemic and reperfusion injury, and its consequents are still inevitable with this approach. Therefore, studies on preventing reperfusion injury seem very important [8].

A proposed pathogenesis of tissue injury during reperfusion is accumulation of the activated neutrophils that release reactive oxygen species [9]. Lipid peroxidation in the cell is the most deleterious effects of free radicals that end up reduction in the membrane potential and subsequently, cell injury. Malondialdehyde (MDA), one of the end products of lipid peroxidation, also results in serious cell damage through induction of polymerization and cross linking in membrane components [10]. Free oxygen radicals react with DNA and form 8-hydroxyguanine (8-OHGua) that is one of the damage products of DNA [11]. In spite of the fact that generation of free oxygen radicals occurs continuously in cells, the presence of endogenous antioxidant defense systems preserves tissues from the harmful effects of free oxygen radicals [12]. Various agents, anti-inflammatory and antioxidant free radical scavengers have been reported with promising beneficial effects on prevention of ischemic/reperfusion injuries in tissues [13-18]. PQQ acts as an antioxidant and it has been reported that it could inhibit lipid peroxidation injury, increase thymidine incorporation into fibroblasts and increase production of growth factors. In animal models, high doses of PQQ have been reported to protect tissues against hypoxic/ischemic injury [19]. The protective effects of PQQ seem to be generally attributed to its antioxidant properties [20]. PQQ could protect mitochondria from oxidative damage and thereby prevents cell death [21].

The present study was different from the other studies in the literature for using PQQ on ischemia/reperfusion injury. Aimed to study peritoneal effects of PQQ on ischemia/reperfusion injury, a study was designed to determine if PQQ could in fact protect against ischemia/reperfusion induced ovarian damage. The assessments were based on histological and biochemical parameters.

Materials and Methods

Animal Grouping

Two weeks before and during the experiments, the animals were housed in individual plastic cages

with an ambient temperature of (23±3) °C, stable air humidity and a natural day/night cycle. The rats had free access to standard rodent laboratory food and tap water. All measurements were made by two blinded observers unaware of the analyzed groups. The present study was designed and modified based on a method described by others [13]. Thirty healthy female Wistar rats ~250g were randomized into five experimental groups (n=6): Group SHAM: The rats underwent only laparotomy. Group Ischemia: A 3-hour ischemia only. Group I/R: A 3-hour ischemia and a 3-hour reperfusion. 30 min before termination of reperfusion 20 µL soybean oil (Solvent of PQQ) was administered. Group I/PQQ: A 3-hour ischemia only and 20 µL (10 mg/kg) intraperitoneal administration (IP) of PQQ 2.5 hours after induction of ischemia. Group I/R/PQQ: A 3-hour ischemia, a 3-hour reperfusion and 20 µL (10 mg/kg) IP of PQQ 2.5 hours after induction of ischemia. The right ovaries were transferred to a 10% formaldehyde solution for histopathological assessments and the left ovaries were cleaned of surrounding soft tissues and then stored in a freezer at -80 °C for biochemical assessments.

Surgery

Animals were anesthetized by interaperitoneal administration of ketamine-xylazine (ketamine 5%, 90mg/kg and xylazine 2%, 5mg/kg). The procedure was carried out based on the guidelines of the Ethics Committee of the International Association for the Study of Pain [22]. The ethical Committee of the Urmia University of Medical Sciences approved all the experiments. A longitudinal midline incision was made in the lower abdomen and the uterine horns and adnexa were exposed. For induction of ischemia, a vascular clamp was applied on vessels of the ovaries in rats. After a 3-hour period of ischemia, both ovaries were surgically dissected out for histopathological and biochemical assessments. For induction of ischemia/reperfusion, both ovaries underwent ischemia the same way and at the end of a 3-hour period, the vascular clamps were chosen, removed and a 3-hour reperfusion was continued. Then, the ovaries were dissected out for histopathological and biochemical assessments.

Histology

Ovaries were fixed in 10% buffered formalin for 24 hours. The tissue samples were then processed and embedded in paraffin. A 5-µm semi-thin section was paraffin-embedded. The samples were then dewaxed, rehydrated and stained routinely with hematoxylin and eosin. The sections were then observed under a light microscope. For semithin sections, ovaries were fixed in 2.5% buffered glutaraldehyde and post fixed in 2% OsO₄ for 2 h, dehydrated through an ethanol series and were next stained with hematoxyline eosin and examined under a light microscope.

Biochemistry

The tissue samples of ovaries were kept at -80°C for 3 days, and then enzyme activities were determined in rat ovary tissues. The ovary tissues were ground with liquid nitrogen in a mortar. One half gram was weighed for each group and then treated with 4.5 mL of an appropriate buffer. This mixture was homogenized on ice with use of an ultra-turrax homogenizer (IKA, Werke, Germany) for 15 minutes. Homogenates were filtered and centrifuged by using a refrigerator centrifuge at 4°C . Then the supernatants were used to determine the enzymatic activities. All assays were carried out at room temperature. Superoxide dismutase estimation was based on the generation of superoxide radicals produced by xanthine and the xanthine oxidase system, which reacts with nitroblue tetrazolium to form formazan dye [23]. Superoxide dismutase activity was then measured at 560 nm by the degree of inhibition of this reaction and is expressed as millimoles per minute per milligram of tissue. Concentrations of ovarian lipid peroxidation were determined by estimating MDA using the thiobarbituric acid test [24]. The rat ovaries were rinsed with cold saline. The corpus mucosa was scraped, weighed, and homogenized in 10 ml of 100 g/l KCl. The homogenate (0.5 ml) was added to a solution containing 2-thiobarbiturate (1.5 ml of 8 g/l), acetic acid (1.5 ml of 200 g/l), sodium lauryl sulfate (0.2 ml of 80 g/l), and distilled water (0.3 ml). The mixture was incubated at 98°C for 1 hr. n-butanol:pyridine 5 ml (ratio:15:1) was then added. The mixture was vortexed for 1 min and centrifuged for 30 min at 4000 rpm. The absorbance of the supernatant was measured at 532 nm using a spectrophotometer. The standard curve was obtained by using 1,1,3,3-tetramethoxypropane. GPO activity was determined according to the method of Lawrence and Burk [25]. After tissue homogenization, supernatant was used for GPO measurement. Following the addition of KH_2PO_4 , EDTA, GSH, B-NADPH, NaN_3 , and GR, the mixture was incubated. As soon H_2O_2 was added the chromometer was turned on and the absorbance at 340 nm was recorded for 5 min every 15 sec.

GST activity was determined by Habig and Jakoby [26]. Enzyme activity was determined in a 4-ml cuvette containing 30 mM GSH, 30 mM 1-chloro-2,6-dinitrobenzene, 0.1 M PBS (pH: 6.5), and tissue homogenate at 340 nm using a spectrophotometer.

Statistical Analysis

Experimental results were expressed as means \pm SD. Statistical analyses were performed using PASW 18.0 (SPSS Inc., Chicago, IL, USA). Model assumptions were evaluated by examining the residual plot. Results were analyzed using repeated measures and a factorial ANOVA with two between-subject factors. Bonferroni test for pairwise comparisons was used to examine the effect of time and treatments. The differences were considered significant when $p < 0.05$.

Results

Histology

The histologic design of the ovarian tissue in the SHAM animals was normal. Ovarian tissues in the ischemia group showed condensed hemorrhage and severe vascular congestion along with degenerative and necrotic changes in many of the cells. The tissues in the I/R group showed histopathological changes of condensed hemorrhage, infiltration of inflammatory cells along with degenerative and apoptotic cells. Polymorphonuclear leukocytes (neutrophils) were dominant cell types. In I/R/PQQ group general histologic and cellular structures of the tissues were not normal in appearance, however, mild vascular congestion and edema were observed. In I/R/PQQ group only a slightly mild hemorrhage was around ovarian follicles. The general histologic structure of the ovarian tissue in this group was normal and no important pathologic findings in the structural level were observed except for only a slightly mild inflammation, vascular congestion and edema (Figure 1).

Biochemistry

The values of SOD were decreased in I and I/R groups. However, interaperitoneal administration

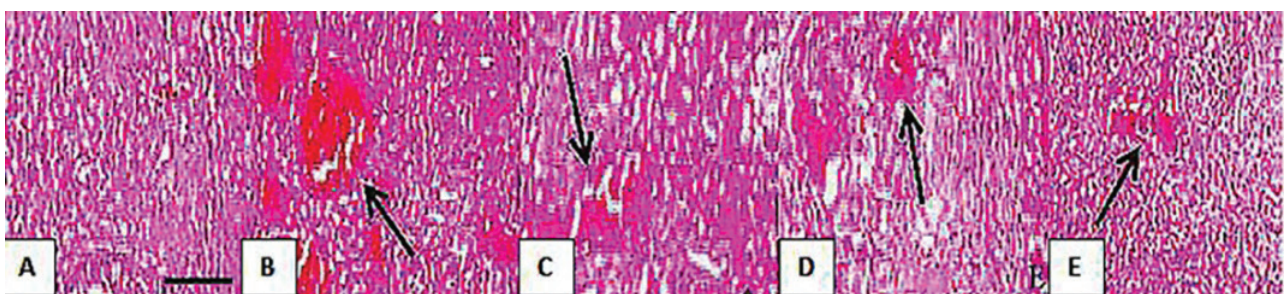


Fig. 1. Histologic micrographs of the ovarian tissue in SHAM (A), I (B), I/R (C), I/PQQ(D), I/R/PQQ (E) groups. (A) Shows normal secondary follicles with compact stroma between them. (B) Many follicles at different stages of development are observed. Edematous ovarian stroma and multiple dilated congested blood vessels with some areas of hemorrhage are shown. (C) Ovarian follicles at different stages of development with edema in the stroma and hemorrhage are observed. (D) Many follicles at different stages of development are seen. There is edematous ovarian stroma and multiple dilated congested blood vessels with some areas of hemorrhage. (E) Normally appearing ovarian tissue with preserved healthy follicles at different stages of development with slight edema or hemorrhage is observed. Scale bar: 200 μm

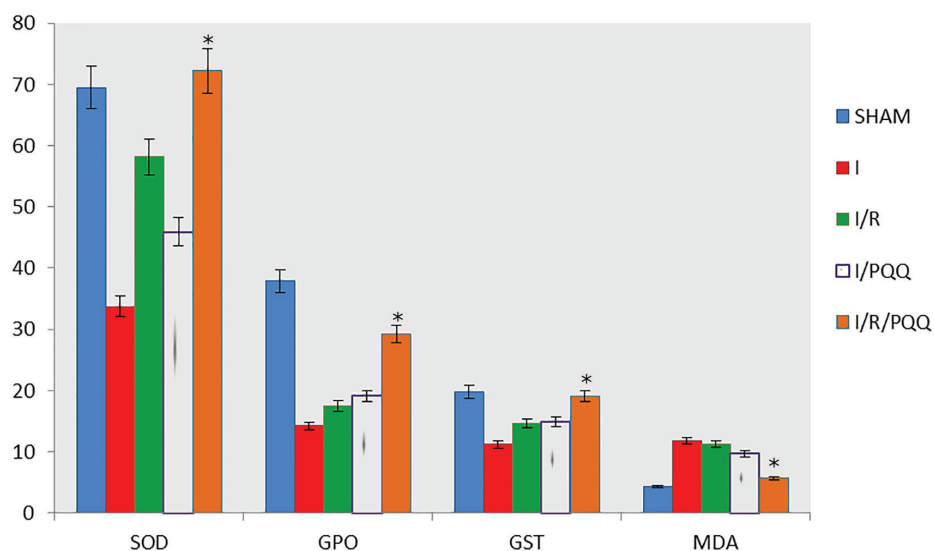


Fig. 2. Bar graph shows comparison of the activities of SOD, GPO, GST and MDA in the ovarian tissues of the animals of the all experimental groups. Data are expressed as Mean±SD.

* $p=0.001$ vs. I, I/R and I/PQQ groups.

of PQQ inverted the trend and increased the activity of SOD in the ovarian tissue in PQQ treated group. The value of SOD activity in I/R/PQQ group was significantly higher than those of the other experimental groups ($p=0.001$). The MDA level I/R group was significantly increased ($p=0.001$). Intraperitoneal administration of PQQ significantly decreased level of MDA in ovarian tissues of PQQ treated animals ($p=0.001$). Intraperitoneal administration of PQQ significantly increased level of GPO in ovarian tissues of PQQ treated animals ($p=0.001$). Intraperitoneal administration of PQQ significantly increased level of GST in ovarian tissues of PQQ treated animals ($P=0.001$) (Figure 2).

Discussion

The present study it was investigated whether intraperitoneally administration of α -tocopherol loaded nanoparticles is useful or not in the prevention of ovarian damage in ischemia/reperfusion conditions in rat ovaries and it was found to have beneficial effects. Histopathological and biochemical assessments were performed in SHAM, ischemia, ischemia-reperfusion, ischemia-controlled plus intraperitoneal administration of α -tocopherol loaded nanoparticles groups. Histopathological, edema, vascular congestion, hemorrhages and leukocyte infiltration parameters were used. Ischemia, ischemia-reperfusion and intraperitoneal PQQ applied to tissues were analyzed histologically. Results showed that oxidative stress level followed a parallelism with the tissue damage. Edema, vascular congestion, hemorrhages, and leukocyte infiltration have been used as histopathological parameters in the evaluation of the condition of the cell [27]. Edema, vascular congestion, hemorrhage, and leukocyte infiltration in the PQQ treated animals were milder.

In the present study, levels of SOD in ovarian tissue were assessed and compared in all the experimental groups. SOD is an antioxidant enzyme that catalyzes the conversion of superoxide free radical into hydrogen peroxide and molecular oxygen. SOD and endogenous antioxidant enzymes neutralize free radicals and protect tissues from the harmful effects of free radicals and active oxygen species [28]. Our results showed that in the PQQ treated animals, SOD was increased compared to that in I/R group and intraperitoneal administration of PQQ, secured ovarian tissue against ischemia-reperfusion injury. MDA is a lipid peroxidation product and occurs as a result of the peroxidation of fatty acids that contain three or more double bonds. MDA causes cross-linking of membrane components and leads to negative consequences like changes in ion permeability and enzyme activity via affecting the ion exchange through the cell membranes [29, 30]. MDA levels in the present study were found to be much lower in the PQQ treated animals compared to those in other experimental groups. This could protect the tissues against ischemia-reperfusion injury in PQQ treated animals. GPO activity is significantly reduced in tissues undergoing oxidative stress-related conditions like ischemia-reperfusion injury [31]. GPO detoxifies the hydrogen peroxide radical that forms in the cell by converting it to water and prevents the formation of more toxic products from hydrogen peroxide radical [32]. In the present study a significant decrease in GPO activity was observed in ovarian tissues of PQQ treated animals. GST binds foreign substances to the -SH group of cysteine in glutathione, neutralizes the electrophilic regions and protects the cells from the harmful effects of foreign substance regions [33]. Activity of GST has been reported to be suppressed in oxidative tissue injury induced by ischemia [33]. Consistently,

our findings showed that GST activity in ovarian tissue of PQQ treated animals was significantly lower than that in I/R group.

There are many studies in the literature about the improvement of ischemia reperfusion injury. Studies demonstrated that the agents with antioxidant or anti-inflammatory activities may be beneficial in reducing ovarian ischemia reperfusion injury. Also, studies revealed the beneficial effect of controlled reperfusion in the prevention of ovarian tissue damage. Although there are many studies in the literature; ischemia/reperfusion damage continues to be a serious problem clinically. Essentially, early diagnosis and treatment of ovarian torsion plays an important role to provide urgent protection against life-threatening complications from ischemia and to prevent future infertility [34].

It has been indicated that PQ is non-toxic to mitochondria and is an effective antioxidant. PQQH₂ appears to be produced (via reduction) from PQQ when in a buffer in the presence of glutathione and this process is known to use the semiquinone (PQQH) as an intermediate exposure to oxygen either by ambient atmosphere or by singlet oxygen readily oxidizes PQQH₂ back into PQQ. This suggests that glutathione is capable of recycling PQQ as an antioxidant [35].

Substances are administered by a wide variety of routes. A key factor determining the route selected is whether the agent is being administered for a local or systemic (either enteral or parenteral effect). Parenteral administration methods typically produce the highest bioavailability of substances because these methods avoid the first-pass effect of

hepatic metabolism, which occurs commonly with orally administered chemicals and therapeutics [36]. Intraperitoneal administration seems more effective and available where oral administration of an agent may cause difficulties. It is clear that transperitoneal absorption of the agent is far faster than oral administration [36]. It seems time saving is very important in emergency conditions like ovarian torsion.

In conclusion, histopathological results obtained from all the experimental groups were consistent with the results of the biochemical analyses indicating that intraperitoneal administration of PQQ could be helpful in minimizing ischemia-reperfusion injury in ovarian tissue exposed to ischemia. Regarding the transperitoneal absorption of the PQQ that is far faster than its oral administration, it could be considered in clinical practice where that ovarian torsion is the case and ovarian functions must be resumed as early as possible to preserve and prevent future infertility. The present study demonstrated that intraperitoneal administration of PQQ could improve ischemia-reperfusion injury in ovarian tissue exposed to ischemia.

Acknowledgment

This work was fully supported by grants (No.95-D-001) and date: June 20, 2016 from Vice-Chancellor for Research and Technology of Urmia University that is acknowledged by the authors.

Conflicts of Interest: None declared.

References

- Oelsner G, Shashar D. Adnexal torsion. *Clin Obstet Gynecol.* 2006;**49**(3):459-63.
- Geimanaite L, Trainavicius K. Ovarian torsion in children: management and outcomes. *J Pediatr Surg.* 2013;**48**(9):1946-53.
- Celik A, Ergün O, Aldemir H, Ozcan C, Ozok G, Erdener A, et al. Long-term results of conservative management of adnexal torsion in children. *J Pediatr Surg.* 2005;**40**(4):704-8.
- Carden DL, Granger DN. Pathophysiology of ischaemia-reperfusion injury. *J Pathol.* 2000;**190**(3):255-66.
- Zimmerman BJ, Granger DN. Reperfusion injury. *Surg Clin North Am.* 1992;**72**(1):65-83.
- Nakagiri A, Sunamoto M, Takeuchi K. Evidence for the involvement of NADPH oxidase in ischemia/reperfusion-induced gastric damage via angiotensin II. *J Physiol Pharmacol.* 2010;**61**(2):171-9.
- Javanmardi S, Khordadmehr M. Benidipine reduces ischemia/reperfusion injury following testicular torsion/detorsion in rats. *Iranian Journal of Veterinary Surgery.* 2017;**12**(2):21-30.
- Ingec M, Isaoglu U, Yilmaz M, Calik M, Polat B, Alp HH, et al. Prevention of ischemia-reperfusion injury in rat ovarian tissue with the on-off method. *J Physiol Pharmacol.* 2011;**62**(5):575-822.
- Filho DW, Torres MA, Bordin AL, Crezcynski-Pasa TB, Boveris A. Spermatic cord torsion, reactive oxygen and nitrogen species and ischemia-reperfusion injury. *Mol Aspects Med.* 2004;**25**(1-2):199-210.
- Girotti AW. Lipid hydroperoxide generation, turnover, and effector action in biological systems. *J Lipid Res.* 1998;**39**(8):1529-42.
- Huang HY, Helzlsouer KJ, Appel LJ. The effects of vitamin C and vitamin E on oxidative DNA damage: results from a randomized controlled trial. *Cancer Epidemiol Biomarkers Prev.* 2000;**9**(7):647-52.
- Ames BN, Shigenaga MK, Hagen TM. Oxidants, antioxidants, and the degenerative diseases of aging. *Proc Natl Acad Sci USA.* 1993;**90**(17):7915-22.
- Oral A, Odabasoglu F, Halici Z, Keles ON, Unal B, Coskun AK, et al. Protective effects of montelukast on ischemia-reperfusion injury in rat ovaries subjected to torsion and detorsion: biochemical and histopathologic evaluation. *Fertil Steril.* 2011;**95**(4):1360-6.
- Mogilner JG, Lurie M, Coran AG, Nativ O, Shiloni E, Sukhotnik I. Effect of diclofenac on germ cell apoptosis following testicular ischemia-reperfusion injury in a rat. *Pediatr Surg Int.* 2006;**22**(1):99-105.
- Halici Z, Karaca M, Keles ON, Borekci B, Odabasoglu F, Suleyman H, et al. Protective effects of amlodipine on ischemia-reperfusion injury of rat ovary: biochemical and histopathologic evaluation. *Fertility and sterility.* 2008;**90**(6):2408-15.
- Anderson AM, Mitchell MS, Mohan RS. Isolation of curcumin from

- turmeric. *Journal of Chemical Education*. 2000;**77**(3):359.
17. Hashemnia S, Oloumi MM, Rezayan M, Derakhshanfar A, Mostafavi A, Hojabri K, et al. Persian Sage (*Salvia Rhytidia*) Essential Oil can Ameliorate the Renal Ischemia-Reperfusion Injuries in Rat. *Iranian Journal of Veterinary Surgery*. 2009;**4**(1):67-76.
 18. Behroozi-Lak T, Zarei L, Moloody-Tapeh M, Farhad N, Mohammadi R. Protective effects of intraperitoneal administration of nimodipine on ischemia-reperfusion injury in ovaries: Histological and biochemical assessments in a rat model. *J Pediatr Surg*. 2017;**52**(4):602-608.
 19. Zhang Y, Rosenberg PA. The essential nutrient pyrroloquinoline quinone may act as a neuroprotectant by suppressing peroxynitrite formation. *European Journal of Neuroscience*. 2002;**16**(6):1015-24.
 20. Rucker R, Chohanadisai W, Nakano M. Potential physiological importance of pyrroloquinoline quinone. *Altern Med Rev*. 2009;**14**(3):268-77.
 21. He K, Nukada H, Urakami T, Murphy MP. Antioxidant and pro-oxidant properties of pyrroloquinoline quinone (PQQ): implications for its function in biological systems. *Biochem Pharmacol*. 2003;**65**(1):67-74.
 22. Zimmermann M. Ethical guidelines for investigations of experimental pain in conscious animals. *Pain*. 1983;**16**(2):109-10.
 23. Sun Y, Larry WO, Ying L. A simple method for clinical assay of superoxide dismutase. *Clin Chem*. 1988;**34**(3):497-500.
 24. Ohkawa H, Ohishi N, Yagi K. Assay for lipid peroxides in animal tissues by thiobarbituric acid reaction. *Anal Biochem*. 1979;**95**(2):351-8.
 25. Lawrence RA, Burk RF. Glutathione peroxidase activity in selenium-deficient rat liver. 1976. *Biochem Biophys Res Commun*. 2012;**425**(3):503-9.
 26. Habig WH, Jakoby WB. Assays for differentiation of glutathione S-transferases. *Methods Enzymol*. 1981;**77**:398-405.
 27. Celik O, Turkoz Y, Hascalik S, Hascalik M, Cigremis Y, Mizrak B, et al. The protective effect of caffeic acid phenethyl ester on ischemia-reperfusion injury in rat ovary. *Eur J Obstet Gynecol Reprod Biol*. 2004;**117**(2):183-88.
 28. Arosio B, Gagliano N, Fusaro LM, Parmeggiani L, Tagliabue J, Galetti P, et al. Aloe-Emodin quinone pretreatment reduces acute liver injury induced by carbon tetrachloride. *Pharmacol Toxicol*. 2000;**87**(5):229-33.
 29. Niki E, Yoshida Y, Saito Y, Noguchi N. Lipid peroxidation: mechanisms, inhibition, and biological effects. *Biochem Biophys Res Commun*. 2005;**338**(1):668-76.
 30. Ximenes VF, Paino IM, Faria-Oliveira OM, Fonseca LM, Brunetti IL. Indole ring oxidation by activated leukocytes prevents the production of hypochlorous acid. *Braz J Med Biol Res*. 2005;**38**(11):1575-83.
 31. Valko M, Rhodes CJ, Moncol J, Izakovic M, Mazur M. Free radicals, metals and antioxidants in oxidative stress-induced cancer. *Chem Biol Interact*. 2006;**160**(1):1-40.
 32. Sharma H, Zhang X, Dwivedi C. The effect of ghee (clarified butter) on serum lipid levels and microsomal lipid peroxidation. *Ayu*. 2010;**31**(2):134-40.
 33. Mansoorali KP, Prakash T, Kotresha D, Prabhu K, Rama Rao N. Cerebroprotective effect of *Eclipta alba* against global model of cerebral ischemia induced oxidative stress in rats. *Phytomedicine*. 2012;**19**(12):1108-16.
 34. Srivastava G, Mehta JL. Currying the heart: curcumin and cardioprotection. *J Cardiovasc Pharmacol Ther*. 2009;**14**(1):22-7.
 35. Mukai K, Ouchi A, Nakano M. Kinetic study of the quenching reaction of singlet oxygen by Pyrroloquinolinequinol (PQQH₂), a reduced form of Pyrroloquinolinequinone) in micellar solution. *J Agric Food Chem*. 2011;**59**(5):1705-12.
 36. Turner PV, Brabb T, Pekow C, Vasbinder MA. Administration of Substances to Laboratory Animals: Routes of Administration and Factors to Consider. *J Am Assoc Lab Anim Sci*. 2011;**50**(5):600-13.

Open Access License

All articles published by Bulletin of Emergency And Trauma are fully open access: immediately freely available to read, download and share. Bulletin of Emergency And Trauma articles are published under a Creative Commons license. Mandated authors will be offered CC-BY; all other authors will choose between CC-BY, CC-BY-NC and CC-BY-NC-ND.