

cause of TF: folliculitis decalvans, central centrifugal cicatricial alopecia (CCCA), pemphigus vulgaris, folliculitis keloidalis, dissecting cellulitis, lichen planopilaris, discoid lupus, and tinea capitis.<sup>3</sup> TF has already been described in a patient treated with cyclosporine and in two women having chemotherapy to treat breast cancer, one using lapatinib and the other, trastuzumab.

One cause of confusion is that most authors use the terms TF and polytrichia as synonyms.<sup>3</sup> Polytrichia is defined as multiple (5 or more) hairs emerging from the same follicular opening. By defining TF only according to this pattern, it is easy to understand it just as a final stage of different diseases. Under this perspective, the use of the two terms for the same condition is a cause for confusion. The term TF could be abolished from the medical vocabulary in favor of polytrichia, which is semantically more appropriate.

However, the authors who see TF as a specific diagnosis understand that the term could not be used for all the patients with polytrichia, but should be reserved just for those cases of inflamed hair scalp with pustules that grow *S. aureus* (as in Smith's original description). As such, TF would be a subset of folliculitis decalvans.<sup>4</sup>


Despite this controversy, TF is frequently observed in patients with folliculitis decalvans. In a retrospective multicenter review study with 82 patients with folliculitis decalvans, 88% of them presented with TF.<sup>5</sup> Huge tufts with more than 10 hairs are characteristic of this condition. □

#### REFERENCES

1. Smith NP. Tufted folliculitis of the scalp. *J R Soc Med.* 1978;71:606-8.
2. Annessi G. Tufted folliculitis of the scalp: a distinctive clinicohistological variant of folliculitis decalvans. *Br J Dermatol.* 1998;138:799-805.
3. Sperling LC, Cowper S, Knopp EA. *An Atlas of Hair Pathology with Clinical Correlations.* 2nd ed. Boca Raton: CRC Press; 2012.
4. Powell J, Dawber RP. Folliculitis decalvans and tufted folliculitis are specific infective diseases that may lead to scarring, but are not a subset of central centrifugal scarring alopecia. *Arch Dermatol.* 2001;137:373-4.
5. Vañó-Galván S, Molina-Ruiz AM, Fernández-Crehuet P, Rodrigues-Barata AR, Arias-Santiago S, Serrano-Falcón C, et al. Folliculitis decalvans: a multicentre review of 82 patients. *J Eur Acad Dermatol Venereol* 2015; 29:1750-7.


#### AUTHORS' CONTRIBUTIONS

Paulo Müller Ramos

 ORCID 0000-0002-1561-414X

Approval of the final version of the manuscript; Conception and planning of the study; Elaboration and writing of the manuscript; Obtaining, analyzing and interpreting the data; Intellectual participation in propaedeutic and/or therapeutic conduct of the cases studied; Critical review of the literature; Critical review of the manuscript

Helio Amante Miot

 ORCID 0000-0002-2596-9294

Approval of the final version of the manuscript; Elaboration and writing of the manuscript; Critical review of the literature; Critical review of the manuscript

**How to cite this article:** Ramos PM, Miot HA. Exuberant tufted folliculitis. *An Bras Dermatol.* 2019;94(1):115-6.

*An Bras Dermatol.* 2019;94(1):105-21.

## Follicular psoriasis: an underdiagnosed entity?\*

Bruno de Castro e Souza<sup>1</sup>

Luisa Groba Bandeira<sup>1</sup>

Thais do Amaral Carneiro Cunha<sup>1</sup>

Neusa Yuriko Sakai Valente<sup>1</sup>

DOI: <http://dx.doi.org/10.1590/abd1806-4841.20197987>

Dear Editor,

Psoriasis is one of the most common inflammatory dermatoses and, in most patients, presents with erythematous scaling plaques on extensor areas. Classically, several clinical subtypes are described, such as plaque, inverted, guttate, palmoplantar, erythrodermic, and pustular. A minor variant discussed and reported is follicular psoriasis (FP), with only 25 reports in the international literature to date. Thus, the present article describes the first Brazilian case and revises concepts of this little known entity.

A 58-year-old female diabetic type 2 patient presented with erythematous, keratotic, exclusively follicular non-pruritic papules measuring 2-3mm in diameter. The lesions were generalized, but with higher density in the gluteal and proximal regions of the thighs (Figures 1 and 2). Still, few isolated follicular pustules could be seen. Palms of the hands and soles of the feet were unchanged. The lesions appeared 4 years ago in the lower limbs with later gradual spread. Diagnostic hypotheses were pityriasis rubra pilaris (PRP) and keratosis pilaris with secondary infection. Previous histopathological examination of biopsy specimens revealed a diagnosis of follicular porokeratosis. Histopathological review showed parakeratosis and numerous intact and degenerate neutrophils within the lumens and in the epithelium of the follicular isthmus, where they formed a spongiform pustule. In addition, mild regular perifollicular acanthosis was also present (Figure 3). Grocott's staining

Received 16 December 2017.

Accepted 19 April 2018.

\* Work conducted at Hospital do Servidor Público do Estado de São Paulo, São Paulo (SP), Brazil.

Financial support: None.

Conflict of interest: None.

<sup>1</sup> Department of Dermatology, Hospital do Servidor Público do Estado de São Paulo, São Paulo (SP), Brazil.

MAILING ADDRESS:

Bruno de Castro e Souza

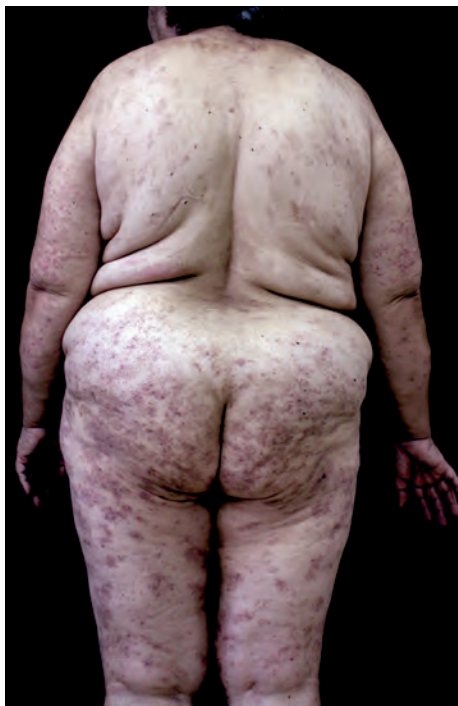E-mail: brunocastro1990@hotmail.com

©2019 by Anais Brasileiros de Dermatologia

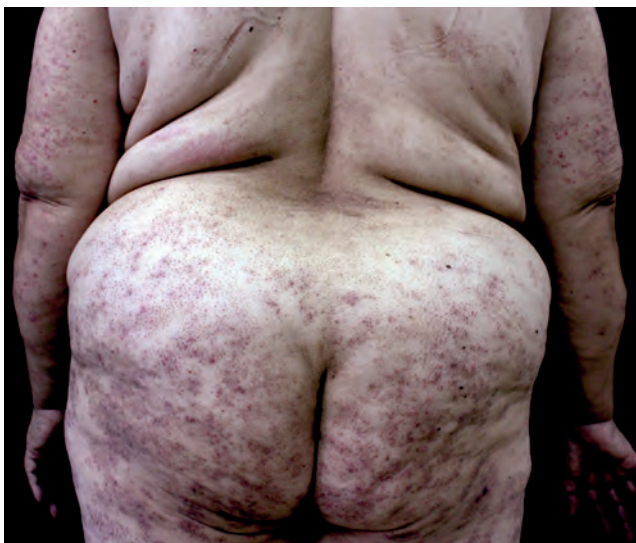

revealed no fungal elements. We decided to use cephalexin for 10 days as a therapeutic test for primary bacterial folliculitis or impetiginization with no success. A second biopsy was also performed with similar results to the first. Confronting clinical and histopathological findings, we concluded by the diagnosis of follicular psoriasis. We started treatment with acitretin with improvement after 2 months.

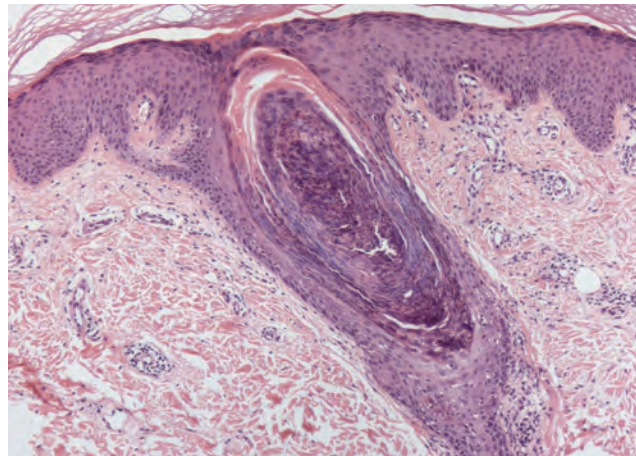
Although FP was first described in 1920 by McLeod, only 25 cases were reported in the literature.<sup>1</sup> The largest series of cases,



**FIGURE 1:** Erythematous, keratotic, exclusively follicular papules, 2-3mm in diameter



**FIGURE 2:** Detail of follicular papules



**FIGURE 3:** Numerous intact and degenerate neutrophils within the lumen and in the epithelium of the follicular isthmus. Mild perifollicular acanthosis is also present (Hematoxylin & eosin, x100)

published in 1981 by Stankler and Ewen, served as the basis for the division into adult and child types.<sup>2</sup> The former has a predilection for black and diabetic women, with follicular papules concentrated mainly on the thighs, while the latter presents itself with follicular keratotic papules located on bony prominences or with disseminated lesions simulating PRP. More recently, Cuong *et al.* surveyed the published cases and found that 78% of the patients reported were black, corroborating the classic description.<sup>3</sup> FP follows a chronic course with some authors suggesting that it may be an early stage of psoriasis since it may evolve into other forms of the disease.<sup>4</sup> The clinical picture of our patient fulfills the criteria of adult-type follicular psoriasis since, besides her high pigmentation level and diabetes, the most affected areas were the thighs.





The predominant histopathological findings are parakeratosis with neutrophils, as well as acanthosis of the infundibular epithelium with hypogranulosis. Both clinically and mainly histopathologically, infected follicular keratosis is an important differential diagnosis. However, onset age of 54 years makes this possibility unlikely. In addition, regarding the histopathology of FP, Arps *et al.* (2013) suggest that minimal spongiosis, little serosity in the parakeratotic scale, and sparse perifollicular inflammation, as seen in our patient, differentiate FP from bacterial folliculitis.<sup>5</sup> A clinical alternative to differentiate FP from bacterial folliculitis is the therapeutic test with antibiotics. In cases of FP, as in our patient, no improvement is observed.

We believe that psoriasis - like other dermatoses, such as lichen planus, follicular porokeratosis, and atopic dermatitis - also has a follicular variant. It is likely that follicular involvement in psoriasis is neglected, especially in countries such as Brazil, where a large part of the population is of African descent. □

## REFERENCES

1. Mercado JOC, Lopez LEB, Wolosky OC, Ordiales LL, Caire ST. Follicular psoriasis: A forgotten entity. *J Am Acad Dermatol*. 2017;76(Suppl 1):AB141.
2. Stankler L, Ewent SWB. Follicular psoriasis. *Br J Dermatol*. 1981;104:153-6.
3. Nguyen CV, Farah RS, Maguiness SM, Miller DD. Follicular Psoriasis: Differentiation from Pityriasis Rubra Pilaris—An Illustrative Case and Review of the Literature. *Pediatr Dermatol* 2017;34:65-8.
4. Babino G, Moscarella E, Longo C, Lallas A, Ferrara G, Cusano F, et al. Follicular psoriasis: an under-recognized condition. *J Eur Acad Dermatol Venereol*. 2016;30:1397-9.
5. Arps DP, Chow C, Lowe L, Chan MP. Follicular Psoriasis. *J Cutan Pathol*. 2013;40:859-62.

## AUTHORS' CONTRIBUTIONS

Bruno de Castro e Souza	 ORCID 0000-0001-7140-3462
Elaboration and writing of the manuscript; Obtaining, analyzing and interpreting the data; Critical review of the literature	
Luisa Groba Bandeira	 ORCID 0000-0003-0602-1016
Elaboration and writing of the manuscript; Obtaining, analyzing and interpreting the data; Critical review of the literature	
Thais do Amaral Carneiro Cunha	 ORCID 0000-0002-8092-1277
Approval of the final version of the manuscript; Conception and planning of the study; Intellectual participation in propaedeutic and/or therapeutic conduct of the cases studied; Critical review of the manuscript	
Neusa Yuriko Sakai Valente	 ORCID 0000-0002-8065-2695
Approval of the final version of the manuscript; Conception and planning of the study; Effective participation in research orientation; Intellectual participation in propaedeutic and/or therapeutic conduct of the cases studied; Critical review of the manuscript	

**How to cite this article:** Souza BC, Bandeira LG, Cunha TAC, Valente NYS. Follicular psoriasis: an underdiagnosed entity? *An Bras Dermatol*. 2018;94(1):116-8.

## Successful management of chronic refractory onycholysis by partial nail avulsion followed by topical tretinoin\*

Pedro Colli Rocha Dias<sup>1</sup>  
Anna Carolina Miola<sup>1</sup>  
Helio Amante Miot<sup>1</sup>

DOI: <http://dx.doi.org/10.1590/abd1806-4841.20198009>

Received 19 December 2017.

Accepted 02 April 2018.

\* Work conducted at the Department of Dermatology and Radiotherapy, Faculdade de Medicina de Botucatu, Universidade Estadual Paulista, Botucatu (SP), Brazil.  
Financial support: None.  
Conflict of interest: None.

<sup>1</sup> Department of Dermatology and Radiotherapy, Faculdade de Medicina de Botucatu, Universidade Estadual Paulista, Botucatu (SP), Brazil.

MAILING ADDRESS:

Anna Carolina Miola  
E-mail: [anna\\_fmrip@yahoo.com.br](mailto:anna_fmrip@yahoo.com.br)

©2019 by Anais Brasileiros de Dermatologia



Dear Editor,

Onycholysis is a common complaint in dermatologic clinics and consists of the separation of the nail plate from its distal bed. Due to its several etiologies (e.g. onychomycosis, neoplasia, trauma, contact dermatitis, psoriasis, lichen planus, and medications), it requires an intensive semiological practice and clinical suspicion prior to the definition of its therapeutic strategy.<sup>1</sup>

Chronic onycholysis leads to keratinization of the nail bed and may cause a disappearing nail bed, defined as the shortening of the nail plate by more than 20% compared to an unaffected contralateral finger. In addition, subclinical bacterial proliferation may occur (e.g. *Pseudomonas sp.*), which makes chronic onycholysis even more challenging.<sup>2,3</sup>

This is the first report of successful treatment of chronic onycholysis by surgical avulsion of the onycholytic portion of the nail, followed by the application of topical tretinoin on the nail bed.

A 49-year-old female patient, without comorbidities or use of medications, presented with yellow-greenish fingernail discoloration of the right third finger, and shortening of the nail plate of the right first finger six years ago (Figure 1). The patient showed no improvement after successive previous oral (fluconazole) and topical (ketoconazole 2% cream and ciprofloxacin 0.3% eye drops) treatments. Mycological examination, culture, and nail clipping were all negative, leading to the hypothesis of chronic onycholysis and disappearing nail bed. Our therapeutic option was avulsion of the affected area (Figure 2) and daily treatment with tretinoin 0.025% gel on both nail beds, which resulted in complete improvement of the condition at a three-month follow-up (Figure 3).

Since onychomycosis represents the main cause of onycholysis and demands a long term specific treatment with potential toxicity, diagnostic investigation of onycholysis should be conducted with direct mycological exams, culture, and nail clipping.<sup>4</sup> Dermoscopy and biopsy of nail plate and nail bed are additional elements for the diagnostic investigation.

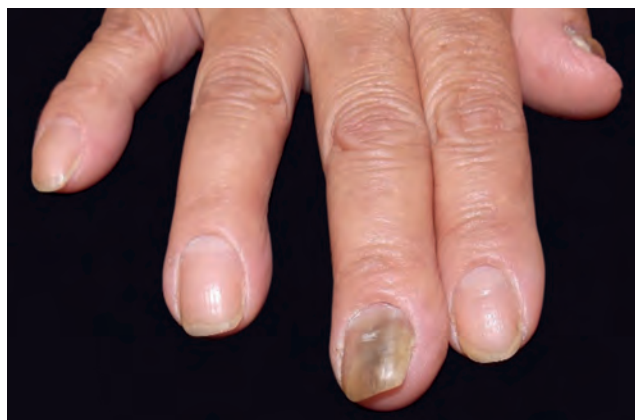

FIGURE 1: Onycholysis with yellowish-green discoloration suggesting underlying bacterial proliferation