



Published in final edited form as:

Kidney Int. 2012 January ; 81(2): 129–131. doi:10.1038/ki.2011.374.

Recipe for a new imaging biomarker: carefully combine target, reagent, and technology

Hisataka Kobayashi¹ and Peter L. Choyke¹

¹Molecular Imaging Program, Center for Cancer Research, National Cancer Institute, National Institutes of Health, Bethesda, Maryland, USA

Abstract

A careful combination of biological targeting moieties (C3 fragments), imaging reagents (a small particle of iron oxide), and appropriate technology (T2-weighted magnetic resonance imaging) is the key to the successful development of an imaging agent for glomerulonephritis. This recipe applies to virtually any molecular imaging probe for the kidney and throughout the body. However, each organ and disease requires a unique combination of these three components in order to achieve success.

Kidney biopsy is the traditional method of diagnosing glomerulonephritis. However, there is a growing understanding that noninvasive imaging biomarkers could replace, or at least reduce the need for, biopsy. Imaging has the advantage that it is noninvasive and, therefore, could be repeatedly used to evaluate disease status. Rapid progress has been made in molecular imaging, which makes possible targeted probes that could only be hypothesized a decade ago. Nevertheless, in reality, there are few examples of successful molecular probes for specific diseases. Even fewer have been reported with magnetic resonance imaging (MRI), despite its inherent advantage of not using ionizing radiation. Unfortunately, MRI suffers from lower sensitivity compared with radionuclide methods. Sargsyan *et al.*¹ (this issue) report the development of just such a new MRI biomarker and demonstrate its utility in a lupus nephritis model. It uses a targeting agent for C3 activation fragments conjugated to an iron oxide particle that binds C3 fragments in sufficient quantities to be detected by MRI. By carefully selecting the biological target (C3 activation fragments), combining it with an imaging agent (small iron oxide nanoparticles), and using appropriate imaging technology (T2-weighted MRI), the authors demonstrate the feasibility of developing a potentially useful imaging biomarker for clinical application. Their experience holds important lessons for those seeking to develop novel imaging biomarkers.

The challenges facing the development of such an agent are formidable. Glomerulonephritis is easily masked by the excretion of imaging contrast agents, which is often by way of the

Correspondence: Hisataka Kobayashi, Molecular Imaging Program, National Cancer Institute /NIH, Building 10, Room B3B69, MSC 1088, Bethesda, Maryland 20892-1088, USA., Kobayash@mail.nih.gov.

DISCLOSURE

The authors declared no competing interests.

kidney. A fundamental principle of imaging is that in order to localize abnormal signal, it is first necessary to visualize the background anatomy in high spatial resolution but with relatively homogeneous low background signal, so that any abnormality stands out like a star against a black sky. From this point of view, MRI is an appropriate choice because it displays the normal kidney at high resolution with relatively homogeneous signal on both T1- and T2-weighted sequences.^{2,3} The next challenge is to deliver the agent to the kidney such that nonspecific accumulation can be differentiated from binding to the target molecule. The targets in this case are deposits of C3 activation fragments, located in and around the glomerulus. High blood flow to the glomerulus ensures that delivery of the agent will be rapid and efficient. However, in order to obtain specific signal from the target, the unbound imaging agent must be rapidly cleared from the kidney. Since the major function of the glomeruli is filtration of small molecules, the kidneys are often the main route of excretion of imaging agents, even when they are several nanometers in diameter.^{4,5} Renal excretion causes increased background signal and will mask the signal from the bound imaging agent. Even if the agent is not cleared rapidly and remains in the blood pool with long circulation times, it can produce background signal that will interfere with target-specific signal. Over time, such blood pool agents will leak from the vessels and cause nonspecific background signal in the interstitial fluid, where they are engulfed by macrophages and dendritic cells. For this application, most gadolinium-based contrast agents are too small and will rapidly be excreted. Ultrasmall nanoparticles of iron oxide (USPIOs), which are considerably larger than gadolinium chelates (20–30 nm in diameter), have been used to demonstrate inflammatory foci in the kidney induced by ischemia and reperfusion injury based on activated phagocytosis of USPIOs by tissue macrophages.² Even larger molecules such as small particles of iron oxide (SPIOs, about 200 nm in diameter) have the added advantage of clearance through the liver instead of the kidney but still can leak into areas of glomerulonephritis, where they can bind C3 activation fragments with relatively low background signal. Thus, by carefully combining targeting molecules for C3 activation fragments (biological target) with an SPIO platform (chemical agent), and detecting pathological signal on T2-weighted MRI (imaging technology), a successful imaging biomarker was designed (Figure 1). It is important to understand that this design is well suited for targets located in and around the glomerulus but might not work as well for targets away from the glomerulus, including in the proximal and distal tubules. For such targets, nanomaterial-based imaging agents must be flexibly designed to fit a specific target.

There are important lessons here for the design of imaging agents for other organs. Different sites of the body have distinct physiology, blood supply, and tissue composition; therefore, each imaging agent must be uniquely designed based on the proper target, reagent, and imaging modality.⁶ However, thinking beyond the current ‘one probe, one disease’ paradigm, there are expanding efforts to develop multiplexed⁷ and activatable signaling.⁸ Multiplexed imaging refers to techniques that yield multiple distinct data sets from a single imaging session. Three general strategies for multiplexed imaging have been proposed: (1) multiple modality, in which two (or more) distinct imaging modalities are simultaneously or consecutively used; (2) multiple color imaging agents, in which multiple different agents, with distinct energies (colors), are simultaneously imaged by a single modality; and (3) multiple signal collection, in which a single modality can detect and interpret multiple

signals obtained with distinct signaling technologies. Activatable signaling uses ‘smart’ reagents that emit signal in target tissue only after cellular internalization or other triggering events.^{9,10} Multiplexed and activatable strategies overcome the limitations of a single modality or a single target. For instance, there is usually a trade-off between anatomic resolution and sensitivity such that combining a high-sensitivity technique (such as positron emission tomography scanning) with a high-resolution technique (such as computed tomography scanning) makes sense. Similarly, one target provides a limited amount of information, whereas a profile of targets provides more enriched information. However, even with multiplexing, the basics remain the same: the target, reagent, and imaging modality must be carefully chosen to maximize the utility of the probe. Even for multiplexing, each one of the imaging agents and modalities should be designed carefully and work appropriately. Thus, the imaging agent designed by Sargsyan *et al.*¹ is quite promising and forms the basis to develop successful multiplexed imaging agents, which will noninvasively obtain more complete information about disease status than is now possible.

ACKNOWLEDGMENTS

This research was supported by the Intramural Research Program of the Center for Cancer Research, National Cancer Institute, National Institutes of Health.

REFERENCES

1. Sargsyan SA, Serkova NJ, Renner B et al. Detection of glomerular complement C3 fragments by magnetic resonance imaging in murine lupus nephritis. *Kidney Int* 2012;81:152–159. [PubMed: 21956190]
2. Jo SK, Hu X, Kobayashi H et al. Detection of inflammation following renal ischemia by magnetic resonance imaging. *Kidney Int* 2003; 64:43–51. [PubMed: 12787394]
3. Kobayashi H, Kawamoto S, Jo SK et al. Renal tubular damage detected by dynamic micro-MRI with a dendrimer-based magnetic resonance contrast agent. *Kidney Int* 2002; 61: 1980–1985. [PubMed: 12028438]
4. Longmire M, Choyke PL, Kobayashi H. Clearance properties of nano-sized particles and molecules as imaging agents: considerations and caveats. *Nanomedicine (Lond)* 2008; 3:703–717. [PubMed: 18817471]
5. Longmire MR, Ogawa M, Choyke PL et al. Biologically optimized nanosized molecules and particles: more than just size. *Bioconjug Chem* 2011;22:993–1000. [PubMed: 21513351]
6. Kobayashi H, Longmire MR, Ogawa M, Choyke PL. Rational chemical design of the next generation of molecular imaging probes based on physics and biology: mixing modalities, colors and signals. *Chem Soc Rev* 2011; 40:4626–4648. [PubMed: 21607237]
7. Kobayashi H, Longmire MR, Ogawa M et al. Multiplexed imaging in cancer diagnosis: applications and future advances. *Lancet Oncol* 2010;11:589–595. [PubMed: 20338808]
8. Kobayashi H, Choyke PL. Target-cancer-cell-specific activatable fluorescence imaging probes: rational design and in vivo applications. *Acc Chem Res* 2011;44:83–90. [PubMed: 21062101]
9. Kobayashi H, Ogawa M, Alford R et al. New strategies for fluorescent probe design in medical diagnostic imaging. *Chem Rev* 2010; 110: 2620–2640. [PubMed: 20000749]
10. Urano Y, Asanuma D, Hama Y et al. Selective molecular imaging of viable cancer cells with pH-activatable fluorescence probes. *Nat Med* 2009;15: 104–109. [PubMed: 19029979]

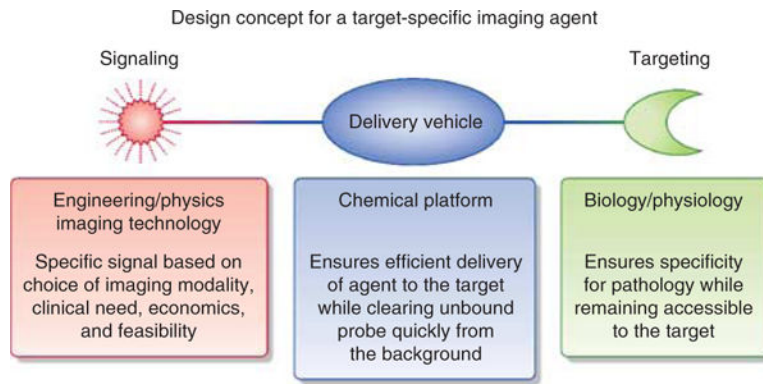


Figure 1 |. Schematic showing the strategy for developing a target-specific molecular imaging agent, which can be used as a biomarker of a disease.