

HOSTED BY



ELSEVIER

Available online at www.sciencedirect.com

ScienceDirect

journal homepage: <http://www.elsevier.com/locate/ijpam>



Case Report

Pott's puffy tumor due to *Aspergillus fumigatus*: A case report and review



Zainab Abdulaziz AlMoosa ^{a,*}, Tariq AlFawaz ^b, Fahad AlFawaz ^c

^a Pediatric Infectious Diseases, King Abdulaziz Hospital, Ministry of National Guard, Al-Hassa, Saudi Arabia

^b Pediatric Infectious Diseases, King Fahad Medical City, Riyadh, Saudi Arabia

^c ENT, King Fahad Medical City, Riyadh, Saudi Arabia

Received 31 May 2016; received in revised form 28 June 2016; accepted 1 August 2016
Available online 10 September 2016

KEYWORDS

Potts puffy tumor;
Sinusitis;
Osteomyelitis;
Aspergillus fumigatus

Abstract Pott's puffy tumor (PPT) is a very rare, nearly forgotten condition. We describe a 9-year-old girl with PPT due to trauma and surgical cultures that revealed *Aspergillus fumigatus*. Copyright © 2016, King Faisal Specialist Hospital & Research Centre (General Organization), Saudi Arabia. Production and hosting by Elsevier B.V. This is an open access article under the CC BY-NC-ND license (<http://creativecommons.org/licenses/by-nc-nd/4.0/>).

1. Introduction

Pott's puffy tumor (PPT) is a condition that is characterized by frontal bone osteomyelitis, which may be associated with sub periosteal abscess [1]. An English surgeon, Sir Percival Pott, first described Pott's puffy tumor in 1760 and explained it in his own words as "a puffy, circumscribed, indolent tumor of the scalp, and a spontaneous separation of the pericranium from the skull under such a tumor" [2].

Sir Pott initially thought that trauma was the only cause for this condition, but he later discovered that frontal sinus infection is the leading cause of PPT. Due to the wide use of broad spectrum antibiotics, its incidence has dramatically decreased [3], but the exact incidence is unknown. However, Clayman et al found that PPT may be seen in up to 0.5% of cases of acute and chronic sinusitis [4,5].

The infection in PPT typically spreads from the frontal sinus into the frontal bone via direct extension or through septic emboli [3].

PPT can affect all age groups and has a male: female ratio of 9:1. It is noted that adolescents are affected more frequently. This is thought to be due to high vascularity of the diploic venous system, and the accelerated growth of the frontal bone at this particular age [6–8]. The most common factors leading to PPT are frontal sinusitis and trauma [9]. Other rare etiologies include hematogenous spread of sinusitis, retrograde thrombophlebitis through the diploic veins, or even an insect bite [10,11]. Signs and

* Corresponding author. Zainab Abdulaziz Almoosa, King Abdulaziz Hospital, Ministry of National Guard, Al-Hassa, Saudi Arabia Tel.: +966 504980068.

E-mail addresses: zay.almo@hotmail.com (Z.A. AlMoosa), talfawaz@kfmc.med.sa (T. AlFawaz), falfawaz@kfmc.med.sa (F. AlFawaz).

Peer review under responsibility of King Faisal Specialist Hospital & Research Centre (General Organization), Saudi Arabia.

symptoms of PPT include forehead swelling and frontal headaches with or without fever. These clinical manifestations usually progress slowly, however, rapid progression may suggest the development of complications [12]. The most common cultured organisms are the same organisms causing chronic sinusitis: streptococci, staphylococci, and anaerobes [13].

PPT is a serious condition because it is associated with high rate of intracranial complications such as meningitis, subdural and epidural empyema, cerebral abscess, and cavernous sinus thrombosis or superior sagittal sinus thrombosis [14,15]. The diagnostic modality is the contrast enhanced CT scan of the brain and sinuses. The most important aspect in the management of PPT is early diagnosis, early use of proper antimicrobial therapy, and urgent surgical intervention to prevent serious complications [16–18].

2. Case report

A previously healthy 9-year-old girl presented with a one-month history of intermittent moderate frontal headaches after head trauma. She stated: "A swing fell over her forehead". She subsequently developed forehead swelling, which was later diagnosed as frontal sinusitis. She made a complete recovery after a course of oral antibiotic. Two weeks later, the swelling reappeared, and she was treated with a course of both IV and oral antibiotics but without significant improvement. She denied any history of fever, nasal discharge, or cough.

Upon examination, she had an undulating erythematous firm swelling over the right frontal area with mild right



Figure 1 Frontal view of fluctuant firm swelling over the right frontal area with mild right periorbital swelling.

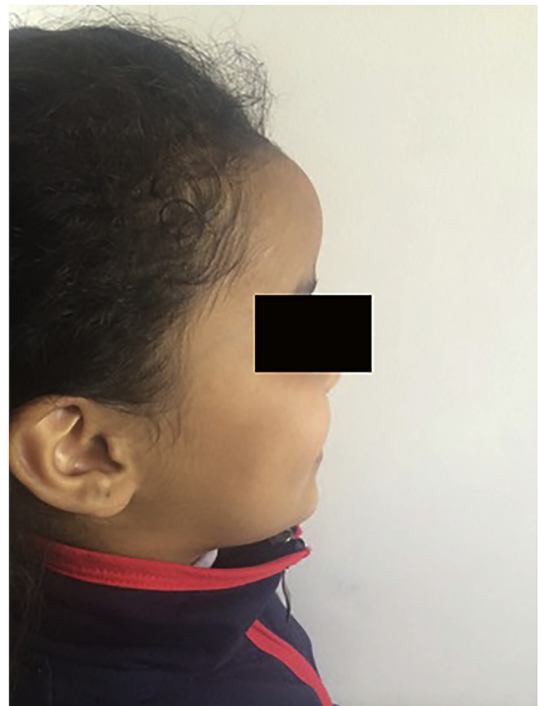

Figure 2 Lateral view of Fluctuant firm swelling over the right frontal area with mild right periorbital swelling.

periorbital swelling (Figs. 1 and 2). Normal pupillary reflexes and extra-ocular eye movements were intact. There were no meningeal signs that were elicited, and no neurological deficits were present.

Laboratory tests showed a normal CBC and normal inflammatory markers.

Brain imaging including a CT scan and MRI showed signs of frontal bone osteomyelitis with sequestrum formation and abnormal communication between the two frontal sinuses, both of which were filled with fluid (Fig. 3).

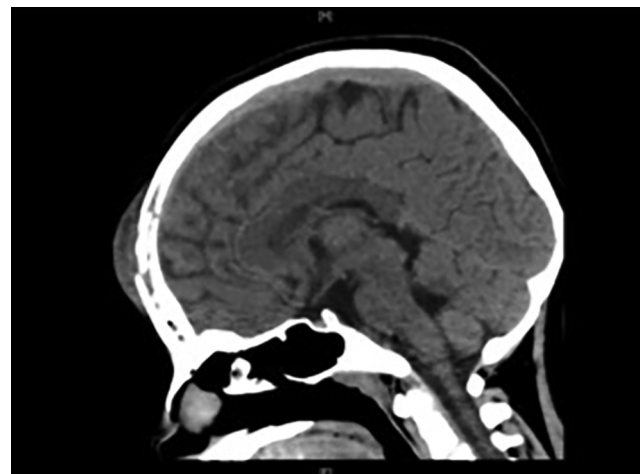


Figure 3 Computed tomography of the brain (CT scan) showing frontal bone osteomyelitis with sequestrum formation and abnormal communication between the two frontal sinuses, both filled with fluid.

A multidisciplinary approach was conducted that involved pediatric infectious diseases, ENT and neurosurgery. The patient was empirically treated with broad spectrum intravenous (IV) antibiotics Clindamycin and ceftriaxone.

Urgent surgical intervention was done by functional endoscopic sinus surgery (FESS) and a craniotomy with a flap to repair the defect (Fig. 4).

Sterile culture from the frontal bone, which was taken intra-operatively, grew *Aspergillus fumigatus*. Bone histopathology showed fungal hyphae. Voriconazole was initiated with a high dose (9 mg/kg/dose) every 12 h. She was kept on the voriconazole for 6 months because of the chronic nature of the osteomyelitis. Laboratory tests were used to closely monitor for signs of voriconazole toxicity. Fortunately, there was no toxicity detected. She showed significant improvement with complete clinical and radiological resolution at the end of her six-month treatment.

3. Discussion

Pott's puffy tumor is a very rare condition and nothing from previously reported cases detailed fungal species as a causative agent. However, the most commonly cultured organisms in PPT are *Streptococci*, mainly *Streptococcus milleri* which was found in approximately 50% of the reported cases, *Staphylococci*, anaerobes, namely *Fusobacterium* and *Bacteroides*, and less commonly *Proteus* and *Pseudomonas* [11,19–23]. In our case, the surgical culture from the frontal bone grew *A. fumigatus*, which is abnormal to have grown as a fungal organism in an immunocompetent individual.

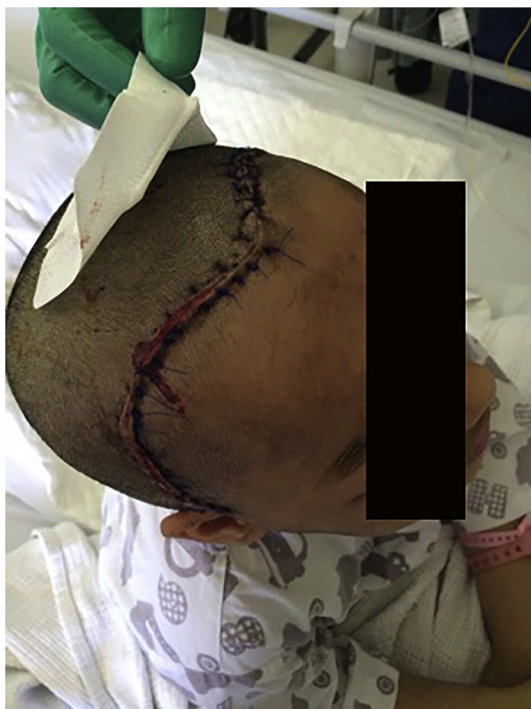

Figure 4 Post functional endoscopic sinus surgery (FESS) and craniotomy with flap to repair the defect.

In regards to diagnosis, computed tomography (CT) of the brain is the best diagnostic modality in such cases. It helps in the critical assessment of the sinuses as well as gauging the extent of the disease to rule out any intracranial complications [24,25]. In our case, a brain CT scan showed signs of frontal bone osteomyelitis with sequestrum formation, which indicated a chronic infection, and an abnormal communication between the two frontal sinuses, which were both filled with fluid, which could be a post-traumatic occurrence.

Pott's puffy tumor is considered to be an emergency medical condition, and broad spectrum antibiotics should be initiated as soon as possible along with urgent surgical intervention which may include: sinus wash-outs, percutaneous aspiration, trepanation, endoscopic sinus surgery, or craniotomy [23]. Functional endoscopic sinus surgery is a safe and less invasive surgical procedure [26,27]. The decision of whether or not a craniotomy is indicated depends on the size of the intracranial fluid collection [28].

In our case, a combined surgical approach was coordinated by ENT and neurosurgery. FEES along with craniotomy, aspiration of the sub periosteal collection, sequestrectomy, and frontal bone debridement were all conducted at the same time.

Furthermore, antimicrobial therapy should be tailored according to the cultured organism [29]. In our case, we started voriconazole which is an antifungal agent that is known to be fungicidal against most of the *Aspergillus* species.

Furthermore, a high dose of voriconazole is the best regimen for such condition [30].

We conclude that although PPT is rare, it still must be part of the differential diagnosis of forehead swelling and headache, especially if it was preceded by sinusitis or trauma. Broad spectrum antimicrobial therapy should be initiated immediately after surgical intervention. Adequate sampling should be attained for cultures, and serious consideration should be given to the possibility of fungal infections.

Conflict of interest

The authors declare that they have no competing interests.

References

- [1] Skomro R, McClean KL. Frontal osteomyelitis (Pott's puffy tumour) associated with *Pasteurella multocida*: a case report and review of the literature. *Can J Infect Dis* 1998;9:115–21.
- [2] Pott P. The surgical works of Percivall Pott. Wood and Innes 1808; 1.
- [3] Pott P. Observations on the Nature and Consequences of Wounds and Contusions of the Head. C Hitch and L Hawes 1760.
- [4] Clayman GL, Adams GL, Paugh DR, Koopmann Jr CF. Intracranial complications of paranasal sinusitis: a combined institutional review. *Laryngoscope* 1991;101:234–9.
- [5] Domville Lewis C. Pott's puffy tumour and intracranial complications of frontal sinusitis in pregnancy. *J Laryngology Otolaryngology* 2013;127:35–8.
- [6] Shehu BB, Mahmud MR. Pott's puffy tumour: a case report. *Ann Afr Med* 2008;7:138–40.

- [7] Furstenberg AC. Osteomyelitis of the skull. *Ann Otol* 1931;40: 996–1012.
- [8] Woodward FD. Osteomyelitis of skull. *JAMA* 1930;95:927.
- [9] Emejulu JC, Ekweogwu OC. Complicated Pott's Puffy Tumor Involving both Frontal and Parietal Bones: A Case Report. *J Infect Dis Ther* 2014;2(5):166. <http://dx.doi.org/10.4172/2332-0877.1000166>.
- [10] Steele RW, Ward KJ. A "Hickey". *Clin Pediatr* 2003;42: 657–60.
- [11] Raja V, Low C, Sastry A, Mariarty B. Pott's puffy tumor following an insect bite. *J Postgrad Med* 2007;53(2):114–6.
- [12] Forgie Sarah E. Pott's puffy tumor. *Am J Med* 2008;121(12).
- [13] Verbon A, Husni RN, Gordon SM, Lavertu P, Keys TF. Pott's puffy tumor due to *Haemophilus influenzae*: case report and review. *Clin Infect Dis* 1996;23:1305–7.
- [14] Tsai BY, Lin KL, Lin TY, Chiu CH, Lee WJ, Hsia SH, et al. Pott's puffy tumor in children. *Childs Nerv Syst* 2010;26:53–60.
- [15] Gupta M, El-Hakim H, Bhargava R, Mehta V. Pott's puffy tumour in a pre-adolescent child: the youngest reported in the post-antibiotic era. *Int J Pediatr Otorhinolaryngol* 2004;68(3): 373–8.
- [16] Parida Pradipta Kumar. Pott's puffy tumor in pediatric age group: a retrospective study. *Int J Pediatr Otorhinolaryngol* 2012;76:1274–7.
- [17] Shah P, Mishriki YY. The puffy periorbital protrusion: Pott's puffy tumor. *Postgrad Med* 1999;105:45–6.
- [18] Mammen-Prasad E, Murillo JL, Titelbaum JA. Infectious disease rounds: Pott's puffy tumor with intracranial complications. *N J Med* 1992;89:537–9.
- [19] Khan MA. Pott's puffy tumor: a rare complication of mastoiditis. *Pediatr Neurosurg* 2006;42(2):125–8.
- [20] Wu CT, Huang JL, Hsia SH, Lee HY, Lin JJ. Pott's puffy tumor after acupuncture therapy. *Eur J Pediatr* 2009;168(9):1147–9.
- [21] Marshall AH, Jones NS. Osteomyelitis of the frontal bone secondary to frontal sinusitis. *J Laryngol Otol* 2000;114:944–6.
- [22] Gallagher RM, Gross CW, Phillips CD. Suppurative intracranial complications of sinusitis. *Laryngoscope* 1998;108:1635–42.
- [23] Fenton JE, Smyth DA, Viani LG, Walsh MA. Sinogenic brain abscess. *Am J Rhinol* 1999;13:299–302.
- [24] Huijssoon E, Woerdeman PA, Van Diemen- Steenvoorde RAAM, Hanlo PW, Plötz FB. An 8-year-old boy with a Pott's puffy tumor. *Int J Pediatr Otorhinolaryngol* 2003;67(9):1023–6.
- [25] Martinez-Diaz GJ, Hsia R. Pott's Puffy tumor after minor head trauma. *Am J Emerg Med* 2008;26(6):739.
- [26] Blackman SC, Schleiss MR. Forehead swelling caused by Pott's puffy tumor in a 9-year-old boy with sinusitis. *Pediatr Int* 2005;47(6):704–7.
- [27] Suwan Phillip T. Pott's puffy tumor: an uncommon clinical entity. *Case Rep Pediatr* 2012;2012:4. Article ID 386104. <http://dx.doi.org/10.1155/2012/386104>.
- [28] DelGaudio JM, Evans SH, Sobol SE, Parikh SL. Intracranial complications of sinusitis: what is the role of endoscopic sinus surgery in the acute setting. *Am J Otolaryngol* 2010;31:25–8.
- [29] McDermott C, O'Sullivan R, McMahon G. An unusual cause of headache: Pott's puffy tumor. *Eur J Emerg Med* 2007;14(3): 170–3.
- [30] Dornbusch Hans Jürgen. Invasive fungal infections in children. *Pediatr Infect Dis J* 2009;28:734–7.