



Published in final edited form as:

Clin Cancer Res. 2019 February 15; 25(4): 1156–1164. doi:10.1158/1078-0432.CCR-18-2024.

Inhibition of mTOR Signaling and Clinical Activity of Rapamycin in Head and Neck Cancer in a Window of Opportunity Trial

Terry A. Day¹, Keisuke Shirai¹, Paul E. O'Brien¹, Maria Gisele Matheus¹, Kristina Godwin¹, Amit J. Sood¹, Anvesh Kompelli¹, Julie A. Vick², Daniel Martin³, Lynn Vitale-Cross³, Juan Luis Callejas-Varela^{4,7}, Zhiyong Wang⁴, Xingyu Wu⁴, Olivier Harismendy⁴, Alfredo A. Molinolo^{3,4}, Scott M. Lippman⁴, Carter Van Waes⁵, Eva Szabo⁶, and J. Silvio Gutkind^{3,4,*}

¹Medical University of South Carolina, Charleston, SC

²Rho, Inc, Chapel Hill, NC

³National Institute of Dental and Craniofacial Research, NIH, Bethesda

⁴University of California San Diego (UCSD) Moores Cancer Center, San Diego, CA

⁵National Institute on Deafness and Other Communication Disorders, Bethesda, MD

⁶National Cancer Institute, Potomac, MD

Abstract

Purpose: We studied the impact of mTOR signaling inhibition with rapamycin in head and neck squamous cell carcinoma (HNSCC) in the neoadjuvant setting. The goals were to evaluate the mTOR pathway as a therapeutic target for advanced HNSCC patients, and the clinical safety, anti-tumor, and molecular activity of rapamycin administration on HNSCC.

Patients and Methods: Patients with untreated stage II-IVA HNSCC received rapamycin for 21 days (day 1, 15mg; days 2–12, 5mg) prior to definitive treatment with surgery or chemoradiation. Treatment responses were assessed clinically and radiographically with CT and FDG-PET. Pre- and post-treatment biopsies and blood were obtained for toxicity, immune monitoring and immunohistochemical assessment of mTOR signaling, as well as exome sequencing.

Results: Sixteen patients (8 oral cavity, 8 oropharyngeal) completed rapamycin and definitive treatment. Half of patients were p16 positive. One patient had a pathological complete response and 4 (25%) patients met RECIST criteria for response (1 CR, 3 PR, 12 SD). Treatment was well tolerated with no grade 4 or unexpected toxicities. No significant immune suppression was observed. Downstream mTOR signaling was downregulated in tumor tissues as measured by phosphorylation of S6 ($p < 0.0001$), AKT ($p < 0.0001$), and 4EBP ($p = 0.0361$), with a significant compensatory increase in phosphorylated ERK in most patients ($p < 0.001$). Ki67 was reduced in tumor biopsies in all patients ($p = 0.013$).

*Corresponding Author: Moores Cancer Center, University of California San Diego, 3855 Health Sciences Drive, Room 2344, La Jolla, CA 92093-0803, USA; Phone: 858-534-5980, sgutkind@ucsd.edu.

⁷current address, Sanford Research, Cancer Biology Research Center, Sioux Falls, SD.57104

Disclaimers: None

Conclusions: Rapamycin treatment was well tolerated, reduced mTOR signaling and tumor growth, and resulted in significant clinical responses despite the brief treatment duration, thus supporting the potential role of mTOR inhibitors in treatment regimens for HNSCC.

Keywords

rapamycin; mTOR; HNSCC; targeted therapies; mechanistic biomarkers; neoadjuvant

Introduction

Head and neck squamous cell carcinoma (HNSCC), including cancers of the oral cavity, oropharynx, and larynx, is the 6th most common cancer in the world, affecting over 500,000 people per year and accounting for 223,000 cancer deaths (1,2). In the United States, more than 51,000 new cases of HNSCC, and 10,030 deaths were predicted to occur in 2018(1). The main risk factors include tobacco and alcohol use, and human papillomavirus (HPV) infection (3,4). The incidence of HNSCC is rising with the increasing incidence of HPV+ oropharyngeal cancer (5). HNSCC has a poor five-year survival rate at 63% (6). Despite recent advances in treatment, such as immune modulation with checkpoint inhibitors, long term survival after development of metastatic disease is poor and there is an urgent need to develop new effective options to prevent and treat HNSCC (7,8).

A striking finding from the recent deep sequencing of the HNSCC genomic landscape was the remarkable multiplicity and diversity of genetic alterations (9–11). The emerging picture from the in-depth analysis of the HNSCC oncogenome is that while the specific molecules altered in each individual tumor may be distinct, many converge on a handful of signal networks, including those regulated by the *TP53*, *FAT1*, *NOTCH1*, *CASP8*, *CDKN2A* (*p16^{INK4A}*) tumor suppressor genes, and PI3K pathway oncogenes (11,12). Among these, *PIK3CA*, encoding the PI3K α catalytic subunit, is the most commonly mutated oncogene in HNSCC (~20%), with a significant enrichment of *PIK3CA* mutations in HPV+ tumors (25%) (9,11). *PIK3CA* is also frequently amplified with other genes on chromosome 3q (9,11).

In addition to frequent *PIK3CA* mutations and gene amplification, multiple genetic and epigenetic alterations in HNSCC converge to sustain aberrant PI3K/mTOR pathway activation (11,12). In this regard, we have previously shown that the persistent activation of the PI3K/mTOR signaling circuitry is frequently dysregulated in HNSCC (>80% of all HPV- and HPV+ cases (13–16)). We also showed that mTOR inhibition causes tumor regression in a large series of genetically-defined and chemically-induced experimental HNSCC models (16–19 and references therein). This overreliance on the PI3K/mTOR signaling network for tumor growth can in turn expose a cancer vulnerability that can be exploited for therapeutic purposes. On the basis of these findings, we undertook an open-label window of opportunity trial to examine the clinical and signaling effects of neoadjuvant mTOR inhibition with rapamycin in patients with advanced HNSCC.

Patients and Methods

Patient Population

This study ([ClinicalTrials.gov](https://clinicaltrials.gov/ct2/show/study/NCT01195922) identifier: NCT01195922) enrolled patients with previously untreated stage II, III, and IVA HNSCC whose curative treatment plan included either surgical resection or chemoradiation. Written informed consent was obtained in accordance to the IRB approved protocol. Accrual occurred at the multidisciplinary Wellin Head and Neck Clinic at the Medical University of South Carolina (MUSC) and the Otolaryngology-Head and Neck Surgery clinic at NIH. The institutional review boards of MUSC and the National Cancer Institute approved the study, in accordance with the Declaration of Helsinki. Eligibility criteria included age \geq 18 years, Eastern Cooperative Oncology Group performance status of 0 or 1, life expectancy \geq 6 months, and adequate organ function (absolute neutrophil count (ANC) \geq 1,500/mL; platelets \geq 100,000/mL; hemoglobin \geq 10 g/dL; CD4 count \geq 400; creatinine \leq 1.5 mg/dL; total bilirubin, AST and ALT \leq 1.5 X upper limit of institutional normal (ULN); serum triglycerides \leq 400 mg/dL; serum cholesterol \leq 350 mg/dL; International Normalized Ratio \leq 1.5). The co-primary endpoints were clinical response (defined as \geq 25% decrease in tumor size) and inhibition of mTOR signaling (assessed by changes in levels of pS6, pAkt473, and Ki-67 in tumor samples).

Treatment, safety, and efficacy assessments

This was a pilot, single-arm, open-label, interventional, neoadjuvant clinical trial. As depicted in Supplemental Figure 1, patients were screened prior to treatment, and underwent laboratory tests, physical exam, CT and PET scans, and the baseline tissue biopsy 1 week prior to the initiation of the intervention. Daily rapamycin was delivered orally for 21 days, with a 15 mg loading dose on day 1, followed by 5 mg daily. Rapamycin serum concentrations were measured weekly, and dosing was decreased if levels \geq 20 ng/ml. Hematologic and metabolic panels were performed weekly. Adverse events were graded using NCI Common Terminology Criteria for Adverse Events, version 4.0. Repeat CT and PET scans, and the second tissue biopsy were performed on day 22 (+1 day), approximately 24h after the last administration of rapamycin. Laboratory tests and physical exam were repeated on day 28 (\pm 2 days), and definitive treatment (surgery or chemoradiation) performed after day 28. Patients were followed up in person 30 days post treatment and for 1 year after definitive treatment by medical record review. Tumor response was assessed using RECIST v1.1 criteria.

Biomarker analysis and statistics

All tissues were fixed overnight and processed for immunohistochemistry (IHC) analysis as described in the Supplementary Information. Quantification of slides stained for different biomarkers was performed using Aperio-Leica Scanscope. H-scores were determined as the product of the staining intensity (0, absent; 1, weak staining; 2, moderate staining; and 3, strong staining) multiplied by the percentage of positive cells quantified. The paired *t*-test method was used to compare pre- and post-treatment values using GraphPad Prism version 7.00 for Windows (GraphPad Software, La Jolla California).

Exome sequencing

The sequencing libraries were prepared and captured using SureSelect Clinical Research Exome (Agilent Technologies) following the manufacturer's instructions, and as germline DNA was not available, specific filtering of germline variants was performed (see Supplementary Information for extensive technical details). The final list of filtered variants is reported in Supplementary Table 2 and summarized in Table 3.

Results

A total of 16 patients met inclusion criteria and completed rapamycin treatment prior to definitive therapy (Table 1). Of the 16 patients, 15 underwent definitive surgery while one underwent chemoradiation. Table 1 includes patient demographics. Eight patients had oral cavity (OC) cancers while the other 8 patients had cancer limited to the oropharynx (OR). There were 8 (50%) T2 lesions, 4 (25%) T3 tumors, and 3 (18.8%) T4a tumors. One patient was staged Tx as an unknown primary. Regarding nodal staging, 3 (18.8%) were N0, 5 (31.3%) N1, 1 (6.3%) N2, 5 (31.3%) N2b and 2 (12.5%) N2c.

The location, staging, and differentiation status of each tumor lesion is summarized in Figure 1. Immunohistochemical analysis revealed that 8 tumors were positive for p16 (a surrogate marker for HPV-associated oropharyngeal cancer (20)), and 8 were positive for p53 (usually associated with the presence of mutations). All p16 positive (HPV+) patients had poorly differentiated tumors. p53 was not analyzed in 2 patients due to limited tissues (not determined, nd). Curiously, one patient with oropharyngeal cancer was positive for both p16 and p53 by IHC, though no *TP53* mutations were identified (see below). Three patients were negative for PTEN expression, aligned with our prior findings that ~20% of HNSCC cases are PTEN deficient (21). Eight patients showed a pattern of EGFR expression comparable to that of normal tissues. High EGFR expression was found in five p16 negative oral cancers patients, and in the remaining patients the expression was similar or even lower than in normal adjacent tissues. Of interest, the latter were all HPV+ HNSCC cases, raising the possibility that EGFR may not be overexpressed in this patient population. Representative IHC cases are depicted in Figure 1. These expression patterns support the notion that the HNSCC patients enrolled reflect the typical trends in terms of biomarkers and disease location.

The waterfall plot in Figure 2A revealed tumor shrinkage in 14/16 patients undergoing rapamycin treatment for 3 weeks, including one complete response (CR). The primary protocol-specified tumor response rate of 25% was achieved in 5 patients, which exceeded the 20% threshold set by the protocol to justify further inquiry. Four patients (25%) also met RECIST criteria for response (1 CR, 3 PR, 12 SD). The profiles of common mutations in the 6 HNSCC cases sequenced (see below) are depicted. The PET scan of patient #3 with a complete response after rapamycin treatment is shown in Figure 2B. Histological analysis of the resected tissue demonstrated a complete pathological response. Figure 2B shows the tumor shrinkage after rapamycin treatment in patient #2 who had minor reduction by RECIST criteria but whose clinical response was quite dramatic. Clinical measurements were used to determine tumor size in two patients for whom CT scans were not informative due to dental implant artefact or presence of flat lesions (denoted by *). One patient with a

retromolar trigone OC and painful trismus exhibited significant clinical improvement with decreased pain and need for narcotics and improved oral opening.

Overall, rapamycin was well tolerated with no new AEs identified. The most common adverse events (AEs) were thrombocytopenia and neutropenia, with 43.8% and 25.0% of patients developing these AEs, respectively (Table 2). Most AEs were grade 1 or 2, with the exception of one grade 3 hypokalemia. One surgical patient with an extended pharyngectomy and neck dissection developed a pharyngeal air leak (Grade 3) and tonsillar bleeding (Grade 2) after surgery requiring intubation and tube feedings that prolonged hospitalization (Grade 3). Indeed, all high grade toxicities were surgical in nature and occurred post-operatively, and deemed to be unlikely to be related to the agent intervention. No other delays in wound healing were reported.

Of note, there were no significant changes in circulating total T cells (CD3+), and CD8+ or CD4+ T cells, or B cells (CD19+) after rapamycin treatment (Figure 3). IHC analysis of HNSCC tissues pre- and post-treatment with rapamycin revealed a dramatic decrease in the phosphorylated forms of two typical mTOR targets, pS6 and pAKT^{S473} (Figure 4). Similarly, there was significant reduction in tumor cell proliferation (Ki67). In contrast, no changes in p53 levels were observed, which served as an internal control. Phosphorylation of 4EBP was not efficiently inhibited by rapamycin. Overall p4EBP levels were significantly decreased when all post-treatment samples were compared with the pre-treatment samples (p=0.036), but this decrease was not significant when performing pairwise pre- post-treatment comparisons (p=0.095). Finally, most post-treatment tissues exhibited an increase in pERK (p 0.001), suggesting compensatory upregulation of the ERK pathway after mTOR inhibition by rapamycin.

To identify mutations that could explain the complete response in patient #3 and the sensitivity and resistance to rapamycin observed in other patients, we conducted whole exome sequencing of 6 HNSCC for which we obtained consent. All mutations identified in these patients are reported in Supplemental Tables 1–3. All patients exhibited approximately 200 genomic alterations. The clearest cancer driver mutations were observed in patient #2 - *TP53*, *CDKN2A*, and *EP300*; in patient #4 - *KRAS* and *PIK3R1*; in patient #12 - *TP53*, *CDKN2A*, and *RAC1*; in patient #15 - *TP53*, *ADCY8*, *FAT1*, and *CASP8*; and in patient #16 - *TP53* and *PIK3CA*. Of interest, patient #3 (who had a CR in response to rapamycin) did not harbor any typical driver mutations, but had mutations in *SLC25A5* and *PIK3R4*.

Discussion

The elucidation of the HNSCC genomic landscape and the identification of its dysregulated oncogenic mechanisms have provided a unique opportunity to identify new targeted options for HNSCC prevention and treatment. In this regard, the widespread activation of mTOR in HNSCC may expose a signaling vulnerability that can be exploited for therapeutic purposes. Indeed, we show here that the use a classical allosteric mTOR inhibitor (mTORi), rapamycin, exerts potent growth suppressive activity in HNSCC in the neoadjuvant setting, concomitant with mTOR signaling inhibition, aligned with our prior observations using mTORi in human HNSCC xenograft (13–16) and genetic and chemically-induced (16–19)

preclinical models of HNSCC. Furthermore, clinical improvement and tumor size reduction were observed in 14 of the 16 rapamycin-treated patients, without clinically significant immune suppression. In 25% of patients, these responses met RECIST criteria despite the short duration of treatment with rapamycin. This supports the potential therapeutic benefit of mTOR inhibition in HNSCC.

Analysis of tumor specimens revealed successful inhibition of mTOR signaling, with decreased phosphorylated S6 (pS6) in all cases and decreased phosphorylated AKT^{S473} in 92% of 14 evaluable patients. The latter is quite remarkable, as mTOR is a protein kinase involved in multiple cellular functions, including cell growth promotion, which can be found as part of two protein complexes, mTOR complex 1 (mTORC1) and mTORC2 (22). Rapamycin is a specific allosteric inhibitor of mTORC1, but the clear reduction in pAkt^{S473} in HNSCC patients suggests that prolonged inhibition of mTORC1 may also result in mTORC2 inhibition, as reported in certain cellular systems (23) and our prior numerous experimental HNSCC mouse models (16–19). Thus, it is tempting to speculate that the absence of an adaptive AKT activation after mTOR inhibition, as reported in other cancer types (24–26), may in part underlie the favourable clinical activity of rapalogs in HNSCC.

In turn, these findings raise the possibility that other yet to be identified therapeutic resistance mechanisms might be more relevant for HNSCC. Our recent synthetic lethal RNAi screen revealed that ERK pathway activation represents the strongest synthetic lethal interaction with rapamycin (27). Indeed, we now show that ERK activation is a widespread event in response to rapamycin in HNSCC patients in the clinic. While rapamycin-induced ERK activation may result in drug resistance, we did not observe a correlation between pERK increase and decreased clinical response, likely due to the short treatment duration and limited number of patients studied. Preclinical studies support increased anti-tumor effects of combining inhibitors of MEK and PI3K-mTOR, but MEK inhibitors appear to have greater immunosuppressive effects than rapamycin (28–30). The increased in ERK activity may help explain the incomplete inhibition of phosphorylation of 4EBP, a classical mTORC1 target (22), since ERK can phosphorylate 4EBP (31) and thereby rescue p4EBP from mTOR blockade. These possibilities warrant further experimental investigation.

Whole exome sequencing was conducted in only 6 HNSCC cases, primarily due the need to re-consent patients for this procedure. Nonetheless, some interesting trends and new findings were observed. For example, although infrequent in HNSCC, one patient (patient 4) harbored a canonical V12 activating *KRAS* mutation. This was also the only HPV+ patient showing p53 by IHC, which is infrequent in HPV+ patients, albeit no mutations in the *TP53* coding region were found. This suggests the presence of a complex oncogenic landscape likely driven by *KRAS* mutant combined with HPV, which was nonetheless partially sensitive to mTOR inhibition (25% tumor volume reduction after rapamycin treatment). The patient who had a complete response (CR) was HPV+, although a correlation between HPV status and clinical response was not observed. Remarkably, this patient did not exhibit any well-established cancer driver mutation, but only had cancer-associated mutations in *SLC25A5* and *PIK3R4*, whose roles in progression and treatment have not been previously studied. Specifically, *PIK3R4*, encoding the VPS15 subunit of the autophagy complex (32), is mutated in a ciliopathy (33) and melanoma (34,35). Preliminary studies show that

knockdown of *PIK3R4*, but not *SLC25A5*, enhances the response to rapamycin in HNSCC cells (results not shown). Future thorough analysis of each genomic alteration in this rapamycin-extreme responder patient may reveal whether autophagy or other molecular events sensitize to mTORi, thus representing a therapeutic target and/or a biomarker of favorable clinical response. As our study did not include analysis of copy number or methylation, we cannot exclude other alterations affecting the PI3K-mTOR pathway in responders, and these analyses warrant future investigation.

Treatment with rapamycin was well tolerated and did not reveal any new toxicities. None of the 16 patients had clinically significant immune suppression as judged by lack of infection and effects on white blood cell subsets. Although rapamycin has a black box warning based on the study of renal transplant patients who were also taking cyclosporine and corticosteroids (36), other trials of single-agent rapamycin (or analogues-rapalogs) in cancer patients have shown similar lack of immunosuppression (37–39). Specifically in our study, weekly monitoring of rapamycin blood concentrations and dose adjustments to maintain it 20 ng/ml at trough levels may have resulted in cancer control without overt immune suppression as a side effect. Paradoxically, recent studies have associated low dose rapamycin with increased immune responses and potentiation of the activity of immune oncology agents in cancer models in a context-dependent fashion (40–44 and references therein). Whether mTOR inhibition at the blood concentrations achieved in our study may enhance, rather than suppress, the anti-tumor immune response deserves future study.

Other mTORis have shown promising (45) or only modest activity in HNSCC in the metastatic, previously treated recurrent, and/or platinum-refractory setting, alone or when combined with erlotinib (46,47). This is contrast with our study that demonstrates efficacy of rapamycin used as a neoadjuvant therapy and demonstrated the safety of this therapy. Indeed, 5/16 (31%) of patients had 25% tumor shrinkage on CT and by clinical exam and photography (which was the primary end-point of the trial) while the remaining 12 patients had stable disease or better. None had progression of disease. Four patients (25%) met RECIST criteria for response (1 CR, 3 PR) and the remainder of patients had stable disease. These responses exceeded the 20% set by the protocol to justify further investigation. Furthermore, there was a significant reduction of aggregate size and metabolic activity on CT and PET. Reduction of glucose tracer uptake by PET supports metabolic effects of rapamycin on PI3K-mTOR signaling. Our findings using mTORis in the neoadjuvant setting highlights the urgent need to identify mechanisms of resistance to mTOR inhibition in advanced HNSCC cases, and new co-targeting options sensitizing to mTOR inhibition without increasing treatment-related toxicities.

A number of limitations to this study must be acknowledged. Notably, the sample size was small, the duration of treatment was short, and one patient did not undergo surgical resection, preventing full tissue sampling. Additionally, this patient population was generally healthy, enriched for HPV+ tumors and might not represent the usual clinical setting. The study was designed prior to more recent knowledge of mTORi impact on response in HPV+ vs HPV- HNSCC and therefore, accrual goals and stratification of this variable along with objective tobacco exposure was not performed. However, future studies should consider this and may reveal more details about response rates to rapalogs in HPV HNSCC. However, the

study strengths include the prospective and thorough tissue analysis in previously untreated HNSCC. The clinical responses seen after only 3 weeks of treatment were remarkable, but further study is needed to investigate the efficacy of rapamycin and/or other mTORis as a neoadjuvant therapy in comparison to other therapies, and how patients fare long term as well.

In conclusion, rapamycin is a well-characterized FDA-approved drug with a known safety profile and defined molecular target. Cancers with upregulated mTOR signaling, such as HNSCC, may be vulnerable to rapamycin treatment. After only 21 days of treatment, 5 of 16 patients treated with rapamycin had a partial or complete response and cancer tissues showed reduction in Ki67 expression, together with reduced phosphorylation of pS6, p4EBP, and pAKT^{S473}. Overall, the results demonstrate efficacy and support further study on the potential role of mTOR inhibitors, including rapamycin, in treatment regimens for HNSCC.

Supplementary Material

Refer to Web version on PubMed Central for supplementary material.

Acknowledgments

Supported by an NIH Director's Bench to Bedside Award, NIDCR Project Z01DE00558, NIDCD Project ZIA-DC-000073, and NIH Grants R01DE026644, P30CA023100, U01CA196406, and R01DE026870.

Research Support: NIH Director's Bench to Bedside Award, NIDCR Project Z01DE00558, NIDCD Project ZIA-DC-000073, and NIH Grants R01DE026644, P30CA023100, U01CA196406, and R01DE026870.

REFERENCES:

1. Siegel RL, Miller KD, Jemal A. Cancer statistics, 2018. *CA Cancer J Clin* 2018;68(1):7–30 doi 10.3322/caac.21442. [PubMed: 29313949]
2. Jemal A, Bray F, Center MM, Ferlay J, Ward E, Forman D. Global cancer statistics. *CA Cancer J Clin* 2011;61(2):69–90 doi 10.3322/caac.20107. [PubMed: 21296855]
3. Forastiere A, Koch W, Trotti A, Sidransky D. Head and neck cancer. *N Engl J Med* 2001;345(26):1890–900 doi 10.1056/NEJMra001375. [PubMed: 11756581]
4. Mao L, Hong WK, Papadimitrakopoulou VA. Focus on head and neck cancer. *Cancer Cell* 2004;5(4):311–6 doi 10.1016/s1535-6108(04)00090-x. [PubMed: 15093538]
5. Chaturvedi AK, Engels EA, Pfeiffer RM, Hernandez BY, Xiao W, Kim E, et al. Human papillomavirus and rising oropharyngeal cancer incidence in the United States. *Journal of Clinical Oncology* 2011;29(32):4294–301 doi 10.1200/JCO.2011.36.4596. [PubMed: 21969503]
6. Miller KD, Siegel RL, Lin CC, Mariotto AB, Kramer JL, Rowland JH, et al. Cancer treatment and survivorship statistics, 2016. *CA Cancer J Clin* 2016 doi 10.3322/caac.21349.
7. Mehra RS TY;Mahipal A; Weiss J; Berger R; Eder JP; Burtness B; Tahara M;Keam B;Le DT; Muro K; Geva R;Chung HC;Lin CC;Meister A;Hille D; Cheng JD;Chow LQM;Haddad RI Efficacy and safety of pembrolizumab in recurrent/metastatic head and neck squamous cell carcinoma (R/M HNSCC): Pooled analyses after long-term follow-up in KEYNOTE-012. *J Clin Oncol* 2016;34(suppl; abstr 6012).
8. Ferris RL, Blumenschein G, Jr., Fayette J, Guigay J, Colevas AD, Licitra L, et al. Nivolumab for Recurrent Squamous-Cell Carcinoma of the Head and Neck. *N Engl J Med* 2016;375(19):1856–67 doi 10.1056/NEJMoa1602252. [PubMed: 27718784]
9. Lui VW, Hedberg ML, Li H, Vangara BS, Pendleton K, Zeng Y, et al. Frequent mutation of the PI3K pathway in head and neck cancer defines predictive biomarkers. *Cancer discovery* 2013;3(7):761–9. [PubMed: 23619167]

10. Pickering CR, Zhang J, Yoo SY, Bengtsson L, Moorthy S, Neskey DM, et al. Integrative genomic characterization of oral squamous cell carcinoma identifies frequent somatic drivers. *Cancer discovery* 2013;3(7):770–81. [PubMed: 23619168]
11. Cancer Genome Atlas N. Comprehensive genomic characterization of head and neck squamous cell carcinomas. *Nature* 2015;517(7536):576–82 doi 10.1038/nature14129. [PubMed: 25631445]
12. Iglesias-Bartolome R, Martin D, Gutkind JS. Exploiting the head and neck cancer oncogenome: widespread PI3K-mTOR pathway alterations and novel molecular targets. *Cancer Discovery* 2013;3(7):722–5 doi 10.1158/2159-8290.CD-13-0239. [PubMed: 23847349]
13. Amornphimoltham P, Sriuranpong V, Patel V, Benavides F, Conti CJ, Sauk J, et al. Persistent activation of the Akt pathway in head and neck squamous cell carcinoma: a potential target for UCN-01. *Clinical Cancer Research* 2004;10(12):4029–37 doi 10.1158/1078-0432.ccr-03-0249. [PubMed: 15217935]
14. Molinolo AA, Hewitt SM, Amornphimoltham P, Keelawat S, Rangdaeng S, Meneses Garcia A, et al. Dissecting the Akt/mammalian target of rapamycin signaling network: emerging results from the head and neck cancer tissue array initiative. *Clinical cancer research : an official journal of the American Association for Cancer Research* 2007;13(17):4964–73 doi 10.1158/1078-0432.CCR-07-1041. [PubMed: 17785546]
15. Amornphimoltham P, Patel V, Sodhi A, Nikitakis NG, Sauk JJ, Sausville EA, et al. Mammalian target of rapamycin, a molecular target in squamous cell carcinomas of the head and neck. *Cancer research* 2005;65(21):9953–61 doi 10.1158/0008-5472.CAN-05-0921. [PubMed: 16267020]
16. Molinolo AA, Marsh C, El Dinali M, Gangane N, Jennison K, Hewitt S, et al. mTOR as a molecular target in HPV-associated oral and cervical squamous carcinomas. *Clinical Cancer Research* 2012;18(9):2558–68 doi 10.1158/1078-0432.CCR-11-2824. [PubMed: 22409888]
17. Czerninski R, Amornphimoltham P, Patel V, Molinolo AA, Gutkind JS. Targeting mammalian target of rapamycin by rapamycin prevents tumor progression in an oral-specific chemical carcinogenesis model. *Cancer prevention research (Philadelphia, Pa)* 2009;2(1):27–36 doi 10.1158/1940-6207.capr-08-0147.
18. Patel V, Marsh CA, Dorsam RT, Mikelis CM, Masedunskas A, Amornphimoltham P, et al. Decreased Lymphangiogenesis and Lymph Node Metastasis by mTOR Inhibition in Head and Neck Cancer. *Cancer research* 2011 doi 10.1158/0008-5472.CAN-10-3192.
19. Squarize CH, Castilho RM, Gutkind JS. Chemoprevention and treatment of experimental Cowden's disease by mTOR inhibition with rapamycin. *Cancer research* 2008;68(17):7066–72 doi 10.1158/0008-5472.CAN-08-0922. [PubMed: 18757421]
20. Adelstein DJ, Ridge JA, Gillison ML, Chaturvedi AK, D'Souza G, Gravitt PE, et al. Head and neck squamous cell cancer and the human papillomavirus: summary of a National Cancer Institute State of the Science Meeting, November 9–10, 2008, Washington, D.C. *Head & neck* 2009;31(11):1393–422 doi 10.1002/hed.21269. [PubMed: 19787782]
21. Squarize CH, Castilho RM, Abrahao AC, Molinolo A, Lingen MW, Gutkind JS. PTEN deficiency contributes to the development and progression of head and neck cancer. *Neoplasia* 2013;15(5):461–71. [PubMed: 23633918]
22. Zoncu R, Efeyan A, Sabatini DM. mTOR: from growth signal integration to cancer, diabetes and ageing. *Nat Rev Mol Cell Biol* 2011;12(1):21–35 doi 10.1038/nrm3025. [PubMed: 21157483]
23. Sarbassov DD, Ali SM, Sengupta S, Sheen JH, Hsu PP, Bagley AF, et al. Prolonged rapamycin treatment inhibits mTORC2 assembly and Akt/PKB. *Mol Cell* 2006;22(2):159–68 doi S1097–2765(06)00218–8 [pii]10.1016/j.molcel.2006.03.029. [PubMed: 16603397]
24. O'Reilly KE, Rojo F, She QB, Solit D, Mills GB, Smith D, et al. mTOR inhibition induces upstream receptor tyrosine kinase signaling and activates Akt. *Cancer research* 2006;66(3):1500–8 doi 10.1158/0008-5472.Can-05-2925. [PubMed: 16452206]
25. Rodrik-Outmezguine VS, Chandarlapaty S, Pagano NC, Poulikakos PI, Scaltriti M, Moskatel E, et al. mTOR Kinase Inhibition Causes Feedback-Dependent Biphasic Regulation of AKT Signaling. *Cancer Discovery* 2011;1(3):248–59 doi 10.1158/2159-8290.Cd-11-0085. [PubMed: 22140653]
26. Chandarlapaty S, Sawai A, Scaltriti M, Rodrik-Outmezguine V, Grbovic-Huezo O, Serra V, et al. AKT inhibition relieves feedback suppression of receptor tyrosine kinase expression and activity. *Cancer Cell* 2011;19(1):58–71 doi 10.1016/j.ccr.2010.10.031. [PubMed: 21215704]

27. Mullard A 2013 FDA drug approvals. *Nature Reviews Drug Discovery* 2014;13(2):85–9.
28. Cash H, Shah S, Moore E, Caruso A, Uppaluri R, Van Waes C, et al. mTOR and MEK1/2 inhibition differentially modulate tumor growth and the immune microenvironment in syngeneic models of oral cavity cancer. *Oncotarget* 2015;6(34):36400–17. [PubMed: 26506415]
29. Mohan S, Vander Broek R, Shah S, Eytan DF, Pierce ML, Carlson SG, et al. MEK Inhibitor PD-0325901 Overcomes Resistance to PI3K/mTOR Inhibitor PF-5212384 and Potentiates Antitumor Effects in Human Head and Neck Squamous Cell Carcinoma. *Clinical cancer research : an official journal of the American Association for Cancer Research* 2015;21(17):3946–56 doi 10.1158/1078-0432.CCR-14-3377. [PubMed: 25977343]
30. Yamaguchi K, Iglesias-Bartolome R, Wang Z, Callejas-Valera JL, Amornphimoltham P, Molinolo AA, et al. A synthetic-lethality RNAi screen reveals an ERK-mTOR co-targeting pro-apoptotic switch in PIK3CA+ oral cancers. *Oncotarget* 2016;7(10):10696–709 doi 10.18632/oncotarget.7372. [PubMed: 26882569]
31. Cohen JD, Gard JM, Nagle RB, Dietrich JD, Monks TJ, Lau SS. ERK crosstalks with 4EBP1 to activate cyclin D1 translation during quinol-thioether-induced tuberous sclerosis renal cell carcinoma. *Toxicological sciences : an official journal of the Society of Toxicology* 2011;124(1):75–87 doi 10.1093/toxsci/kfr203. [PubMed: 21813464]
32. Yu X, Long YC, Shen HM. Differential regulatory functions of three classes of phosphatidylinositol and phosphoinositide 3-kinases in autophagy. *Autophagy* 2015;11(10):1711–28 doi 10.1080/15548627.2015.1043076. [PubMed: 26018563]
33. Stoetzel C, Bar S, De Craene JO, Scheidecker S, Etard C, Chicher J, et al. A mutation in VPS15 (PIK3R4) causes a ciliopathy and affects IFT20 release from the cis-Golgi. *Nature communications* 2016;7:13586 doi 10.1038/ncomms13586.
34. Xia J, Jia P, Hutchinson KE, Dahlman KB, Johnson D, Sosman J, et al. A meta-analysis of somatic mutations from next generation sequencing of 241 melanomas: a road map for the study of genes with potential clinical relevance. *Molecular cancer therapeutics* 2014;13(7):1918–28 doi 10.1158/1535-7163.MCT-13-0804. [PubMed: 24755198]
35. Shull AY, Latham-Schwark A, Ramasamy P, Leskoske K, Oroian D, Birtwistle MR, et al. Novel somatic mutations to PI3K pathway genes in metastatic melanoma. *PloS one* 2012;7(8):e43369 doi 10.1371/journal.pone.0043369. [PubMed: 22912864]
36. Haydar AA, Denton M, West A, Rees J, Goldsmith DJ. Sirolimus-induced pneumonitis: three cases and a review of the literature. *American journal of transplantation : official journal of the American Society of Transplantation and the American Society of Transplant Surgeons* 2004;4(1):137–9.
37. O'Donnell A, Faivre S, Burris HA, 3rd, Rea D, Papadimitrakopoulou V, Shand N, et al. Phase I pharmacokinetic and pharmacodynamic study of the oral mammalian target of rapamycin inhibitor everolimus in patients with advanced solid tumors. *J Clin Oncol* 2008;26(10):1588–95 doi 10.1200/jco.2007.14.0988. [PubMed: 18332470]
38. Bissler JJ, McCormack FX, Young LR, Elwing JM, Chuck G, Leonard JM, et al. Sirolimus for angiomyolipoma in tuberous sclerosis complex or lymphangiomyomatosis. *N Engl J Med* 2008;358(2):140–51 doi 10.1056/NEJMoa063564. [PubMed: 18184959]
39. Hahnel PS, Thaler S, Antunes E, Huber C, Theobald M, Schuler M. Targeting AKT signaling sensitizes cancer to cellular immunotherapy. *Cancer research* 2008;68(10):3899–906 doi 10.1158/0008-5472.can-07-6286. [PubMed: 18483275]
40. Dao V, Liu Y, Pandeswara S, Svatek RS, Gelfond JA, Liu A, et al. Immune-Stimulatory Effects of Rapamycin Are Mediated by Stimulation of Antitumor gamma delta T Cells. *Cancer research* 2016;76(20):5970–82 doi 10.1158/0008-5472.CAN-16-0091. [PubMed: 27569211]
41. Mannick JB, Del Giudice G, Lattanzi M, Valiante NM, Praestgaard J, Huang B, et al. mTOR inhibition improves immune function in the elderly. *Science translational medicine* 2014;6(268):268ra179 doi 10.1126/scitranslmed.3009892.
42. Jiang Q, Weiss JM, Back T, Chan T, Ortaldo JR, Guichard S, et al. mTOR kinase inhibitor AZD8055 enhances the immunotherapeutic activity of an agonist CD40 antibody in cancer treatment. *Cancer research* 2011;71(12):4074–84 doi 10.1158/0008-5472.can-10-3968. [PubMed: 21540234]

43. Li Q, Rao R, Vazzana J, Goedegebuure P, Odunsi K, Gillanders W, et al. Regulating mammalian target of rapamycin to tune vaccination-induced CD8(+) T cell responses for tumor immunity. *Journal of immunology (Baltimore, Md : 1950)* 2012;188(7):3080–7 doi 10.4049/jimmunol.1103365.
44. Moore EC, Cash HA, Caruso AM, Uppaluri R, Hodge JW, Van Waes C, et al. Enhanced Tumor Control with Combination mTOR and PD-L1 Inhibition in Syngeneic Oral Cavity Cancers. *Cancer immunology research* 2016;4(7):611–20 doi 10.1158/2326-6066.cir-15-0252. [PubMed: 27076449]
45. Grunwald V, Keilholz U, Boehm A, Guntinas-Lichius O, Hennemann B, Schmoll HJ, et al. TEMHEAD: a single-arm multicentre phase II study of temsirolimus in platin- and cetuximab refractory recurrent and/or metastatic squamous cell carcinoma of the head and neck (SCCHN) of the German SCCHN Group (AIO). *Annals of oncology : official journal of the European Society for Medical Oncology* 2015;26(3):561–7 doi 10.1093/annonc/mdl571. [PubMed: 25527417]
46. Massarelli E, Lin H, Ginsberg LE, Tran HT, Lee JJ, Canales JR, et al. Phase II trial of everolimus and erlotinib in patients with platinum-resistant recurrent and/or metastatic head and neck squamous cell carcinoma. *Annals of oncology : official journal of the European Society for Medical Oncology* 2015;26(7):1476–80 doi 10.1093/annonc/mdv194. [PubMed: 26025965]
47. Geiger JL, Bauman JE, Gibson MK, Gooding WE, Varadarajan P, Kotsakis A, et al. Phase II trial of everolimus in patients with previously treated recurrent or metastatic head and neck squamous cell carcinoma. *Head & neck* 2016;38(12):1759–64 doi 10.1002/hed.24501. [PubMed: 27232378]

Translational Relevance

The persistent activation of the PI3K/mTOR signaling circuitry is the frequent dysregulated signaling pathway in head and neck squamous cell carcinoma (HNSCC). The overreliance on the PI3K/mTOR signaling network for tumor growth can in turn expose a cancer vulnerability that can be exploited for therapeutic purposes. Indeed, we show here that the use of a classical allosteric mTOR inhibitor (mTORi), rapamycin, exerts potent growth suppressive activity in patients with advanced HNSCC in a window of opportunity trial, concomitant with mTOR signaling inhibition and compensatory ERK reactivation. Furthermore, clinical improvement and tumor size reduction were observed in 14 of the 16 rapamycin-treated patients, without clinically significant immune suppression. These responses met RECIST criteria in 25% of patients, including a complete response, despite the short duration of treatment with rapamycin. This study supports the potential therapeutic benefit of mTOR inhibition in HNSCC.

1A

Tumor Characteristics and Biomarker Analysis

Patient	Location	P Stage	Differentiation	p16	p53	PTEN	EGFR
1	OP	TxN2b	PD	+	-	+	normal
2	OC	T4aN0	MD	-	+	+	normal
3	OP	Tis N0	PD	+	-	+	low
4	OP	T1 N2b	PD	+	+	+	normal
5	OP	T4a N2b	PD	+	-	-	normal
6	OC	T4a N2b	MD	-	+	+	high
7	OC	T2 N1	MD	-	+	+	high
8	OP	T4N2b	PD	+	-	+	normal
9	OC	T4 N2c	WD	-	+	+	normal
10	OC	T1 Nx	WD	-	+	-	high
11	OC	T2 N2b	MD	-	+	-	high
12	OP	T3 N1b	PD	+	-	+	normal
13	OC	T4a N2b	PD	+	-	+	normal
14	OC	T3 N2b	MD	-	+	+	high
15	OC	T0N1	MD	-	nd	nd	nd
16	OC	T1 N2b	PD	+	nd	nd	nd

1B

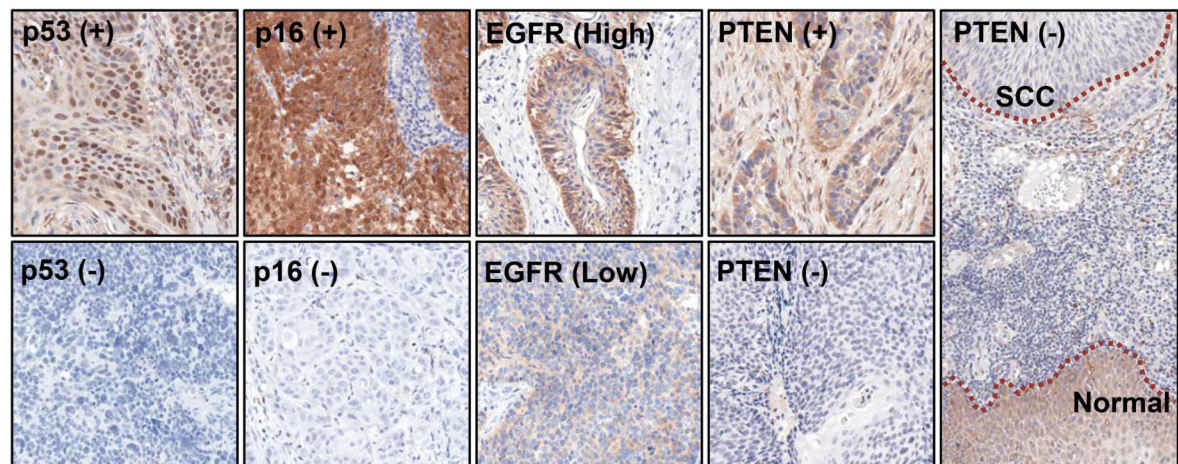


Figure 1. Tumor characteristics and biomarker analysis.

A. Cancer were located in the oral cavity (OC) or oropharynx (OP). P stage for each patient is indicated. Tumors were classified as well differentiated (WD), moderate differentiation (MD) or poorly differentiated (PD). All markers results are expressed as positive or negative, except for EGFR that is expressed in relation to the expression of the normal epithelium. nd: not determined. **B.** Examples of tumors positive and negative for p53 are shown in the first two panels (right). In the positive tumors, the expression is limited to the nuclei of the malignant proliferating cells. The negative example corresponds to a p16 positive case. In

the following panel, examples of p16 positive and negative tumors are shown. The protein is strongly expressed in both the cytoplasm and nuclei of the cancer cells. The negative example shown corresponds to a p53 positive case. EGFR, the figures depict examples of high and low expressors. The following three figures show examples of positive and negative PTEN tumors, and a stark histological comparison of a negative HNSCC (top of the last panel), as compared with the positive non-neoplastic epithelium of the same patient.

Author Manuscript

Author Manuscript

Author Manuscript

Author Manuscript

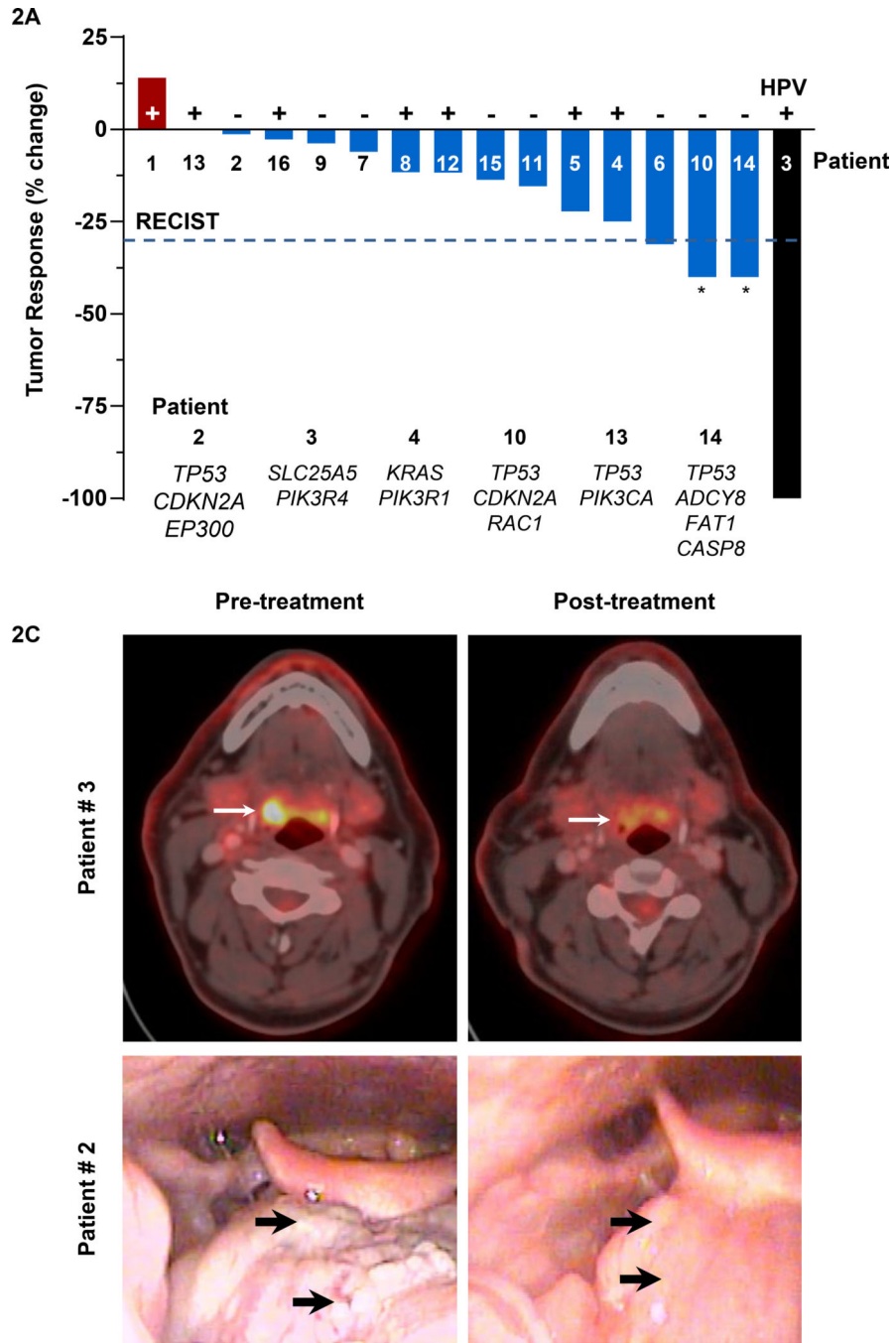


Figure 2. Clinical response to rapamycin.

A. A waterfall of the response to treatment is shown below, with most patient with high percentage of tumor volume change, and four with RECIST responses. *, patients evaluated clinically, all other patients were evaluated by CT scan. The individual patient responses as well as the status of HPV infection and profiles of common mutations in the HNSCC sequenced are depicted following the same numbering than in Figure 2. **B.** PET scan of patient 3, a complete response, before and after rapamycin therapy. The decrease in the affected area, as depicted in bright and yellow surrounded by a red outline, is evident in this

picture. While there was a residual lesion by visual inspection, it was biopsy-negative for cancer, which was confirmed by pathological evaluation of the resected tumor. Example of the response to treatment in another patient showing the visible changes in the tumor lesions. Tumor response was also dramatic.

Author Manuscript

Author Manuscript

Author Manuscript

Author Manuscript

Lymphocytes

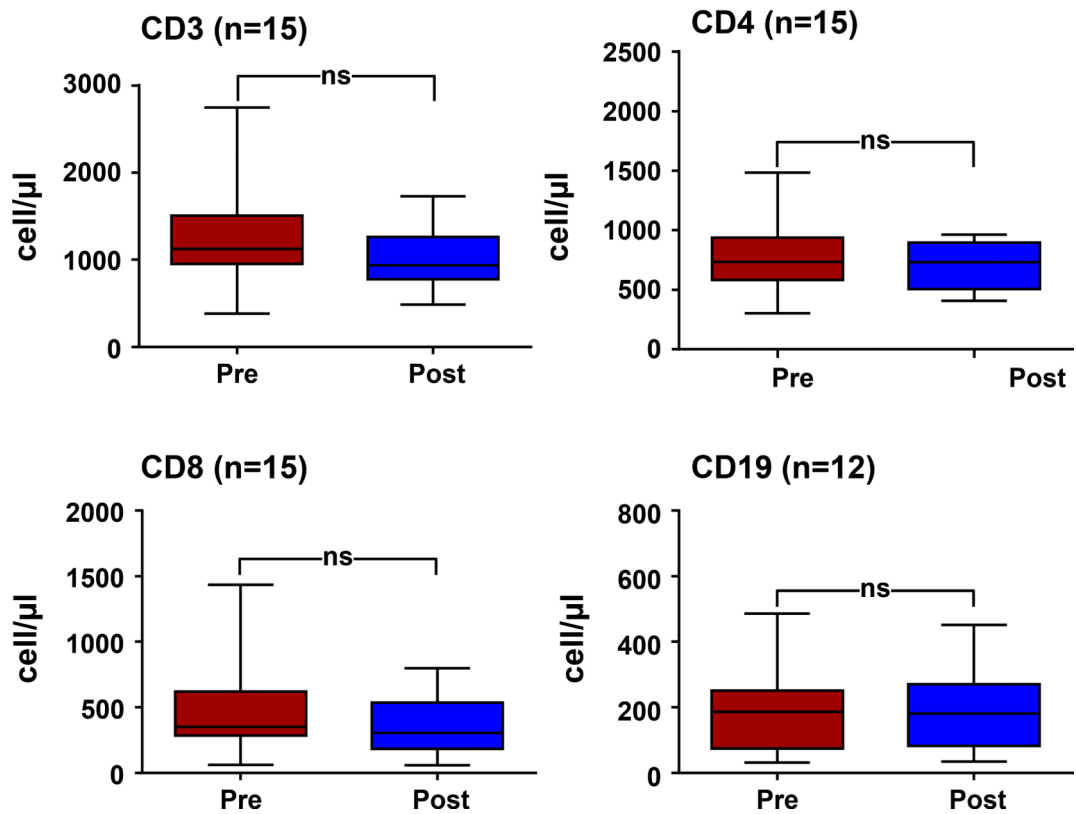


Figure 3. Impact of rapamycin on immune cell populations.

The lymphocytic subpopulations were evaluated in the blood of the patients at the initiation (pre) and end (post) of the rapamycin treatment, and whisker plots depicting the media included. ns: not significant differences. The corresponding number of patients evaluated (n) is also included.

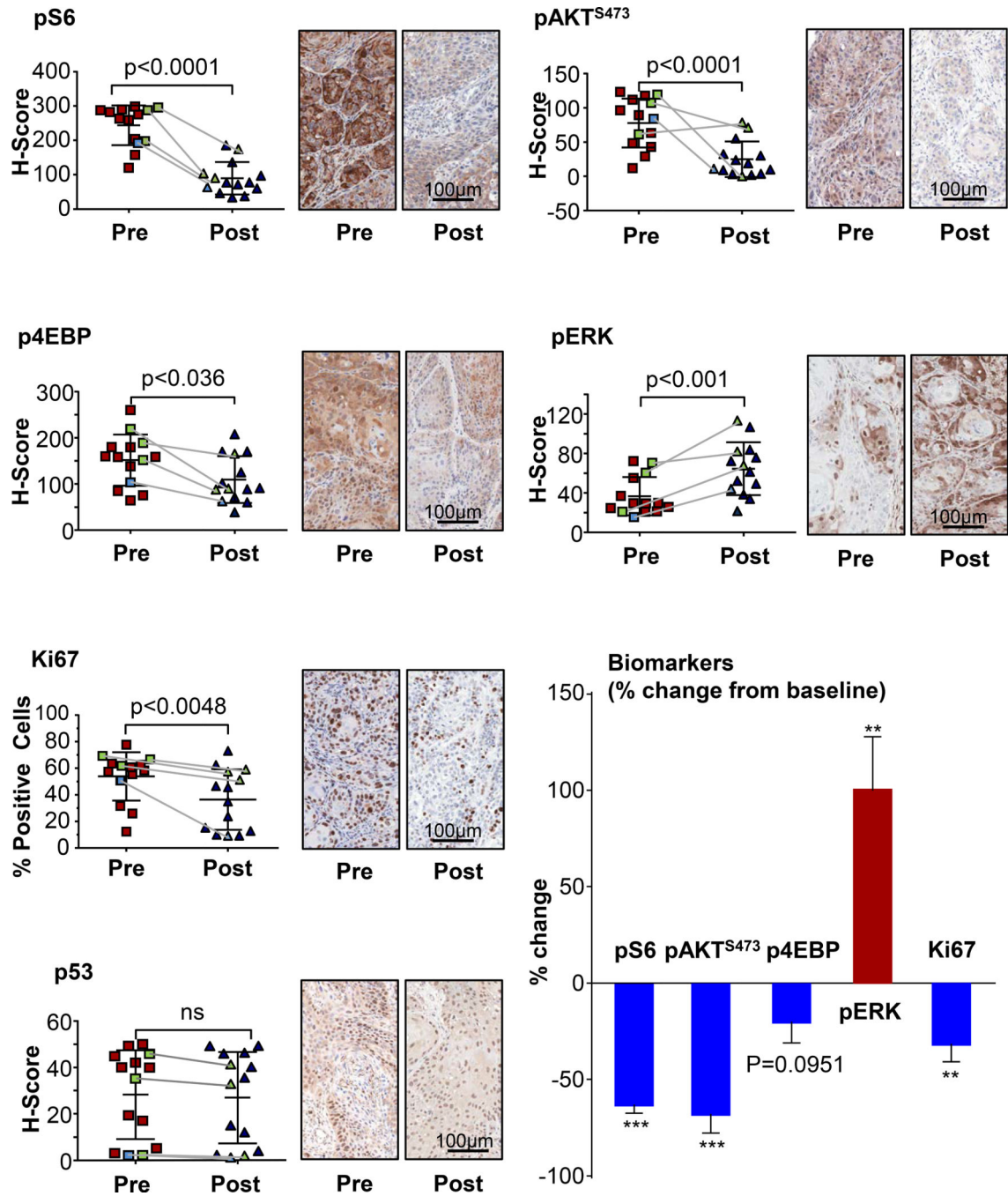


Figure 4. Impact of rapamycin on HNSCC signaling networks and proliferation. Quantification of the immunohistochemistry evaluations of pS6, p4EBP, and pAKT⁴⁷³ (surrogate indicators of mTOR pathway activity), together with the proliferation marker Ki-67, pERK, and p53 was evaluated and reported as H-Score pre- and post-rapamycin treatment, with the exception of Ki67 that is reported as % of positive cells. Pairwise analysis of % change from baseline is included. Statistical significance is indicated. **, p 0.01; ***, p 0.001; ns, not significant. Individual patients with a complete response (light

blue) and partial response (light green) are depicted, and their corresponding pre- and post-treatment results linked by a grey line.

Author Manuscript

Author Manuscript

Author Manuscript

Author Manuscript

Table 1.

General demographics and clinical stage at diagnosis. The general demographics of the patients enrolled in the trial and the clinical data are shown, including staging. In one patient the primary tumor could not be evaluated (TX). All patients presented with lymph node metastases (N1-N3), but none with evaluable distant metastases (MX and M0).

General Demographics (n=16)		Clinical Stage at Diagnosis – n (%)	
Gender – n (%)		Tumor Size	
Male	11 (68.8)	Tx	1 (6.3)
Female	5 (31.3)	T0	0
Age		Tis	0
Mean±SD	60.0±11.5	T1	0
Race - n (%)		T2	8 (50.0)
White	16 (100.0)	T3	4 (25.0)
Ethnicity - n (%)		T4a	3 (18.8)
Not Hispanic or Latino		T4b	0
Latino	15 (93.8)	Regional Lymph Nodes	
Hispanic or Latino	1 (6.3)	N0	0
Weight (Kg)		N1	5 (18.8)
Mean±SD	85.8±15.9	N2	5(31.3)
Height (cm)		N2a	1 (6.3)
Mean±SD	172.6±11.2	N2b	0
BMI (Kg/m²)		N2c	5(31.3)
Mean±SD	28.7±3.9	N3	2 (12.5)
Diagnoses		Distant Metastasis	
OC SCC	8	Mx	6 (37.5)
OR SCC	8	M0	10 (62.5)
		M1	0

Table 2.

Treatment side effects. Adverse events are listed based on the number of patients and percentage of patients affected (left), and the number and percentage of the corresponding severity (1–4, right).

Adverse Events	n	%	Grade n (%)			
			1	2	3	4
Thrombocytopenia	7	43.8	6 (37.5)	1 (6.3)	0	0
Neutropenia	4	25	4 (25)	0	0	0
Headaches	2	12.5	1 (6.3)	1 (6.3)	0	0
Hyperglycemia	1	6.3	1 (6.3)	0	0	0
Elevated Liver Enzymes	1	6.3	1 (6.3)	0	0	0
Mucositis	1	6.3	0	1 (6.3)	0	0
Anemia	1	6.3	1 (6.3)	0	0	0
Hypokalemia	1	6.3	0	0	1 (6.3)	0
Infection	1	6.3	0	1 (6.3)	0	0
Photosensitivity	1	6.3	1 (6.3)	0	0	0
Rash	1	6.3	1 (6.3)	0	0	0
Hypogeusia	1	6.3	0	1 (6.3)	0	0
Pain	1	6.3	0	1 (6.3)	0	0
Hot flushes	1	6.3	1 (6.3)	0	0	0