



ORIGINAL ARTICLE

The best radiographic method for determining root canal morphology in mandibular first premolars: A study of Chinese descendants in Taiwan



Yu Sun ^a, Tzu-Yi Lu ^b, Yi-Chen Chen ^{c,d}, Shue-Fen Yang ^{c,d*}

^a Department of Dentistry, Division of Endodontics, Taipei Tzu Chi Hospital, Buddhist Tzu Chi Medical Foundation, Taipei, Taiwan

^b Division of Endodontics, Konichiwa Dental Clinic, Tainan, Taiwan

^c Department of Stomatology, Division of Endodontics and Periodontology, Taipei Veterans General Hospital, Taipei, Taiwan

^d School of Dentistry, National Yang-Ming University, Taipei, Taiwan

Received 14 October 2015; Final revision received 15 January 2016

Available online 12 April 2016

KEYWORDS

mandibular first premolar;
root canal morphology;
complicated root canal anatomy;
sensitivity;
specificity;
diagnostic accuracy

Abstract *Background/purpose:* There is large variation in root canal morphology and undetected canals and incomplete instrumentation are reasons for root canal treatment failure. The purpose of this study was to determine the best radiographic method for determining root canal morphology in mandibular first premolars in Chinese descendants in Taiwan.

Materials and methods: Mandibular first premolars extracted due to caries, periodontal diseases, trauma, or for orthodontic reasons were used. Four indices were examined: (1) root canal bifurcation observed in the buccolingual view; (2) root canal continuity in the buccolingual view; (3) double root outline in the buccolingual view; and (4) Vertucci canal classification in the mesiodistal view.

Results: A total of 82 left and right mandibular first premolars were included, a complicated root canal was confirmed in 38 (46.3%) by cross-sectional imaging and a single root canal was found in 44 (53.7%). Bifurcation identified on the mesiodistal view exhibited the highest sensitivity (94.7%) and second highest specificity (88.6%) for identifying a complicated root canal; however, this view is not possible to obtain clinically. Canal bifurcation on the buccolingual view was the most specific (93.2%), but had the lowest sensitivity (73.7%). Canal continuity on the buccolingual view had a sensitivity of 94.7%, and specificity of 70.5%.

* Corresponding author. Department of Stomatology, Taipei Veterans General Hospital, Number 201, Section 2, Shih-Pai Road, Taipei 11217, Taiwan.

E-mail address: sfyang@vghtpe.gov.tw (S.-F. Yang).

Conclusion: Combined X-ray analyses, such as performing the buccolingual view for identification of canal bifurcation and canal continuity, may increase the accuracy of identifying complex root canal morphology.

Copyright © 2016, Association for Dental Sciences of the Republic of China. Published by Elsevier Taiwan LLC. This is an open access article under the CC BY-NC-ND license (<http://creativecommons.org/licenses/by-nc-nd/4.0/>).

Introduction

Root canal treatment depends on complete canal debridement and filling of the root canal system. Undetected canals and incomplete instrumentation are reasons for root canal treatment failure.¹ Variation in root canal anatomy is common, and has been shown to be associated with race and gender.^{2–4} To this end, knowledge of the morphology and variations of root canals is essential for successful endodontic treatment.

Canal anatomy of mandibular premolars has been shown to vary greatly. Studies have shown that mandibular first premolars with two or more canals occur in 13.7% of Caucasians in the United States and 46% of Chinese individuals.^{2,5} Another study has shown that the incidence of three canals in mandibular first premolars ranges from 0.4% to 2%.^{6,7} Furthermore, Fan et al^{8,9} reported that 24% or more of mandibular first premolars have C-shaped root canals.

Cone-beam computed tomography (CBCT) and micro-CT are commonly used in dentistry,¹⁰ and can accurately determine root canal morphology.^{11–16} However, CBCT and micro-CT are not available in all parts of the world, especially underdeveloped and developing countries, and due to the cost and dose of radiation periapical X-rays are still the most widely used method for determining root canal morphology prior to endodontic treatment.¹⁰ Accurate detection of complex canal morphology on X-ray is necessary to avoid missing root canals during treatment, but this can be difficult. Thus, the purpose of this study was to determine the best radiographic method for determining root canal morphology of mandibular first premolars.

Materials and methods

This study utilized mandibular first premolars extracted due to caries, periodontal disease, trauma, and other reasons at the Department of Oral and Maxillofacial Surgery of Taipei-Veteran General Hospital. Only first premolars with a mature and intact root structure and devoid of fractures were used. The details of the collection, preparation, and anatomical examination of the teeth have been previously published.⁵ This study was approved by the Institutional Review Board of the hospital, and all patients had previously provided informed consent for the dental procedures performed.

Both buccolingual and mesiodistal parallel radiographs were obtained for each tooth using a Size 2, E speed radiograph cassette (CEA AB, Strangnas, Sweden), and a

Heliident DS X-ray system (Sirona Dental Company, Bensheim, Germany). The source–object distance was 55 mm, and other parameters were 7 mA, 60 kVp, and a 0.12-second exposure time. Radiographs were developed with an automatic X-ray film processor (Dent-X 810 Basic Auto Film Processor; Dentx Visionary Imaging, Elmsford, NY, USA) and mounted. Each radiograph was examined independently by two endodontists, each with > 10 years' experience, using a 2 × magnifying viewer (JS Dental Manufacturing, Inc., Ridgefield, CT, USA) with a bright view box (King bright box, 5000 D × 10 W × 2; Asanuma & Co., Ltd., Hamamatsu, Shizuoka, Japan). The final analysis and findings of the radiographs were reached by consensus of the two reviewers.

Four indices were examined for their ability to identify complex root canal morphology: (1) root canal bifurcation observed in the buccolingual view; (2) root canal continuity in the buccolingual view; (3) double root outline in the buccolingual view; and (4) Vertucci canal classification in the mesiodistal view.¹⁷

Root canal continuity was classified as previously described.¹⁸ Briefly, the classifications were as follows: (A) large canal becoming less obvious, and may logically determine there is a bifurcation; (B) large canal becoming thinner and deviating towards one side, there may be one small and one large canal or furcated roots, and may logically determine that there is a bifurcation; (C) medium root canal, gradual tapering, cannot logically determine that there are two canals but proximal view may display a second root canal; and (D) buccolingual view shows a direct bifurcation.

Statistical analysis

Counts and percentages were calculated for the X-ray characteristics of the root canal configuration and outline of the root in both the bucco-lingual and mesio-distal views. To test the efficacy of the four indices, the sensitivity, specificity, positive predictive value (PPV), negative predictive value (NPV), accuracy, and positive and negative likelihood ratios (LRs) with 95% confidence intervals were calculated using the findings of standard of cross-sectional imaging as the gold standard. The indices were calculated by the following formulas.

Sensitivity (true positive rate) = (number of positive results / total number of complicated canals) × 100.

Specificity (true negative rate) = (number of negative results / total number of single canals) × 100.

PPV = (number of confirmed complicated canals / total number of positive results) \times 100.

NPV = (number of confirmed single canals / total number of negative results) \times 100.

Positive LR = ratio of the true positive to false positive rate = sensitivity / (1–specificity).

Negative LR = ratio of the false negative to true negative rate = (1–sensitivity) / specificity.

The index with relatively higher values in terms of the sensitivity, specificity, PPV, NPV, accuracy, and positive LR along with a lower negative LR was defined as the best index to identify a complicated root canal. The difference in accuracy among the four indices was examined by Cochran's Q test, followed by McNemar's test with Bonferroni correction for multiple *post hoc* comparisons. The significance level was defined as 0.05, with an adjusted significance level of 0.008 (0.05/6). All statistical analyses were two-sided, and performed with SAS version 9.2 software (SAS Inc., Cary, NC, USA).

Results

A total of 82 left and right mandibular first premolars were included in this study. A complicated root canal was confirmed in 38 (46.3%) by cross-sectional imaging, and a single root canal was found in 44 (53.7%) (Table 1). The three most common mesio-distal features identified on X-rays were root tapering (47, 57.3%), roots with a C-shaped configuration (13, 15.9%), and blunt roots (11, 13.4%). Of the 38 premolars with complicated root canals, 21 (55.3%) were Vertucci Type IV, six (15.8%) Type I, five (13.2%) Type III, four (10.5%) Type II, and two (5.2%) Type V.

Buccolingual X-rays showed that 67 (81.7%) premolars had tapering roots, eight (9.8%) had fissured roots, and seven (8.5%) had blunt or bulging roots. Root tapering and skew was found in 18.3% of canals, root tapering and shrinkage in 15.9%, root disappearance in 14.6%, and root bifurcation in 9.8%. Thirty-one (37.8%) bifurcated root canals were identified by the endodontists based on buccolingual features, among which 54.9% of the root canals were disappeared, 35.5% were deviated, and 9.6% were Vertucci Type IV. Root canal bifurcation was also identified in 49 premolars based on a double root outline in the buccolingual view, and in 41 premolars from the mesiodistal view.

The diagnostic efficacies of the four indices for detecting a complicated root canal are summarized in Table 2. The analysis indicated that bifurcation identified in the mesiodistal view exhibited the best diagnostic accuracy of 91.5%, the lowest negative LR, and higher values of the other measures. Additionally, the four indices showed varying degrees of accuracy ($P = 0.011$), and a difference between the canal continuity in buccolingual view and the bifurcation in mesiodistal view was noted (81.7% vs. 91.5%, $P = 0.004$). Likewise, the presence of a double root outline displayed lower accuracy than the morphological reading of the mesiodistal view (74.4% vs. 91.5%, $P = 0.001$).

Table 1 Canal configuration and X-ray characteristics of study teeth from the buccolingual and mesiodistal views.

| | No. | Percentage of total |
|--|-----|---------------------|
| Cross-sectional image | | |
| Single root canal | 44 | 53.7 |
| Complicated root canal | 38 | 46.3 |
| Outline of root in mesiodistal view | | |
| Continuous tapering | 47 | 57.3 |
| Blunt | 11 | 13.4 |
| Bulge | 6 | 7.3 |
| Bifurcated root | 4 | 4.9 |
| C-shaped/fissured root | 13 | 15.9 |
| Uncertain | 1 | 1.2 |
| Radiographic features of complicated canals in mesiodistal view ^a | | |
| Type I | 6 | 15.8 |
| Type II | 4 | 10.5 |
| Type III | 5 | 13.2 |
| Type IV | 21 | 55.3 |
| Type V | 2 | 5.2 |
| Outline of root in buccolingual view | | |
| Continuous tapering | 67 | 81.7 |
| Blunt | 1 | 1.2 |
| Bulge | 6 | 7.3 |
| C-shaped/fissured root | 8 | 9.8 |
| Canal configuration in buccolingual view | | |
| Normal | 33 | 40.2 |
| Disappeared root | 12 | 14.6 |
| Tapered and skewed root | 15 | 18.3 |
| Tapered and small root with a suspected second canal specified from P-view | 13 | 15.9 |
| Bifurcated root | 8 | 9.8 |
| Uncertain | 1 | 1.2 |
| Specified bifurcation in buccolingual view | | |
| No | 51 | 62.2 |
| Yes | 31 | 37.8 |
| Radiographic feature of complicated canal in buccolingual view ^b | | |
| Sudden disappearance of root canal | 17 | 54.9 |
| Sudden disappearance with canal deviation | 11 | 35.5 |
| Type IV canal | 3 | 9.6 |
| Double root outline in buccolingual view | | |
| No | 33 | 40.2 |
| Yes | 49 | 59.8 |
| Bifurcation in mesiodistal view | | |
| No | 41 | 50.0 |
| Yes | 41 | 50.0 |

^a Data were from 38 complicated canals identified by cross-sectional imaging.

^b Data were from 31 bifurcated roots identified by the buccolingual view.

Table 2 Diagnostic performance of X-ray characteristics to detect complicated root canal morphology.

| | Buccolingual view: canal bifurcation | Buccolingual view: canal continuity | Buccolingual view: double root outline (PDL double shadow) | Mesiodistal view: vertucci Type II–V |
|-------------|---|--|--|---|
| Sensitivity | 73.7% (56.9%, 86.6%) | 94.7% (71.9%, 95.6%) | 86.8% (82.3%, 99.4%) | 94.7% (82.3%, 99.4%) |
| Specificity | 93.2% (81.3%, 98.6%) | 70.5% (47.8%, 77.6%) | 63.6% (54.8%, 83.2%) | 88.6% (75.4%, 96.2%) |
| PPV | 90.3% (74.3%, 98.0%) | 73.5% (52.5%, 80.1%) | 67.3% (58.9%, 85.1%) | 87.8% (73.8%, 96.2%) |
| NPV | 80.4% (66.9%, 90.2%) | 93.9% (68.1%, 94.9%) | 84.8% (78.0%, 99.3%) | 95.1% (83.5%, 99.4%) |
| Accuracy | 84.1% (80.5%, 87.2%) | 81.7% (63.6%, 83.4%) | 74.4% (71.6%, 89.4%) | 91.5% (83.2%, 96.5%) |
| LR+ | 10.81 (3.57, 32.75) | 3.21 (2.02, 5.09) | 2.39 (1.58, 3.60) | 8.34 (3.64, 19.29) |
| LR– | 0.28 (0.16, 0.48) | 0.07 (0.02, 0.29) | 0.21 (0.09, 0.48) | 0.06 (0.02, 0.23) |

Data presented with (95% confidence interval).

LR– = negative likelihood ratio; LR+, positive likelihood ratio; NPV = negative predicted value; PDL = periodontal ligament; PPV = positive predicted value.

Representative tooth radiographs are shown in [Figures 1–4](#).

Discussion

This study investigated the diagnostic accuracy of different X-ray views for identifying complicated root canals of mandibular first premolars. Each premolar tooth was assessed in four different X-ray images by two endodontists, and the results were compared against those of anatomic pathological evaluation. The analysis indicated that bifurcation identified on the mesiodistal view exhibited the best diagnostic accuracy (91.5%) with the highest sensitivity (94.7%) and second highest specificity (88.6%) for identifying a complicated root canal. The reason that bifurcation identified on the mesiodistal view had the best diagnostic accuracy is likely because mandibular premolars have two root canals, which are in a buccolingual direction. However, the mesiodistal view is clinically impossible and X-ray films from different angles are necessary for diagnosis.¹⁹

Canal bifurcation identified on the buccolingual view was the most specific (93.2%) and had highest PPV (90.3%); however, it had the lowest sensitivity (73.7%). Canal continuity identified on the buccolingual view also had a high sensitivity (94.7%, identical to that of the mesiodistal view), but a lower specificity (70.5%). Taken together the results suggest that combined X-ray analyses, such as performing the buccolingual view for identification of canal bifurcation and canal continuity, may increase the accuracy of identifying complex root canal morphology.

Whereas the skills and knowledge of the endodontist are paramount for successful root canal treatment, radiographic analysis is important for determining canal morphology.¹⁰ Although micro-CT is highly accurate, in a typical practice X-ray is the most common tool used for examining root canals due to the cost and dose of radiation. Two-dimensional X-rays, however, often cannot effectively display the full anatomy of the root canal system, though a combination of X-rays from different angles may be useful.²⁰ England et al²¹ suggested that two X-rays with a 20° difference in angle combined with zooming can assist in

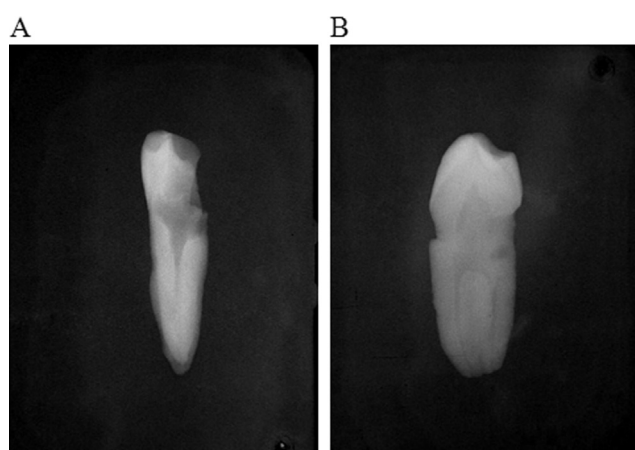


Figure 1 Representative Case 1; (A) buccolingual view. Canal reading: continuity A, root canal becomes unclear in the middle third of tooth root. Root reading: root outline in the middle and apical third is observed as a double root outline (PDL double shadow), apex bifurcation; (B) mesiodistal view shows a Vertucci Type IV canal.

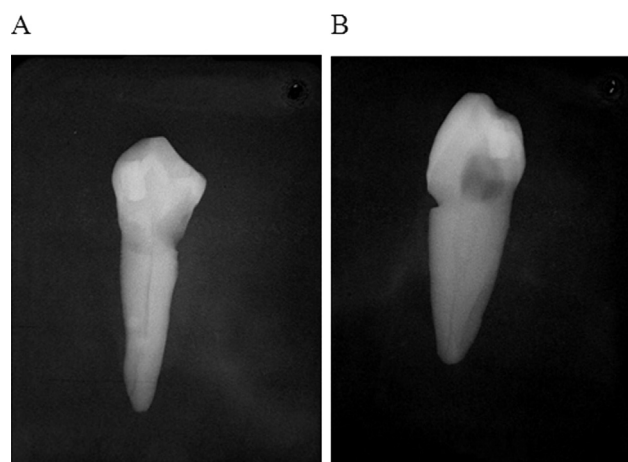


Figure 2 Representative Case 2; (A) buccolingual view. Canal reading: continuity B, shift to one side in the middle third of the tooth root. Root reading: root outline in the middle third is observed as a double root outline (PDL double shadow), apex bifurcation; (B) mesiodistal view: Vertucci Type II canal, fused in the middle third of the tooth.

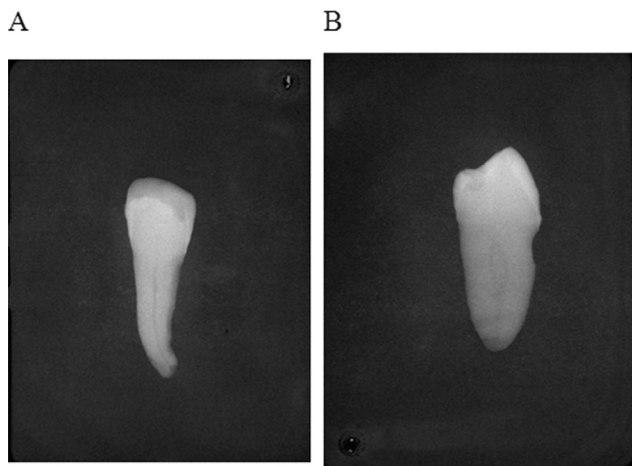


Figure 3 Representative Case 3; (A) buccolingual view. Canal reading: continuity C, medium root canal, gradual tapering, cannot logically determine that there are two canals but proximal view may display a second root canal. Root reading: root outline in the middle and apical third is observed as a double root outline (PDL double shadow), no bifurcation at the apex; (B) mesiodistal view: Vertucci Type II canal.

determining multicanal morphology of mandibular first premolars. Martínez-Lozano et al²² examined X-rays taken from different angles to view premolars, and found 20° and 40° angles to be effective in identifying multicanal morphology of mandibular first premolars. In a study by Yoshioka et al,¹⁸ four dentists interpreted the X-rays of 139 mandibular first premolars followed by cross-sectioning of the teeth to observe the root canal morphology. The authors found that a sudden narrowing of the main canal accurately predicted the existence of multicanal morphology and there was no statistically significant difference among the four dentists with respect to the coincidence rate (93%–96%) of the canal number evaluated on radiographs ($P > 0.05$). Literature reviews of human mandibular first and second premolar root canal morphology concluded that using a second X-ray with a 40° offset and zooming an image of sudden narrowing of the

canal may help diagnose mandibular first premolar variations.^{23,24}

Numerous studies have illustrated variation in root canal morphology. The aforementioned review of mandibular first premolars included data of > 6700 teeth, and found that ~98% were single-rooted, 1.8% had two roots, 0.2% had three roots, and < 0.1% had four roots.²³ A single canal was present in 75.8% of the teeth, two or more canals were found in 24.2% of the teeth, a single apical foramen was found in 78.9% of the teeth, and 21.1% had two or more apical foramina. With respect to racial variations, in an early study Amos²⁵ assessed 1000 patients and found that 16% of Caucasians and 21.6% of African Americans had bifurcated canals of the lower first premolar. Zillich and Dowson⁶ performed X-rays followed by opening the pulp chamber for inspection and reported that 23.1% of mandibular first premolars had multiple root canals. Trope et al² studied 400 African Americans and 400 Caucasians who received full mouth X-rays, and based on obvious changes in the density of the root canal space, a second periodontal ligament (PDL) contour, and root furcation, they reported that 13.7% and 32.8%, respectively, had multicanal morphology. In a study in Hong Kong, Walker⁷ examined 1000 mandibular first premolars and found multicanal morphology in 36%. Serman and Hasselgren²⁶ reported that 15.7% of dental patients had multicanal morphology, and Sabala et al²⁷ reported that 22.8% of patients had lower first premolar canal variation, the highest percentage of all teeth. A study in Kuwait that examined X-rays of teeth that had previous root canal treatment found that 40% of mandibular first premolars had more than one root canal.²⁰ In our prior study, we cross-sectioned 82 mandibular first premolars of the Chinese ethnicity and found 44% had complex root canal morphology, of which 22% had two canals, 18% had C-shaped canals, and 6% were circumferential at the apical area.⁵

Studies of multicanal morphology with respect to gender have provided inconclusive findings. For example, Sert and Bayirli⁴ studied Turks and found 44% of men and 35% of women had multicanal morphology. However, Serman and Hasselgren²⁶ found no significant difference in the occurrence of multicanal morphology between males and

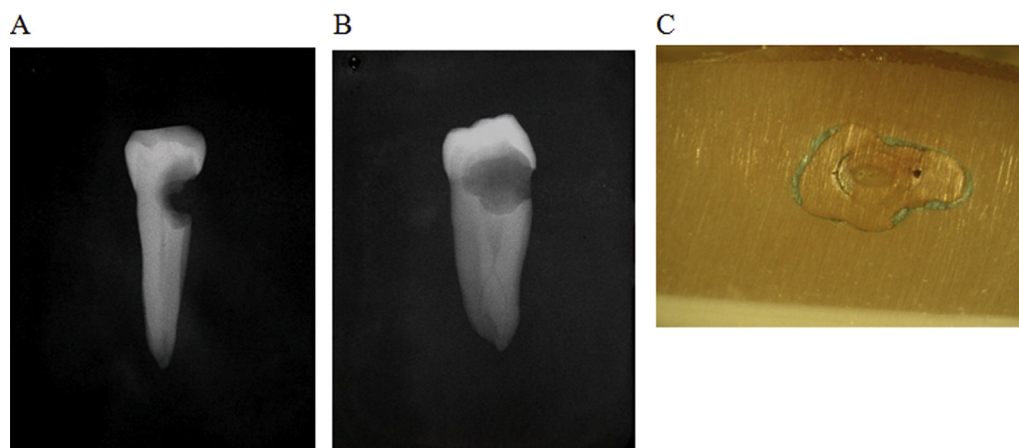


Figure 4 Representative Case 4; (A) buccolingual view. Canal reading: continuity E, direct bifurcation. Root reading: root outline in the middle third is observed as a double root outline (PDL double shadow), apex bifurcation; (B) mesiodistal view: Vertucci Type IV canal, bifurcation in the middle third of the tooth root; (C) section showing a C-shaped canal.

females. Some recent genetic studies have found multi-canal morphology of first premolars to be associated with X-chromosome mutations.^{28,29}

In this study the sensitivity of a double root outline on the buccolingual view for identifying complex root canal morphology was 86.8%; however, its specificity was 63.6% resulting in the lowest diagnostic accuracy of 74.4%. As determined by sectioning, there were 10 cases with a radicular groove, and the X-rays of those teeth all exhibited a double root outline. Two of 10 cases had one root canal, and the other eight cases had complicated canals. No relationship between a double root outline and radicular grooves was noted. Radicular grooves are developmental depressions on the surface of the root, and when they are present the area of the PDL may be increased.³⁰ Furthermore, X-ray images of teeth with radicular grooves may be misdiagnosed as having an extra root canal,¹⁶ and radicular grooves are associated with complicated root canal morphology.^{9,16,31} Studies have shown that radicular grooves are present in 24–41% of mandibular first premolars.^{9,15,16} Chen et al¹⁶ also reported that in Chinese mandibular first premolars the prevalence of radicular grooves in multiple and complex canals was 90.2%, which was much greater than the prevalence in single canals (17.4%).

There are limitations of this study that should be considered. Although considered highly accurate, the cross-sectioning method of evaluating root canal morphology may be inaccurate as a result of technical cone cut error. However, the use of teeth with pathologically confirmed root canal morphology as the gold standard is a strength of this analysis. Radiographic findings were obtained by consensus of the two readers, and thus no evaluation of inter- or intraobserver reliability was performed. This study used film X-rays, and currently digital X-rays are commonly performed. There may be differences in the interpretation of the two types of images,^{32–35} and this was not evaluated in the current study. An ideal method of performing the study would have been to perform digital radiographs prior to extraction of the teeth. Lastly, the number of teeth studied was limited; further study with a larger sample number should be performed to confirm the results.

In conclusion, although bifurcation identified on mesio-distal radiographs exhibits high diagnostic accuracy (91.5%) for identifying a complicated root canal, these images are not possible to obtain clinically. Combined X-ray analyses, however, such as performing the buccolingual view for identification of canal bifurcation and canal continuity, may increase the accuracy of identifying complex root canal morphology.

Conflicts of interest

The authors have no conflicts of interest relevant to this article.

References

1. Hoen MM, Pink FE. Contemporary endodontic retreatments: an analysis based on clinical treatment findings. *J Endod* 2002;28: 834–6.
2. Trope M, Efenbein L, Tronstad L. Mandibular premolars with more than one root canal in different race groups. *J Endod* 1986;12:343–5.
3. Awawdeh L, Abdullah H, Al-Qudah A. Root form and canal morphology of Jordanian maxillary first premolars. *J Endod* 2008;34:956–61.
4. Sert S, Bayirli GS. Evaluation of the root canal configurations of the mandibular and maxillary permanent teeth by gender in the Turkish population. *J Endod* 2004;30:391–8.
5. Lu TY, Yang SF, Pai SF. Complicated root canal morphology of mandibular first premolar in a Chinese population using the cross section method. *J Endod* 2006;32:932–6.
6. Zillich R, Dowson J. Root canal morphology of mandibular first and second premolars. *Oral Surg Oral Med Oral Pathol* 1973;36: 738–44.
7. Walker RT. Root canal anatomy of mandibular first premolars in a southern Chinese population. *Endod Dent Traumatol* 1988;4: 226–8.
8. Fan B, Ye W, Xie E, Wu H, Gutmann JL. Three-dimensional morphological analysis of C-shaped canals in mandibular first premolars in a Chinese population. *Int Endod J* 2012;45: 1035–41.
9. Fan B, Yang J, Gutmann JL, Fan M. Root canal systems in mandibular first premolars with C-shaped root configurations. Part I: Microcomputed tomography mapping of the radicular groove and associated root canal cross-sections. *J Endod* 2008; 34:1337–41.
10. Vandenberghe B, Jacobs R, Bosmans H. Modern dental imaging: a review of the current technology and clinical applications in dental practice. *Eur Radiol* 2010;20:2637–55.
11. Neelakantan P, Subbarao C, Subbarao CV. Comparative evaluation of modified canal staining and clearing technique, cone-beam computed tomography, peripheral quantitative computed tomography, spiral computed tomography, and plain and contrast medium-enhanced digital radiography in studying root canal morphology. *J Endod* 2010;36:1547–51.
12. Ok E, Altunsoy M, Nur BG, Aglarci OS, Çolak M, Güngör E. A cone-beam computed tomography study of root canal morphology of maxillary and mandibular premolars in a Turkish population. *Acta Odontol Scand* 2014;72:701–6.
13. Yang H, Tian C, Li G, Yang L, Han X, Wang Y. A cone-beam computed tomography study of the root canal morphology of mandibular first premolars and the location of root canal orifices and apical foramina in a Chinese subpopulation. *J Endod* 2013;39:435–8.
14. Yu X, Guo B, Li KZ, et al. Cone-beam computed tomography study of root and canal morphology of mandibular premolars in a western Chinese population. *BMC Med Imaging* 2012;12: 18.
15. Liu N, Li X, Liu N, et al. A micro-computed tomography study of the root canal morphology of the mandibular first premolar in a population from southwestern China. *Clin Oral Investig* 2013; 17:999–1007.
16. Chen J, Li X, Su Y, et al. A micro-computed tomography study of the relationship between radicular grooves and root canal morphology in mandibular first premolars. *Clin Oral Investig* 2015;19:329–34.
17. Vertucci FJ. Root canal anatomy of the human permanent teeth. *Oral Surg Oral Med Oral Pathol* 1984;58:589–99.
18. Yoshioka T, Villegas JC, Kobayashi C, Suda H. Radiographic evaluation of root canal multiplicity in mandibular first premolars. *J Endod* 2004;30:73–4.
19. Vertucci FJ, Haddix JE. *Tooth morphology and access cavity preparation. Pathways of the pulp*, 10th ed. St. Louis: CV Mosby, 2011:136–222.
20. Zaatari EI, al-Kandari AM, Alhomidah S, al-Yasin IM. Frequency of endodontic treatment in Kuwait: radiographic evaluation of 846 endodontically treated teeth. *J Endod* 1997;23:453–6.

21. England Jr MC, Hartwell GR, Lance JR. Detection and treatment of multiple canals in mandibular premolars. *J Endod* 1991;17:174–8.
22. Martínez-Lozano MA, Forner-Navarro L, Sánchez-Cortés JL. Analysis of radiologic factors in determining premolar root canal systems. *Oral Surg Oral Med Oral Pathol Oral Radiol Endod* 1999;88:719–22.
23. Cleghorn BM, Christie WH, Dong CC. The root and root canal morphology of the human mandibular first premolar: a literature review. *J Endod* 2007;33:509–16.
24. Cleghorn BM, Christie WH, Dong CC. The root and root canal morphology of the human mandibular second premolar: a literature review. *J Endod* 2007;33:1031–7.
25. Amos ER. Incidence of bifurcated root canals in mandibular bicuspids. *J Am Dent Assoc* 1955;50:70–1.
26. Serman NJ, Hasselgren G. The radiographic incidence of multiple roots and canals in human mandibular premolars. *Int Endod J* 1992;25:234–7.
27. Sabala CL, Benenati FW, Neas BR. Bilateral root or root canal aberrations in a dental school patient population. *J Endod* 1994;20:38–42.
28. Varrela J. Root morphology of mandibular premolars in human 45 X females. *Arch Oral Biol* 1990;35:109–12.
29. Kusiak A, Sadlak-Nowicka J, Limon J, Kocharńska B. Root morphology of mandibular premolars in 40 patients with Turner syndrome. *Int Endod J* 2005;38:822–6.
30. Simon JH, Dogan H, Ceresa LM, Silver GK. The radicular groove: its potential clinical significance. *J Endod* 2000;26:295–8.
31. Gu Y, Zhang Y, Liao Z. Root and canal morphology of mandibular first premolars with radicular grooves. *Arch Oral Biol* 2013;58:1609–17.
32. Parissis N, Kondylidou-Sidira A, Tsirlis A, Patias P. Conventional radiographs versus digitized radiographs: image quality assessment. *Dentomaxillofac Radiol* 2005;34:353–6.
33. Malleshi SN, V G M, Raina A, Patil K. A subjective assessment of perceived clarity of indirect digital images and processed digital images with conventional intraoral periapical radiographs. *J Clin Diagn Res* 2013;7:1793–6.
34. Akcay I, Ilhan B, Dundar N. Comparison of conventional and digital radiography systems with regard to radiopacity of root canal filling materials. *Int Endod J* 2012;45:730–6.
35. Parissis N, Angelopoulos C, Mantegari S, Karamanis S, Masood F, Tsirlis A. A comparison of panoramic image quality between a digital radiography storage phosphor system and a film-based system. *J Contemp Dent Pract* 2010;11:E009–16.