



## Case report

# Long term control of luteinized thecoma with sclerosing peritonitis with leuprorelin and tamoxifen treatment

Muratori L.<sup>a,\*</sup>, Gorzegno G.<sup>a</sup>, Sperone P.<sup>a</sup>, Andreozzi A.<sup>c</sup>, Di Maio M.<sup>b</sup>, Scagliotti G.V.<sup>a</sup>

<sup>a</sup> Medical Oncology, Department of Oncology, University of Turin, Azienda Ospedaliera Universitaria San Luigi Gonzaga, Regione Gonzole 10, 10043 Orbassano, Turin, Italy

<sup>b</sup> Medical Oncology, Department of Oncology, University of Turin, Azienda Ospedaliera Ordine Mauriziano, Corso Re Umberto 109, 10128 Turin, Italy

<sup>c</sup> Anatomopathology, Department of Pathology, University of Turin, Azienda Ospedaliera Universitaria San Luigi Gonzaga, Regione Gonzole 10, 10043 Orbassano, Turin, Italy

## ARTICLE INFO

## Keywords:

Thecoma  
Sclerosing  
Peritonitis  
Hormonal  
Therapy  
Ovary

## ABSTRACT

**Background:** Luteinized thecoma with sclerosing peritonitis (LTSP) is a very rare condition, and its clinical management is not evidence-based. Here we describe a case of long-term disease control achieved with leuprorelin and tamoxifen therapy.

**Case presentation:** A 18-year-old woman with acute abdomen underwent surgical removal of an ovarian mass and received diagnosis of LTSP. Treatment plan consisted of leuprorelin and tamoxifen, followed by a good instrumental response. After 5 years, leuprorelin was stopped, and the patient continued tamoxifen alone. Ten years after diagnosis, she is still disease free.

**Conclusion:** Even in the absence of solid evidence, the combination of leuprorelin and tamoxifen could be considered as a possible medical treatment of LTSP. Considering the limitations related to the rarity of disease, further studies are needed to improve its management.

## 1. Introduction

Thecoma is a very uncommon cancer, originated by ovarian theca cells, that represents less of 5% of all ovarian cancers (Chechia et al., 2008). It arises normally in young and midlife women, presenting as a single round mass in the abdomen. An even rarer variant of thecoma is luteinized thecoma with sclerosing peritonitis (LTSP). This entity was originally described in 1994 and represents less than 0.01% of all ovarian cancers (Clement et al., 1994). Sclerosing peritonitis, that is a complication of this kind of cancer, consists of an abnormal proliferation of fibroblasts below the mesothelium, resulting in the growth of a mass of fibrous tissue that incorporates abdominal organs (Iwasa et al., 1996). The consequence is the progressive incarceration of intestinal loops, followed by clinically relevant gut obstruction. Nowadays, the pathogenesis of LTSP is still unknown; an association between this condition and antiepileptic drugs administration was proposed based on clinical observations (Levavi et al., 2009). Currently, there are no clear guidelines about the management of LTSP, and the few available evidences are mostly based on the description of single cases. Surgery is burdened by a high mortality rate; therefore, it is normally reserved to

the emergency treatment of intestinal obstruction. Regarding the pharmacological therapy, a single case of objective response to hormonal therapy has been reported in literature: after surgical resection of thecoma, a 39-year-old patient was treated with toremifene and leuprorelin, achieving the complete regression of peritoneal lesions after 3 months of therapy (Bianco et al., 2005). Another case report showed a similar therapeutic result with the combination of corticosteroid and leuprorelin in a 25-year-old patient with LTSP (Schonman et al., 2008). Here we report the very long follow-up (10 years) of an 18-year-old woman affected by LTSP, treated with leuprorelin and tamoxifen.

## 2. Case presentation

An 18-year-old woman was admitted to the emergency room in February 2008 because of the progressive onset of severe abdominal pain. An exploratory laparotomy was performed, showing appendicitis, and a right ovarian mass. The patient underwent appendectomy and left salpingo-oophorectomy, and a biopsy of the ovarian mass was performed, without removing the mass. The histological exam showed only cells of ovarian fibroma with hemorrhagic infarction. One month

\* Corresponding author.

E-mail addresses: [leonardo.muratori@unito.it](mailto:leonardo.muratori@unito.it) (L. Muratori), [g.gorzegno@sanluigi.piemonte.it](mailto:g.gorzegno@sanluigi.piemonte.it) (G. Gorzegno), [a.andreozzi@sanluigi.piemonte.it](mailto:a.andreozzi@sanluigi.piemonte.it) (A. Andreozzi), [massimo.dimaio@unito.it](mailto:massimo.dimaio@unito.it) (M. Di Maio), [giorgio.scagliotti@unito.it](mailto:giorgio.scagliotti@unito.it) (G.V. Scagliotti).

<https://doi.org/10.1016/j.gore.2019.02.004>

Received 12 December 2018; Received in revised form 12 February 2019; Accepted 14 February 2019

Available online 16 February 2019

2352-5789/© 2019 The Authors. Published by Elsevier Inc. This is an open access article under the CC BY-NC-ND license (<http://creativecommons.org/licenses/by-nc-nd/4.0/>).

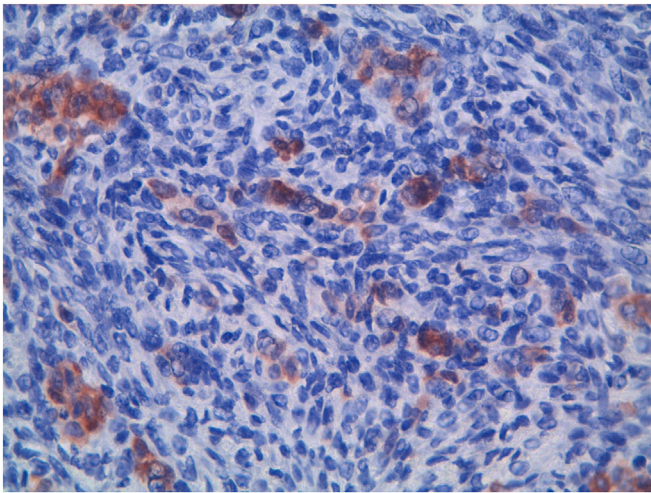


Fig. 1. Cells of thecoma, immunohistochemistry positive for inhibin (40×).

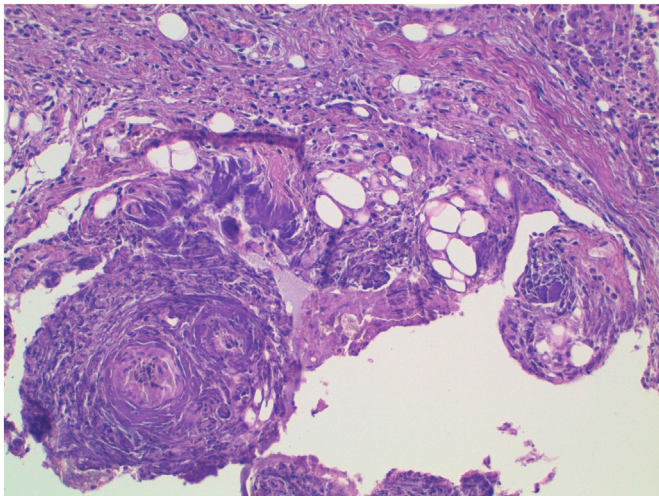


Fig. 2. Sclerosing peritonitis with granulomas and foreign-body giant cells (20×).

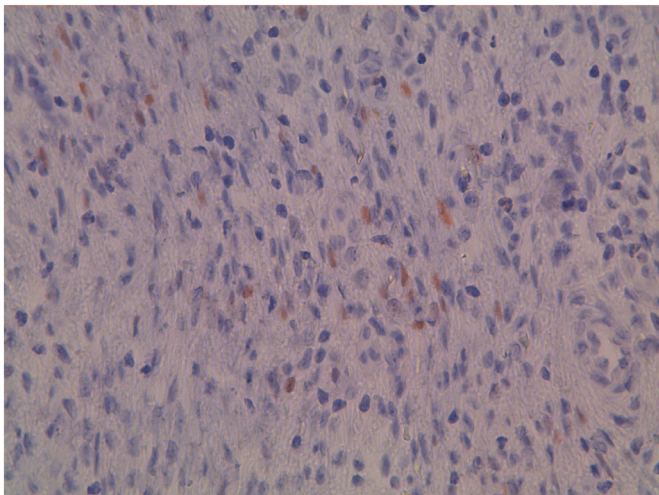


Fig. 3. Immunohistochemical expression of estrogen-receptors (40×).

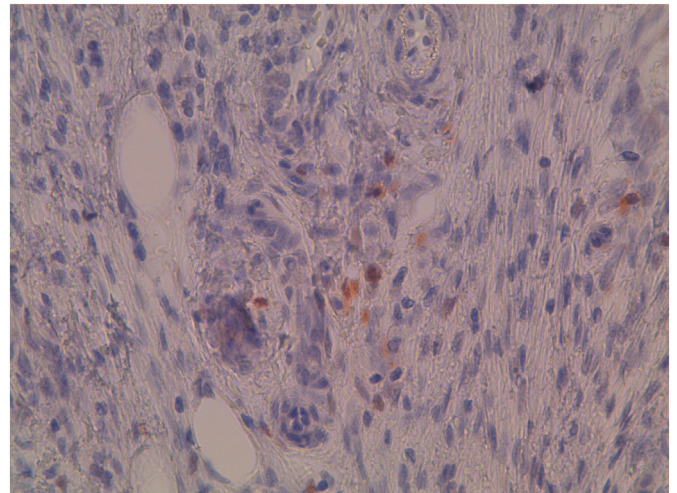


Fig. 4. Immunohistochemical expression of progesterone-receptors (40×).

well as a portion of peritoneum. The histological examination showed cells of luteinized thecoma (Fig. 1), associated with follicular cysts and granulosa-cells hyperplasia, and sclerosing peritonitis with foreign-body giant cells (Fig. 2). Expression of estrogen-receptors (Fig. 3) and progesterone-receptors (Fig. 4) was detected by immunohistochemistry on thecoma cells. No assumption of antiepileptic drugs was reported by the patient. The case was initially assessed by gynecologist and hormonal therapy with the aromatase inhibitor letrozole, 2.5 mg/day was suggested. Because of the extreme rarity of the disease, the patient was collectively evaluated by a multidisciplinary team of gynecologists and oncologists, in June 2008. A treatment with leuporelin 3.75 mg/month and tamoxifen 20 mg/day was started and the hormonal therapy with letrozole was suspended. In the next two months, the patient experienced a relevant clinical improvement, moving to a regular function of bowel and she regularly restarted oral intake of food. A single episode of severe vomiting occurred in May 2008, and the patient underwent a CT scan that showed a thickening of intestinal loops, compatible with sclerosing peritonitis, and a mild amount of peritoneal effusion. However, this episode resolved spontaneously, and the patient continued the hormonal treatment with leuporelin and tamoxifen. In December 2009, after 18 months of disease stabilization and progressive resorption of peritoneal effusion, as showed in two follow-up CT scans, the patient had a new episode of partial bowel obstruction. At that time, an MRI of abdomen was conducted, showing that the sclerosing peritonitis was substantially unchanged. During next four years, the patient did not develop any other episode of complete or partial bowel obstruction, but a bone densitometry showed a condition of osteoporosis (T-score of femoral neck:  $-2.1$ ), and a therapy with zoledronic acid (a single intravenous infusion of 5 mg, administered once a year) was initiated. Because of the complete absence of symptoms, no radiological re-assessments were conducted until October 2013, when a new CT scan showed the complete regression of peritoneal lesions. Based on this favorable CT findings, and considering the time elapsed from diagnosis, after multidisciplinary re-assessment, therapy with leuporelin was stopped, while continuing tamoxifen. In February 2014, after five years, also the treatment with zoledronic acid was suspended. In April 2014, the patient underwent a further CT scan, that confirmed the absence of the relapse of the disease. Nowadays, the patient is continuing her follow-up, and since the last CT scan, she did not show any sign or symptom related to the relapse of the disease. In April 2018, within multidisciplinary re-assessment, considering the time of ten years elapsed from starting of hormonal treatment with leuporelin and tamoxifen, the decision to stop tamoxifen was taken.

later, due to the occurrence of a partial bowel obstruction, the patient was again referred to the surgeons. Another laparotomy was performed and the ovarian mass in the right ovary was completely removed, as

### 3. Discussion

To our knowledge, this case represents the first experience of a long-term disease control in a patient with LTSP treated with leuporelin for 5 years and tamoxifen for 10 years. LTSP is a very uncommon disease, with a few cases reported in literature and scanty evidence about effective treatments. The first attempts of a systemic treatment for this disease were based on the hypothesis that hormonal stimulation could drive the growth of this neoplasm, even triggering the formation of fibrous tissue in the peritoneum. At the same time, tamoxifen had already shown activity in the treatment of fibrosis associated with peritoneal dialysis, a clinical-radiological condition similar to thecoma-related sclerosing peritonitis (Bajo et al., 2003). In the present case, a hormonal therapeutic approach with an aromatase inhibitor, not justified by the existing evidence, was initially attempted, but shortly interrupted thereafter in favor of a treatment with leuporelin plus tamoxifen, based on the already mentioned case report that, at the time of diagnosis, represented the only treatment experience that had demonstrated activity (Bianco et al., 2005). However, the management of the disease was not without complications. First of all, the clinical history was characterized, mainly in the first years, by repeated episodes of partial bowel obstruction caused by the develop of abdominal adhesions, which was followed by a progressive impairment of food oral intake and weight loss, as well as therapy discontinuation. Secondly, the effect of bone depletion induced by leuporelin prevailed over the bone protective effect of tamoxifen, causing osteoporosis that required bisphosphonate therapy. However, hormonal therapy has been successful and the patient now, disease-free ten years after diagnosis, could be considered potentially healed. Nowadays, despite the time elapsed, the evidence about the treatment of this disease is substantially unchanged. In 2008, a review of 27 cases of LTSP was published, in which the immunohistochemical profile of the primary ovarian lesion was evaluated, reporting that a subgroup of patients had tumor cells expressing estrogen (ER) and progesterone (PgR) receptors (Staats et al., 2008). This receptor status would justify the successes obtained with hormonal therapy, but at the same time it suggests that patients benefiting from this approach could represent only a subgroup of the overall group of patients with a diagnosis of thecoma. In the future, patients with thecoma should be investigated for the

immunohistochemical positivity of ER and PgR receptors, which could help to select the patients who would most likely benefit from hormonal treatment. However, the rarity of the disease makes hard to adequately describe the interaction between the efficacy of treatments and potential predictive factors. Generally, the rarity of the disease makes unrealistic any attempt to perform randomized clinical trials and produce solid evidence-based treatment guidelines. Therefore, reporting the clinical experience of individual cases or collecting retrospective series represent a potentially useful way to accumulate novel data, that over time could potentially improve the management of this rare disease.

#### Author contribution

All authors contributed equally to the paper.

#### Conflict of interest statement

All authors declare to have no conflict of interest.

#### References

- Bajo, M.A., et al., 2003. Clinical experience with tamoxifen in peritoneal fibrosing syndromes. In: *Advances in Peritoneal Dialysis. Conference on Peritoneal Dialysis*. vol. 19.
- Bianco, R., et al., 2005. Ovarian luteinized thecoma with sclerosing peritonitis in an adult woman treated with leuprolide and toremifene in complete remission at 5 years. *Gynecol. Oncol.* 96 (3), 846–849.
- Chechia, A., et al., 2008. Incidence, clinical analysis, and management of ovarian fibromas and fibrothecomas. *Am. J. Obstet. Gynecol.* 199 (5), 473–e1.
- Clement, P.B., et al., 1994. Sclerosing peritonitis associated with luteinized Thecomas of the ovary: a clinicopathological analysis of six cases. *Am. J. Surg. Pathol.* 18 (1), 1–13.
- Iwasa, Y., et al., 1996. Sclerosing peritonitis associated with luteinized thecoma of the ovary. *Pathol. Int.* 46 (7), 510–514.
- Levavi, H., et al., 2009. Sclerosing peritonitis associated with bilateral luteinized thecoma, linked to anticonvulsant therapy. *Eur. J. Gynaecol. Oncol.* 30 (6), 695–700.
- Schonman, R., et al., 2008. Luteinized thecoma associated with sclerosing peritonitis—conservative surgical approach followed by corticosteroid and GnRH agonist treatment—a case report. *Gynecol. Oncol.* 111 (3), 540–543.
- Staats, P.N., et al., 2008. Luteinized thecomas (thecomatosis) of the type typically associated with sclerosing peritonitis: a clinical, histopathologic, and immunohistochemical analysis of 27 cases. *Am. J. Surg. Pathol.* 32 (9), 1273–1290.