

Cyst volume changes measured with a 3D reconstruction after decompression of a mandibular dentigerous cyst with an impacted third molar

Faouzi Riachi,¹

Carla Maria Khairallah,¹ Nabil Ghosn,²

Antoine Nicolas Berberi³

¹Department of Oral Surgery, Faculty of Dental Medicine, St-Joseph University;

²Department of Oral and Maxillofacial Radiology, Faculty of Dental Medicine, St-Joseph University; ³Department of Oral and Maxillofacial Surgery, Faculty of Dental Medicine, Lebanese University, Beirut, Lebanon

Abstract

The aim of this article is to describe a large mandibular cyst treated with decompression followed by surgical enucleation. Furthermore, we described the utility of cyst volume measurements by using a 3D reconstruction on Cone Beam Computed Tomography (CBCT). The dentigerous cyst is the most common cyst type of epithelial origin, arising from remnants of odontogenic epithelium, asymptomatic and associated with the crown of an unerupted or partially or completely impacted tooth. However, after a long duration and extension of the cyst volume it may provoke significant bone resorption, cortical expansion, tooth displacement and the vitality of neighboring teeth may be affected. The regular treatment of this lesion is enucleation and extraction of the involved tooth. Marsupialization and decompression are proposed when the volume of the cyst is well developed to release the cystic pressure and allow the bone cavity to progressively decrease in volume with the gradual apposition of bone. This report presents a large dentigerous cyst related to impacted mandibular third molar of a 21-year-old male patient. The cyst was treated successfully by decompression and later by surgical enucleation with surgical extraction of the related molar. In conclusion, the combination of decompression and surgical approach showed on the three-dimensional CBCT investigation a significant correlation between the treatment and volume reduction of the cyst. The clinical case described allows us to observe bone formation after decompression and surgical enucleation was performed with less risk on vital anatomic elements.

Introduction

Odontogenic cysts, in almost all classifications, are divided into two major groups: developmental and inflammatory. Some cysts arise from the proliferation of epithelial residues left behind during odontogenesis; such cysts are generally described as being developmental in origin.^{1,2} While other types arise from epithelial hyperplasia of the residues due to adjacent foci of inflammation as a consequence of the two major dental diseases, decays and periodontal disease; such cysts are generally described as being inflammatory in origin.^{3,4}

The dentigerous cyst is the second most common odontogenic cyst^{5,6} and represent 22.3 % of odontogenic cysts.⁷ Dentigerous cysts have the potential to bone resorption and can expand into the surrounding tissue and tooth roots causing malocclusion or facial asymmetry⁸ or mandibular paresthesia.⁹ The diagnosis is not based only on the radiographic evaluation alone, a histopathologic exam must be conducted to confirm it.¹⁰ The keratocysts and unilocular ameloblastomas are commonly misdiagnosed with dentigerous cysts because conventional ameloblastoma show cystic degeneration with no biologic differences. The unilocular ameloblastoma represents an ameloblastoma, which presents as a cyst and has a lower recurrence rate following conservative removal. The histopathologic detection is recognized by luminal, intraluminal, and mural types depending on whether only the cyst lining is affected or not.¹¹ These cysts vary in size; if allowed to enlarge, they may, over time, cause significant bony expansion and destruction of large portions of the bone.¹² Plus, they may spread to adjacent anatomical structures such as the maxillary sinus or nasal cavity due to the increasing intra-cystic pressure.¹² However, this cyst is asymptomatic in majority^{9,13} and discovered on dental radiographs usually appearing as a well-defined radiolucency associated with the crown of an unerupted tooth.¹⁴ Marsupialization of odontogenic cystic was described by Partsch in 1892, it is a technique where a large window is made in cystic wall and then sutured to the oral mucosa.¹⁵ Marsupialization has the advantage of reducing the cyst volume.¹⁵ For those cases when no eruption occurs, a period of 3 to 4 months after marsupialization is suggested as critical time for deciding whether to extract or conserve.¹⁵ The aim of this paper is to present a case report of the treatment of a large odontogenic cyst in the retro-molar region of the lower jaw by decompression,

Correspondence: Antoine Nicolas Berberi, Department of Oral and Maxillofacial Surgery, Faculty of Dental Medicine, Lebanese University, P.O. Box: 5208-116 Beirut, Lebanon.
E-mail: aberberi@ul.edu.lb - anberberi@gmail.com
Tel.: +961.3731173 - Fax: +961.4533060.

Key words: Dentigerous cyst; Mandibular; Decompression; Three-dimension; Cone Beam Computed Tomography.

Contributions: CMK and NG: conception and design, acquisition of data, analysis and interpretation of data; FR and ANB: drafting the article, critical revision of the article; ANB: final approval of the version to be published.

Conflict of interest: the authors declare no potential conflict of interest.

Funding: none.

Received for publication: 1 February 2019.
Revision received: 18 February 2019.
Accepted for publication: 18 February 2019.

This work is licensed under a Creative Commons Attribution NonCommercial 4.0 License (CC BY-NC 4.0).

©Copyright F. Riachi et al., 2019
Licensee PAGEPress, Italy
Clinics and Practice 2019; 9:1132
doi:10.4081/cp.2019.1132

with a 12 months clinical and radiological follow-up.

Case Report

A 21-year-old male reported to the department of oral surgery at the Saint Joseph University in Beirut, with the main complaint of swelling in his lower left jaw. The swelling was growing for the past 3 weeks with no history of pain, numbing or any other complaints. Patient had no history of systemic or local contraindications, including uncontrolled diabetes, bruxism, smoking, or uncontrolled periodontal disease.

Clinical and radiological examination

The face was asymmetric with a small swelling on the left side of the mandible angle. The overlying skin was normal and light swelling was palpable on the sub-mandibular lymph nodes. The vitality test was negative for the left first and second molars, positive on the first and second mandibular left premolars and the test of paresthesia was negative. Intra-orally, there

was a sensitive swelling posterior to the molars with a hard bony on palpation. The color of the overlying mucosa was normal (Figure 1A). Panoramic radiograph showed a radiolucent lesion, unilocular, in contact with the impacted third molar with the crown of the tooth and the roots of the two other molars and the second premolar completely involved in the lesion. Resorption appear on the roots of the second molar. The inferior alveolar nerve is repressed to the basal bone of the lower jaw (Figure 1B). Axial and coronal cuts of the Cone Beam Computed Tomography (CBCT) showed a radiolucency, ball-shaped, measuring 30.29×43.19×37.26 mm (Figure 2A, B). The differential diagnosis was a dentigerous cyst or odontogenic keratocyst tumor or a unicystic ameloblastoma.

Biopsy

The importance of the biopsy was discussed with the patient and he gave his approval. Preoperatively, the patient rinsed with 0.12% chlorhexidine gluconate oral rinse (PerioGard; Colgate-Palmolive, Salford, United Kingdom) 5 minutes before the surgery. Local analgesia was achieved by inferior alveolar nerve block 2% articaine with 1:100,000 adrenaline (3M ESPE, Seefeld, Germany). Buccal mucosa was also anesthetized by infiltration close to the second molar. A sample of the intra-cystic fluid was aspirated by a fine needle syringe. The aspiration revealed a clear, light-yellow fluid with shiny cholesterol crystals.

Muco-periosteal flap was reflected by sulcular incision from the second premolar to the second molar with a distal buccal releasing incision, and a part of the cyst membrane was dissected and fixed in 10% formaldehyde (Merck, Darmstadt, Germany).

The flap was adjusted and hermetically closed by means of single sutures (Vicryl® 4/0, Johnson & Johnson, medical limited, UK).

Histopathological examination

The cystic border was composed of fibrous tissue, lined with a non-keratinized stratified squamous epithelium. The liquid contained a hematologic smear with polymorphous leucocytes as well as foamy or pigmented macrophages. The results came as a dentigerous cyst with no sign of malignity (Figure 2C, D).

From a practical standpoint, dentigerous cysts are differentiated from keratocysts by the absence of specific features: parakeratosis, palisaded basal layer and corrugated surface.³

Treatment plan

After the histological findings, treatment modalities, enucleation, marsupialization and decompression were discussed with the patient and he accepted our plan to do a decompression followed by enucleation and surgical extraction of the impacted molar after the endodontic treatment of the non-vital first and second left molars. The patient was informed to have a strict soft food diet, to avoid any complication such as mandibular fracture.

Decompression

Under local anesthesia as described before, a triangular distal wedge incision was performed, with the base of the triangle on the distal surface of the second molar. Copious irrigation with physiological saline serum was realized to evacuate all the intra-cystic fluids. The opening was adjusted to suit the confectioned acrylic stent. The patient was prescribed Amoxicillin + Clavulanic acid 1g, BID for 7 days.

Analgesic medication (400 mg ibupro-

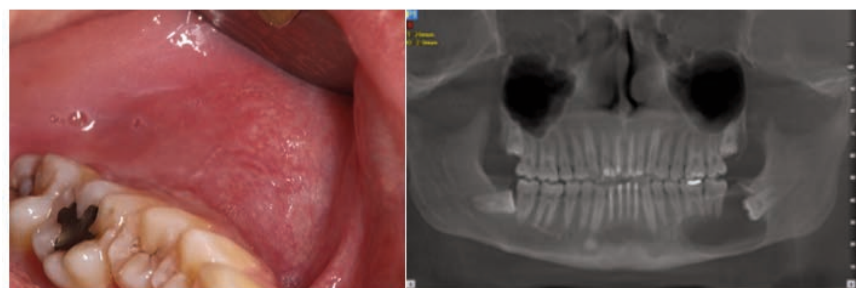


Figure 1. (A) Initial photograph of the left side of the mandible showing posterior swelling and a normal color of the overlying mucosa; (B) Initial panoramic radiograph reconstructed from the cone beam computed tomography (CBCT).

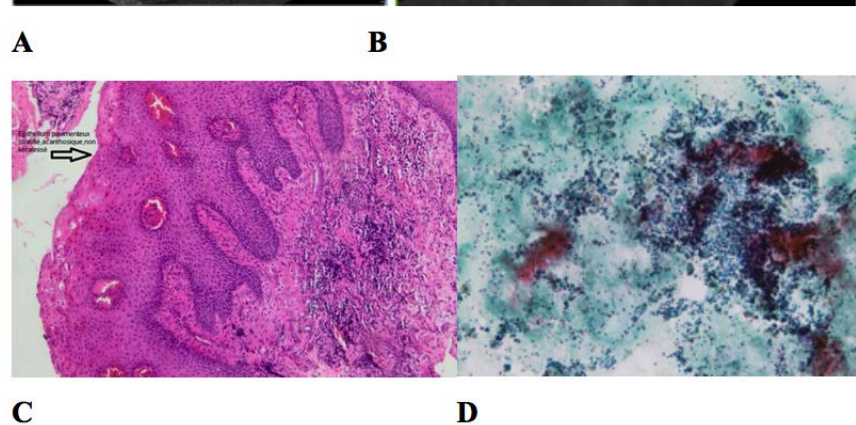
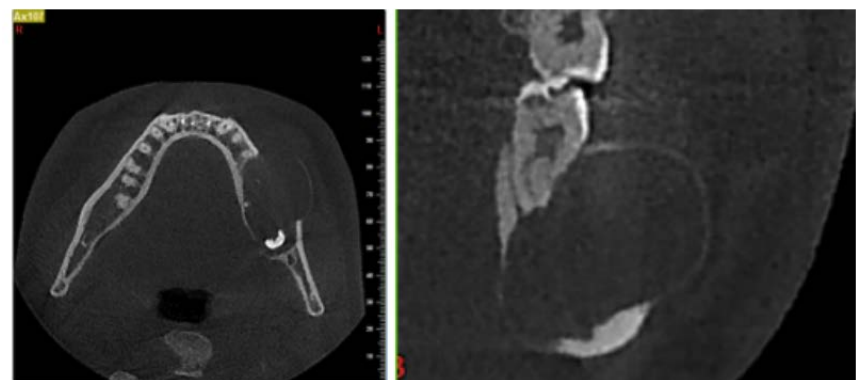


Figure 2. CBCT slices (A) axial (B) coronal to change with a new one with measures. (C, D) Histopathology slides. (C) Cystic membrane: cystic wall composed of fibrous tissue, lined with a non-keratinized stratified squamous epithelium; (D) intra-cystic liquid: a hematologic smear with polymorphous leucocytes as well as foamy or pigmented macrophages.

fen; Abbott Healthcare Products Limited, Vanwall, United Kingdom) was also prescribed, and the patient was advised to rinse his mouth daily with 0.12% chlorhexidine gluconate oral rinse (PerioGard; Colgate-Palmolive, Salford, United Kingdom) during healing. He was instructed to leave the stent in place and visit us twice a week to remove the stent and disinfect it with a 0.12% chlorhexidine solution and thoroughly clean the cavity with saline serum. Through the months, with the bone formation and mesial progression of the third molar the obturator was lifted by the pressure, so every few weeks the obturator part that goes into the cavity was shortened (Figure 3).

After three months, a panoramic radiograph was taken to check the evolution of the lesion. The lesion had retracted but there was not enough bone formation to be able to remove the third molar without damage. Thus, the treatment was resumed for another two months (Figure 4A).

Another panoramic radiograph was taken 5 months post-decompression. It showed mesial displacement of the third molar for about 9 mm, plus a significant bone formation on the basal bone of the jaw which became sufficiently thick to extract the third molar and enucleate the remnants of the cyst, with minimal risk of jaw fracture (Figure 4B).

Enucleation and surgical extraction

The surgical procedure was done under loco-regional analgesia as described for the decompression with the same technique and product. A mucoperiosteal flap was elevated, the third molar was visible. A minimal

bone resection was performed, on the buccal and distal side of the molar with a cylindrical bur. The fragmentation of the tooth was a must, to avoid a lot of force on the lower jaw. First, the crown of the tooth was cut and removed. Second, the roots were separated and extracted one by one with angulated root elevators. After tooth removal,

the enucleation of the remnants of the cyst were slowly dissected and removed. Abundant irrigation was realized to remove all the debris and suturing was performed with a Vicryl® 4/0 (Johnson & Johnson, medical limited, UK). Post-operative medication was the same as for the decompression procedure (Figure 5). Four months

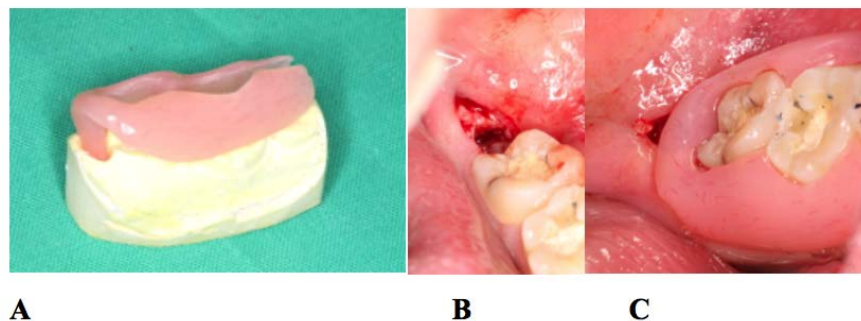


Figure 3. Decompression procedure: (A) acrylic drain, (B) opening of the cyst distally to the second lower left molar, (C) drain stabilized in the mouth without any interference with the occlusion.

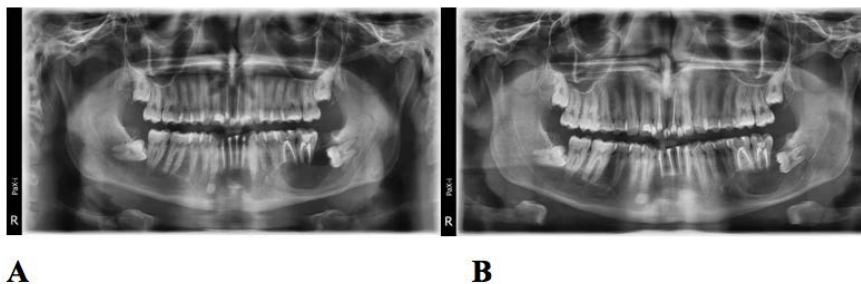

Figure 4. (A) Panoramic radiograph 3 months post-decompression; (B) Panoramic radiograph 5 months post-decompression.

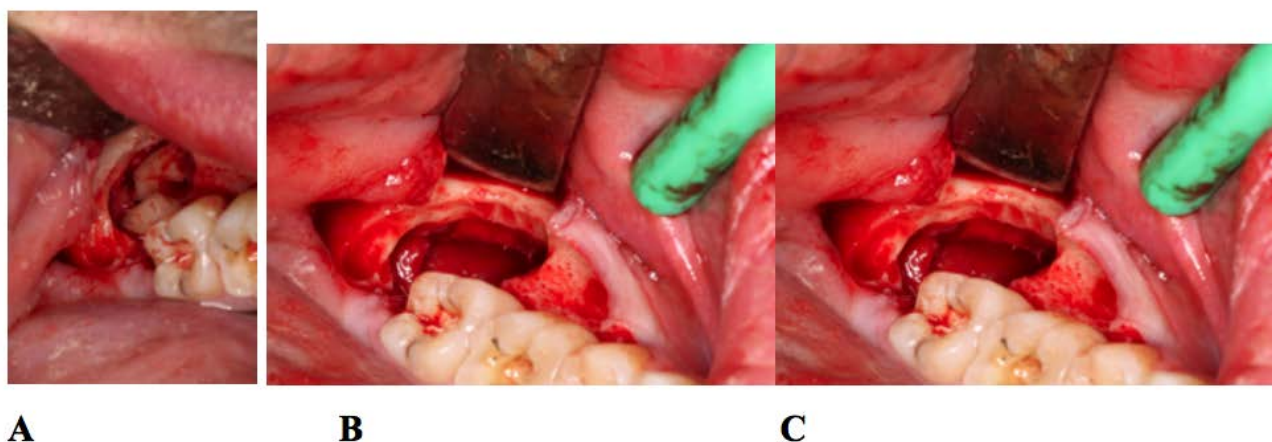


Figure 5. Enucleation surgery: (A) tooth fragmented after osteotomy, (B) cyst enucleation, (C) empty cystic cavity after tooth extraction and enucleation.

post-operatively the panoramic radiograph showed complete bone formation in the cystic cavity (Figure 6).

Volumetric and linear measurements

The patient underwent two CBCT scans (initial and 4 months after the beginning of the treatment) using the Newtom VGI scanner with a 15×15 cm field of view and 0.3mm voxel size. Scan data were saved in DICOM format and imported to the Simplant Pro 15® (Materialize Dental, Leuven, Belgium) software for further analysis. A semi-automatic segmentation technique¹⁶ was used to isolate the affected area from the bone, teeth and soft tissue.

This was done by creating a mask in the Simplant® software. A mask is a selection of voxels within a specified range of gray values. The minimum threshold was set to the lowest (-1024: Empty spaces) while the maximum threshold was adjusted manually in a way that the created mask followed the edge of the surrounding bone structures. The mask was edited in 3D and then manually checked on every single slice using the

multi slice editing tool to remove any selection that did not correspond to the cystic cavity or to select and add a missing part of the lesion. A 3D object was created, and the volume of the cyst was calculated automatically by the software in mm³ in the two datasets.

The measured volumes (Figure 7A, B) were:

- i) 16,775 cc pre-operatively;
- ii) 6,937 cc after 4 months of decompression.

3D models of the cyst were also prepared in the Blue Sky Plan® 4.2.5 (Blue Sky Bio, LLC, Grayslake, IL, USA) software and exported as stereolithography (STL) models. A superimposition of the two datasets was realized in the same software (Figure 7C, D, E). Using the Autodesk® Meshmixer® software, the maximum linear dimensions were measured automatically in the 3 planes in mm for both datasets (Figure 7 F, G):

- i) X: Coronal plane (maximal width/buccal-lingual direction);
- ii) Y: Axial plane (maximal length/antero-posterior direction);
- iii) Z: Sagittal plane (maximal height/coro-

no-apical direction).

The measured linear dimensions (in mm) were:

- i) X: 29.12 Y: 40.58 Z: 33.23 pre-operatively;
- ii) X: 22.12 Y: 31.51 Z: 27.32 after 4 months of decompression.

The percent reduction in maximal linear dimensions were:

- i) X: 24.04% Y: 22.38% Z: 17.79%.

In order to assess the speed of shrinkage and the reduction in volume, four formulas

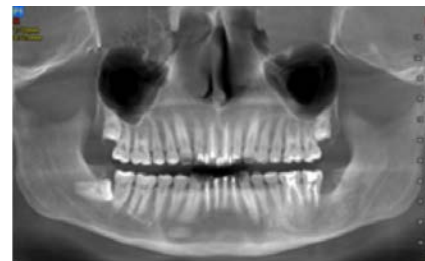

Figure 6. Panoramic radiograph 6 months post-extraction, reconstructed from the CBCT.

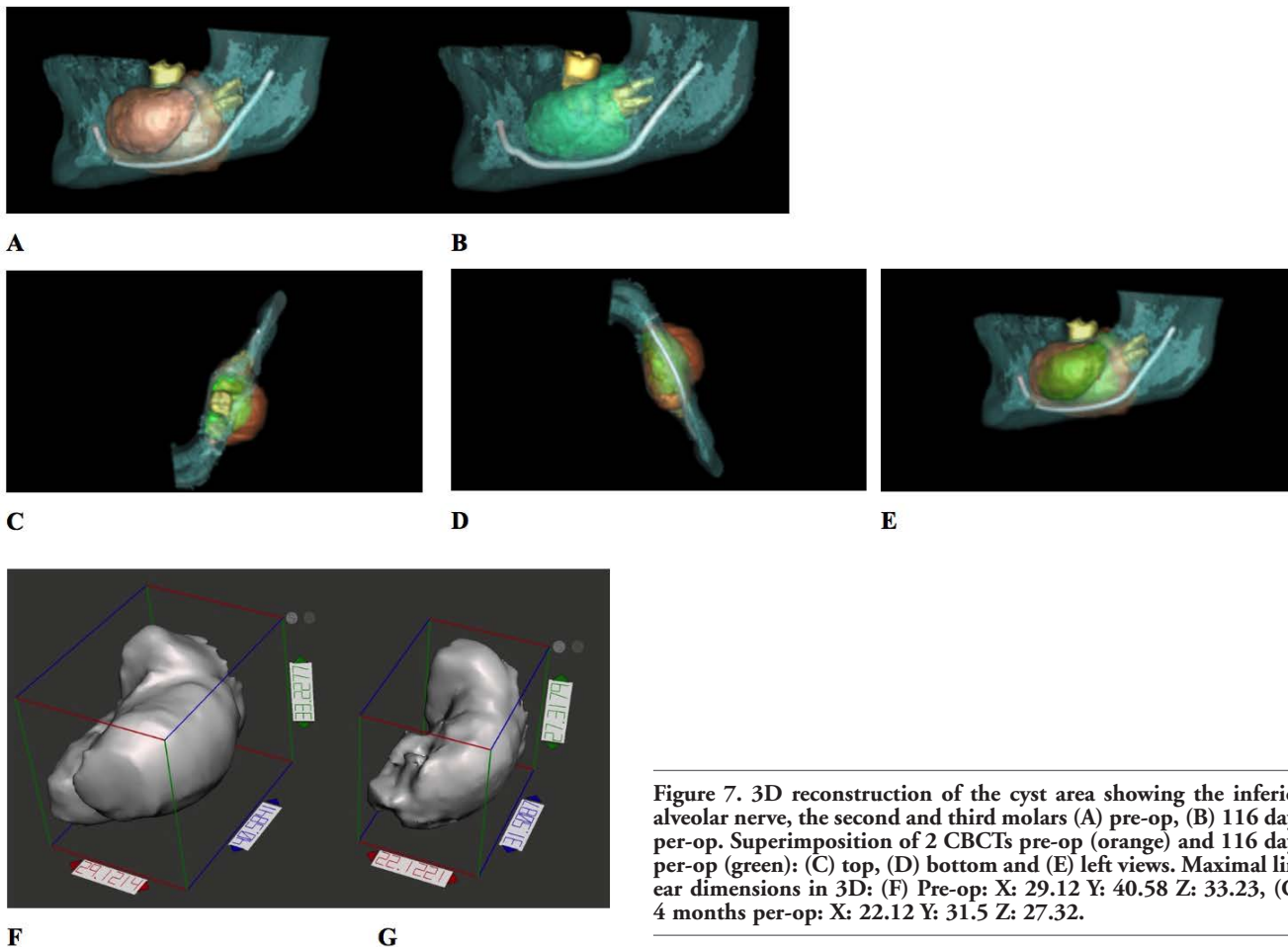


Figure 7. 3D reconstruction of the cyst area showing the inferior alveolar nerve, the second and third molars (A) pre-op, (B) 116 days per-op. Superimposition of 2 CBCTs pre-op (orange) and 116 days per-op (green): (C) top, (D) bottom and (E) left views. Maximal linear dimensions in 3D: (F) Pre-op: X: 29.12 Y: 40.58 Z: 33.23, (G) 4 months per-op: X: 22.12 Y: 31.5 Z: 27.32.

were calculated as:

- i) Absolute speed of shrinkage (ml/day) = $(\text{initial detected volume} - \text{final volume}) / \text{duration of decompression} = 16,775 - 6,937 / 116 = 0.085 \text{ ml/day}$.
- ii) Relative speed of shrinkage (/day) = $(\text{initial detected volume} - \text{final volume}) \times 100 / \text{initial detected volume} \times \text{duration of decompression} = 9.838 \times 100 / 16,775 \times 116 \text{ days} = 0.51/\text{day}$.
- iii) Reduction in volume (ml) = initial detected volume – final volume = 9,838 ml.
- iv) Relative reduction in volume (%) = $\text{reduction in volume} \times 100 / \text{initial detected volume} = 58,64\%$.

Discussion

The most common odontogenic cysts are apical and lateral cysts, followed by dentigerous cysts and odontogenic keratocysts. The relative incidence of dentigerous cysts according to several studies and related to different populations are 22.3% in France by Meningaud *et al.*,¹⁷ 33% in Mexico by Mosqueda *et al.*,¹⁸ and 35.5% by Ledesma-Montes *et al.*,¹⁹ 24% in Canada by Daley *et al.*,²⁰ 27% in Japan by Nakamura *et al.*,²¹ 16.6% in South Africa by Shear *et al.*,²² 19% in Nigeria by Arotiba *et al.*,²³ 21.3% in Germany by Kreidler *et al.*,²⁴ 24.8% in Jordan by Bataineh *et al.*²⁵

Moreover, dentigerous cysts are the most common odontogenic cysts in children and adolescents.²⁶ The relative incidence of dentigerous cysts in pediatric populations is 76.2% in China by Li *et al.*,²⁶ 59.7% in UK by Jones *et al.*,²⁷ 68.2% in Chile by Ochsenius *et al.*,²⁸ 89.7% in Brazil by De Souza *et al.*²⁹ and 66% in Turkey by Tekkesin *et al.*³⁰

Adults have high rates of inflammatory cysts, whereas in children developmental cysts are more common.²⁶ The most frequent unerupted teeth involved with dentigerous cysts are respectively the mandibular third molars, the maxillary permanent canines, the mandibular premolars and the maxillary third molars and the first common symptom is progressive swelling, followed occasionally by pain if infected.³¹

The radiographic feature is an unilocular radiolucent lesion involved with the crown of an impacted tooth. The lesion is well-defined by a radio-opaque margin. These cysts tend to resorb the roots of adjacent teeth due to their dental follicle origin.³¹

Large dentigerous cysts are usually treated by marsupialization or decompression,

which reduce the pressure inside the cystic cavity and permits new bone to reconstruct the bone defect. Adjacent anatomical structures such as a tooth, the sinus, or the inferior alveolar nerve can be protected from damage.³²

The procedure decreased the volume of the cyst before enucleation, and extensive surgery can be avoided, and is considered the best treatment for large dentigerous cyst.^{33,34} The enucleation after marsupialization will be determined by the changes within the cyst cavity. Only when sufficient bone has been created, the enucleation can be safely achieved. However, some studies regarding the assessment of bone apposition after marsupialization have rarely been reported.³⁵

The determination of the proximity of the cyst to vital adjacent anatomic structures is extremely important in enabling the surgeon to decide between marsupialization, decompression and enucleation.³²

Traditionally, 4 to 6 months, after marsupialization or decompression, has been considered as a period in which sufficient bone formation to perform enucleation. However, Bodner *et al.*³⁵ recommended, that cysts should be enucleated at 3 months after marsupialization, based on CT scans with multiplanar reconstruction on 23 patients with marsupialized. The disadvantages of marsupialization are poor oral hygiene in the opening area, healing time prolonged, cystic remnants left behind and patient's cooperation. The cooperation of the patient is required for a long period of time.^{36,37} Pathologic epithelium left in situ may lead to epithelial proliferation and cystic recurrence.³⁷

One other disadvantage regarding the marsupialization in the lower jaw, is the difficulty of cleaning and drainage, whilst in the upper jaw the drainage is gravity dependent.³⁷

In our case, the stent was well fit and stable around the two molars, to avoid food impaction under it. Without being too bulky causing patient's discomfort and without interfering with the occlusion.

Comparing our results to a previous study by Song *et al.*,³⁸ compared reduction in volume in cystic diseases by 3-dimensional CT analysis, the absolute speed of shrinkage was 0,048 ml/day, reduction in volume 0,3ml, relative speed of shrinkage 26,71/day and relative reduction in volume 48,5%. So, we had a relatively faster shrinkage of the dentigerous cyst, even though our patient was 21 years old and this same study concluded that age correlated negatively with the speed of shrinkage in dentigerous cysts and the speed of shrinkage is related to

the initial size of the cystic lesion.³⁸

In this report, the evolution in the bone apposition was assessed through measurement of bone density and the cyst volume after decompression. Significant increases in bone apposition and a remarkable decrease in the cyst cavity were found 3 months after decompression, in agreement with Bodner *et al.*³⁵ However, if the cyst volume is larger than 80 mL and the cortex is very thin or even absent before decompression, secondary enucleation should be delayed for another 2 to 3 months. In our case report, the total healing time was 12 months. The patient was well motivated, compliant and had no complaint about the treatment modality.

Conclusions

The decompression can be a valuable treatment for dentigerous cysts despite the need of a second surgery and the prolonged treatment. From a clinical point of view, the case treated in this paper allows us to confirm that decompression of large cyst is a very important step before enucleation and the use of 3D CBCT reconstruction was very useful for evaluation the decrease of the intra-cyst volume and to observe the bone apposition.

References

1. Browne RM. Investigative pathology of the odontogenic cysts. Boca Raton: CRC Press; 1991.
2. Mehra P. Benign cysts and tumors of the jaw bones. In: Stucker FJ, de Souza C, Kenyon GS, et al., eds. Rhinology and facial plastic surgery. Berlin, Heidelberg: Springer Berlin Heidelberg; 2009, pp 395-429.
3. Manor E, Kachko L, Puterman MB, et al. Cystic lesions of the jaws- a clinicopathological study of 322 cases and review of the literature. *Int J Med Sci* 2012;9:20-6.
4. Koseoglu BG, Atalay B, Erdem MA. Odontogenic cysts: a clinical study of 90 cases. *J Oral Sci* 2004;46:253-7.
5. Gondim JO, Moreira Neto JJS, Nogueira RLM, Giro EMA. Conservative management of a dentigerous cyst secondary to primary tooth trauma. *Dental Traumatol* 2008; 24:676-9.
6. Dinkar AD, Dawasaz AA, Shenoy S. Dentigerous cyst associated with multiple mesiodens: a case report. *J Indian*

- Soc Pedod Prev Dent 2007;128:201-5.
7. Meningaud JP, Oprean N, Pitak-Arnop P, Bertrand J. Odontogenic cysts: a clinical study of 695 cases. *J Oral Sci* 2006;48:59-62.
 8. Ziccardi VB, Eggleston TI, Schneider R. Using fenestration technique to treat a large dentigerous cyst. *JADA* 1997;128:201-5.
 9. Summer M, Bas B, Yildiz L. Inferior alveolar nerve paresthesia caused by dentigerous cyst associated with three teeth. *Med Oral Patol Oral Cir Bucal* 2007;12:E388-90.
 10. Robinson RA. Diagnosing the most common odontogenic cystic and osseous lesions of the jaws for the practicing pathologist. *Mod Pathol* 2017;30:S96-103.
 11. Porgel MA. The keratocystic odontogenic tumor. *Oral Maxillofac Surg Clin North Am* 2013;25:21-30.
 12. Kubota Y, Yamashiro T, Oka S, et al. Relation between size of odontogenic jaw cysts and the pressure of fluid with in. *Br J Oral Maxillofac Surg* 2004;42:391-514.
 13. Ertas U, Yavuz S. Interesting eruption of 4 teeth associated with a large dentigerous cyst in mandible by only marsupialization. *J Oral Maxillofac Surg* 2003; 61:728-30.
 14. Shand JM, Heggie AA. Cysts of the jaws and advances in the diagnosis and management of nevoid basal cell carcinoma syndrome. *Oral Maxillofac Surg Clin N Am* 2005;17:403-14.
 15. Miyawaki S, Hyomoto M, Tsubouchi J, et al. Eruption speed and rate of angulation change of a cyst-associated mandibular second premolar after marsupialization of a dentigerous cyst. *Am J Orthod Dentofac Orthoped* 1999;116:562-78.
 16. Ghosn N, Khoury J, Naaman N. Computer-assisted analysis of bone volume for sinus augmentation procedure. *IAJD* 2016;7:95-108.
 17. Meningaud J-P, Oprean N, Pitak-Arnop P, Bertrand J-C. Odontogenic cysts: a clinical study of 695 cases. *J Oral Sci* 2006;48:59-62.
 18. Mosqueda-Taylor A, Irigoyen-Camacho ME, Diaz-Franco MA, Torres-Tejero MA. Odontogenic cysts. Analysis of 856 cases. *Med Oral Organo Of Soc Espanola Med Oral Acad Iberoam Patol Med Bucal* 2007;7:89-96.
 19. Ledesma-Montes C, Hernández-Guerrero JC, Garcés-Ortiz M. Clinico-pathologic study of odontogenic cysts in a Mexican sample population. *Arch Med Res* 2000;31:373-6.
 20. Daley TD, Wysocki GP, Pringle GA. Relative incidence of odontogenic tumors and oral and jaw cysts in a Canadian population. *Oral Surg Oral Med Oral Pathol* 1994;77:276-80.
 21. Nakamura T, Ishida J, Nakano Y, et al. A study of cysts in the oral region. Cysts of the jaw. *J Nihon Univ Sch Dent* 1995;37:33-40.
 22. Shear M. Cysts of the oral regions. third. Oxford: Wright Butterworth-Heinemann; 1992. pp 75-98.
 23. Arotiba JT, Lawoyin JO, Obiechina AE. Pattern of occurrence of odontogenic cysts in Nigerians. *East Afr Med J* 1998;75:664-6.
 24. Kreidler JF, Raubenheimer EJ, van Heerden WF. A retrospective analysis of 367 cystic lesions of the jaw—the Ulm experience. *J Cranio-Maxillo-fac Surg Off Publ Eur Assoc Cranio-Maxillo-fac Surg* 1993;21:339-41.
 25. Bataineh AB, Rawashdeh MA, Al Qudah MA. The prevalence of inflammatory and developmental odontogenic cysts in a Jordanian population: a clinicopathologic study. *Quintessence Int Berl Ger* 2004;35:815-9.
 26. Li N, Gao X, Xu Z, et al. Prevalence of developmental odontogenic cysts in children and adolescents with emphasis on dentigerous cyst and odontogenic keratocyst (keratocystic odontogenic tumor). *Acta Odontol Scand* 2014; 72:795-800.
 27. Jones AV, Craig GT, Franklin CD. Range and demographics of odontogenic cysts diagnosed in a UK population over a 30-year period. *J Oral Pathol Med* 2006;35:500-7.
 28. Ochsenius G, Escobar E, Godoy L, Peñafiel C. Odontogenic cysts: analysis of 2,944 cases in Chile. *Med Oral Patol Oral Cirugia Bucal* 2007;12:E85-91.
 29. de Souza L-B, Gordón-Núñez M-A, Nonaka C-F-W, et al. Odontogenic cysts: demographic profile in a Brazilian population over a 38-year period. *Med Oral Patol Oral Cirugia Bucal* 2010;15:e583-90.
 30. Tekkesin MS, Olgac V, Aksakalli N, Alatlı C. Odontogenic and nonodontogenic cysts in Istanbul: Analysis of 5088 cases. *Head Neck* 2012;34:852-5.
 31. Mortazavi H, Baharvand M. Jaw lesions associated with impacted tooth: A radiographic diagnostic guide. *Imaging Sci Dent* 2016;46:147-57.
 32. Zhao Y, Liu B, Han QB, et al. Changes in bone density and cyst volume after marsupialization of mandibular odontogenic keratocysts. *J Oral Maxillofac Surg* 2011;69:1361-6.
 33. Nakamura N, Mitsuyasu T, Mitsuyasu Y, et al. Marsupialization for odontogenic keratocysts: Long-term follow-up analysis of the effects and changes in growth characteristics. *Oral Surg Oral Med Oral Pathol Oral Radiol Endod* 2002;94:543.
 34. Tan ZZ, Liu B, Wei JX, et al. Effects of mandibular odontogenic keratocyst surgery and removable partial prostheses on masticatory performance. *J Prosthet Dent* 2007;97:107.
 35. Bodner L, Bar-Ziv J. Characteristics of bone formation following marsupialization of jaw cysts. *Dentomaxillofac Radiol* 1998;27:166.
 36. Enislidis G, Fock N, Sulzbacher I, Ewers R. Conservative treatment of large cystic lesions of the mandible: a prospective study of the effect of decompression. *Br J Oral Maxillofac Surg* 2004;42:546-50.
 37. Soliman MM, Dayem Hassan HA, Elgazaerly H, et al. Marsupialization as a treatment modality of large jaw cysts. *World Appl Sci J* 2013;21:1752-9.
 38. Song IS, Park HS, Seo BM, et al. Effect of decompression on cystic lesions of the mandible: 3-dimensional volumetric analysis. *Br J Oral Maxillofac Surg* 2015;53:841-8.