

Human Tail: A Benign Condition Hidden Out of Social Stigma and Shame in Young Adult – A Case Report and Review

Abstract

A human tail is a rare congenital anomaly which mostly presents immediately after birth or in early childhood. Here, we are presenting a case of 17-year-old male who presented with 18-cm long tail, which was hidden till this age because of social stigma and shame. This is longest human tail reported of our knowledge. This patient presented to us because he started having difficulty, pain while sitting, and discomfort in daily activities because of long tail. We suspect there are far more cases of human tails in developing world which are hidden because of lack of knowledge, illiteracy, social stigma, and shame. This patient had no neurological deficit and had no bowel/bladder involvement. The radiological investigation was suggestive of spina bifida at L₅ and S3–S4 levels (site of attachment of the tail), and tip of the coccyx had bony spur directed posteriorly. Intraoperatively, no connection was found between tail and neural tissue. Human tail is associated with occult spinal lesions in 50% of cases, hence careful neurological and radiological investigations are warranted before surgical exploration.

Keywords: Human tail, spina bifida, spinal dysraphism

Introduction

The occurrence of human tail is a phenomenon of great interest to both lay and medical community. There are only 40 cases of true human tails reported in literature, hence this condition warrants review.^[1] This condition usually presents in newborns, causes anxiety and fear in parents, hence it is brought to medical attention very early. In this case, the patient presented to doctors very late at the age of 17 years when his tail had grown considerably to the size of 18 cm. This patient and his family did not consult doctors because of superstition, illiteracy, social stigma, and shame. The parents were made to believe that this tail is a gift from Hindu monkey god “Hanuman,” and hence named their child after him. There can be other such cases in the parts of rural India which are not brought to medical attention, hence awareness in general public regarding this condition is necessary.

The human tail is usually considered as marker of underlying pathology of occult spinal dysraphism. The reported presentations of spinal dysraphism includes spina bifida occulta, meningocele, and

spinal lipoma or tethered spinal cord.^[2] The etiological basis of human tail is not clear yet. Dao and Netsky *et al.* have classified these lesions as true or pseudotails.^[3] Although this classification is under debate and criticized for insufficient clinical application, it still maintains its place in the center of the reports.

Case Report

A 17-year-old adult male was referred to our hospital with a tail-like appendage in the middle of lumbosacral region that was present since birth. He presented to us with a complaint of difficulty and slight pain while sitting. He also started having discomfort while doing daily activities such as wearing clothes due to this long tail. He was first child of healthy young mother and was born after normal full-term pregnancy with uncomplicated labor and delivery. He was delivered at home and no consultation was made with doctors even after tail-like structure was discovered. There is no family history of such appendages or any other congenital anomaly. The exact length of tail at birth is unknown, but according to mother, it was less than half the size of adult little finger.

This is an open access journal, and articles are distributed under the terms of the Creative Commons Attribution-NonCommercial-ShareAlike 4.0 License, which allows others to remix, tweak, and build upon the work non-commercially, as long as appropriate credit is given and the new creations are licensed under the identical terms.

For reprints contact: reprints@medknow.com

How to cite this article: Giri PJ, Chavan VS. Human tail: A benign condition hidden out of social stigma and shame in young adult – A case report and review. *Asian J Neurosurg* 2019;14:1-4.

**Pramod Janardan
Giri, Vaibhav
Sharadrao Chavan**

*Department of Neurosurgery,
Super Speciality Hospital and
Government Medical College,
Nagpur, Maharashtra, India*

Address for correspondence:
Dr. Vaibhav Sharadrao Chavan,
Department of Neurosurgery,
Super Speciality Hospital and
Government Medical College,
Nagpur - 440 008, Maharashtra,
India.
E-mail: vschavan86@gmail.com

Access this article online

Website: www.asianjns.org

DOI: 10.4103/ajns.AJNS_209_17

Quick Response Code:



Examination

On examination, the patient had no neurological deficit and bowel/bladder involvement. At sacrococcygeal area, exactly in midline, a straight 18-cm long tail was present covered with normal skin. There was no hyperpigmented patches or hypertrichosis along the entire spine. The tail had 2.7 cm × 1.7 cm diameter at the base and tapered toward the tip. It was soft in consistency. No movement of this appendage was observed [Figure 1].

Radiological investigation

Computed tomography [Figure 2] is suggestive of spina bifida at level of L₅ and S₃–S₄. The tail was attached to trunk at S₃–S₄ level. The tip of coccyx was everted and had bony spur which was directed posteriorly toward base of the tail. Magnetic resonance imaging (MRI) scan [Figure 3] is suggestive of midline discontinuity of posterior spinal elements and deep lumbosacral fascia near the attachment of tail. The conus is lying at L₃ spinal level. There is no connection seen between tail and neural element; however, the fibrous band connecting tail to dura is visible.

Operation

The patient was operated under general anesthesia. At operation, an elliptical skin incision was made around base of appendage. The stalk of appendage was identified and followed through a defect in lumbosacral fascia. The tail was connected with small fibrous band to the dura. There was no intradural connection with neural tissue or filum. There was no tethering of the cord; however, the filum terminale was cut as low as possible. The bony spur at the base of tail was nibbled and flattened. Primary layered closure was achieved. There was no postoperative complication.

Discussion

The occurrence of tails in humans continues to be a rare and fascinating phenomenon. There is a wide variation in social status attributed to tailed humans. For most people, having a tail is a reason for fear, shame, and surprise and is considered a curse, while for some people, it is regarded as a symbol of status. In case of the Ranas of Porbunder in India, rulers of Rajput tribes, a tail was considered a

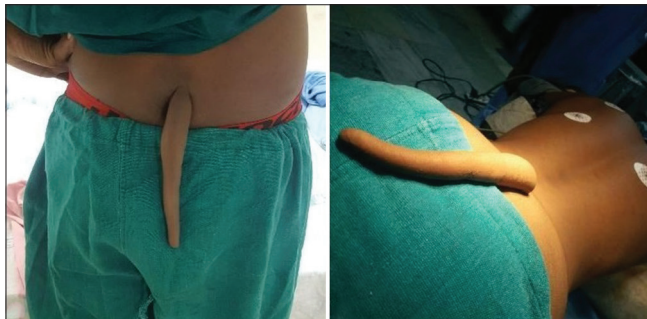

Figure 1: Preoperative images of 18-cm long human tail in the sacral region

mark of divinity, giving evidence of their descent from the monkey god “Hanuman.”^[4,5]

Embryology

The human tail is an example of vestigial organ and is supposed to represent useless remnant of what were once functional and useful organ in our primitive ancestors. During the 4–6th week of embryonic development, the embryo possesses a tail containing 10–12 caudal vertebrae.^[3,6] It has short distal portion which contains mesodermal elements and lacks bone.^[3] The tail has maximum length at the end of 5th week of development when it measures approximately one-sixth the length of the entire embryo.^[1,7] By the 6th week, notochord degenerates and vertebral column becomes the main supporting structure of the axial skeleton.^[8] At 8th week, distal coccygeal segments of the vertebrae are phagocytosed by white blood cells.^[9] The vertebrate portion of tail regresses into soft tissues and the distal nonvertebrate portion continues to protrude longer. This distal portion of tail is also phagocytosed by macrophages migrating back into the trunk.^[10] In general, at the end of 8th week, the tail is fully diminished.^[3] Some people argue that the presence of a tail in a newborn represents reversion to lower species, but it is now widely accepted that a human tail is a result of defect during development that causes a portion of the embryonic tail to persist.^[3,11]

Classification

There is much confusion regarding the definition of human tail and its classification. Harrison^[4] described anything that is appended to sacral or coccygeal region as a tail.

Virchow^[12] in 1880 probably first classified human tail into three categories as follow: (a) Cauda perfecta – tails containing vertebrae, (b) Cauda imperfect – tails without vertebrae, and (c) various protuberances that resembled tail (pseudotails). Virchow’s classification system was never widely adopted.

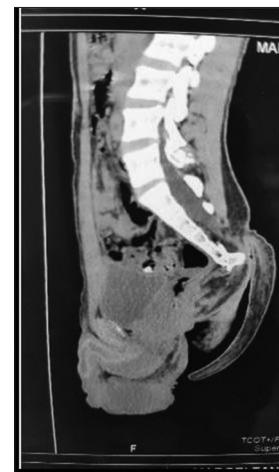


Figure 2: Sagittal image of computed tomography scan showing tip of coccyx everted toward base of tail. This everted bony spur is reason for pain while sitting

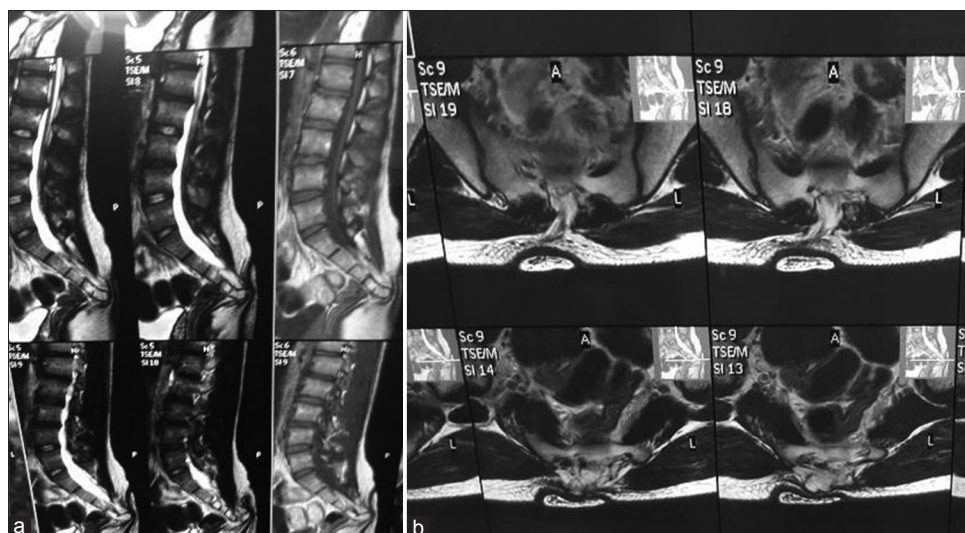


Figure 3: (a) Preoperative sagittal magnetic resonance imaging showing conus lying at L3 and tail arising from sacral region (b) axial magnetic resonance imaging showing spina bifida and fibrous band connecting tail and dura

Bartel^[13] in 1884 classified human tails into 5 categories as follows: (a) Stummelschwänze (Boneless stumpy tails), (b) Schwänze von der Schweineschwanzform (resemble pigtails), (c) Angewachseneschwänze (swollen tails), (d) echte Tierschwänze (true animal tails), and (e) Stummelschwänze mit knöchernen Inhalt (stumpy tails with osseous elements). The Bartels system is now mostly historical endnote.

Dao and Netskys^[3] system of classification has been widely used often dogmatically to classify caudal appendages. Dao and Netsky published “Human tails and pseudotails” in 1984, in an attempt to distinguish true human tails from pseudotails. A true human tail is defined as a boneless, midline protrusion which contains adipose and connective tissue, striated muscle, blood vessels, and nerves covered by normal skin with usual number of hair follicles and sweat glands but no bone, cartilage, notochord, or spinal cord elements. On the other hand, “pseudotail” term includes those lesions protruding and located in the lumbosacral region and demonstrating resemblance to true tails such as coccygeal vertebrae, lipomas, teratomas, chondromegaly, glioma, and parasitic fetus. Recent reports have criticized this classification for being inconclusive and obscure from a clinical perspective and naming almost all cases as pseudotails. It is claimed that this classification is not supported by the embryological findings.^[2]

Lin *et al.*^[14] provided a classification scheme based on anatomic location and the presence of associated lesions (spinal dysraphism, lipoma, and tethered cord); Lin *et al.*'s classification: (a) True tail – (1) Lumbosacral region – not associated with spinal dysraphism and (2) Gluteal/coccygeal region – not associated with other lesions (lipoma, tethered cord, etc.) (b) Pseudotail – (1) Lumbosacral region – associated with spinal dysraphism and (2) Gluteal/coccygeal region – associated with other lesions (lipoma, tethered cord, etc.).

Cai *et al.*^[15] classified human tail as follows: (a) True tails – benign cosmetic lesions not associated with underlying anomaly and (b) Pseudotails – associated with complex underlying abnormalities.

Recently, in 2016, Wilkinson and Boylan^[16] proposed a new caudal appendage classification system: (a) Soft-tissue caudal appendages – primarily composed of soft tissue may have small inclusion of cartilage or bone, (b) Bony caudal appendages – primarily composed of bone, include cases of sacrococcygeal eversion, (c) Bony caudal prominences – surface manifestations of normal but prominent vertebrae, (d) True tails – remnant of embryonic tail contains supernumerary vertebrae, (e) Other caudal appendages – includes surface manifestations of various underlying abnormal structures. The authors claim that this classification based on the clinical and radiological findings is more practical decision making tool.

Our case can be classified as “True tail” according to “Dao and Netskys” system of classification. The distinction between true tail and pseudotail is very much important and cannot be always made clinically. Despite a normal neurological examination, normal X-ray and clinical classification as true tail; surgical exploration may show tethered cord or lipomeningomyelocele. Hence, we feel even after classifying a human tail, there is a need for comprehensive preoperative evaluation in each case to detect associated lesions.

Associated anomalies

The human tail or caudal appendage is usually associated with occult spinal dysraphism. Lu *et al.*^[2] reviewed 59 cases of human tails reported in the literature from 1960 to 1997. The human tails were associated with occult spinal dysraphism and lipoma in 49.2% and 27.1% of cases, respectively. The incidence of tethered spinal cord

is also quite high (20.3%) in same series. The club foot was reported in one patient. In an article on lumbosacral mass lesions, the series included lipomas (67%), teratomas (25%), and meningocele (4%) cases.^[17]

Surgical treatment

The surgical management of the human tail depends on MRI findings showing the presence or absence of associated anomalies rather than a lesion being true tail or pseudotail clinically. A true human tail is accepted as a failure of regression in fetal life and should be treated as a benign lesion and treatment is simple excision. On the other hand, pseudotail is associated with other anomaly, hence surgical treatment includes more extensive surgery for both removal of lesion and correction of underlying anomaly like tethered cord.^[14] The timing of surgery is related to the presence of tethered cord. If neurological findings allow, delaying the surgery for 3 months or until the patient weight reaches 5 kg has been recommended.^[18] Lu *et al.* suggest early surgery for untethering before 2 years of age to keep the patients free of symptoms.^[2]

Social aspect of human tail

In some parts of the world, human tail is considered to be a curse and hence social stigma, fear, and shame associated with this condition along with lack of knowledge and illiteracy may be causing underreporting or late reporting of this condition. In rural parts of India, child born with tail is sometimes considered as auspicious gift from monkey god “Hanuman,” and the parents may be hesitant to report this condition due to superstition and fear of rejection. Hence, it is very much important to make general public aware about this condition and successful treatment available for the same.

Consent

The patient has given consent to be enrolled and have their data published.

Financial support and sponsorship

Nil.

Conflicts of interest

There are no conflicts of interest.

References

1. Kansal R, Agrawal N, Khare S, Khare A, Jain S, Singhal BM. Newborn with a tail – A genetic throwback. *Peoples J Sci Res* 2010;3:15-7.
2. Lu FL, Wang PJ, Teng RJ, Yau KI. The human tail. *Pediatr Neurol* 1998;19:230-3.
3. Dao AH, Netsky MG. Human tails and pseudotails. *Hum Pathol* 1984;15:449-53.
4. Harrison RG. On the occurrence of tails in man, with a description of the case reported by Dr. Watson. *Johns Hopkins Hosp Bull* 1901;12:96-101.
5. Parsons RW. Human tails. *Plast Reconstr Surg Transplant Bull* 1960;25:618-21.
6. Ledley FD. Evolution and the human tail: A case report. *N Engl J Med* 1982;306:1212-5.
7. Arey LB. *Developmental Anatomy*. Revised 7th ed. Philadelphia: W.B. Saunders Company; 1974.
8. Williams PL, Wendell-Smith CP, Treadgold S. *Basic Human Embryology*. London: Pitman Medical Publishing Company; 1966.
9. Bar-Maor JA, Kesner KM, Kaftori JK. Human tails. *J Bone Joint Surg Br* 1980;62-B:508-10.
10. Fallon JF, Simandl BK. Evidence of a role for cell death in the disappearance of the embryonic human tail. *Am J Anat* 1978;152:111-29.
11. Belzberg AJ, Myles ST, Trevenen CL. The human tail and spinal dysraphism. *J Pediatr Surg* 1991;26:1243-5.
12. Virchow R. Über schwanzbildung beim menschen. *Virchows Arch Pathol Anat Physiol* 1880;79:176-82.
13. Bartels M. Die geschwanzten menschen. *Arch Anthropol* 1884;15:45-132.
14. Lin PJ, Chang YT, Tseng HI, Lin JY, Huang YS. Human tail and myelomeningocele. *Pediatr Neurosurg* 2007;43:334-7.
15. Cai C, Shi O, Shen C. Surgical treatment of a patient with human tail and multiple abnormalities of the spinal cord and column. *Adv Orthop* 2011;2011:153797.
16. Wilkinson CC, Boylan AJ. Proposed caudal appendage classification system; spinal cord tethering associated with sacrococcygeal eversion. *Childs Nerv Syst* 2017;33:69-89.
17. McLone DG, Naidich TP. Terminal myelocystocele. *Neurosurgery* 1985;16:36-43.
18. Samura K, Morioka T, Hashiguchi K, Yoshida F, Miyagi Y, Yoshiura T, *et al.* Coexistence of a human tail and congenital dermal sinus associated with lumbosacral lipoma. *Childs Nerv Syst* 2009;25:137-41.