



Toxoplasma gondii in four captive kangaroos (*Macropus* spp.) in China: Isolation of a strain of a new genotype from an eastern grey kangaroo (*Macropus giganteus*)

Ruijing Su^{a,1}, Hui Dong^{a,1}, Tongyi Li^b, Yibao Jiang^a, Ziguoyuan^c, Chunlei Su^d, Longxian Zhang^a, Yurong Yang^{a,*}

^a College of Animal Science and Veterinary Medicine, Henan Agricultural University, Zhengzhou, PR China

^b Zhengzhou Zoo, Zhengzhou, PR China

^c Key Laboratory of Zoonosis of Ministry of Agriculture and Rural Affairs, South China Agricultural University, Guangzhou, PR China

^d Department of Microbiology, University of Tennessee, Knoxville, USA

ARTICLE INFO

Keywords:

Toxoplasmosis
Kangaroo
Isolation
Genotype
Virulence
China

ABSTRACT

Marsupials are highly susceptible to *Toxoplasma gondii* infection. Here, we report *T. gondii* infection in four kangaroos from a zoo in China. Kangaroos were imported into China in 2000 and were since bred in zoo. In 2017–2018, four kangaroos died due to respiratory system disease or injury. The bodies were submitted to the laboratory to test for *T. gondii* infection. Antibodies to *T. gondii* were found in 75% (3/4) of the kangaroos via the modified agglutination test with the cut-off 1:25. Cysts were observed in the histopathological sections of tongue and diaphragm or squashes of fresh myocardium in two kangaroos. These cysts were confirmed as *T. gondii* by immunohistochemical staining and molecular biological analysis. One viable *T. gondii* strain was isolated from one kangaroo and designated as TgRooCHn1. DNA from *T. gondii* tachyzoites obtained from cell culture was characterized by 10 PCR-RFLP markers and the virulence genes ROP5 and ROP18. The genotype of this isolate did not match with any known genotypes; it was designated as ToxoDB#292. The virulence of TgRooCHn1 (10⁴ tachyzoites) was non-lethal to mice, and it formed tissue cysts. To our knowledge, the present study is the first isolation of ToxoDB#292 strain from kangaroo. Improvemets for captive settings were initiated, including greater attention being paid to birds and stray cats, fed frozen meat for carnivores.

1. Introduction

Toxoplasma gondii infects virtually all warm-blooded animals, including birds, humans, livestock, and wild animals (Dubey, 2010). Felids are the definitive hosts, and other warm-blooded animals can be intermediate hosts. Most animals are resistant to *T. gondii* infection, and most infections are subclinical; however, some species such as new world primates, squirrel monkeys, lemurs, marmosets, meerkats and kangaroos are very susceptible to the infection (Dubey et al., 1988; Epiphanio et al., 2003; Cenci-Goga et al., 2011; Nishimura et al., 2019). Horizontal transmission by *T. gondii* cysts or oocysts is likely the most important mode of transmission of *T. gondii* for these animals.

Initially, kangaroos (*Macropus* spp.) in zoos around the world were imported from Australia and New Zealand; some zoos then started to

breed these animals locally. Mortality of captive marsupials infected with *T. gondii* has been reported, and some animals have also been reported to develop chronic infection (More et al., 2010; Guthrie et al., 2017; Dubey, 2010; Diaz-Ayala et al., 2016). There are few reports concerning genotyping of *T. gondii* from kangaroos and wallabies. Two *T. gondii* strains with ToxoDB #1 and #2 were isolated from kangaroos from zoos in Argentina (More et al., 2010). Three *T. gondii* strains isolated from wallabies were ToxoDB #2 (Dubey and Crutchley, 2008). Non-archetypal type II-like strains of *T. gondii* were found in marsupials from Australia (Parameswaran et al., 2010). ToxoDB#263 and ToxoDB#4 *T. gondii* strains were identified in wallaby tissues from the Virginia Zoo (Guthrie et al., 2017).

Kangaroos usually eat grass and grassroots, and infection of *T. gondii* is a useful indicator of soil and environmental contamination by

* Corresponding author.

E-mail addresses: suruijingcomeon@126.com (R. Su), hui150614@126.com (H. Dong), zoolty@126.com (T. Li), yibaojiang@sina.com (Y. Jiang), ziguooyuan@scau.edu.cn (Z. Yuan), csu1@utk.edu (C. Su), zhanglx8999@henau.edu.cn (L. Zhang), yangyu7712@sina.com (Y. Yang).

¹ Ruijing Su and Hui Dong contributed equally.

<https://doi.org/10.1016/j.ijppaw.2019.03.003>

Received 27 January 2019; Received in revised form 7 March 2019; Accepted 9 March 2019

2213-2244/ © 2019 The Authors. Published by Elsevier Ltd on behalf of Australian Society for Parasitology. This is an open access article under the CC BY-NC-ND license (<http://creativecommons.org/licenses/by-nc-nd/4.0/>).

Table 1
Background and isolation of *Toxoplasma gondii* from kangaroos in China.

Samples (<i>T. gondii</i> ID)	Sample received	Species	Sex, age in year	Clinical signs	Pathological findings	MAT	<i>T. gondii</i> cysts	IHC	PCR ^b	Mice bioassay ^c		
										Date assayed	BALB/C	γ-IFN ^{-/-}
Case 1	5/30/2017	<i>Macropus giganteus</i>	Female, 5	Nasal discharge, depressed, anorexia.	Interstitial pneumonia, necrotic splenitis, necrotic hepatitis	+	Not found	nd	-	6/1/2017	0/5	nd
Case 2 (TgRooChn1)	7/23/2017	<i>M. giganteus</i>	Female, 6	Without obvious clinical signs.	Bacteria, liver fatty degeneration, necrotic splenitis, <i>T. gondii</i> cysts. Neuronal necrosis.	+	+	+	+	7/24/2017	5/5	nd
Case 3	7/26/2017	<i>M. giganteus</i>	Male, 5	Nasal injury, intermittent muscle spasms, dyspnea.		+	Not found	nd	-	7/31/2017	0/3	nd
Case 4	9/11/2018	<i>Macropus rufus</i>	Male, 4	Depression, hematuria, salivation, skin injury, anorexia.	Acute splenitis, interstitial pneumonia, glomerulonephritis.	^a	+	nd	+	9/12/2018	0/5	0/2

nd: experiment not done.

^a Titration: 1:25–1:12800.

^b Primer was TOX5/TOX8.

^c Number of positive mice/number of inoculated mice.

oocysts. Here, we present a study on the diagnosis, molecular characterization, and isolation of *T. gondii* from captive kangaroos from a zoo in China. This is the first report of *T. gondii* isolated from kangaroo in this region.

2. Materials and methods

2.1. History of the kangaroos

Kangaroos were first imported to zoo (Henan Province, China) from Australia in 2000, and the animals were bred in the zoo to establish a colony. The colony now has 42 kangaroos. In 2017–2018, the carcasses of four kangaroos that were born in captivity were submitted to the Veterinary Pathology Laboratory, Henan Agriculture University for pathological diagnosis, and this provided the opportunity to survey for *T. gondii* infection. Table 1 summarizes the background information for the animals. After necropsy, tissues samples (myocardium, liver, spleen, lung, kidney, leg muscle, tongue, and diaphragm) were collected and fixed in 10% (v/v) neutral buffered formalin. Meat juice samples were collected from hearts. The heart, tongue, diaphragm, and leg muscle were digested and bioassayed using mice following previously published methods (Dubey, 2010).

2.2. Detection of antibodies against *T. gondii* and *T. gondii* DNA in the serum and tissue digests of kangaroos

Kangaroo meat juice was serially diluted from 1:25 to 1:200 (case 1–3) and 1:25 to 1:12,800 (case 4) and tested for antibodies to *T. gondii* using the modified agglutination test (MAT) as described by Dubey and Desmonts (1987). Whole formalin fixed *T. gondii* antigens were obtained from the University of Tennessee Research Foundation (Knoxville, TN, USA; <https://utrf.tennessee.edu/>). A titer of 1:25 was considered indicative of exposure to *T. gondii*. The sera of positive controls from mice inoculated with *T. gondii* Me 49 strain and negative controls from mice were included in the same 96-well plate. Digested tissues (myocardium, leg muscle, tongue, and diaphragm) from kangaroos were used to detect *T. gondii* DNA. The DNA from the digested samples was extracted using a commercial DNA extraction kit (Tiangen Biotec Company, China, DP 304) and eluted in 50 μl deionized water. PCR assays were done to detect *T. gondii* using the specific primer pairs TOX5/TOX8 (5'-CGCTGCAGACACAGTGCATCTGGATT-3' and 5'-CCCA GTCGCTGTGTCGGGAT-3') (Schares et al., 2008). Quality control of PCR analyses including eliminating nucleic acid contaminating and running negative and positive controls was conducted (Burkhardt, 2000). Negative PCR controls (not including template DNA) and the positive control DNA from *T. gondii* Me 49 were included in all batches. The PCR products from *T. gondii* were expected to be 450 bp in length.

2.3. Histopathological analysis

The tissues were processed using routine histological techniques and then embedded in paraffin. Paraffin sections (5 μm in thickness) of the samples were prepared and stained with hematoxylin and eosin (H&E). Immunohistochemistry (IHC) was conducted using rabbit anti-*T. gondii* serum as the primary antibody and mouse anti-rabbit IgG conjugated with HRP/DAB as the second antibody (IHC detection kit, Abcam, ab64264). Brain tissue sections of a VEG *T. gondii*-infected mouse were used as a positive control for IHC (kindly provided by Dr. Dubey, ARS, USDA).

2.4. Isolation of viable *T. gondii* from kangaroo tissues by bioassay in mice

Tissue samples (hearts, tongues, diaphragm, and leg muscle) of four kangaroos were bioassayed in mice following published methods (Dubey, 2010). Briefly, striated muscle (50 g) was homogenized, digested in pepsin (5.2 g pepsin, 10.0 g NaCl, and 14 mL HCl diluted to 1 L

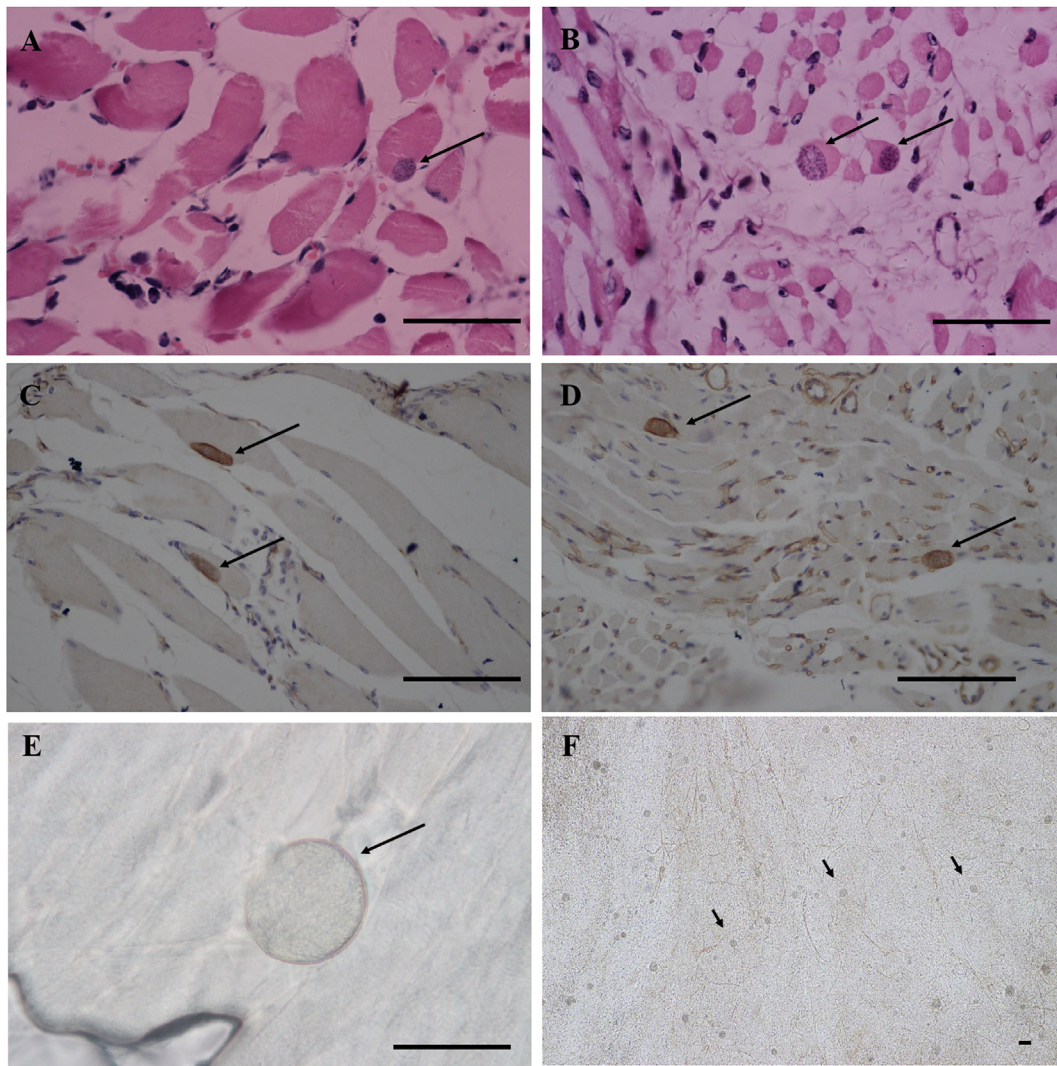


Fig. 1. *Toxoplasma gondii* cysts in kangaroos or mice. A. *Toxoplasma gondii* cysts in the diaphragm of case 2 kangaroo, H&E. B. *Toxoplasma gondii* cysts in the tongue of case 2 kangaroo, H&E. C. *Toxoplasma gondii* cysts in the diaphragm of case 2 kangaroo, IHC. D. *Toxoplasma gondii* cysts in the tongue of case 2 kangaroo, IHC. E. *Toxoplasma gondii*-like cysts in the myocardium of case 4 kangaroo, squashed section, unstained. F. Many TgRooCHn1 *Toxoplasma gondii* cysts were observed in the mouse brain, 27 DPI, squashed section, unstained. Bar = 50 μ m.

with deionized water, pH 1.1–1.2). The striated muscle homogenate was subsequently incubated at 37 °C in a shaking water bath for 60 min. After this, the sample was filtered through double gauze and centrifuged at 1200 \times g for 10 min. The supernatant was then removed, and the pellet was suspended in 0.01 M PBS (pH 7.2) and neutralized by mixing with 1.2% sodium bicarbonate. Following mixing, the sample was centrifuged at 1200 \times g for 10 min, after which the supernatant was removed and 5 mL of saline containing 1000 units penicillin and 100 μ g of streptomycin per mL was added. Striated muscle digested liquid was then inoculated subcutaneously into mice (1 mL per mouse). The homogenates were inoculated subcutaneously into 2–5 BALB/C mice or/and gamma interferon (γ -IFN) knockout mice. Survivors were bled on day 60 post-inoculation (DPI), and 1:25 and 1:200 dilutions of mouse serum were tested for *T. gondii* antibodies using MAT. Mice were euthanized at 61 DPI, and brain cysts were examined and counted as described by Dubey et al. (2012). Smears of tissues of dead or euthanized mice were examined for *T. gondii* tachyzoites or cysts. If cysts or tachyzoites were not found in the mouse tissue, homogenized lung, brain, heart, and tongue were used for subpassage into new groups of mice.

2.5. In vitro cultivation and genotyping

Brain homogenates of *T. gondii*-positive mice were seeded into CV-1 cell culture flasks as described previously by Dubey (2010). DNA was extracted from cell culture-derived tachyzoites. Multiplex PCR of the *T. gondii* strain was performed using 10 PCR-RFLP genetic markers (SAG1, SAG2 (5'-3' SAG2, alt.SAG2), SAG3, BTUB, GRA6, c22-8, c29-2, L358, PK1, and Apico) as previously described by Su et al. (2010). Genotyping of virulence genes ROP5 and ROP18 was also performed as previously reported (Rego et al., 2017; Cheng et al., 2017). Reference *T. gondii* DNA was included in all batches.

2.6. Evaluation of the pathogenicity of *T. gondii* tachyzoites isolated from kangaroo

Virulence of the *T. gondii* isolated from the kangaroo was evaluated in BALB/C mice. *T. gondii* tachyzoites collected from cell cultures were counted in a disposable hemocytometer and diluted in 10-fold steps from 10^{-1} to 10^{-6} to reach an end-point of < 1 tachyzoite. Then, < 1 , 10^0 , 10^1 , 10^2 , 10^3 , and 10^4 tachyzoites were intraperitoneally inoculated into five BALB/C mice for each dilution. The clinical symptoms were recorded, and mice were monitored daily. The smears of

Table 2Genotypes of *T. gondii* isolates from kangaroos in China according to PCR-RFLP of 10 markers and virulence proteins.

Isolated ID	SAG1	(3'+5') SAG2	Alt SAG2	SAG3	BTUB	GRA6	C22-8	C29-2	L358	PK1	Apico	ROP5	ROP18	Genotype ToxoDB
GT1, reference	I	I	I	I	I	I	I	I	I	I	I	1	1	#10
PTG, reference	II	II	II	II	II	II	II	II	II	II	II	2	2	#1
CTG, reference	II/III	III	III	III	III	III	III	III	III	III	III	3	3	#2
TgCgCa1, reference	I	II	II	III	II	II	II	u-1	I	u-2	I	5	2	#66
MAS, reference	u-1	I	II	III	III	III	u-1	I	I	III	I	4	4	#17
TgCatBr5, reference	I	III	III	III	III	III	I	I	I	u-1	I	4	4	#19
TgCatBr64, reference	I	I	u-1	III	III	III	u-1	I	III	III	I	3	3	#111
TgRsCr1, reference	u-1	I	II	III	I	III	u-2	I	I	III	I	3	3	#52
TgRooCHn1	u-1	II	II	III	III	III	III	III	III	III	III	3	3	#292, new, this study

lung or mesenteric lymph nodes of sacrificed mice were examined for *T. gondii* tachyzoites. After 60 days, all surviving mice were bled and tested for IgG antibodies to *T. gondii* using the MAT assay with titers between 1:25 and 1:200. The mice were euthanized at 61 DPI, and cysts of *T. gondii* were counted in the brains of all mice using a squash preparation (Dubey et al., 2012). Mice were considered infected when either antibodies to *T. gondii* or parasites were detected in their sera or tissues.

2.7. Ethics

This study was approved by the Institutional Animal Use Protocol Committee of the Henan Agricultural University, China. The Beijing Association for Science and Technology (Approval SYXK [Beijing] 2007–0023) approved the protocol used in this study. We handled all mice in strict accordance with the good animal practices of the Animal Ethics Procedures, Recycle-Reduce-Reuse principle, and Guidelines of the People's Republic of China.

2.8. Statistical analysis

Statistical analysis was performed using Graph Pad Prism 4.0 software (Graph Pad Software Inc., San Diego, CA, USA). Data were analyzed with the chi-squared test or Fisher's exact test. A value of $p < 0.05$ was considered statistically significant.

3. Results

3.1. Necropsy and pathologic findings

Four dead kangaroos were collected from the zoo during 2017–2018 (Table 1). Case 1 kangaroo presented signs of yellow nasal discharge, depression and anorexia. Postmortem findings were pulmonary congestion, spleen atrophy, and enlarged liver. Microscopic analysis showed interstitial pneumonia, necrotic splenitis and hepatitis. Case 2 kangaroo died suddenly without obvious clinical signs. The gross findings were pulmonary and liver congestion, pleural effusion, and spleen atrophy. Many rod-shaped bacteria were present in the alveolar edema fluid and blood in the lung. Liver fatty degeneration, necrotic splenitis, and *T. gondii* cysts were observed in the tongue and diaphragm (Fig. 1). Case 3 kangaroo displayed a history of nasal injury from fighting with other kangaroos. Intermittent muscle spasms and dyspnea were observed. Multifocal glial nodules with neuronal necrosis were present in the brain, along with alveolar expansion and rupture. Case 4 kangaroo showed signs of depression, salivation, skin injury, and anorexia. This kangaroo developed hematuria and failed to respond to penicillin, streptomycin or supportive therapy. Gross examination showed pulmonary and kidney congestion, as well as splenomegaly. The histopathological findings were acute splenitis, interstitial pneumonia, and glomerulonephritis.

3.2. Immunohistochemical staining and PCR

Under light microscopy, many oval-shaped cysts were observed in the skeletal muscle cells of the tongue and diaphragm of case 2 (Fig. 1 A and B), *T. gondii* cysts were confirmed with IHC-staining (Fig. 1 C and D). The average cyst load was 17.1 ± 10.8 per square centimeter, and the sizes of the cysts were within the range of $5.2 \mu\text{m}–8.0 \mu\text{m} \times 2.4 \mu\text{m}–6.1 \mu\text{m}$ by H&E sections. No inflammation was found around the cysts. Round cysts were found in squashes of fresh myocardium from case 4 kangaroo (Fig. 1E). The average cyst load was 4.2 ± 2.6 per square centimeter, and the sizes of the cysts were $42.5 \mu\text{m}–68.0 \mu\text{m} \times 47.6 \mu\text{m}–70.2 \mu\text{m}$ by squash sections. *T. gondii* DNA in the tissue digests from all kangaroo cases was checked. However, *T. gondii* DNA using the primers TOX5/TOX8 was detected only in case 2 and 4 (Table 1).

3.3. Serological examination and isolation of *T. gondii* in mice and cell cultures

Antibodies to *T. gondii* were found in three of the four kangaroos (75%), with titers 1:200 (Table 1). The striated muscle homogenates from all kangaroos were individually tested via bioassay in mice. One group of mice (5/5) was inoculated with tissue samples from case 2 kangaroo, and the mice were sacrificed after showing signs of toxoplasmosis 22–27 DPI. Tachyzoites were found in the lungs, and many small cysts (diameter around $5 \mu\text{m}–50 \mu\text{m}$) were found in the brains of the mice (Fig. 1 F). This isolate was successfully propagated in cell culture after seeding cell 14 days from *T. gondii* positive mouse tissues, and the strain was designated as TgRooCHn1. Genetic typing using 10 genetic markers revealed that this isolate did not match with any known genotypes. This isolate was designated as a new ToxoDB number #292, atypical type III. In addition, the isolate showed ROP5 allele 3 and ROP18 allele 3 (Table 2).

3.4. Virulence evaluation of TgRooCHn1

After inoculating BALB/C mice with different dosages of TgRooCHn1 tachyzoites, all the mice survived and showed no clinical signs. No mice died before termination at 60 days (Table 3). Tachyzoite

Table 3Virulence of *T. gondii* strain TgRooCHn1 in BALB/C mice.

No. of tachyzoites	No. of mice infected/No. of mice inoculated (%)	Brain cysts by day 61 DPI
10^4	5/5(100%)	386.0 ± 97.0^b
10^3	5/5(100%)	502.5 ± 147.4^b
10^2	5/5(100%)	224.4 ± 47.5^a
10^1	3/5(60%)	Not found
1	2/5(40%)	Not found
< 1	0/5(0%)	Not found
Blank control	0	Not found

^{a,b} Different letters indicate significant differences ($p < 0.05$).

numbers above 10^2 induced *T. gondii* infection in all of the mice. *T. gondii* cysts were detected in the brains of mice when euthanized at 61 DPI. The number of brain cysts in the group of mice inoculated with 10^2 tachyzoites had 224.4 ± 47.5 cysts. The numbers were significantly increased in groups inoculated with 10^3 tachyzoites (502.5 ± 147.4) or 10^4 tachyzoites (386.0 ± 97.0) ($P < 0.05$). No obvious pathological lesions were observed in mice infected with the TgRooCHn1 strain at 61 DPI.

4. Discussion

In this study, *T. gondii* infection was identified in four kangaroos from a zoo in China. Three out of the four kangaroos were positive for *T. gondii* IgG. Meat juice from one kangaroo's (case 4) heart was seronegative for *T. gondii* IgG (titer from 1:25 to 1:12,800); however, *T. gondii* DNA and *T. gondii*-like cysts were found in this animal. It may be because due to acute infection, and anti-*T. gondii* IgG antibody was not produced yet. Unfortunately, isolation *T. gondii* was unsuccessful from case 1, case 3 and case 4 kangaroos.

T. gondii cysts in the tongue and diaphragm of case 2 kangaroo were observed, and this was further confirmed by specific *T. gondii* PCR from digested tissues, by cysts reactive to *T. gondii* antibody by IHC in histopathological sections (Fig. 1 C and D), and bioassays in mice. Histopathological evidence of *T. gondii* in tissues has been found in the skeletal muscle, adrenal gland, brain, heart, liver, stomach, intestine, and mesenteric lymph node of marsupials (Dubey et al., 1988; Fernandez-Aguilar et al., 2013; Basso et al., 2007; Bermudez et al., 2009; More et al., 2010; Diaz-Ayala et al., 2016). A large number of *T. gondii* cysts were detected in the skeletal muscles of case 2 kangaroo and the brains of inoculated mice. This is in agreement with the findings of More et al. (2010). Furthermore, *T. gondii*-specific DNA was detected in the brain or tongue of all seropositive kangaroos, indicating a high level of infection by *T. gondii* in this species (Parameswaran et al., 2009; Guthrie et al., 2017). The infection level of *T. gondii* cysts may also be related to the genotype or strain of *T. gondii*, the infective dose, the host species, and the immunity of hosts. The heavy load of *T. gondii* cysts in kangaroo tissues may be an indicator of the susceptibility of this species. As kangaroo meat is available for human consumption, meat contaminated with *T. gondii* can be a risk factor for transmission of the parasite to humans.

T. gondii was successfully isolated from kangaroo by bioassay in mice. Genotyping revealed that TgRooCHn1 is a new type and designated as ToxoDB #292. Experimental infection in mice showed that TgRooCHn1 is avirulent and can readily establish chronic infection and form tissue cysts in mice. In this study, the ROP18/ROP5 genotype combination suggests this strain TgRooCHn1 is non-lethal to mice (Shwab et al., 2016), which matched with the mouse virulence test in this study. To date, only a few *T. gondii* genotypes have been identified in animals and humans in China. These genotypes include ToxoDB #1 (type II), #3 (type II variant), #4, #9, #10 (type I), #204, and #225, and the ToxoDB #9 is the dominant type in China (Dong et al., 2018). There was no *T. gondii* inspection when the kangaroos were imported from Australia to China. 45 distinct *T. gondii* genotypes were detected directly from tissues of 16 macropods (Shuting et al., 2012). However, few isolates of *T. gondii* from Oceania have been genetically characterized using multilocus PCR-RFLP genotyping. ToxoDB#3 and ToxoDB#1 are the predominant genotypes in animals from Oceania, with ToxoDB#10 also being detected (Brennan et al., 2016; Schwab et al., 2014). However, because these kangaroos were born in captivity, they may have ingested *T. gondii* oocysts shed by stray cats or captive felids in the zoo. The ToxoDB#292 genotype may have already been circulating in local source, as genetic diversity may exist in China. It is important to investigate *T. gondii* infection in more animals, especially cats and small mammals. It is not clear that the mortality of the kangaroos in this study was solely due to *T. gondii* infection or whether the infection was mixed with other pathogens. Improvements for the

captive setting were implemented after this study; more attention was paid to birds and stray cats, and the frozen meat fed to carnivores.

Declarations

Abbreviations

MAT: modified agglutination test; H&E: hematoxylin and eosin staining; IHC: immunohistochemistry.

Consent for publication

All authors consent for publication of this report.

Availability of data and material

The data, materials, and protocols associated with this report may be shared by the readers without undue qualifications.

Competing interests

The authors declare no competing interests. None of the authors of this report have financial or personal relationships with other people or organizations that could inappropriately influence its content.

Funding

The China Postdoctoral Science Foundation (Grant No. 2016M600577) and Henan Natural Science Foundation of China (Grant No. 162300410138) supported this study.

Authors' contributions

RJS performed laboratory tests and IHC analysis. HD performed laboratory tests and PCR-RFLP analysis. NJ participated in laboratory testing. TYL and YBJ collected the samples. LXZ and ZGY helped in the writing of the manuscript. CLS helped in analyze genotypes and writing this manuscript. YRY designed the study protocol, analyzed the results and wrote the manuscript. All authors have read and approved the final version of the manuscript.

Conflicts of interest

None.

Acknowledgements

We thank Jitender Prakash Dubey (US Department of Agriculture, Beltsville, MD, USA) for critical reading the manuscript. We thank Yaoyao Lu and Mengyao Wang (Henan Agricultural University, Zhengzhou, China) for collecting samples.

Appendix A. Supplementary data

Supplementary data to this article can be found online at <https://doi.org/10.1016/j.ijppaw.2019.03.003>.

References

- Basso, W., Venturini, M.C., More, G., Quiroga, A., Bacigalupe, D., Unzaga, J.M., Larsen, A., Laplace, R., Venturini, L., 2007. Toxoplasmosis in captive Bennett's wallabies (*Macropus rufogriseus*) in Argentina. *Vet. Parasitol.* 144, 157–161.
- Bermudez, R., Failde, L.D., Losada, A.P., Nieto, J.M., Quiroga, M.I., 2009. Toxoplasmosis in Bennett's wallabies (*Macropus rufogriseus*) in Spain. *Vet. Parasitol.* 160, 155–158.
- Brennan, A., Donahoe, S.L., Beatty, J.A., Belov, K., Lindsay, S., Briscoe, K.A., Slapeta, J., Barrs, V.R., 2016. Comparison of genotypes of *Toxoplasma gondii* in domestic cats from Australia with latent infection or clinical toxoplasmosis. *Vet. Parasitol.* 228,

- 13–16.
- Burkhardt, H.J., 2000. Standardization and quality control of PCR analyses. *Clin. Chem. Lab. Med.* 38 (2), 87–91.
- Cenci-Goga, B.T., Rossitto, P.V., Sechi, P., McCrindle, C.M., Cullor, J.S., 2011. *Toxoplasma* in animals, food, and humans: an old parasite of new concern. *Foodb. Pathog. Dis.* 8 (7), 751–762.
- Cheng, W., Wang, C., Xu, T., Liu, F., Pappoe, F., Luo, Q., Xu, Y., Lu, F., Shen, J., 2017. Genotyping of polymorphic effectors of *Toxoplasma gondii* isolates from China. *Parasites Vectors* 10, 580.
- Diaz-Ayala, N., Hidalgo-Hermoso, E., Cabello-Araya, C., Carvallo-Chaigneau, F., 2016. Infection with *Toxoplasma gondii* in a red kangaroo (*Macropus rufus*) and a Patagonian mara (*Dolichotis patagonum*) in captivity. *Rev. Bras. Parasitol. Vet.* 25, 523–526.
- Dong, H., Su, R., Lu, Y., Wang, M., Liu, J., Jian, F., Yang, Y., 2018. Prevalence, risk factors, and genotypes of *Toxoplasma gondii* in food animals and humans (2000–2017) from China. *Front. Microbiol.* 9, 2108.
- Dubey, J.P., 2010. *Toxoplasmosis of Animals and Humans*, second ed. CRC Press, Taylor & Francis Group, Boca Raton, Florida, USA 1–313.
- Dubey, J.P., Crutchley, C., 2008. Toxoplasmosis in wallabies (*Macropus rufogriseus* and *Macropus eugenii*): blindness, treatment with atovaquone, and isolation of *Toxoplasma gondii*. *J. Parasitol.* 94, 929–933.
- Dubey, J.P., Desmonts, G., 1987. Serological responses of equids fed *Toxoplasma gondii* oocysts. *Equine Vet. J.* 19, 337–339.
- Dubey, J.P., Ott-Joslin, J., Torgerson, R.W., Topper, M.J., Sundberg, J.P., 1988. Toxoplasmosis in black-faced kangaroos (*Macropus fuliginosus melanops*). *Vet. Parasitol.* 30, 97–105.
- Dubey, J.P., Ferreira, L.R., Martins, J., McLeod, R., 2012. Oral oocyst-induced mouse model of toxoplasmosis: effect of infection with *Toxoplasma gondii* strains of different genotypes, dose, and mouse strains (transgenic, out-bred, in-bred) on pathogenesis and mortality. *Parasitology* 139 (1), 1–13.
- Epiphany, S., Sinhonini, I.L., Catão-Dias, J.L., 2003. Pathology of toxoplasmosis in captive new world primates. *J. Comp. Pathol.* 129 (2–3), 196–204.
- Fernandez-Aguilar, X., Ajzenberg, D., Cabezon, O., Martinez-Lopez, A., Darwich, L., Dubey, J.P., Almeria, S., 2013. Fatal toxoplasmosis associated with an atypical *Toxoplasma gondii* strain in a Bennett's wallaby (*Macropus rufogriseus*) in Spain. *Vet. Parasitol.* 196, 523–527.
- Guthrie, A., Rooker, L., Tan, R., Gerhold, R., Trainor, K., Jiang, T., Su, C., 2017. Newly described *Toxoplasma gondii* strain causes high mortality in red necked wallabies (*Macropus rufogriseus*) in a zoo. *J. Zoo Wildl. Med.* 48 (3), 694–702.
- More, G., Pardini, L., Basso, W., Machuca, M., Bacigalupe, D., Villanueva, M.C., Schares, G., Venturini, M.C., Venturini, L., 2010. Toxoplasmosis and genotyping of *Toxoplasma gondii* in *Macropus rufus* and *Macropus giganteus* in Argentina. *Vet. Parasitol.* 169, 57–61.
- Nishimura, M., Goyama, T., Tomikawa, S., Fereig, R.M., El-Alfy, E.N., Nagamune, K., Kobayashi, Y., Nishikawa, Y., 2019. Outbreak of toxoplasmosis in four squirrel monkeys (*Saimiri sciureus*) in Japan. *Parasitol. Int.* 68 (1), 79–86.
- Parameswaran, N., O'Handley, R.M., Grigg, M.E., Fenwick, S.G., Thompson, R.C.A., 2009. Seroprevalence of *Toxoplasma gondii* in wild kangaroos using an ELISA. *Parasitol. Int.* 58, 161–165.
- Parameswaran, N., Thompson, R.C., Sundar, N., Pan, S., Johnson, M., Smith, N.C., Grigg, M.E., 2010. Non-archetypal Type II-like and atypical strains of *Toxoplasma gondii* infecting marsupials of Australia. *Int. J. Parasitol.* 40 (6), 635–640.
- Rego, W.M.F., Costa, J.G.L., Baraviera, R.C.A., Pinto, L.V., Bessa, G.L., Lopes, R.E.N., Vitor, R.W.A., 2017. Association of ROP18 and ROP5 was efficient as a marker of virulence in atypical isolates of *Toxoplasma gondii* obtained from pigs and goats in Piauí, Brazil. *Vet. Parasitol.* 247, 19–25.
- Schares, G., Herrmann, D.C., Beckert, A., Schares, S., Hosseinienejad, M., Pantchev, N., Vrhovec, M.G., Conrath, F.J., 2008. Characterization of a repetitive DNA fragment in *Hammondia hammondi* and its utility for the specific differentiation of *H. hammondi* from *Toxoplasma gondii* by PCR. *Mol. Cell. Probes* 22, 244–251.
- Shuting, Pan, Andrew Thompson, R.C., Grigg, Michael E., Natarajan, Sundar, Smith, Andrew, Lymbery, Alan J., 2012. Western Australian marsupials are multiply infected with genetically diverse strains of *Toxoplasma gondii*. *PLoS One* 7 (9), e45147.
- Shwab, E.K., Zhu, X.Q., Majumdar, D., Pena, H.F., Gennari, S.M., Dubey, J.P., Su, C., 2014. Geographical patterns of *Toxoplasma gondii* genetic diversity revealed by multilocus PCR-RFLP genotyping. *Parasitology* 141, 453–461.
- Shwab, E.K., Jiang, T., Pena, H.F., Gennari, S.M., Dubey, J.P., Su, C., 2016. The ROP18 and ROP5 gene allele types are highly predictive of virulence in mice across globally distributed strains of *Toxoplasma gondii*. *Int. J. Parasitol.* 46 (2), 141–146.
- Su, C., Schwab, E.K., Zhou, P., Zhu, X.Q., Dubey, J.P., 2010. Moving towards an integrated approach to molecular detection and identification of *Toxoplasma gondii*. *Parasitology* 137 (1), 1–11.