

# Fluoroscopy-free cryoablation of atrial fibrillation guided solely by transoesophageal echocardiography: a case report

Damian Charles Balmforth<sup>1,2,3</sup>, Andrew Smith<sup>1</sup>, Richard Schilling<sup>1,2,3</sup>, and Ben O'Brien<sup>1,2,3\*</sup>

<sup>1</sup>Department of Perioperative Medicine, Barts Heart Centre, St Bartholomew's Hospital, 1st Floor KGV Wing, London EC1A 7BE, UK; <sup>2</sup>Department of Cardiology, London Bridge Hospital, 27 Tooley Street, London, SE1 2PR, UK; and <sup>3</sup>William Harvey Research Institute, Queen Mary University of London, Charterhouse Square, London, EC1M 6BQ, UK

Received 8 March 2018; accepted 1 November 2018; online publish-ahead-of-print 26 November 2018

## Background

Atrial fibrillation (AF) ablation has been shown to be possible using minimal or no fluoroscopic imaging for guidance. However, the techniques previously described focus on radiofrequency ablation or rely on the use of resource-heavy technology such as intra-cardiac echocardiography. We describe the first reported case in the literature of successful fluoroscopy-free AF cryoablation guided solely by transoesophageal echocardiography (TOE).

## Case summary

A 65-year-old gentleman underwent cryoablation of paroxysmal AF using TOE guidance only with no use of fluoroscopy. Transoesophageal echocardiography was used in all stages of the procedure including guidance for transseptal puncture, ensuring balloon position in the pulmonary veins, and checking for post-procedure pericardial effusion. After 5 months of follow-up, the patient remains in sinus rhythm and has discontinued all antiarrhythmic and anticoagulant medication.

## Discussion

This case demonstrates for the first time the feasibility of fluoroscopy-free cryoablation using only TOE for guidance.

## Keywords

Echocardiography • Ablation • Fluoroscopy-free • Atrial fibrillation • Case report

## Learning point

- It is possible to perform fluoroscopy-free cryoablation for atrial fibrillation using only transoesophageal echocardiography for guidance.

## Introduction

Atrial fibrillation (AF) ablation is routinely performed using either radiofrequency (RF) energy or cryotherapy to disrupt tissue and terminate unwanted electrical circuits. The application of both techniques is commonly guided by fluoroscopy. However, it is a universal goal in medical imaging to keep exposure to harmful ionising radiation 'as low as reasonably achievable'.<sup>1</sup> To this aim, several studies have

reported the practice of performing AF ablation with minimal or zero use of fluoroscopy. In general, these studies either focus on RF ablation, which is easier to perform without fluoroscopy than cryoablation due to the use of electro-anatomical mapping (EAM), or employ resource-heavy imaging techniques such as intra-cardiac echocardiography (ICE).<sup>2,3</sup> Here, we report a case of successful fluoroscopy-free cryoablation of AF and describe a protocol for guidance using standard transoesophageal echocardiography (TOE) only.

\* Corresponding author. Tel: +442034658054, Email: ben.obrien@bartshealth.nhs.uk

Handling Editor: Tom de Potter

Peer-reviewers: Rami Riziq Yousef Abumualeq and Philipp Sommer

Compliance Editor: Mohammed Akhtar

Supplementary Material Editor: Peysh Patel

© The Author(s) 2018. Published by Oxford University Press on behalf of the European Society of Cardiology.

This is an Open Access article distributed under the terms of the Creative Commons Attribution Non-Commercial License (<http://creativecommons.org/licenses/by-nc/4.0/>), which permits non-commercial re-use, distribution, and reproduction in any medium, provided the original work is properly cited. For commercial re-use, please contact [journals.permissions@oup.com](mailto:journals.permissions@oup.com)

## Timeline

5 years prior to presentation	Diagnosed with atrial fibrillation (AF) after a prostate biopsy for raised prostate specific antigen. Initially managed medically with Flecainide.
Initial presentation: January 2018	Patient became increasingly symptomatic with AF. Decision made to perform cryoablation of AF. Rivaroxaban commenced.
10 days post-presentation: January 2018.	Cryoablation and transoesophageal echocardiography performed under anaesthesia-uncomplicated procedure. Patient discharged on the 1st post-procedural day in sinus rhythm. Antiarrhythmics discontinued.
May 2018	Patient reviewed in clinic. Remains in sinus rhythm whilst off all antiarrhythmic medication. No recurrence of symptoms previously associated with AF. Occasional dropped beats reported by patient. ECG recordings corresponding to these episodes confirm sinus rhythm on every occasion. Anticoagulation discontinued.

## Case presentation

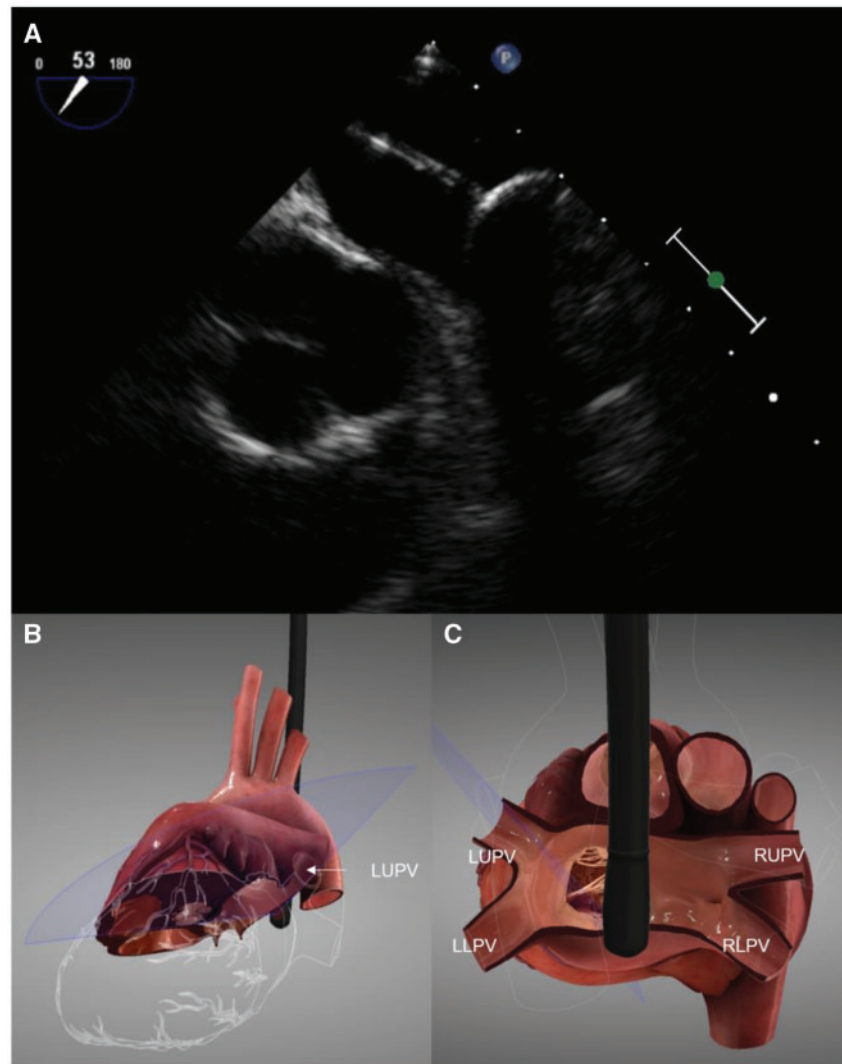
A 65-year-old gentleman presented to the outpatient department with a history of non-valvular paroxysmal atrial fibrillation for the last 5 years. He had recently been experiencing increasing frequency of palpitations associated with symptoms of light headedness and hot flushing despite increasing doses of Flecainide (maximal dose 150 mg, twice a day). These symptoms were correlated with episodes of AF seen on Holter monitoring. The patient had no other significant past medical history. Examination of the cardiovascular system was unremarkable and blood tests revealed no evidence of thyrotoxicosis or other secondary causes of AF. After discussion of various treatment options, it was decided to proceed with a catheter ablation. The patient's CHA<sub>2</sub>DS<sub>2</sub>-VASc score was 1. As such, he was switched from oral Aspirin to Rivaroxaban for anticoagulation, with a plan to revert back to Aspirin at 3 months of post-successful ablation.

In January 2018, the patient underwent fluoroscopy-free cryoablation of his AF in accordance with a locally developed protocol. He was in sinus rhythm at the start of the procedure. The patient was anaesthetized using a total intravenous anaesthesia protocol with propofol and remifentanyl. Uninterrupted oral anticoagulation was used together with 10 000 U of intravenous (IV) heparin given as a weight-adjusted dose. The activated clotting time (ACT) was not measured in accordance with our locally developed protocol,<sup>4</sup> as we have found that the short-procedure duration makes it impossible to reliably measure and respond to ACT measurements prior to the end of the procedure.

Transoesophageal echocardiography was used to confirm that the left atrium (LA) was free of thrombus. The LA diameter was 41 mm. The procedure itself was performed using TOE guidance only with no X-ray exposure. The catheter laboratory team did not wear lead aprons. We have previously described our protocol for transseptal puncture under TOE with accompanying imaging.<sup>4</sup> A single transseptal puncture was performed using an Endrys needle (Cook Medical, IN, USA) and a Mullins sheath and dilator (Cook Medical, IN, USA) under TOE guidance. This sheath was then exchanged for a FlexCath Steerable Sheath (Medtronic, MN, USA). Next, the Endrys needle was exchanged for a 20 mm Achieve Mapping Catheter over which a 28 mm cardiac cryoablation catheter (Medtronic, MN, USA) was introduced. All four pulmonary veins were then isolated using the Achieve wire to demonstrate electrical isolation (*Figure 1*; [Supplementary material Videos 1 and 2](#)). Entry block was determined by loss of pulmonary vein potential during the freeze. Exit block was harder to reliably confirm because of the limited number of electrodes on the Achieve wire making pace capture in the pulmonary veins unreliable. Correct positioning of the cryoballoon in the pulmonary veins was aided by flushing the cryoablation catheter and checking for the appearance of micro bubbles in the LA. Micro bubbles were looked for on TOE during flushing of agitated saline through the distal port of a pressure line that is usually used to inject contrast for fluoroscopy. Transoesophageal echocardiography views were obtained to assess the LA immediately distal to the pulmonary vein origins and then adjusted to identify the anatomical position of the leak to assist with cryoballoon positioning. During the right pulmonary vein freezes the phrenic nerve was paced and diaphragmatic contraction confirmed throughout by palpation of the abdomen. Electrical isolation of the pulmonary veins was confirmed on the electrograms generated by the EP recording system (LABSYSTEM Pro EP, Boston Scientific) (*Figure 2*). At the end of the procedure, TOE was used to check for the absence of pericardial effusion. The total procedure time, from induction of anaesthesia, to completion of ablation, was 72 min. The patient stayed overnight in hospital prior to being discharged without complication. He was instructed to use an electrocardiogram (ECG) event recorder (AliveCor KardiaMobile) periodically as well as during any symptomatic periods during his recovery. At 5 months of follow-up, the patient remained in sinus rhythm on 12-lead ECG with no reported symptoms of palpitation but occasional ectopic beats. Results from the ECG event recorder confirmed sinus rhythm throughout, even during episodes of missed beats, whilst off all antiarrhythmic medication. As such, Rivaroxaban therapy was discontinued.

## Discussion

Best practice dictates that radiation exposure within the catheter laboratory be reduced to 'As low as reasonably possible'.<sup>1</sup> This principal is driven primarily by the need to minimize the risk to healthcare workers of repeat radiation exposure from fluoroscopy. As such, efforts continue to be made to reduce radiation exposure from fluoroscopy. A recent report by Sommer et al.,<sup>5</sup> describes the experience of 'near-zero fluoroscopy' in 1000 patients undergoing RF ablation with a mean fluoroscopy time of 0.9 min. This protocol reduced fluoroscopic exposure by using a 'non-fluoroscopic catheter visualization technology' (NFCV) in which a transmitter generating a three-dimensional electromagnetic map is incorporated into the

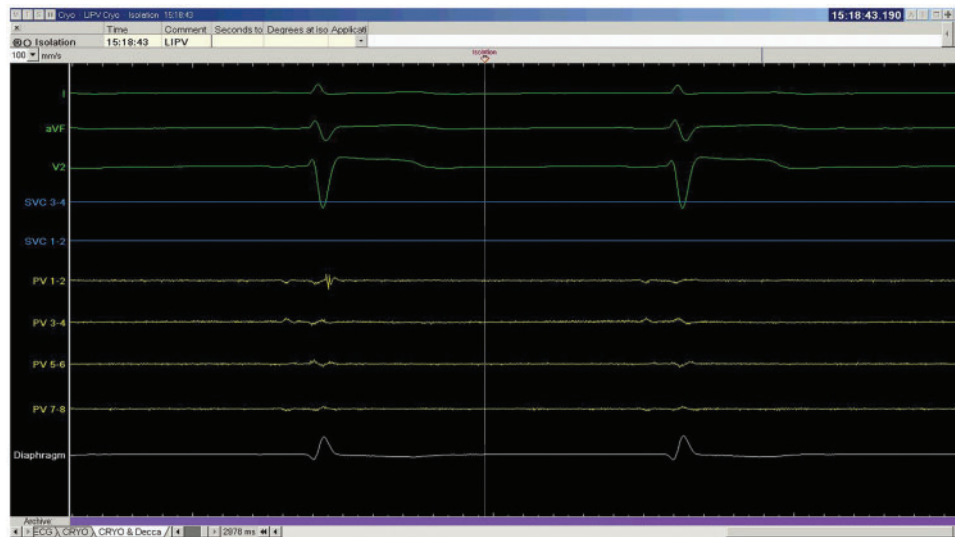


**Figure 1** (A) Transoesophageal echocardiographic images showing the cryoablation catheter seen in the left atrium with the balloon inflated in the left upper pulmonary vein. (B and C) Three-dimensional simulated representations of transoesophageal echocardiography probe position and imaged section of heart corresponding to the image seen in A.

fluoroscopy detector. However, this protocol still utilizes fluoroscopy to calibrate the NFCV system and to guide the transeptal puncture. Several studies describe the use of fluoroscopy-free RF ablation but rely on the use of ICE for guidance<sup>3,6-8</sup> in addition to EAM. Whilst ICE produces high quality images of the structure of the heart it is limited by its high associated costs, as well as the need for separate vascular access and the space that it occupies in the heart. As such, it is rarely used within Europe.

We have recently described our experience of fluoroscopy-free RF ablation guided solely by TOE and EAM in 69 patients.<sup>4</sup> Cryoablation for pulmonary vein isolation has been shown to have a similar efficacy and safety profile as RF ablation.<sup>9</sup> However, cryoablation has the significant advantage of a shorter procedure duration due to the ability of the cryoballoon to deliver circumferential, single

step ablations of the pulmonary veins. Whilst several other studies describe the use of TOE to guide cryoablation, this is in addition to the use of fluoroscopy.<sup>10,11</sup> Our experience of using TOE to guide transeptal puncture has enabled us to progress to fluoroscopy-free cryoablation of the pulmonary veins using TOE as the sole imaging modality. This was a gradual process whereby we found that our increasing experience of TOE guidance resulted in us using less and less fluoroscopy in each case of cryoablation. Eventually, we evolved our practice to a point where the use of fluoroscopy was no longer required. To the best of our knowledge, the current case represents the first description of completely fluoroscopy-free cryoablation. However, it is important to note that we retain the facilities to employ fluoroscopy if it should be required at any time during the procedure. Transoesophageal echocardiography can be used to guide the



**Figure 2** An example of electrograms from the EP system during sinus rhythm and isolation of the left inferior pulmonary vein. Recordings are shown at 100 mm/s for the standard surface ECG leads I, aVF, and V2 (green), the quadripolar catheter in the superior vena cava (blue), the pulmonary vein (yellow) and the surface diaphragm potential (white). A local pulmonary vein (PV) potential can be seen on the first set of electrograms with delayed conduction into the vein just before isolation and loss of the local electrogram on the subsequent complex of the PV electrograms. The far-field electrogram component which times with the P wave on the surface ECG remains unaffected in size and timing.

transseptal puncture as well as to identify the target veins, navigate the catheter towards the orifice and visualize the position of the catheter balloon within the pulmonary veins (Figure 1). Furthermore, micro air bubbles injected via the ablation catheter distal to the balloon can give the experienced operator an indication of the exact location of the catheter balloon within the pulmonary vein, to optimize balloon position prior to freezing. From our experience of imaging the balloon with TOE during fluoroscopy assisted procedures and correlating the appearances with the success of ablation, we had found that it is optimal if some bubbles are seen within the LA on injection. It is our opinion that a complete absence of bubbles indicates that the balloon is placed too distally within the vein. The resulting increase in volume of the balloon that occurs on freezing can be dangerous if the initial balloon position within the vein is occlusive.

In summary, we report the first case of successful fluoroscopy-free AF cryoablation guided solely by TOE. Further studies are required to determine if such a method confers additional benefits over and above that of reduced radiation exposure, for example by virtue of more optimal positioning of the balloon within the vein.

## Conclusion

Fluoroscopy-free cryoablation of AF can be performed successfully using TOE alone for guidance.

## Supplementary material

Supplementary material is available at *European Heart Journal - Case Reports* online.

**Slide sets:** A fully edited slide set detailing this case and suitable for local presentation is available online as [Supplementary data](#).

**Consent:** The author/s confirm that written consent for submission and publication of this case report including image(s) and associated text has been obtained from the patient in line with COPE guidance.

**Conflict of interest:** R.S. has received research grants and speaker fees from Medtronic and Boston Scientific.

## References

- Limacher MC, Douglas PS, Germano G, Laskey WK, Lindsay BD, McKetty MH, Moore ME, Park JK, Prigent FM, Walsh MN. ACC expert consensus document. Radiation safety in the practice of cardiology. American College of Cardiology. *J Am Coll Cardiol* 1998;**31**:892–913.
- Earley MJ, Showkathali R, Alzetani M, Kistler PM, Gupta D, Abrams DJ, Horrocks JA, Harris SJ, Sporton SC, Schilling RJ. Radiofrequency ablation of arrhythmias guided by non-fluoroscopic catheter location: a prospective randomized trial. *Eur Heart J* 2006;**27**:1223–1229.
- Bulava A, Hanis J, Eisenberger M. Catheter ablation of atrial fibrillation using zero-fluoroscopy technique: a randomized trial. *Pacing Clin Electrophysiol* 2015;**38**: 797–806.
- O'Brien B, Balmforth DC, Hunter RJ, Schilling RJ. Fluoroscopy-free AF ablation using transesophageal echocardiography and electroanatomical mapping technology. *J Interv Card Electrophysiol* 2017.
- Sommer P, Bertagnolli L, Kircher S, Arya A, Bollmann A, Richter S, Rolf S, Hindricks G. Safety profile of near-zero fluoroscopy atrial fibrillation ablation with non-fluoroscopic catheter visualization: experience from 1000 consecutive procedures. *Europace* 2018.
- Reddy VY, Morales G, Ahmed H, Neuzil P, Dukkipati S, Kim S, Clemens J, D'Avila A. Catheter ablation of atrial fibrillation without the use of fluoroscopy. *Heart Rhythm* 2010;**7**:1644–1653.
- Razminia M, Manankil MF, Eryazici PL, Arrieta-Garcia C, Wang T, D'Silva OJ, Lopez CS, Crystal GJ, Khan S, Stancu M, Turner M, Anthony J, Zheutlin TA, Kehoe RF. Nonfluoroscopic catheter ablation of cardiac arrhythmias in adults: feasibility, safety, and efficacy. *J Cardiovasc Electrophysiol* 2012;**23**: 1078–1086.

8. Razminia M, Willoughby MC, Demo H, Keshmiri H, Wang T, D'Silva OJ, Zheutlin TA, Jibawi H, Okhumale P, Kehoe RF. Fluoroless catheter ablation of cardiac arrhythmias: a 5-year experience. *Pacing Clin Electrophysiol* 2017;**40**:425–433.
9. Kuck K-H, Brugada J, Fürnkranz A, Metzner A, Ouyang F, Chun KRJ, Elvan A, Arentz T, Bestehorn K, Pocock SJ, Albenque J-P, Tondo C. Cryoballoon or radiofrequency ablation for paroxysmal atrial fibrillation. *N Engl J Med* 2016;**374**: 2235–2245.
10. Kerut EK, Hanawalt C, McKinnie J. Transesophageal echocardiography during pulmonary vein cryoballoon ablation for atrial fibrillation. *Echocardiography* 2015; **32**:281–290.
11. Ottaviano L, Chierchia G-B, Bregasi A, Bruno N, Antonelli A, Alsheraei ATA, Porrini AM, Gronda E, Donatelli F, Duijnhower A-L, Brugada P, Montenero AS. Cryoballoon ablation for atrial fibrillation guided by real-time three-dimensional transoesophageal echocardiography: a feasibility study. *Europace* 2013;**15**:944–950.