

CASE REPORT

# Possible Role of a Missense Mutation of p.P167S on *NOTCH3* Gene Associated with Cerebral Autosomal Dominant Arteriopathy with Subcortical Infarcts and Leukoencephalopathy

Byung Woo Choi,\* Seongho Park,\* Hee-Jin Kim

Department of Neurology, College of Medicine, Hanyang University, Seoul, Korea

**Background** Cerebral autosomal dominant arteriopathy with subcortical infarcts and leukoencephalopathy (CADASIL) is a single-gene disorder caused by mutations in the *NOTCH3* gene, located on chromosome 19p13. *NOTCH3* encodes a transmembrane receptor which plays a role in cellular differentiation and cell cycle regulation.

**Case Report** A 71-year-old female showing headache and memory impairment, familial history of stroke and having a missense mutation from proline to serine at codon 167 in the exon 4 on *NOTCH3* gene. Five family members revealed the same mutation (c.499C>T), who presented migrainous headache and stroke. In this study, we have uncovered a novel *NOTCH3* mutation at the nucleotide position 499 (c.499C>T; p.P167S) in a family with CADASIL.

**Conclusions** We suggested a missense mutation of proline to serine at codon 167 in exon 4 of the *NOTCH3* gene, which resulted in the substitution of cytosine to thymine (c.499C>T) resulting migraine, stroke and vascular cognitive impairment.

**Key Words** cerebral autosomal dominant arteriopathy with subcortical infarcts and leukoencephalopathy, c.499C>T, p.P167S.

**Received:** June 10, 2016 **Revised:** June 16, 2016 **Accepted:** June 16, 2016

**Correspondence:** Hee-Jin Kim, MD, PhD, Department of Neurology, College of Medicine, Hanyang University, 222-1 Wangsimni-ro, Seongdong-gu, Seoul 04763, Korea

**Tel:** +82-2-2290-8374, **Fax:** +82-2-2296-8370, **E-mail:** hyumcbrain@hanyang.ac.kr

\*These authors are equally contributed.

## INTRODUCTION

Cerebral autosomal dominant arteriopathy with subcortical infarcts and leukoencephalopathy (CADASIL) is a rare autosomal-dominant hereditary disease of the small arterial vessels in the brain. It is clinically associated with subcortical ischemic events, migraine-type headache, mood disturbances (including apathy), cognitive impairment and other clinical manifestations (such as intracerebral hemorrhage, territorial infarct, deafness and Parkinsonism).<sup>1</sup> CADASIL is a single-

gene disorder caused by mutations in the *NOTCH3* gene, located on chromosome 19p13. *NOTCH3* encodes a transmembrane receptor which plays a role in cellular differentiation and cell cycle regulation.<sup>2</sup> In this study, we have uncovered a novel *NOTCH3* mutation at the nucleotide position 499 (c.499C>T; p.P167S) in a family with CADASIL. We reported a case of a 71-year-old female showing headache and memory impairment, familial history of stroke and having a missense mutation from proline to serine at codon 167 in the exon 4 on *NOTCH3* gene.

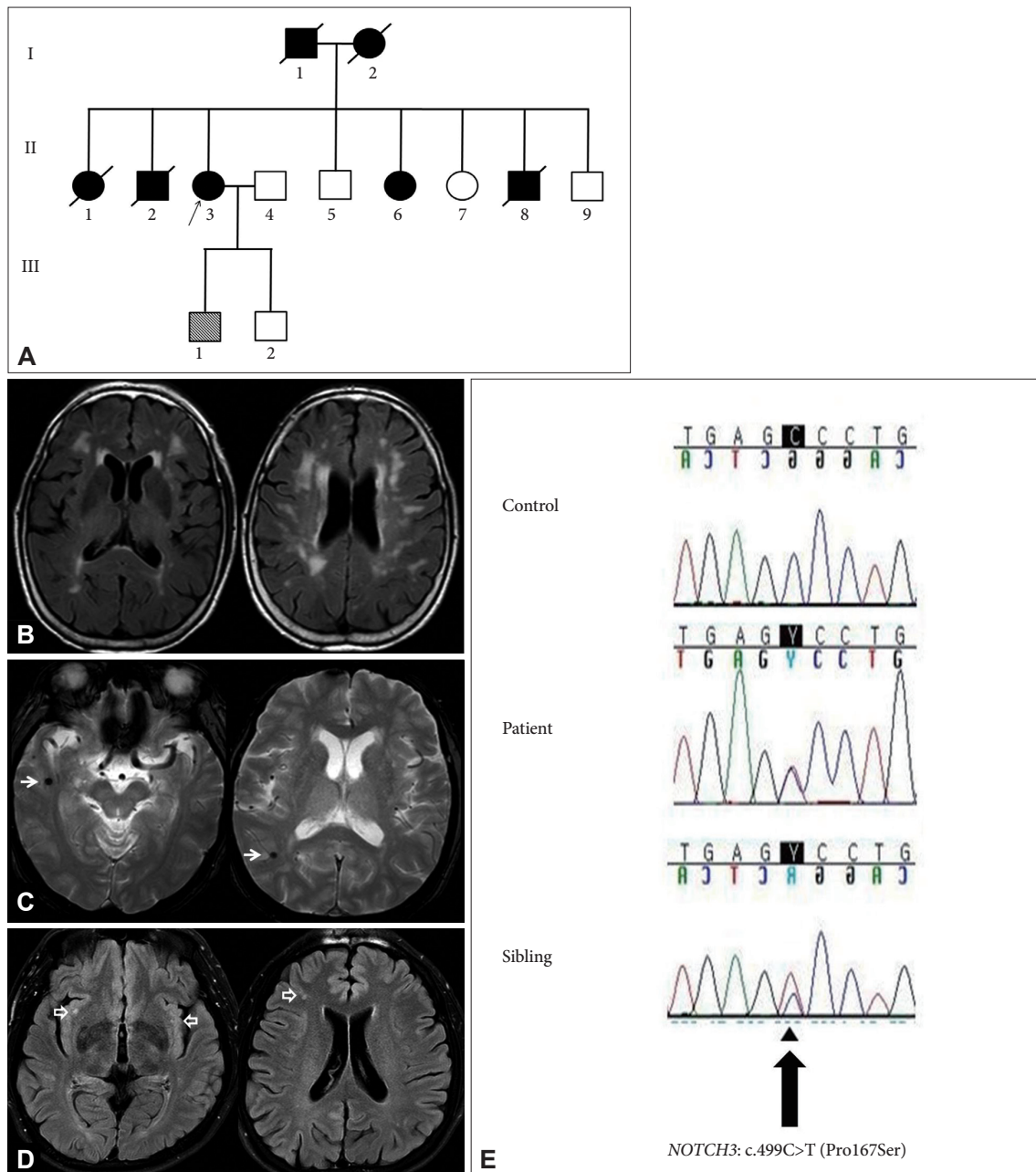
## CASE REPORT

A 71-year-old female patient was admitted to the neurology outpatient clinic. She had suffered from chronic headaches

© This is an Open Access article distributed under the terms of the Creative Commons Attribution Non-Commercial License (<http://creativecommons.org/licenses/by-nc/3.0>) which permits unrestricted non-commercial use, distribution, and reproduction in any medium, provided the original work is properly cited.

and memory disturbance for 20 years. The headache was characterized as dull and pulsating in the bilateral temporal area. The absence of nausea, vomiting and visual or auditory symptoms eliminated the possibility of migraine. Her cognitive examination revealed a Korean Mini-Mental State Examination

score of 26 and a Clinical Dementia Rating score of 0.5. The results from a complex neuropsychological test indicated a mild cognitive impairment. No other neurological symptoms were observed. The patient was a non-smoker with minimal alcohol consumption. Hypertension and hyperlipidemia had



**Fig. 1.** A: Pedigree of a family with c.499C>T mutation. Black arrow (II.3) indicates the proband. Filled symbols indicate individuals who had stroke. Analysis of exon 4 of the *NOTCH3* gene performed on five family members (II.6, II.7, II.9, III.1, III.2). Proband (II.3), her sister (II.6) and first-born son (III.1) had a novel c.499C>T mutation. B: Magnetic resonance imaging (fluid attenuation inversion recovery) revealed bilateral hyperintensities in the periventricular, subcortical and left external capsular white matter. C: Gradient recalled echo showed microbleeds at the right temporal and parietal lobe (arrows). D: Magnetic resonance imaging (fluid attenuation inversion recovery) revealed hyperintensities in the subcortical and right external capsular white matter (open arrows) in first-born son. E: Sequencing of *NOTCH3* in this family revealed a heterozygous C-to-T substitution at nucleotide position 499, which changes a proline to serine at codon 167 (c.499C>T; p.P167S). The proband's first-born son and sibling had the same mutation.

been well controlled in the patient for 8 years. There was a familial history of stroke; both of the patient's parents and three siblings had suffered a stroke previously (Fig. 1A).

Initial laboratory findings were normal. Magnetic resonance imaging of the brain revealed bilateral confluent high-signal changes in the periventricular, subcortical and left external capsular white matter ischemic lesions and microbleeds in the temporal and right parietal lobe (Fig. 1B and C). Targeted analysis of exon 4 in the *NOTCH3* gene of five family members (two brothers and one sister, two sons) revealed that one sibling and her first son had the same mutation (c.499C>T), who had migrainous headache and stroke. His magnetic resonance imaging of the brain revealed high signal changes in the subcortical and right external capsular white matter ischemic lesion (Fig. 1D). Analysis of exon 4 in the *NOTCH3* gene showed uncovered unclassified sequence variant (c.499C>T) (Fig. 1E).

## DISCUSSION

We identified a missense mutation of proline to serine at codon 167 in exon 4 of the *NOTCH3* gene, which resulted in the substitution of cytosine to thymine (c.499C>T) resulting migraine, stroke and vascular cognitive impairment. CADASIL is clinically associated with subcortical ischemic events, migraine-type headache, mood disturbances (including apathy), cognitive impairment and other clinical manifestations (such as intracerebral hemorrhage, territorial infarct, deafness and Parkinsonism).<sup>1</sup> The *NOTCH3* gene has 33 exons and most mutations are located within exons 2-23. In Korea, particularly Jeju Island, the most common mutations are found in exons 3, 6 and 11, such as the p.R544C mutation in exon 11.<sup>3</sup>

A diagnosis of CADASIL in the patient was extremely probable based on a score of 17 on the CADASIL scale (cognitive decline/dementia, leukoencephalopathy extended to external capsule, subcortical infarcts, family history in at least two generations, ranging from 0 to 25).<sup>4</sup> There are some debates whether c.499C>T mutation in the *NOTCH3* gene is responsible for the patient's condition. It has been known Cys-sparing mutation, P167S, is considered as a rare polymorphism rather than CADASIL-causing mutation, because; 1) P167S (rs202157633) is already reported as an east Asian-specific rare variant (five heterozygous individuals among 504 individuals, minor allele frequency=0.005, 1000 Genome phase 3.<sup>5,6</sup> 2) Prediction of functional effect of P167S was tolerated (sorting intolerant from tolerant) or benign (polymorphism phenotyping).<sup>7</sup> However,

some report suggested that possibility of same *NOTCH3* gene mutation has different pattern with typical CADASIL.<sup>8</sup> Although further background study is necessary for proving this theory, we suggested that this missense mutation is CADASIL rather than polymorphism in this family in the points that patient showed headache and memory impairment and other family members with same mutation presented CADASIL-like symptoms such as headache, stroke, or vascular cognitive impairment.

Our study has some limitations. We were unable to analyze those deceased family members who suffered from stroke and were therefore most likely to carry the mutation. Additionally, the living family member (son) with the c.499C>T mutation appears to be minimally affected. We will monitor this patient closely in the future for symptoms of CADASIL.

In conclusion, this study has suggested the possibility that missense variant of p.P167S in *NOTCH3* gene has contributed to our knowledge of CADASIL and related genetic disorders.

## Conflicts of Interest

The authors have no financial conflicts of interest.

## REFERENCES

1. Chabriat H, Joutel A, Dichgans M, Tournier-Lasserre E, Bousser MG. Cadasil. *Lancet Neurol* 2009;8:643-653.
2. Joutel A, Corpechot C, Ducros A, Vahedi K, Chabriat H, Mouton P, et al. Notch3 mutations in CADASIL, a hereditary adult-onset condition causing stroke and dementia. *Nature* 1996;383:707-710.
3. Kim YE, Yoon CW, Seo SW, Ki CS, Kim YB, Kim JW, et al. Spectrum of NOTCH3 mutations in Korean patients with clinically suspicious cerebral autosomal dominant arteriopathy with subcortical infarcts and leukoencephalopathy. *Neurobiol Aging* 2014;35:726.e1-726.e6.
4. Pescini F, Nannucci S, Bertaccini B, Salvadori E, Bianchi S, Ragno M, et al. The Cerebral Autosomal-Dominant Arteriopathy With Subcortical Infarcts and Leukoencephalopathy (CADASIL) Scale: a screening tool to select patients for NOTCH3 gene analysis. *Stroke* 2012;43:2871-2876.
5. Tomimoto H, Ohtani R, Wakita H, Lin JX, Ihara M, Miki Y, et al. Small artery dementia in Japan: radiological differences between CADASIL, leukoariosis and Binswanger's disease. *Dement Geriatr Cogn Disord* 2006;21:162-169.
6. Mizuno T, Mizuta I, Tomimoto H. Evaluation of NOTCH3 Pro167Ser variation in a Japanese family with cerebral autosomal dominant arteriopathy with subcortical infarcts and leukoencephalopathy. *Dement Geriatr Cogn Disord Extra* 2016;6:183-184.
7. Cheng CY, Yamashiro K, Chen LJ, Ahn J, Huang L, Huang L, et al. New loci and coding variants confer risk for age-related macular degeneration in East Asians. *Nat Commun* 2015;6:6063.
8. Yoon CW, Kim YE, Seo SW, Ki CS, Choi SH, Kim JW, et al. NOTCH3 variants in patients with subcortical vascular cognitive impairment: a comparison with typical CADASIL patients. *Neurobiol Aging* 2015;36:2443.e1-2443.e7.