

Role of inflammatory factors in the effects of aflibercept or ranibizumab treatment for alleviating wet age-associated macular degeneration

JIANSHU YUAN

Ophthalmology Department, Ningbo Eye Hospital, Ningbo, Zhejiang 315040, P.R. China

Received February 9, 2018; Accepted September 13, 2018

DOI: 10.3892/etm.2019.7427

Abstract. Aflibercept and ranibizumab are novel drugs for effectively treating wet age-associated macular degeneration (AMD). In the present study, the effect of aflibercept and ranibizumab on wet AMD was compared. A total of 80 AMD patients were intravitreally treated with aflibercept (2.0 mg/dose, 40 participants) or ranibizumab (0.3 mg/dose, 40 participants). The mean visual acuity and central subfield thickness (CTS) were determined at baseline and each follow-up visit (every 4 weeks). ELISA was used to detect the expression of transforming growth factor- β 1 (TGF- β 1), monocyte chemoattractant protein 1 (MCP-1) and interleukin 6 (IL-6). The primary outcome was the mean change in visual acuity letter score (VAS) and CTS at 1 year. The VAS was markedly improved by 13.1 in the aflibercept group and by 11.0 in the ranibizumab group. In a subgroup of patients with an initial VAS of <69, the mean improvement in the VAS was 17.7 in the aflibercept group and 13.2 in the ranibizumab group ($P < 0.01$). The mean CTS was markedly decreased by 141 in the aflibercept group and by 134 in the ranibizumab group. In the subgroup of patients with an initial VAS of <69, the mean CTS was decreased by 171 in the aflibercept group and by 154 in the ranibizumab group ($P < 0.01$). However, the change of VAS and CTS was similar between the ranibizumab and aflibercept groups when the initial VAS was ≥ 69 . No significant differences in serious adverse events were identified between the aflibercept and ranibizumab groups. The levels of TGF- β 1, IL-6 and MCP-1 were decreased by the aflibercept and ranibizumab treatments. The decrease in the levels of the inflammatory factors was more obvious in patients with an initial VAS of <69 in comparison with that in patients with an initial VAS of ≥ 69 . Negative correlations between the levels

of TGF- β 1, MCP-1 and IL-6 and the mean change of VAS when patients were treated with aflibercept or ranibizumab were identified among all ages. Positive correlations between the levels of TGF- β 1, MCP-1 and IL-6 and the mean change of CTS were observed when the initial VAS of the patients was <69. In conclusion, the efficacy of aflibercept in treating patients with AMD was better than that of ranibizumab when the initial VAS of the patients was <69. The inhibition of inflammatory factors may be a secondary effect of aflibercept and ranibizumab treatment. The present study provides a useful reference for the clinical treatment of wet AMD (Chinese Clinical Trial Registry no. ChiCTR1800017782).

Introduction

Age-associated macular degeneration (AMD) is one of the most important causes of blindness in individuals aged >50 years worldwide. The incidence of AMD has been rapidly increasing in recent years (1). The prevalent lesion of AMD is an irreversible vision loss caused by retrogression of retinal pigment epithelium (RPE) and neural retina (2). AMD is classified into dry AMD (geographic atrophy) and wet AMD (exudative). Dry AMD is characterized by drusen accumulation around RPE and retrogression of the RPE, while wet AMD is characterized by choroidal neovascularization (CNV) and results in severe vision loss. As CNV is a major cause of severe vision loss (3,4), therapeutic strategies for AMD focus on reversing neovascularization; they include photodynamic therapy and anti-angiogenic drugs (5).

AMD-associated pathways and factors that stimulate CNV remain to be fully elucidated. However, vascular endothelial growth factor A (VEGF-A), a cytokine that promotes angiogenesis and vascular permeability, is one of the most important factors that promotes neovascularization (6). Active forms of VEGF-A have been identified in CNV (7-9). Anti-VEGF therapies are now becoming the focus of AMD treatment (7). Aflibercept and ranibizumab, two recombinant humanized monoclonal antibodies that inactivate VEGF-A, are novel therapies that help numerous AMD patients gain a sustainable vision (8). They were respectively approved in 2006 and 2011 by the US Food and Drug Administration for use in treating wet AMD (9,10). The clinical implementation of such drugs, which directly inhibit VEGF activity, may offer affected patients hope for improving their vision.

Correspondence to: Dr Jianshu Yuan, Ophthalmology Department, Ningbo Eye Hospital, 855 Min'an Road, Ningbo, Zhejiang 315040, P.R. China

E-mail: jianshu_Yuan6407@163.com

Key words: aflibercept, ranibizumab, age-associated macular degeneration, visual acuity, central subfield thickness, inflammatory response

Chronic inflammation may induce AMD by stimulating the formation of an abnormal vessel structure. Hemamoeba was discovered in choroiditis in the eyes of AMD patients (7). It was identified that auto-antibodies to attack vitreous bodies, retinal pigment epithelium and retinal tissue in AMD patients (11). Lymphocytes and macrophages secrete an increased amount of inflammatory factors in subjects with AMD (12). Certain inflammatory factors, including transforming growth factor- β 1 (TGF- β 1), monocyte chemoattractant protein 1 (MCP-1) and interleukin 6 (IL-6), were reported to be closely associated with the angiogenesis occurring as part of the pathogenesis of AMD (11,13). Regarding drugs for AMD, investigating the correlation between inflammatory factors and drug treatment effects in clinical studies may help to further assess their efficiency.

The present study aimed to compare the treatment outcome of aflibercept and ranibizumab in patients with wet AMD by evaluating their visual acuity letter score (VAS) and measuring central subfield thickness (CST). In addition, the possible correlation between inflammatory factors and the treatment efficacy of aflibercept and ranibizumab was investigated. The present study provides a reference for the clinical treatment of wet AMD.

Materials and methods

Patients and aqueous humor collection. A total of 80 patients with wet AMD (mean age, 57 \pm 10 years) who presented at Ningbo No. 6 Hospital (Ningbo, China) between May 2016 and November 2017 were recruited for the present study. The patients enrolled all had primary or recurrent CNV associated with wet AMD. None of the patients included had received any anti-VEGF treatment for one year prior to the study commencing. Subjects with hyperlipidaemia, hypertension, diabetes mellitus, heart failure and renal failure were excluded. The collection of aqueous humor samples was in accordance with the procedures approved by the institutional review board of the independent ethics committee of Ningbo No. 6 Hospital (Ningbo, China) and following a standard sterilization procedure. After topical anesthesia with 0.4% oxybuprocaine hydrochloride eye drops (Eisai Co., Ltd., Tokyo, Japan), 100 μ l of aqueous humor was withdrawn with a tuberculin syringe (30-gauge needle) at the corneal limbus and was immediately stored at -80°C.

Treatment. A total of 40 patients with wet AMD were intravitreally injected with aflibercept (Eylea; Regeneron Pharmaceuticals, Eastview, NY, USA) at a dose of 2.0 mg, and the other 40 patients with wet AMD were intravitreally injected with 0.3 mg ranibizumab in a dose of 0.5 mg (LUCENTIS™; Genentech Inc., San Francisco, CA, USA) every 4 weeks (\pm 1 week) for 1 year. If two eyes were available in one patient, the eye with the better visual acuity was chosen to be treated, unless the clinician considered the other eye more appropriate for certain medical reasons (14).

Observations. The VAS (ranging from 0 to 100) and CST were monitored every 4 weeks (\pm 1 week) during the one-year treatment period. The VAS was measured based on using the Electronic Early Treatment of Diabetic Retinopathy Study

Visual Acuity Test (15). A VAS of <69 was equivalent to 20/50 or worse according to a previous study (16), and thus, 69 was selected as the cut-off point for the initial VAS. The CST was measured using a Cirrus™ SD-OCT (Zeiss AG, Oberkochen, Germany) with best-corrected visual acuity. The higher VAS and lower CST correlated with better visual acuities. An increase in the VAS by 5 or a decrease in CST by 10% (\sim 1 Snellen line) was considered to indicate an improvement in visual acuity. After 6 months, the treatment would be terminated if the VAS or CST was not improved or even deteriorated after 2 successive injections, or when the visual acuity was better than 20/20. All cases with adverse events were recorded and monitored.

ELISA. The quantities of TGF- β 1, IL-6 and MCP-1 in aqueous humor samples collected from the patients at baseline and the follow-up time-points were determined using ELISA kits (R&D Systems, Minneapolis, MN, USA) following the manufacturer's protocols, including Human TGF-beta 1 Quantikine ELISA kit (cat. no. SB100B), Human IL-6 Quantikine ELISA kit (cat. no. S6050) and Human CCL2/MCP-1 Quantikine ELISA kit (cat. no. SCP00). Finally, the optical density values were read at 450 nm by using Multiskan FC microplate photometer (Thermo Fisher Scientific, Inc., Waltham, MA, USA). The quantities of the analytes were determined by using a standard curve.

Statistical analysis. The mean changes of VAS and CST were calculated and compared among the different treatment groups. All results are expressed as the mean \pm standard deviation. Statistical analysis was performed using the SPSS 22.0 statistical package (IBM Corp., Armonk, NY, USA) and GraphPad Prism 6.0 (GraphPad Inc., La Jolla, CA, USA). The Chi-squared test was used to compare categorical variables. Spearman's correlation analysis was used to evaluate the correlation among numerical data. One-way analysis of variance followed by Dunnett's test was used to compare differences among groups. $P < 0.05$ was considered to indicate a statistically significant difference.

Results

Patients and treatments. The 80 patients with wet AMD were randomly assigned into two groups that were respectively injected with aflibercept or ranibizumab intravitreally. The clinical characteristics of the patients are displayed in Table I. At baseline, the characteristics in the two groups were similar. When the initial VAS was \geq 69, the median number of injections was 10 in each group (data not shown). However, when the initial VAS was <69, the median number of injections was 11 in each group (data not shown). These differences were not significant.

Effect of aflibercept or ranibizumab on VAS. The mean VAS improved significantly during the one-year treatment period, with an overall increase by 13.1 in the aflibercept group and by 11.0 in the ranibizumab group. As presented in Fig. 1A, the improvement of VAS in the aflibercept group was significantly higher than that in the ranibizumab group. The extent of improvement of the VAS varied depending

Table I. Characteristics of patients included in the present study.

Characteristic	Aflibercept (n=40)	Ranibizumab (n=40)	P-value
Sex			
Male	17 (42.5)	19 (47.5)	>0.05
Female	23 (57.5)	21 (52.5)	
Age (years)	60.5±4.3	62.4±7.1	0.15
Course of disease (months)	39.5±9.2	43.5±13.2	0.12

Values are expressed as n (%) or mean ± standard deviation.

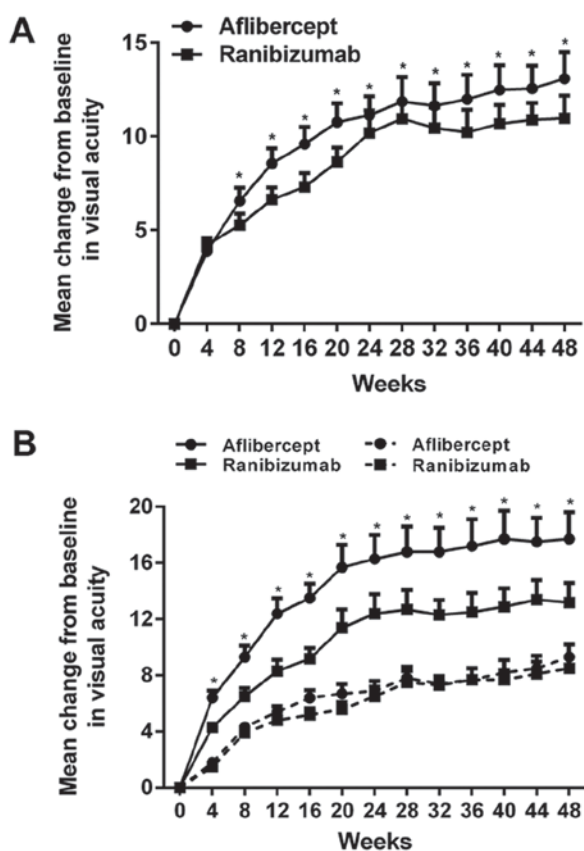


Figure 1. Mean changes of VAS from baseline over time. (A) Changes of VAS from baseline in the entire cohort. *P<0.05 vs. ranibizumab group. (B) Changes of VAS from baseline in patients stratified based on their initial VAS. Solid lines represent an initial VAS of <69, while dashed lines represent an initial VAS of ≥69. *P<0.05 vs. the patients with an initial VAS of <69 in the ranibizumab group. Values are expressed as the mean ± standard deviation. VAS, visual acuity letter score.

on the initial visual acuity. When the initial VAS was <69 (Snellen equivalent, 20/50), the mean improvement in VAS was 17.7 in the aflibercept group and 13.2 in the ranibizumab group (P<0.01; Table II), with a significant difference between the groups. When the initial VAS was ≥69, the mean improvement in VAS was 9.3 in the aflibercept group and 8.5 in the ranibizumab group, with no significant difference between the groups. As presented in Fig. 1B, the mean improvement of VAS after drug injection was higher when the initial VAS of the patients was <69 (Snellen equivalent, 20/50) compared with that in the subgroups with an initial

VAS of ≥69. In addition, when the initial VAS was <69 (18 eyes for those who were treated with aflibercept and 21 eyes for those who were treated with ranibizumab), the number of eyes with a VAS improvement of ≥15 was 61.1% (11/18) for patients who received aflibercept and 28.5% (6/21) for patients who received ranibizumab, and a significant difference was identified (P<0.05). Furthermore, the number of eyes with a VAS improvement of 10-15 was 27.8% (5/18) for patients who received aflibercept and 52.4% (11/21) for patients who received ranibizumab, and no significant difference was observed. When the initial VAS was ≥69 (22 eyes treated with aflibercept and 19 eyes treated with ranibizumab), the number of eyes with an improvement in the VAS by ≥15 was 31.8% (7/22) for patients using aflibercept and 21.1% (4/19) for patients using ranibizumab, and no significant difference was identified. Furthermore, the number of eyes with an improvement in the VAS by 10-15 was 59.1% (13/22) for those using aflibercept and 63.2% (12/19) for those using ranibizumab, and no significant difference was observed.

Effect of aflibercept or ranibizumab on CST. The mean CST decreased significantly within one year of treatment. In the aflibercept group, the CST was decreased by 140 μm and in the ranibizumab group by 134 μm. As presented in Fig. 2A, the decrease in CST in the aflibercept group was larger than that in the ranibizumab group. The reduction in CST was dependent on the initial VAS, as presented in Fig. 2B. When the initial VAS was <69, the mean decline was 171 μm in the aflibercept group and 154 μm in the ranibizumab group, and a significant difference was identified. When the initial VAS was ≥69, the decline in the CST was 113 μm in the aflibercept group and 112 μm in the ranibizumab group, with no significant inter-group difference (Table III). The mean decline in CST after drug injection was obvious when the initial VAS of the patients was <69 in comparison with that in the subgroup with an initial VAS of ≥69 (Fig. 2B). When the initial VAS was <69 (18 eyes in the aflibercept subgroup and 21 in the ranibizumab subgroup), the number of eyes with a CST of <250 μm after 1 year was 61.1% (11/18) for those treated with aflibercept and 38.1% (8/21) for those treated with ranibizumab. When the initial VAS was ≥69 (22 eyes in the aflibercept subgroup and 19 in the ranibizumab subgroup), the number of eyes with a CST of <250 μm after 1 year was 54.5% (12/22) for those treated with aflibercept and 42.1% (8/19) for those who received ranibizumab, and no significant difference was identified.

Table II. Changes in VAS in different groups.

A, <69			
VAS	Aflibercept (n=40)	Ranibizumab (n=40)	P-value
Eyes (n)	18	21	-
Mean improvement	17.7±5.2	13.2±4.9	0.009
Change VAS			
≥15	11 (61.1)	6 (28.5)	0.044
10-15	5 (27.8)	11 (52.4)	0.124
0±10	1 (5.5)	2 (9.5)	0.647
-(10-15)	1 (5.5)	1 (4.7)	0.355
-(≥15)	0 (0.0)	1 (4.7)	-
B, ≥69			
VAS	Aflibercept (n=40)	Ranibizumab (n=40)	P-value
Eyes (n)	22	19	-
Mean improvement	9.3±3.7	8.5±4.2	0.52
Change in VAS			
≥15	7 (31.8)	4 (21.1)	0.443
10-15	13 (59.1)	12 (63.2)	0.627
0±10	2 (9.1)	2 (10.5)	0.879
-(10-15)	0 (0.0)	1 (5.3)	0.282
-(≥15)	0 (0.0)	0 (0.0)	1.000

Values are expressed as n (%) or the mean ± standard deviation. VAS, visual acuity letter score.

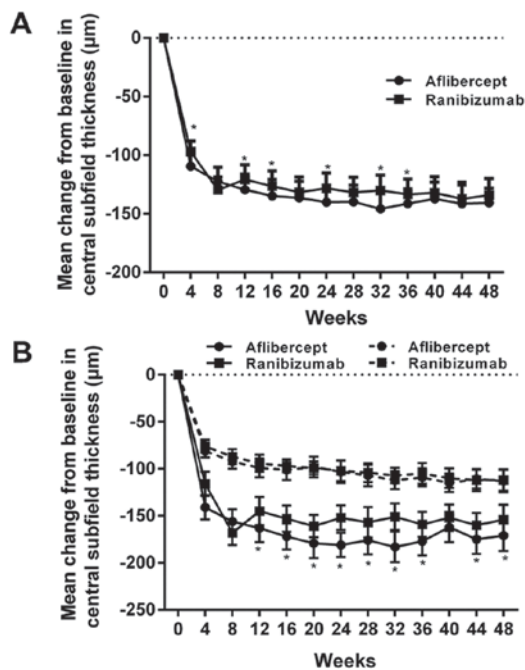


Figure 2. Mean changes of central subfield thickness from baseline over time. (A) Changes of central subfield thickness in the entire cohort. * $P < 0.05$ vs. ranibizumab group. (B) Changes of central subfield thickness from baseline in patients stratified based on their initial VAS. Solid lines represent an initial VAS of < 69 , while dashed lines represent an initial VAS of ≥ 69 . * $P < 0.05$ vs. patients with an initial VAS of < 69 in the ranibizumab group. Values are expressed as the mean \pm standard deviation. VAS, visual acuity letter score.

Safety evaluation. The occurrence of adverse events is listed in Table IV. No death or endophthalmitis induced by injection occurred during the study period. One case of inflammation other than endophthalmitis was encountered in each group treated with aflibercept or ranibizumab. The rate of patients with serious adverse events was identical (25%, 10 in 40 eyes) in the two treatment groups. The adverse events that occurred at higher rates, e.g., gastrointestinal (9 for aflibercept and 7 for ranibizumab) or renal events (6 for aflibercept and 5 for ranibizumab), were similar among the two treatment groups, and no significant difference was identified. The rates of vascular events (determined according to the Anti-platelet Trialists' Collaboration definition), including non-fatal myocardial infarction and non-fatal stroke were reported in a previous study (16), were similar between the two treatment groups, and no significant difference was identified.

Effects of aflibercept or ranibizumab on inflammatory factors in aqueous humor of patients with wet AMD. The concentrations of TGF- β 1, MCP-1 and IL-6 in aqueous humor samples from patients with wet AMD treated with aflibercept or ranibizumab were identified by using ELISA (Fig. 3). The mean concentrations of TGF- β 1, MCP-1 and IL-6 all decreased significantly in the two treatment groups over the 1-year period ($P < 0.05$; Fig. 3A1-C1). TGF- β 1 decreased by 62.7% in the aflibercept group and by 58.7% in the ranibizumab group. MCP-1 was decreased by 38.8%

Table III. CST changes in the different groups.

A, <69			
Visual acuity letter score	Aflibercept (n=40)	Ranibizumab (n=40)	P-value
Eyes (n)	18	21	
Mean change in CST from baseline (μm)	-171 \pm 48.5	-154 \pm 43.6	0.127
CST <250 μm at 1 year	11 (61.1)	8 (38.1)	0.152
B, \geq 69			
Visual acuity letter score	Aflibercept (n=40)	Ranibizumab (n=40)	P-value
Eyes (n)	22	19	
Mean change in CST from baseline (μm)	-113 \pm 32.7	-112 \pm 30.8	0.923
CST <250 μm at 1 year	12 (54.5%)	8 (38.1)	0.427

Values are expressed as n (%) or the mean \pm standard deviation. CST, central subfield thickness.

Table IV. Serious adverse events within 1 year of recruitment.

Events	Aflibercept (n=40)	Ranibizumab (n=40)	P-value
Endophthalmitis	0 (0.0)	0 (0.0)	-
Ocular inflammation	1 (2.5)	1 (2.5)	1.000
Retinal detachment or tear	0 (0.0)	1 (2.5)	0.314
Vitreous hemorrhage	1 (2.5)	2 (5.0)	0.556
Injection-associated cataract	1 (2.5)	1 (2.5)	1.000
Elevation of intraocular pressure	6 (15.0)	5 (12.5)	0.745
Non-fatal myocardial infarction	1 (2.5)	0 (0.0)	0.314
Non-fatal stroke	0 (0.0)	1 (2.5)	0.314
Death from any cause	0 (0.0)	0 (0.0)	-
Gastrointestinal events	9 (22.5)	7 (17.5)	0.576
Renal events	6 (15.0)	5 (12.5)	0.745
Hypertension	5 (12.5)	5 (12.5)	1.000

Values are expressed as n (%).

in the aflibercept group and by 36.4% in the ranibizumab group. Furthermore, IL-6 was decreased by 42.0% in the aflibercept group and by 38.1% in the ranibizumab group. The decline of TGF- β 1, MCP-1 and IL-6 levels after drug injection was more noticeable when the initial VAS of the patients was <69 compared with that in the subgroup with a VAS of \geq 69 (Fig. 3A2-C2).

A correlation analysis was then performed to determine the correlation between inflammatory factors and the mean change of VAS and CST in patients with wet AMD treated with aflibercept or ranibizumab. Negative correlations were identified between the levels of TGF- β 1, MCP-1 or IL-6 and the mean change of VAS if the initial VAS was <69 (Fig. 4A and B). Furthermore, a positive correlation between the levels of TGF- β 1, MCP-1 and IL-6 and the mean change of CST was observed when the initial VAS of the patients

was <69 (Fig. 4C and D). However, while the levels of TGF- β 1, MCP-1 and IL-6 were negatively correlated with the mean change of VAS when the initial VAS of the patients was \geq 69, the degree of the correlation was relatively low in comparison with that for the group of patients with an initial VAS of <69 (Fig. 5A and B). In addition, the levels of TGF- β 1, MCP-1 and IL-6 had no significant correlation with the mean change of CST when the initial VAS of the patients was \geq 69 (Fig. 5C and D).

Discussion

AMD, a retinal eye disease that affects aged individuals, is characterized by retrogression of RPE and the neural retina. The therapeutic strategies for wet AMD, including aflibercept or ranibizumab treatment (as recombinant humanized

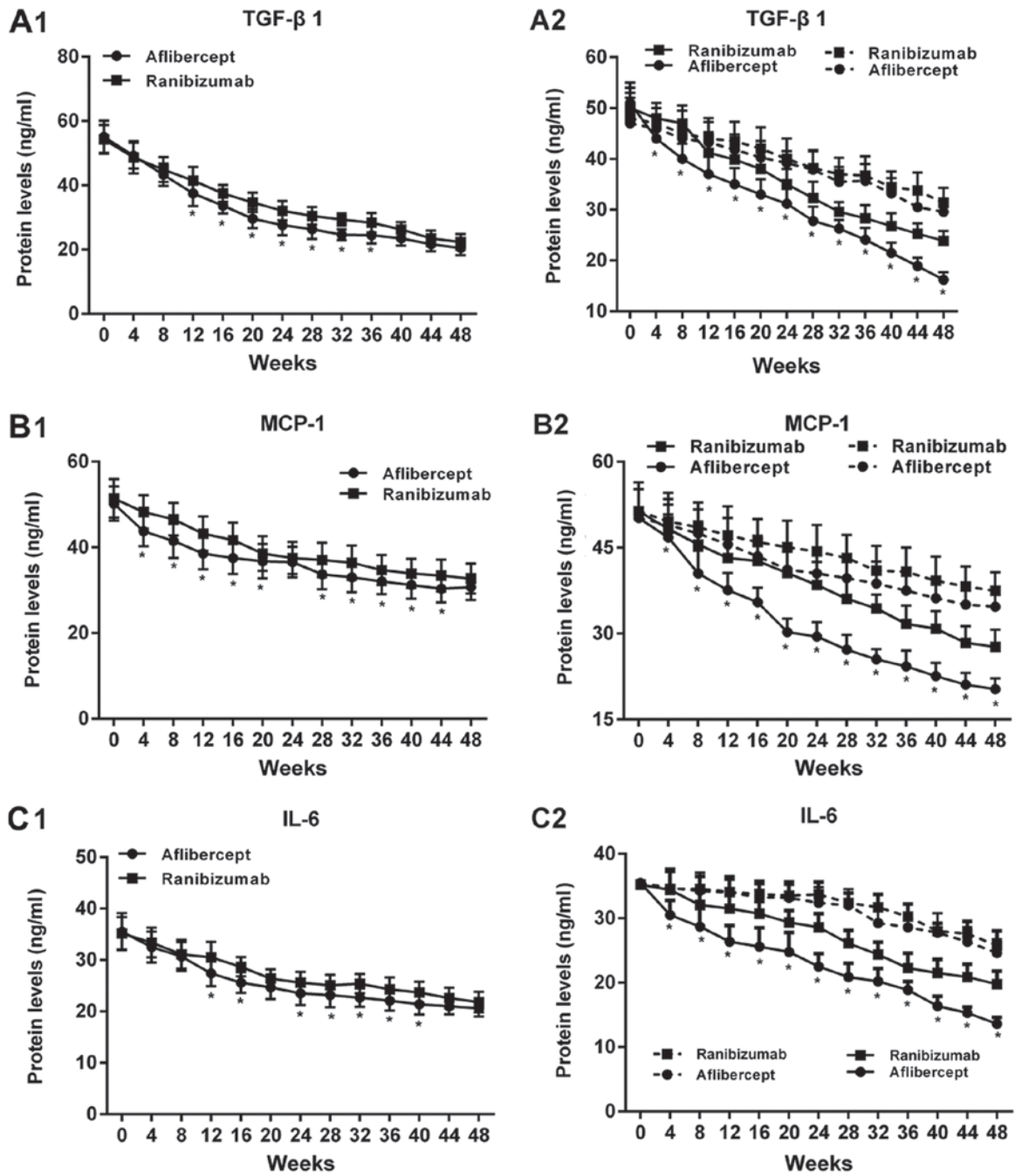


Figure 3. Effect of aflibercept and ranibizumab on the concentration of inflammatory factors, including (A) TGF-β1, (B) MCP-1 and (C) IL-6. (A1-C1) Effects in the entire cohort. *P<0.05 vs. ranibizumab group. (A2-C2) Effect in patients stratified based on their initial VAS. Solid lines represent an initial VAS of <69, while dashed lines represent an initial VAS of ≥69. *P<0.05 vs. patients with the initial VAS of <69 in the ranibizumab group. Values are expressed as the mean ± standard deviation. TGF, transforming growth factor; MCP, monocyte chemoattractant protein; IL, interleukin; VAS, visual acuity letter score.

monoclonal antibodies inhibiting VEGF), which is a major regulator of normal and pathological angiogenesis, are focusing on reversing neovascularization (17).

In the present study, the treatment effects of aflibercept and ranibizumab on 80 patients with wet AMD patients, as evaluated via the VAS and the CST, as well as the correlation between these effects and the decrease of inflammatory factors, were assessed. At baseline, the VAS and CST were equal among the groups. When the initial VAS was ≥69, the median injection number was 10 in each group. During the one-year treatment period, aflibercept was more effective in

treating wet AMD than ranibizumab based on the improvement in VAS and CST. When the initial VAS was <69, the effect of aflibercept on the improvement of VAS and the decrease of CST was more significant than that of ranibizumab. The visual acuity improvement was mostly in the scope of ≥15 letter scores in aflibercept-treated patients with wet AMD, while the improvement was mostly in the range of 10-15 letter scores in the ranibizumab group. While changes in VAS and CST were achieved by each of the two treatments, aflibercept was more effective than ranibizumab when the VAS at baseline was <69. By contrast, when the initial VAS

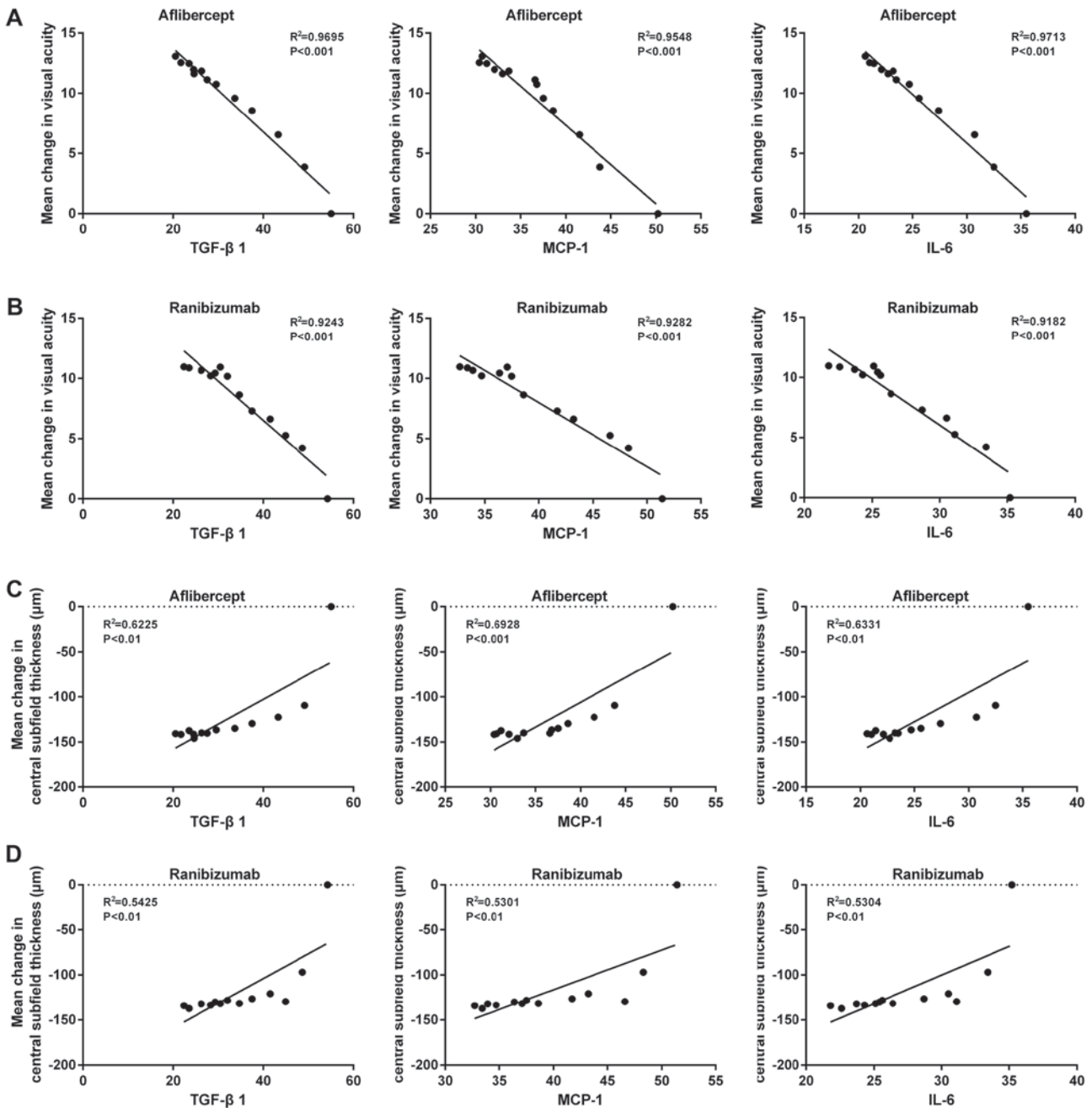


Figure 4. Correlation analysis of TGF-β1, MCP-1 and IL-6 levels with (A and B) visual acuity improvement in patients treated with (A) aflibercept and (B) ranibizumab and with (C and D) central subfield thickness in patients treated with (C) aflibercept and (D) ranibizumab with an initial visual acuity letter score of <69. TGF, transforming growth factor; MCP, monocyte chemoattractant protein; IL, interleukin.

was ≥69, no difference was identified between the effects of aflibercept and ranibizumab on VAS and CST. However, the average changes in VAS and CST were not significantly different between the aflibercept and ranibizumab treatment groups. Hence, in patients with a VAS of <69, aflibercept should be prescribed.

The safety of the two drugs aflibercept and ranibizumab was monitored during the present clinical study. Apart from the common medical history inquiry, blood routine examination was performed in the present study in order to exclude recent infections and the possibility that general infection affects the results. Mortalities and endophthalmitis did not occur in the present study. The incidence of adverse events, including

serious adverse events, e.g., gastrointestinal, renal or vascular events, was similar between the aflibercept and ranibizumab groups. It may be concluded that aflibercept and ranibizumab are safe and effective reagents for improving VAS and decreasing CST in patients with wet AMD. When the initial VAS was low (<96), the effect of aflibercept on improving the VAS was slightly better than that of ranibizumab. By contrast, when the initial VAS was high (≥96), the effect of aflibercept and ranibizumab was similar.

Previous studies have indicated that complement cascades and immunological mechanisms mediating inflammatory reactions are critical elements in the initiation and development of wet AMD (18,19). Wet AMD is a type of continuous

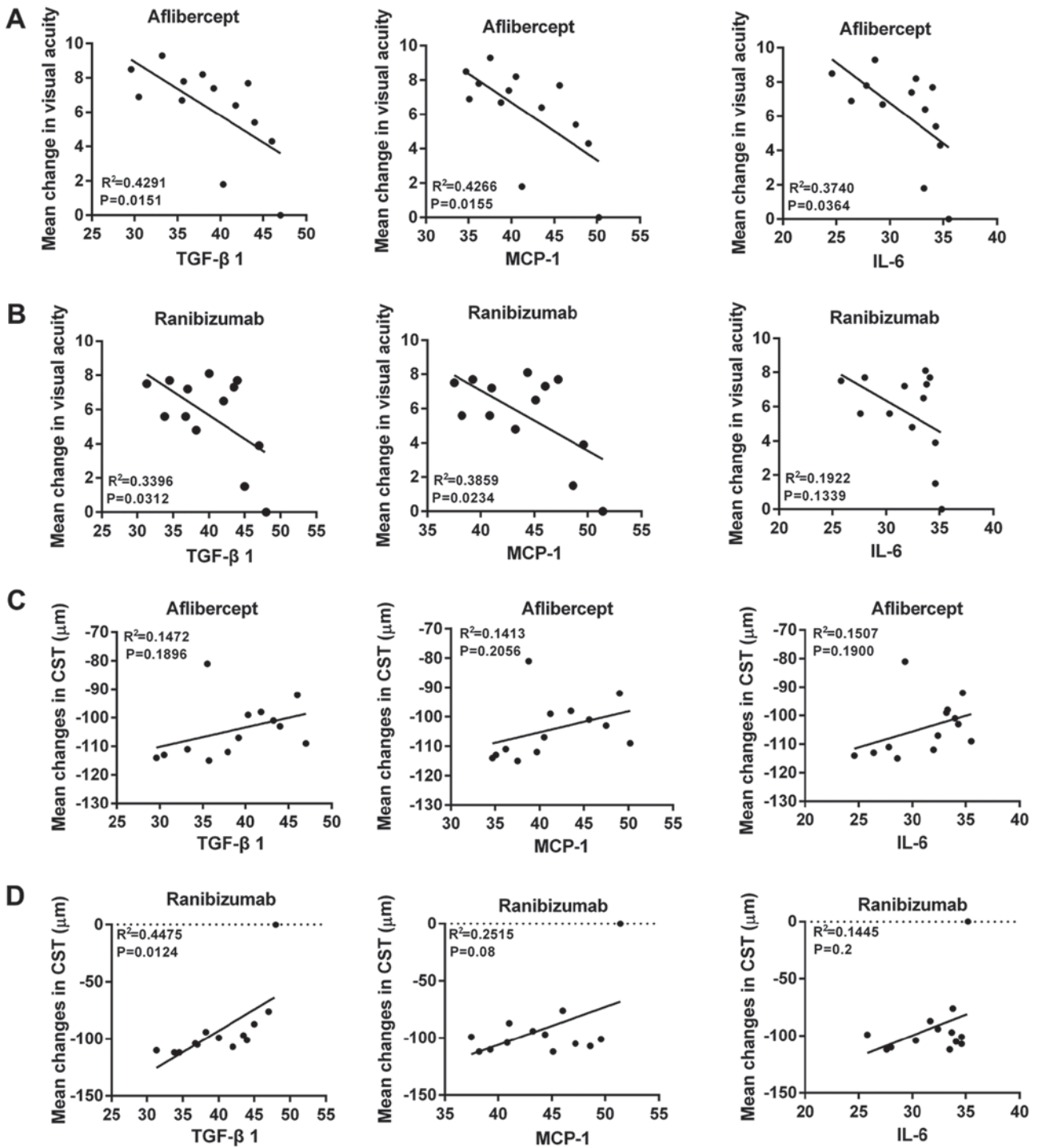


Figure 5. Correlation analysis of TGF-β1, MCP-1 and IL-6 levels with (A and B) visual acuity improvement in patients treated with (A) aflibercept and (B) ranibizumab and with (C and D) central subfield thickness in patients treated with (C) aflibercept and (D) ranibizumab with an initial visual acuity letter score of ≥ 69 . TGF, transforming growth factor; MCP, monocyte chemoattractant protein; IL, interleukin.

low chronic inflammatory disease, in which the blood-retinal barrier breakdown and release of inflammatory factors are induced by regional tissue damage (20). To further elucidate the mechanisms by which aflibercept and ranibizumab restore eyesight in patients with wet AMD, particularly in terms of changes of inflammatory factors, the present study determined the concentrations of characteristic inflammatory cytokines.

The pathophysiology of AMD involves systemic and ocular inflammation (21). Aflibercept and ranibizumab are

recombinant humanized monoclonal antibodies that inactivate VEGF (22). VEGF is a potent angiogenic factor, the overexpression of which is known to deteriorate AMD (23). TGF-β1, a critical regulator in various physiological and pathological processes, stimulates endothelial cells to synthesize as well as secrete VEGF. CNV is the imbalance of angiogenic and anti-angiogenic factors within/among the choroid, RPE and retina. TGF-β1 induces VEGF secretion in choroid cells, and it may have a key role in CNV development

in AMD (24). Secreted by mononuclear cells, macrophages, lymphocytes and endothelial cells, MCP-1 is an important inflammatory factor that induces mononuclear cell migration and differentiation to macrophages in tissues (25). VEGF may cause increases in the mRNA expression of MCP-1, which in turn participates in the development and infiltration of neovasculature. MCP-1 is known as a key factor to promote neovascular development, and it has important roles in regulating the migration and infiltration of mononuclear cells. The levels of MCP-1 in wet AMD are dependent on the degree of macular edema (26). IL-6 is a multifunctional cytokine secreted by mononuclear cells, macrophages and lymphocytes, and it is a major inflammation-inducing factor in infection or the acute-phase response to injury. IL-6 is able to activate the production of antibodies, promote the generation of fibrinogens, and induce the expression of proteins as well as the accumulation of T lymphocytes in the acute phase of inflammation (27). Hence, IL-6 may induce disorders of immune mechanisms and the autoimmune response. Furthermore, IL-6 may stimulate transformation factor 3 and promote CNV generation (28). The present study indicated that the expression levels of TGF- β 1, MCP-1 and IL-6 decreased significantly during one year of treatment with aflibercept or with ranibizumab ($P < 0.05$). No significant difference between the 2 groups was identified. A correlation analysis for inflammatory factors (TGF- β 1, MCP-1 or IL-6) and the improvement of VAS or the decrease of CST was performed. The results revealed a negative correlation between the levels of the inflammatory factors and the effect of aflibercept or ranibizumab treatment when the initial VAS of the patients was < 69 , suggesting that the relative treatment effect on AMD varied depending on the initial VAS. If the initial VAS was ≥ 69 , there was no difference, and it may be recommended that, if the initial VAS is < 69 , aflibercept should be prescribed. In addition, this correlation was higher in the aflibercept group than that in the ranibizumab group. This suggested that aflibercept and ranibizumab alleviate wet AMD by inhibiting inflammatory factors, including TGF- β 1, MCP-1 and IL-6, to improve the VAS and decrease the CST. The mechanism behind the actions of aflibercept and ranibizumab may need further corroborative studies. Taken together, the increase in VAS, reduction of CST and inhibition of inflammatory factors were more noticeable in the aflibercept treatment group than those in the ranibizumab treatment group. Therefore, the inhibition of inflammation may be a secondary effect of the treatment effect produced by aflibercept and ranibizumab, the primary effect should be assessed in future studies.

In addition, in the previous SCORE2 trial, the effect of bevacizumab and aflibercept in treating macula edema was compared (29). After 6 months of treatment, it was indicated that intravitreal bevacizumab was not inferior to aflibercept with regard to its ability to improve the VAS. However, the present study compared the effect of aflibercept and ranibizumab and in addition, the association between pro-inflammatory cytokines, and the VAS and CST of patients with AMD was assessed. The results indicated that the treatment effect on AMD of aflibercept was better than that of ranibizumab. Taken together, the present study may provide references for deciding on the treatment strategy for AMD.

In conclusion, the present study suggested that aflibercept and ranibizumab improved the VAS and decreased the CST of patients with wet AMD. The drug treatment outcome was dependent on the patients' initial VAS. Aflibercept was only better than that of ranibizumab if the initial VAS was < 69 , while the effect was similar for VAS ≥ 69 . Therefore, the initial VAS can be used to guide the treatment decision between aflibercept and ranibizumab, which appears to be a novel finding of the current study. Aflibercept and ranibizumab alleviated wet AMD by inhibiting the expression of TGF- β 1, MCP-1 and IL-6. The inhibition of inflammation may be a secondary effect produced by aflibercept and ranibizumab, the primary effect should be assessed in future studies. Thus, the present study provides evidence for the effect of aflibercept and ranibizumab in treating wet AMD.

Acknowledgements

Not applicable.

Funding

The present study was funded by the General Plan of Medical and Health Research of the Health and Family Planning Commission of Zhejiang Province (grant no. 2013 KYA186).

Availability of data and materials

All data generated or analyzed during this study are included in this published article.

Authors' contributions

JY designed the study, collected and analyzed the data, and wrote the manuscript.

Ethical approval and consent to participate

Informed consent was obtained from each patient prior to enrolment. The present study (Chinese Clinical Trial Registry no. 1800017782) was approved by the ethics committee of Ningbo No. 6 Hospital (Ningbo, China).

Patient consent for publication

Not applicable.

Competing interests

The authors declare that they have no competing interests.

References

1. Neely DC, Bray KJ, Huisinigh CE, Clark ME, McGwin G Jr and Owsley C: Prevalence of undiagnosed age-related macular degeneration in primary eye care. *JAMA Ophthalmol* 135: 570-575, 2017.
2. Bastawrous A, Mathenge W, Peto T, Shah N, Wing K, Rono H, Weiss HA, Macleod D, Foster A, Burton M and Kuper H: Six-year incidence and progression of age-related macular degeneration in Kenya: Nakuru eye disease cohort study. *JAMA Ophthalmol* 135: 631-638, 2017.

3. Tang Z, Zhang Y, Wang Y, Zhang D, Shen B, Luo M and Gu P: Progress of stem/progenitor cell-based therapy for retinal degeneration. *J Transl Med* 15: 99, 2017.
4. Ho AC, Chang TS, Samuel M, Williamson P, Willenbacher RF and Malone T: Experience with a subretinal cell-based therapy in patients with geographic atrophy secondary to age-related macular degeneration. *Am J Ophthalmol* 179: 67-80, 2017.
5. Chen Y, Wiesmann C, Fuh G, Li B, Christinger HW, McKay P, de Vos AM and Lowman HB: Selection and analysis of an optimized anti-VEGF antibody: Crystal structure of an affinity-matured Fab in complex with antigen. *J Mol Biol* 293: 865-881, 1999.
6. Miyamoto N, Mandai M, Kojima H, Kameda T, Shimozono M, Nishida A and Kurimoto Y: Response of eyes with age-related macular degeneration to anti-VEGF drugs and implications for therapy planning. *Clin Ophthalmol* 11: 809-816, 2017.
7. Sun Y, Lin Z, Liu CH, Gong Y, Liegl R, Fredrick TW, Meng SS, Burnim SB, Wang Z, Akula JD, *et al*: Inflammatory signals from photoreceptor modulate pathological retinal angiogenesis via c-Fos. *J Exp Med* 214: 1753-1767, 2017.
8. de Oliveira Dias JR, Costa de Andrade G, Kniggendorf VF, Novais EA, Takahashi VKL, Maia A, Meyer C, Watanabe SES, Farah ME and Rodrigues EB: Intravitreal Ziv-Aflibercept for neovascular age-related macular degeneration: 52-week results. *Retina*: Dec 11, 2017 (Epub ahead of print).
9. Reich O, Schmid MK, Rapold R, Bachmann LM and Blozik E: Injections frequency and health care costs in patients treated with aflibercept compared to ranibizumab: New real-life evidence from Switzerland. *BMC Ophthalmol* 17: 234, 2017.
10. Wilke RGH, Finger RP and Sachs HG: Time course of changes in visual acuity after a single injection of aflibercept or ranibizumab in neovascular age-related macular degeneration-analysis of aggregated real life data. *Klin Monbl Augenheilkd* 234: 1508-1514, 2017 (In German).
11. Wu KH, Tan AG, Rochtchina E, Favaloro EJ, Williams A, Mitchell P and Wang JJ: Circulating inflammatory markers and homeostatic factors in age-related maculopathy: A population-based case-control study. *Invest Ophthalmol Vis Sci* 48: 1983-1988, 2007.
12. Kuse Y, Tsuruma K, Kanno Y, Shimazawa M and Hara H: CCR3 is associated with the death of a photoreceptor cell-line induced by light exposure. *Front Pharmacol* 8: 207, 2017.
13. Klein R, Klein BE, Knudtson MD, Wong TY, Shankar A and Tsai MY: Systemic markers of inflammation, endothelial dysfunction, and age-related maculopathy. *Am J Ophthalmol* 140: 35-44, 2005.
14. Fouda SM and Bahgat AM: Intravitreal aflibercept versus intravitreal ranibizumab for the treatment of diabetic macular edema. *Clin Ophthalmol* 11: 567-571, 2017.
15. Beck RW, Moke PS, Turpin AH, Ferris FL III, SanGiovanni JP, Johnson CA, Birch EE, Chandler DL, Cox TA, Blair RC and Kraker RT: A computerized method of visual acuity testing: Adaptation of the early treatment of diabetic retinopathy study testing protocol. *Am J Ophthalmol* 135: 194-205, 2003.
16. Wells JA, Glassman AR, Ayala AR, Jampol LM, Bressler NM, Bressler SB, Brucker AJ, Ferris FL, Hampton GR, Jhaveri C, *et al*: Aflibercept, bevacizumab, or ranibizumab for diabetic macular edema: Two-year results from a comparative effectiveness randomized clinical trial. *Ophthalmology* 123: 1351-1359, 2016.
17. van der Giet M, Henkel C, Schuchardt M and Tolle M: Anti-VEGF drugs in eye diseases: Local therapy with potential systemic effects. *Curr Pharm Des* 21: 3548-3556, 2015.
18. Anderson DH, Mullins RF, Hageman GS and Johnson LV: A role for local inflammation in the formation of drusen in the aging eye. *Am J Ophthalmol* 134: 411-431, 2002.
19. Lin T, Walker GB, Kurji K, Fang E, Law G, Prasad SS, Kojic L, Cao S, White V, Cui JZ and Matsubara JA: Parainflammation associated with advanced glycation endproduct stimulation of RPE in vitro: Implications for age-related degenerative diseases of the eye. *Cytokine* 62: 369-381, 2013.
20. Xu H, Chen M and Forrester JV: Para-inflammation in the aging retina. *Prog Retin Eye Res* 28: 348-368, 2009.
21. Sato T, Takeuchi M, Karasawa Y, Enoki T and Ito M: Intraocular inflammatory cytokines in patients with neovascular age-related macular degeneration before and after initiation of intravitreal injection of anti-VEGF inhibitor. *Sci Rep* 8: 1098, 2018.
22. Demirel S, Bilici S, Batioglu F and Ozmert E: Is there any difference between ranibizumab and aflibercept injections in terms of inflammation measured with anterior chamber flare levels in age-related macular degeneration patients: A comparative study. *Ophthalmic Res* 56: 35-40, 2016.
23. Tosi GM, Caldi E, Neri G, Nuti E, Marigliani D, Baiocchi S, Traversi C, Cevenini G, Tarantello A, Fusco F, *et al*: HTRA1 and TGF- β 1 concentrations in the aqueous humor of patients with neovascular age-related macular degeneration. *Invest Ophthalmol Vis Sci* 58: 162-167, 2017.
24. Fisichella V, Giurdanella G, Platania CB, Romano GL, Leggio GM, Salomone S, Drago F, Caraci F and Bucolo C: TGF- β 1 prevents rat retinal insult induced by amyloid- β (1-42) oligomers. *Eur J Pharmacol* 787: 72-77, 2016.
25. Kramer M, Hasanreisoglu M, Feldman A, Axer-Siegel R, Sonis P, Maharshak I, Monselise Y, Gurevich M and Weinberger D: Monocyte chemoattractant protein-1 in the aqueous humour of patients with age-related macular degeneration. *Clin Exp Ophthalmol* 40: 617-625, 2012.
26. Jonas JB, Tao Y, Neumaier M and Findeisen P: Monocyte chemoattractant protein 1, intercellular adhesion molecule 1, and vascular cell adhesion molecule 1 in exudative age-related macular degeneration. *Arch Ophthalmol* 128: 1281-1286, 2010.
27. Stewart MW: Clinical and differential utility of VEGF inhibitors in wet age-related macular degeneration: Focus on aflibercept. *Clin Ophthalmol* 6: 1175-1186, 2012.
28. Lazzeri S, Orlandi P, Piaggi P, Sartini MS, Casini G, Guidi G, Figus M, Fioravanti A, Di Desidero T, Ripandelli G, *et al*: IL-8 and VEGFR-2 polymorphisms modulate long-term functional response to intravitreal ranibizumab in exudative age-related macular degeneration. *Pharmacogenomics* 17: 35-39, 2016.
29. Scott IU, Vanvelthuisen PC, Ip MS, Blodi BA, Oden NL, Awh CC, Kunimoto DY, Marcus DM, Wroblewski JJ and King J; SCORE2 Investigator Group: Effect of bevacizumab vs. aflibercept on visual acuity among patients with macular edema due to central retinal vein occlusion: The SCORE2 randomized clinical trial. *JAMA* 317: 2072-2087, 2017.