

Retrospective Study

Efficacy and complications of argon plasma coagulation for hemorrhagic chronic radiation proctitis

Qing-Hua Zhong, Zhan-Zhen Liu, Zi-Xu Yuan, Teng-Hui Ma, Xiao-Yan Huang, Huai-Ming Wang, Dai-Ci Chen, Jian-Ping Wang, Lei Wang

ORCID number: Qing-Hua Zhong (0000-0001-6199-5599); Zhan-Zhen Liu (0000-0003-3647-6329); Zi-Xu Yuan (0000-0001-8249-3352); Teng-Hui Ma (0000-0003-4547-865X); Xiao-Yan Huang (0000-0002-5450-1500); Huai-Ming Wang (0000-0002-1976-3396); Dai-Ci Chen (0000-0002-8872-0592); Jian-Ping Wang (0000-0002-5596-7070); Lei Wang (0000-0003-3724-7392).

Author contributions: Zhong QH designed the study, collected and analyzed the data, and drafted the manuscript; Liu ZZ helped in collecting and analyzing the data; Yuan ZZ helped in collecting the data and drafting the manuscript; Ma TH helped in analyzing the data; Huang XY helped in collecting and analyzing the data; Wang HM helped in drafting the manuscript; Chen DC helped in designing the study and analyzing the data; Wang JP helped in designing the study and supervised the study; Wang L designed and supervised the study and revised the manuscript.

Supported by National Natural Science Foundation of China, No. 81573078; and the National Natural Science Foundation of Guangdong Province, No. 2016A030311021.

Institutional review board

statement: This study was approved by the Ethics Committee of the Sixth Affiliated Hospital of Sun Yat-sen University.

Informed consent statement:

Informed consent for this study was waived due to its retrospective

Qing-Hua Zhong, Zhan-Zhen Liu, Zi-Xu Yuan, Teng-Hui Ma, Xiao-Yan Huang, Huai-Ming Wang, Dai-Ci Chen, Jian-Ping Wang, Lei Wang, Guangdong Provincial Key Laboratory of Colorectal and Pelvic Floor Diseases, Sun Yat-sen University, Guangzhou 510655, Guangdong Province, China

Qing-Hua Zhong, Zhan-Zhen Liu, Zi-Xu Yuan, Teng-Hui Ma, Huai-Ming Wang, Jian-Ping Wang, Lei Wang, Department of Colorectal Surgery, the Sixth Affiliated Hospital, Sun Yat-sen University, Guangzhou 510655, Guangdong Province, China

Xiao-Yan Huang, Dai-Ci Chen, Jian-Ping Wang, Lei Wang, Guangdong Institute of Gastroenterology, Guangzhou 510655, Guangdong Province, China

Corresponding author: Lei Wang, MD, PhD, Chief Doctor, Professor, Department of Colorectal Surgery, the Sixth Affiliated Hospital of Sun Yat-sen University, 26 Yuancunheng Road, Guangzhou 510655, Guangdong Province, China.

wangl9@mail.sysu.edu.cn

Telephone: +86-20-38254052

Fax: +86-20-38254159

Abstract**BACKGROUND**

Chronic radiation proctitis (CRP) is a complication which occurs in 1%-5% of patients who undergo radiotherapy for pelvic malignancies. Although a wide range of therapeutic modalities are available, there is no literature to date showing any particularly appropriate therapeutic modality for each disease stage. Argon plasma coagulation (APC) is currently recommended as the first-choice treatment for hemorrhagic CRP, however, its indication based on long-term follow-up is still unclear. On the hypothesis that the long-term efficacy and safety of APC are not fully understood, we reviewed APC treatment for patients with hemorrhagic CRP from a single center.

AIM

To assess the long-term efficacy and safety of APC for hemorrhagic CRP.

METHODS

This is a retrospective study of consecutive patients treated with APC for hemorrhagic CRP from January 2013 to October 2017. Demographics, clinical variables, and typical endoscopic features were recorded independently. Success was defined as either cessation of bleeding or only occasional traces of bloody

nature. Patients agreed to undergo treatment by written consent.

Conflict-of-interest statement: All authors declare no conflicts of interest related to this article.

Data sharing statement: No additional data are available.

Open-Access: This article is an open-access article which was selected by an in-house editor and fully peer-reviewed by external reviewers. It is distributed in accordance with the Creative Commons Attribution Non Commercial (CC BY-NC 4.0) license, which permits others to distribute, remix, adapt, build upon this work non-commercially, and license their derivative works on different terms, provided the original work is properly cited and the use is non-commercial. See: <http://creativecommons.org/licenses/by-nc/4.0/>

Manuscript source: Unsolicited manuscript

Received: January 28, 2019

Peer-review started: January 28, 2019

First decision: February 13, 2019

Revised: February 20, 2019

Accepted: February 22, 2019

Article in press: February 23, 2019

Published online: April 7, 2019

P-Reviewer: Barret M, Souza JL

S-Editor: Ma RY

L-Editor: Wang TQ

E-Editor: Ma YJ



stools with no further treatments for at least 12 mo after the last APC treatment. We performed univariate and multivariate analyses to identify factors associated with success and risk factors for fistulas.

RESULTS

Forty-five patients with a median follow-up period of 24 mo (range: 12-67 mo) were enrolled. Fifteen (33.3%) patients required blood transfusion before APC. Successful treatment with APC was achieved in 31 (68.9%) patients. The mean number of APC sessions was 1.3 (1-3). Multivariate analysis showed that APC failure was independently associated with telangiectasias present on more than 50% of the surface area [odds ratio (OR) = 6.53, 95% confidence interval (CI): 1.09-39.19, $P = 0.04$] and ulcerated area greater than 1 cm² (OR = 8.15, 95%CI: 1.63-40.88, $P = 0.01$). Six (13.3%) patients had severe complications involving rectal fistulation. The only factor significantly associated with severe complications was ulcerated area greater than 1 cm² ($P = 0.035$).

CONCLUSION

The long-term efficacy of APC for hemorrhagic CRP is uncertain in patients with telangiectasias present on > 50% of the surface area and ulceration > 1 cm².

Key words: Argon plasma coagulation; Chronic radiation proctitis; Radiation proctopathy; Efficacy; Safety

©The Author(s) 2019. Published by Baishideng Publishing Group Inc. All rights reserved.

Core tip: Argon plasma coagulation (APC) is currently recommended as the first-choice treatment for hemorrhagic chronic radiation proctitis, however, its indication based on long-term follow-up is still unclear. The purpose of this study was to review APC's long-term efficacy and safety. Forty-five patients with a median follow-up period of 24 mo were enrolled. Successful treatment was achieved in 31 (68.9%) patients. APC failure was independently associated with telangiectasias present on > 50% of the surface area and ulceration > 1 cm². Six (13.3%) patients experienced severe complications involving rectal fistulation. The only factor significantly associated with severe complications was ulceration > 1 cm².

Citation: Zhong QH, Liu ZZ, Yuan ZX, Ma TH, Huang XY, Wang HM, Chen DC, Wang JP, Wang L. Efficacy and complications of argon plasma coagulation for hemorrhagic chronic radiation proctitis. *World J Gastroenterol* 2019; 25(13): 1618-1627

URL: <https://www.wjgnet.com/1007-9327/full/v25/i13/1618.htm>

DOI: <https://dx.doi.org/10.3748/wjg.v25.i13.1618>

INTRODUCTION

Chronic radiation proctitis (CRP) is a complication that occurs in 1%-5% of patients who undergo radiotherapy for pelvic malignancies^[1]. Hemorrhagic CRP is a syndrome characterized by rectal bleeding, tenesmus, mucus discharge, and fecal incontinence^[1,2]. It persists beyond three months after the completion of radiotherapy or begins three months after the initiation of radiotherapy^[3]. The underlying pathological mechanisms of CRP are endarteritis obliterans and submucosal fibrosis, which lead to ischemia^[4]. Telangiectasias, typical endoscopic findings of hemorrhagic CRP, are considered to be a compensatory mechanism for ischemia^[5]. However, these superficial vascular lesions may bleed occasionally or even cause severe rectal bleeding requiring transfusion^[6].

Current treatment modalities for hemorrhagic CRP include three main categories: medical, interventional, and surgical. Medical treatments mainly include formalin application^[7,8] and sucralfate retention enemas^[9,10]. Interventional treatments mainly include endoscopic argon plasma coagulation (APC)^[11,12] and hyperbaric oxygen therapy^[13,14]. Nonsurgical therapy is preferable to surgical treatment, as the latter may cause high morbidity or mortality^[15]. Surgery should be reserved for refractory bleeding or cases complicated by fistulas, abscesses, or strictures. Although a wide range of therapeutic modalities are available, there is no literature to date showing

any particularly appropriate therapeutic modality for each disease stage. APC is currently recommended as the first-choice treatment for hemorrhagic CRP, due to its coagulation depth control, easy accessibility, relatively high effectiveness, and low cost^[16,17]. However, the indication of APC for hemorrhagic CRP is still unclear. The purpose of our study was to review the long-term efficacy and safety of APC for hemorrhagic CRP, and to evaluate the prognostic and risk factors.

MATERIALS AND METHODS

Patients

We retrospectively reviewed consecutive patients with hemorrhagic CRP treated with APC between January 2013 and October 2017 at the Sixth Affiliated Hospital of Sun Yat-sen University. The indications for APC were persistent rectal bleeding despite several treatment attempts with various topical agents including sucralfate, almagate, corticosteroids, and 5-aminosalicylic acid enemas. The exclusion criteria for the present study included the following: (1) patients had received treatments other than medical therapy prior to APC, such as APC, formalin irrigation, fecal diversion, and proctectomy; (2) primary tumor residue/relapse or large bowel cancer occurring during follow-up; and (3) patients had causes of rectal bleeding other than CRP. Patients agreed to undergo treatment by written consent. Informed consent for this study was waived due to its retrospective nature, and the study was approved by the Institutional Review Board of the Sixth Affiliated Hospital of Sun Yat-sen University.

APC technique

Patients maintained a clear fluid diet for 24 h before the APC procedure and underwent standard bowel preparation with 2-L polyethylene glycol. Preparation with enemas was performed in a few patients: 8.9% (4/45) for the first APC procedure and 29.4% (5/17) for the latter procedures. Patients received sedation with individual doses of midazolam, pethidine, or propofol if required. A total large bowel evaluation was not essential for patients who had received a complete evaluation previously or who could not tolerate a complete colonoscopy. A front-firing APC probe with a diameter of 2.3 mm was inserted through the working channel of a therapeutic colonoscope (PCF-Q260J, Olympus). If blood or other contaminating material was present, a volume of water was used to rinse the mucosal surface of the affected colorectum to prepare the surface for APC application. An argon flow of 1.0-3.0 L/min at a power of 40-60 W was applied to the lesions in 1-2 s pulses by the endoscopist, while an argon flow of 1.8 L/min at a power of 50 W was routinely adopted. The endoscopist aimed to ablate all the visible telangiectasia that might require multiple endoscopic procedures. During the APC procedure, adequate endoscopic aspiration was required to avoid overdistension with argon gas. Patients received a low or no residue diet for at least one week after the APC procedure. Repeat procedures, if necessary, were often performed at intervals of 3-4 wk.

Definition and follow-up

Follow-up was scheduled through outpatient clinic or by telephone at 6 and 12 mo after the procedure and thereafter at 12-mo intervals. Patients were advised to contact our departments in the event of recurrence of hemorrhage or anemia. Medical records were reviewed retrospectively. Endoscopic severity of CRP was derived from the highly-detailed endoscopic images in combination with the description on the endoscopic reports. CRP was endoscopically characterized according to the system advocated by Zinicola *et al*^[18]. In addition, ulceration was an important feature according to the Vienna grading system^[19]. Four factors were recorded independently: telangiectasia distribution, the surface area involved, the presence of fresh blood and ulceration (Figure 1).

Success was defined either as cessation of bleeding or only occasional traces of bloody stools with no further treatment for at least 12 mo after the last APC treatment^[20].

Statistical analysis

Categorical variables were compared using the χ^2 test or Fisher's exact test. A two-sided *P*-value < 0.05 was considered significant. We performed univariate and multivariate analyses to identify factors associated with success and risk factors for fistulas. Multivariate models were developed using the enter stepwise method with a removal cutoff of *P* = 0.10. All statistical analyses were performed with SPSS version 20 (SPSS, Inc., Chicago, IL, United States).

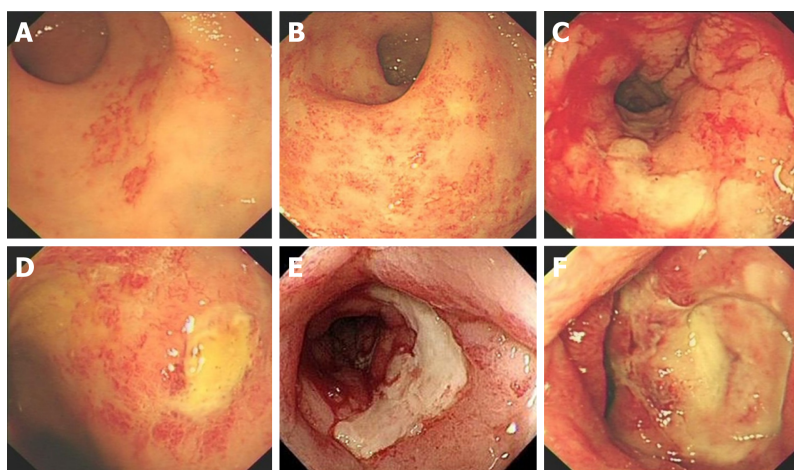


Figure 1 Endoscopic characteristics of hemorrhagic chronic radiation proctitis. A: Telangiectasias present on less than 50% of the surface area; B: Telangiectasias present on more than 50% of the surface area; C: Presence of fresh blood; D: Ulceration < 1 cm²; E and F: Ulceration > 1 cm².

RESULTS

Demographics

Between January 2013 and October 2017, 52 consecutive patients had not received treatments other than medical therapy before undergoing APC treatment for hemorrhagic CRP. After exclusion, a cohort of 45 patients were enrolled in this study. Reasons for exclusion were: (1) the patient was lost to follow-up ($n = 6$), and (2) the patient had a tumor relapse ($n = 1$). Approximately 88.9% of patients were treated with radiotherapy for gynecological malignancies, including cervical ($n = 39$) and vaginal ($n = 1$) cancers. The remaining five patients had prostate cancer. The median age at the time of the first APC treatment was 60 years (range: 43-88 years). The median duration between cessation of radiotherapy and onset of radiation proctitis was 8 mo (range: 0-78 mo). The median follow-up time from the most recent APC procedure was 24 mo (range: 12-67 mo). The median hemoglobin level at the time of first APC treatment was 10.1 g/dL (2.8-13.1 g/dL), and 15 (33.3%) patients required blood transfusion.

Efficacy of APC

At the time of first APC treatment, 14 (31.1%) patients had extensive telangiectasia distributed more than 10 cm from the anal verge, 26 (57.8%) had more than 50% of the surface area covered by telangiectasias, 29 (64.4%) had fresh blood in the lumen, and 12 (26.7%) had ulceration greater than 1 cm² (Table 1).

Successful treatment with APC was achieved in 31 (68.9%) patients. The mean number of APC sessions was 1.3 (1-3). Bleeding was not successfully controlled by APC treatment in the remaining 14 (31.1%) patients. The univariate analysis of clinical and endoscopic variables showed statistically significant associations between APC failure and telangiectasias present on more than 50% of the surface area ($P = 0.011$) and ulceration greater than 1 cm² ($P = 0.006$). Further multivariate analysis showed that APC failure was independently associated with telangiectasias present on more than 50% of the surface area [odds ratio (OR) = 6.53, 95% confidence interval (CI): 1.09-39.19, $P = 0.04$] and ulceration greater than 1 cm² (OR = 8.15, 95% CI: 1.63-40.88, $P = 0.01$).

For all 14 patients for whom APC was unsuccessful, bleeding was successfully controlled after fecal diversion.

Complications

Six (13.3%) patients had severe complications involving rectal fistula formation (including rectovaginal fistula and rectourethral fistula) at 1, 1, 2, 4, 9, and 9 mo after the first treatment session. They were treated with surgical interventions, including fecal diversion ($n = 5$) and restorative resection with pull-through coloanal anastomosis ($n = 1$). In the univariate analysis, the only factor significantly associated with severe complications was ulceration greater than 1 cm² ($P = 0.035$) (Table 2).

Table 1 Univariate analysis of factors associated with argon plasma coagulation treatment failure for hemorrhagic chronic radiation proctitis.

Variable	No. of failure/total patients	P-value
Distribution of telangiectasias		
Distal rectum (within 10 cm from anal verge)	7/31	0.136 ¹
Entire rectum +/- sigmoid (more than 10 cm from anal verge)	7/14	
Surface area covered by telangiectasias		
Less than 50%	2/19	0.011 ²
More than 50%	12/26	
Presence of fresh blood		
No	3/16	0.320 ¹
Yes	11/29	
Ulceration		
< 1 cm ²	6/33	0.006 ¹
> 1 cm ²	8/12	
Gender		
Female	14/40	0.305 ³
Male	0/5	
Hypertensive		
No	11/39	0.356 ³
Yes	3/6	
Diabetic		
No	11/40	0.166 ³
Yes	3/5	
Abdominal surgery		
No	11/33	0.865 ¹
Yes	3/12	
Acute radiation injury		
No	14/39	0.156 ³
Yes	0/6	
Requiring blood transfusions		
No	7/30	0.210 ¹
Yes	7/15	
Number of APC		
1	11/33	0.865 ¹
≥ 2	3/12	
Age, yr		
< 60	8/22	0.457 ²
≥ 60	6/23	
BMI at the first treatment of APC, kg/m ²		
< 21	7/21	0.763 ²
≥ 21	7/24	
Time from the end of radiotherapy to bleeding, mo		
< 8	6/17	0.637 ²
≥ 8	8/28	
Time from the end of radiotherapy to the first time of APC, mo		
< 14	8/23	0.586 ²
≥ 14	6/22	

¹Data were calculated using continuity correction;

²Data were calculated using the χ^2 test;

³Data were calculated using the Fisher exact test.

APC: Argon plasma coagulation; CRP: Chronic radiation proctitis; BMI: Body mass index.

DISCUSSION

Table 2 Univariate analysis of factors associated with argon plasma coagulation treatment complications for hemorrhagic chronic radiation proctitis

Variable	No. of complication/total patients	P-value
Distribution of telangiectasias		
Distal rectum (within 10 cm from anal verge)	4/31	1.000 ²
Entire rectum +/- sigmoid (more than 10 cm from anal verge)	2/14	
Surface area covered by telangiectasias		
Less than 50%	2/19	1.000 ²
More than 50%	4/26	
Presence of fresh blood		
No	1/16	0.399 ²
Yes	5/29	
Ulceration		
< 1 cm ²	2/33	0.035 ²
> 1 cm ²	4/12	
Gender		
Female	5/40	0.529 ²
Male	1/5	
Hypertensive		
No	4/39	0.367 ¹
Yes	2/6	
Diabetic		
No	4/40	0.125 ²
Yes	2/5	
Abdominal surgery		
No	6/33	0.171 ²
Yes	0/12	
Acute radiation injury		
No	6/39	0.699 ¹
Yes	0/6	
Requiring blood transfusions		
No	3/30	0.384 ²
Yes	3/15	
Number of APC		
1	5/33	1.000 ²
≥ 2	1/12	
Age, yr		
< 60	1/22	0.187 ²
≥ 60	5/23	
BMI at the first treatment of APC, kg/m ²		
< 21	3/21	1.000 ²
≥ 21	3/24	
Time from the end of radiotherapy to bleeding, mo		
< 8	2/17	1.000 ²
≥ 8	4/28	
Time from the end of radiotherapy to the first time of APC, mo		
< 14	4/23	0.665 ²
≥ 14	2/22	

¹Data were calculated using continuity correction;

²Data were calculated using the Fisher exact test.

APC: Argon plasma coagulation; CRP: Chronic radiation proctitis; BMI: Body mass index.

Radiation therapy is widely used for pelvic cancer. Although radiation techniques have made substantial advances in delivering more targeted radiation to tumors, as

many as 5% of patients treated with radiotherapy for pelvic cancer will suffer from hemorrhagic CRP. Several treatment modalities, including APC, are strongly recommended by the American Society of Colon and Rectal Surgeons (ASCRS); however, none of them are based on high-quality evidence^[17]. APC has been widely reported as an effective and safe modality for the treatment of hemorrhagic CRP; however, reported effectivity and complication rates vary across studies, with effectivity rates from 50% to 100% and complication rates from 0% to 63.6%^[21]. Few studies have investigated the prognostic factors and risk factors of APC for the treatment of hemorrhagic CRP. Based on the strict definition of success, which states that the follow-up time should be at least 12 mo from the last treatment of APC, our study confirmed that APC was an effective modality with the complete control of bleeding in 68.9% of all patients. The independent prognostic factors were both endoscopic features prior to APC, including telangiectasias present on more than 50% of surface area and ulceration greater than 1 cm². Our study also showed that APC was not a risk-free procedure, with 13.3% of patients developing rectal fistulas. The only risk factor identified was ulceration greater than 1 cm².

The efficacy of APC in our study seemed to be less than that observed in some prior studies^[22-24]. Two main reasons may contribute to this. First, we defined treatment success on the basis of the long-term effect (at least 12 mo of follow-up from the last treatment of APC). A study in Japan analyzed 64 patients who developed hemorrhagic CRP, with a median follow-up period of 35 mo (range: 12-69 mo) to assess treatment efficacy^[25]. In this study, 12 patients received APC therapy, and 5 of them (42%) successfully had their bleeding stopped. Second, 24 (53.3%) patients in our study were categorized as having severe radiation proctitis prior to APC therapy according to the endoscopic severity of hemorrhagic CRP developed by Zinicola *et al.*^[18]. Half of the patients were treated successfully by APC. The results of this study were consistent with Zinicola *et al.*^[18], in which only one of the three patients with severe radiation proctitis was treated successfully by APC. The authors concluded that success was not certain for patients with severe hemorrhagic CRP.

Whether endoscopic severity has predictive value in the treatment of hemorrhagic CRP with APC remains controversial. In a series of 50 patients, Swan *et al.*^[26] found that the endoscopic grade did not predict the likelihood of treatment success. A study by Siow *et al.*^[22] also suggested that endoscopic grading was not a predictor of the number of APC sessions needed to achieve hemostasis. However, Zinicola *et al.*^[18] suggested that endoscopic severity could predict the success of APC. The endoscopic score they developed was based on the telangiectasia distribution, surface area covered by telangiectasias, and presence of fresh blood. APC failed in 2 of 14 patients, both of whom had more than 50% of the surface area covered by telangiectasias and fresh blood in the rectum. The authors considered these two factors to be significant in predicting the treatment success of APC. Karamanolis *et al.*^[20] also confirmed a statistically significant correlation between endoscopic severity and the treatment success of APC. They used a modified 2-grade scale instead of the 3 grades proposed by Zinicola *et al.*^[18] to assess the endoscopic severity. The modified scale included telangiectasia distribution and surface area covered by telangiectasias. Our study also confirmed that telangiectasias present on more than 50% of surface area was an independent prognostic factor for treatment failure of APC. We did not find a significant correlation between the presence of fresh blood and the treatment failure of APC. Some authors argued that luminal blood might result in an unclear view and prevent adequate telangiectasia ablation, which could reduce the efficacy of APC. During the APC procedure, we used a water pump (OFP-2; Olympus) to rinse away blood or other contaminating material, which might have minimized the adverse impact of the blood. According to the Vienna grading system, ulceration represents a severity feature of radiation proctitis. Goldner *et al.*^[27] thought that patients who had received high doses at a certain volume could develop histopathological changes such as ulcers in addition to congested mucosa or telangiectasia. Our study found that ulceration greater than 1 cm² was another independent prognostic factor. The explanation for this is still unclear. One possible explanation is that ulceration greater than 1 cm² indicates more severe disease; another is that the endoscopist might restrict the application of APC in terms of argon flow, power, and time in the case of a large ulceration.

Some gastroenterologists consider APC to be a safe and "risk-free" treatment modality. The major complications reported are mucus discharge, rectal pain, and rectal ulcerations, which are most likely self-limiting and rarely require intervention^[24]. Severe complications, including fistulation and stricture formation, were reported to affect approximately 3% of patients in several studies^[22]. However, Andreyev *et al.* suggested that APC should be used with caution in patients with CRP. They warned that the severe complication rate of APC could reach as high as 26% when used in patients with severe ischemia in the rectum^[28]. Weiner *et al.*^[29] reported

the long-term results of 35 patients who received APC treatment for hemorrhagic CRP, with a median follow-up time of 56 mo (range: 3-112 mo). In their study, two (5.7%) patients developed fistulation, with one mortality. In our study, six (13.3%) patients developed severe complications involving rectal fistulation; however, all of them survived. We further identified ulceration greater than 1 cm² as the only risk factor for severe complications. APC is a noncontact thermal coagulation technique, in which the thermal energy is delivered to the superficial blood vessels by ionized gas. The depth of coagulation is limited to approximately 0.5-3 mm; thus, the risk of perforation is generally considered to be low. Rectums with ulcers developing after pelvic radiation could be considered as having fragile, ischemic, and poor healing tissue. This may partly explain why patients with large ulceration have a higher risk of developing fistulation.

There is no consensus on the optimal APC settings for hemorrhagic CRP. A recent systematic review summarized different APC settings in 32 trials, with the electric power ranging from 25 W to 80 W (median 50 W), and the argon flow ranging from 0.6 L/min to 3.0 L/min (median 1.5 L/min)^[21]. In one study, the optimal APC settings were determined by using a swine rectum at an argon flow of 1.2 L/min and a power of 40 W with application to the lesions in 2-s pulse. Sato *et al*^[30] concluded that this setting was sufficient to ablate telangiectasia but did not damage the muscle layer. However, the review showed that there was no difference in the corresponding complications rates (0%-63.6% *vs* 0%-58.1%) between two electric power settings (50-80 W *vs* 30-50 W, respectively). In addition, four studies using a current of 60 W and an argon flow of > 1.5 L/min reported complications rates of 0%, 0%, 13.3%, and 35.7%. Peng *et al*^[21] noted that APC settings seemed to have no correlation with complication rates. In our study, an argon flow of 1.0-3.0 L/min at a power of 40-60 W with application to the lesions in 1-2 -s pulses was determined by the endoscopist, while an argon flow of 1.8 L/min at a power of 50 W was routinely adopted. This is consistent with the guidelines advocated by ASCRS.

The present study was limited by its retrospective design and a relatively small number of cases. Further large-cohort prospective studies are therefore required to confirm our findings.

In conclusion, the long-term efficacy of APC for hemorrhagic CRP is uncertain in patients with telangiectasias present on more than 50% of the surface area and ulcerated area greater than 1 cm². Ulcerated area greater than 1 cm² is also a risk factor for severe complications.

ARTICLE HIGHLIGHTS

Research background

Radiotherapy is widely used in the treatment of pelvic malignancies. Hemorrhagic chronic radiation proctitis (CRP) is one of the most concerning complication that occurs in 1%-5% of patients who received pelvic radiotherapy for cancer. Current treatment modalities for hemorrhagic CRP include three main categories: medical, interventional, and surgical. Although a wide range of therapeutic modalities are available, there is no literature to date showing any particularly appropriate therapeutic modality for each disease stage.

Research motivation

Argon plasma coagulation (APC) is currently recommended as the first-choice treatment for hemorrhagic CRP, due to its coagulation depth control, easy accessibility, relatively high effectiveness, and low cost. However, its indication based on long-term follow-up is still unclear.

Research objectives

This study aimed to review the long-term efficacy and safety of APC for hemorrhagic CRP, and to evaluate the prognostic and risk factors.

Research methods

We retrospectively analyzed demographics, clinical and endoscopic characteristics, and long-term outcomes of consecutive patients who had received APC treatment for hemorrhagic CRP from January 2013 to October 2017. Success was defined as either cessation of bleeding or only occasional traces of bloody stools with no further treatments for at least 12 mo after the last APC treatment.

Research results

This study enrolled 45 patients with a median 24-mo follow-up period (range: 12-67 mo), 33.3% of whom required blood transfusion before APC. The success rate was 68.9%, with the mean number of APC sessions being 1.3 (1-3). This study showed that telangiectasias present on more than 50% of the surface area [odds ratio (OR) = 6.53, 95% confidence interval (CI): 1.09-39.19, *P* = 0.04] and ulcerated area greater than 1 cm² (OR = 8.15, 95% CI: 1.63-40.88, *P* = 0.01) were poor prognostic indicators for APC treatment of hemorrhagic CRP. Six (13.3%) patients had severe

complications involving rectal fistulation. The only risk factor for severe complications was ulcerated area greater than 1 cm² ($P = 0.035$). Further large-cohort prospective studies are required to confirm our findings.

Research conclusions

Endoscopic severity could predict the success of APC. The long-term efficacy of APC for hemorrhagic CRP is uncertain in patients with telangiectasias present on more than 50% of the surface area and ulcerated area greater than 1 cm². APC is not a "risk-free" treatment modality. Ulcerated area greater than 1 cm² is also a risk factor for severe complications.

Research perspectives

Although APC is currently recommended as the first-choice treatment for hemorrhagic CRP, its long-term efficacy and safety are still not well understood. Our study showed that endoscopic characteristics could predict the success and severe complications of APC. Prospective, multicenter, large-scale studies involving different APC settings ought to be conducted in the follow-up research.

REFERENCES

- Nelamangala Ramakrishnaiah VP, Krishnamachari S. Chronic haemorrhagic radiation proctitis: A review. *World J Gastrointest Surg* 2016; **8**: 483-491 [PMID: 27462390 DOI: 10.4240/wjgs.v8.i7.483]
- Dearnaley DP, Khoo VS, Norman AR, Meyer L, Nahum A, Tait D, Yarnold J, Horwich A. Comparison of radiation side-effects of conformal and conventional radiotherapy in prostate cancer: a randomised trial. *Lancet* 1999; **353**: 267-272 [PMID: 9929018 DOI: 10.1016/S0140-6736(98)05180-0]
- Weiner JP, Wong AT, Schwartz D, Martinez M, Aytaman A, Schreiber D. Endoscopic and non-endoscopic approaches for the management of radiation-induced rectal bleeding. *World J Gastroenterol* 2016; **22**: 6972-6986 [PMID: 27610010 DOI: 10.3748/wjg.v22.i31.6972]
- Hasleton PS, Carr N, Schofield PF. Vascular changes in radiation bowel disease. *Histopathology* 1985; **9**: 517-534 [PMID: 4007790]
- Andreyev HJ. Argon plasma coagulation in chronic radiation proctitis: Postgate *et al.* *Endoscopy* 2007; **39**: 751-2; author reply 752 [PMID: 17661253 DOI: 10.1055/s-2007-966772]
- Dent OF, Galt E, Chapuis PH, Yuile P, Sinclair G, Bokey EL. Quality of life in patients undergoing treatment for chronic radiation-induced rectal bleeding. *Br J Surg* 1998; **85**: 1251-1254 [PMID: 9752870 DOI: 10.1046/j.1365-2168.1998.00821.x]
- Haas EM, Bailey HR, Faragher I. Application of 10 percent formalin for the treatment of radiation-induced hemorrhagic proctitis. *Dis Colon Rectum* 2007; **50**: 213-217 [PMID: 17080283 DOI: 10.1007/s10350-006-0707-y]
- Dziki L, Kujawski R, Mik M, Berut M, Dziki A, Trzciński R. Formalin therapy for hemorrhagic radiation proctitis. *Pharmacol Rep* 2015; **67**: 896-900 [PMID: 26398382 DOI: 10.1016/j.pharep.2015.03.006]
- McElvanna K, Wilson A, Irwin T. Sucralfate paste enema: a new method of topical treatment for haemorrhagic radiation proctitis. *Colorectal Dis* 2014; **16**: 281-284 [PMID: 24299100 DOI: 10.1111/codi.12507]
- Gul YA, Prasanna S, Jabar FM, Shaker AR, Moissinac K. Pharmacotherapy for chronic hemorrhagic radiation proctitis. *World J Surg* 2002; **26**: 1499-1502 [PMID: 12297939 DOI: 10.1007/s00268-002-6529-8]
- Sultania S, Sarkar R, Das K, Dhali GK. Argon plasma coagulation is an effective treatment for chronic radiation proctitis in gynaecological malignancy: an observational study. *Colorectal Dis* 2018 [PMID: 30585689 DOI: 10.1111/codi.14541]
- Postgate A, Saunders B, Tjandra J, Vargo J. Argon plasma coagulation in chronic radiation proctitis. *Endoscopy* 2007; **39**: 361-365 [PMID: 17427074 DOI: 10.1055/s-2007-966284]
- Oscarsson N, Arnell P, Lodding P, Ricksten SE, Seeman-Lodding H. Hyperbaric oxygen treatment in radiation-induced cystitis and proctitis: a prospective cohort study on patient-perceived quality of recovery. *Int J Radiat Oncol Biol Phys* 2013; **87**: 670-675 [PMID: 24035333 DOI: 10.1016/j.ijrobp.2013.07.039]
- Clarke RE, Tenorio LM, Hussey JR, Toklu AS, Cone DL, Hinojosa JG, Desai SP, Dominguez Parra L, Rodrigues SD, Long RJ, Walker MB. Hyperbaric oxygen treatment of chronic refractory radiation proctitis: a randomized and controlled double-blind crossover trial with long-term follow-up. *Int J Radiat Oncol Biol Phys* 2008; **72**: 134-143 [PMID: 18342453 DOI: 10.1016/j.ijrobp.2007.12.048]
- McCrone LF, Neary PM, Larkin J, McCormick P, Mehigan B. The surgical management of radiation proctopathy. *Int J Colorectal Dis* 2017; **32**: 1099-1108 [PMID: 28429071 DOI: 10.1007/s00384-017-2803-y]
- Sebastian S, O'Connor H, O'Morain C, Buckley M. Argon plasma coagulation as first-line treatment for chronic radiation proctopathy. *J Gastroenterol Hepatol* 2004; **19**: 1169-1173 [PMID: 15377295 DOI: 10.1111/j.1440-1746.2004.03448.x]
- Paquette IM, Vogel JD, Abbas MA, Feingold DL, Steele SR; Clinical Practice Guidelines Committee of The American Society of Colon and Rectal Surgeons. The American Society of Colon and Rectal Surgeons Clinical Practice Guidelines for the Treatment of Chronic Radiation Proctitis. *Dis Colon Rectum* 2018; **61**: 1135-1140 [PMID: 30192320 DOI: 10.1097/DCR.0000000000001209]
- Zinicola R, Rutter MD, Falasco G, Brooker JC, Cennamo V, Contini S, Saunders BP. Haemorrhagic radiation proctitis: endoscopic severity may be useful to guide therapy. *Int J Colorectal Dis* 2003; **18**: 439-444 [PMID: 12677457 DOI: 10.1007/s00384-003-0487-y]
- Wachter S, Gerstner N, Goldner G, Pötzi R, Wambersie A, Pötter R. Endoscopic scoring of late rectal mucosal damage after conformal radiotherapy for prostatic carcinoma. *Radiother Oncol* 2000; **54**: 11-19 [PMID: 10719695]
- Karamanolis G, Psatha P, Triantafyllou K. Endoscopic treatments for chronic radiation proctitis. *World J Gastrointest Endosc* 2013; **5**: 308-312 [PMID: 23858374 DOI: 10.4253/wjge.v5.i7.308]
- Peng Y, Wang H, Feng J, Fang S, Zhang M, Wang F, Chang Y, Shi X, Zhao Q, Liu J. Efficacy and Safety of Argon Plasma Coagulation for Hemorrhagic Chronic Radiation Proctopathy: A Systematic Review.

- Gastroenterol Res Pract* 2018; **2018**: 3087603 [PMID: 29681929 DOI: 10.1155/2018/3087603]
- 22 **Siow SL**, Mahendran HA, Seo CJ. Complication and remission rates after endoscopic argon plasma coagulation in the treatment of haemorrhagic radiation proctitis. *Int J Colorectal Dis* 2017; **32**: 131-134 [PMID: 27527929 DOI: 10.1007/s00384-016-2635-1]
- 23 **Yeoh E**, Tam W, Schoeman M, Moore J, Thomas M, Botten R, Di Matteo A. Argon plasma coagulation therapy versus topical formalin for intractable rectal bleeding and anorectal dysfunction after radiation therapy for prostate carcinoma. *Int J Radiat Oncol Biol Phys* 2013; **87**: 954-959 [PMID: 24113059 DOI: 10.1016/j.ijrobp.2013.08.034]
- 24 **Chrusciewska-Kiliszek MR**, Rupinski M, Kraszewska E, Pachlewski J, Regula J. The protective role of antiplatelet treatment against ulcer formation due to argon plasma coagulation in patients treated for chronic radiation proctitis. *Colorectal Dis* 2014; **16**: 293-297 [PMID: 24138319 DOI: 10.1111/codi.12465]
- 25 **Takemoto S**, Shibamoto Y, Ayakawa S, Nagai A, Hayashi A, Ogino H, Baba F, Yanagi T, Sugie C, Kataoka H, Mimura M. Treatment and prognosis of patients with late rectal bleeding after intensity-modulated radiation therapy for prostate cancer. *Radiat Oncol* 2012; **7**: 87 [PMID: 22691293 DOI: 10.1186/1748-717X-7-87]
- 26 **Swan MP**, Moore GT, Sievert W, Devonshire DA. Efficacy and safety of single-session argon plasma coagulation in the management of chronic radiation proctitis. *Gastrointest Endosc* 2010; **72**: 150-154 [PMID: 20493484 DOI: 10.1016/j.gie.2010.01.065]
- 27 **Goldner G**, Tomicek B, Becker G, Geinitz H, Wachter S, Zimmermann F, Wachter-Gerstner N, Reibenwein J, Glocker S, Bamberg M, Feldmann H, Pötzi R, Molls M, Pötter R. Proctitis after external-beam radiotherapy for prostate cancer classified by Vienna Rectoscopy Score and correlated with EORTC/RTOG score for late rectal toxicity: results of a prospective multicenter study of 166 patients. *Int J Radiat Oncol Biol Phys* 2007; **67**: 78-83 [PMID: 17189064 DOI: 10.1016/j.ijrobp.2006.08.055]
- 28 **Andreyev HJ**, Davidson SE, Gillespie C, Allum WH, Swarbrick E; British Society of Gastroenterology; Association of Colo-Proctology of Great Britain and Ireland; Association of Upper Gastrointestinal Surgeons; Faculty of Clinical Oncology Section of the Royal College of Radiologists. Practice guidance on the management of acute and chronic gastrointestinal problems arising as a result of treatment for cancer. *Gut* 2012; **61**: 179-192 [PMID: 22057051 DOI: 10.1136/gutjnl-2011-300563]
- 29 **Weiner J**, Schwartz D, Martinez M, Safdieh J, Aytaman A, Schreiber D. Long-term results on the efficacy of argon plasma coagulation for patients with chronic radiation proctitis after conventionally fractionated, dose-escalated radiation therapy for prostate cancer. *Pract Radiat Oncol* 2017; **7**: e35-e42 [PMID: 27663931 DOI: 10.1016/j.prro.2016.07.009]
- 30 **Sato Y**, Takayama T, Sagawa T, Hirakawa M, Ohnuma H, Miyanishi K, Sato T, Takimoto R, Kobune M, Okamoto K, Takeuchi H, Kato J. Argon plasma coagulation treatment of hemorrhagic radiation proctopathy: the optimal settings for application and long-term outcome. *Gastrointest Endosc* 2011; **73**: 543-549 [PMID: 21257166 DOI: 10.1016/j.gie.2010.11.015]



Published By Baishideng Publishing Group Inc
7041 Koll Center Parkway, Suite 160, Pleasanton, CA 94566, USA
Telephone: +1-925-2238242
Fax: +1-925-2238243
E-mail: bpgoffice@wjgnet.com
Help Desk: <http://www.f6publishing.com/helpdesk>
<http://www.wjgnet.com>

