



Aorto-atrial fistula formation and closure: a systematic review

Jayant S. Jainandunsing^{1#}, Ralph Linnemann^{2#}, Wobbe Bouma², Nicole Natour³, Elham Bidar⁴, Roberto Lorusso⁴, Sandro Gelsomino⁴, Daniel M. Johnson⁴, Ehsan Natour²

¹University of Groningen, University Medical Center Groningen, Department of Anesthesiology, The Netherlands; ²University of Groningen, University Medical Center Groningen, Department of Cardiothoracic Surgery, The Netherlands; ³University of Maastricht, Department of Radiology, Universiteitssingel 50, ER Maastricht 6229, The Netherlands; ⁴University of Maastricht, Department of Cardiothoracic Surgery, Cardiovascular Research Institute Maastricht - CARIM, Universiteitssingel 50, ER Maastricht 6229, The Netherlands

Contributions: (I) Conception and design: J Jainandunsing, R Linnemann, E Natour; (II) Administrative support: R Linnemann, S Gelsomino; (III) Provision of study materials or patients: None; (IV) Collection and assembly of data: J Jainandunsing, R Linnemann, DM Johnson, E Natour; (V) Data analysis and interpretation: J Jainandunsing, R Linnemann, DM Johnson, E Natour; (VI) Manuscript writing: All authors; (VII) Final approval of manuscript: All authors.

[#]These authors contributed equally to this work.

Correspondence to: Ehsan Natour, MD, PhD. Department of Cardiothoracic Surgery, Cardiovascular Research Institute Maastricht - CARIM, Universiteitssingel 50, ER Maastricht 6229, The Netherlands. Email: ehsan.natour@mumc.nl.

Abstract: Blood flow between the aorta and atrium is a rare but complex pathological condition, also known as aorto-atrial fistula (AAF). The exact incidence of this condition is unknown, as are the major precipitating factors and best treatment options. We carried out a systematic review of the available case report literature reporting AAF. We systematically reviewed literature on AAF formation and closure. Separate Medline (PubMed), EMBASE, and Cochrane database queries were performed. The following MESH headings were used: atrium, ventricle, fistula, cardiac, shunts, aortic, aorto-atrial tunnels and coronary cameral fistula. All papers were considered for analysis irrespective of their quality, or the journal in which they were published. Fistula formation from the ascending aorta to the atria occurred more often in the right atrium compared to the left. Endocarditis was the major cause of AAF formation, whilst congenital causes were responsible for nearly 12%. In a number of cases fistula formation occurred secondary to cardiac surgery, whilst chest traumas were a relatively rare cause of AAF. Correction via an open surgical approach occurred in 73.5% of cases, whilst percutaneous intervention was utilised in 10% of patients. In 74.3% of all studied cases the fistula repair was successful and patients survived the procedures. In 14.7% of the cases patients did not survive. Similar outcomes were observed between percutaneous and surgical interventions. Data from larger populations with AAF is lacking, meaning that specific data regarding incidence and prevalence does currently not exist.

Keywords: Aorta; fistula; atria

Submitted Aug 30, 2018. Accepted for publication Nov 15, 2018.

doi: 10.21037/jtd.2019.01.77

View this article at: <http://dx.doi.org/10.21037/jtd.2019.01.77>

Introduction

The presence of blood flow between the aorta and atrium is a rare but complex pathological condition, also known as aorto-atrial fistula (AAF). Systemic symptoms such as heart failure, weakness and oedema may occur as well as more local symptoms including dyspnoea, chest pain, palpitations,

and fatigue or coughing.

The exact incidence of AAF is currently unknown and there are many gaps in our knowledge regarding various aspects of AAF, such as diagnosis strategies and management options. The aim of the present study was to systematically review the available case report literature reporting AAF.

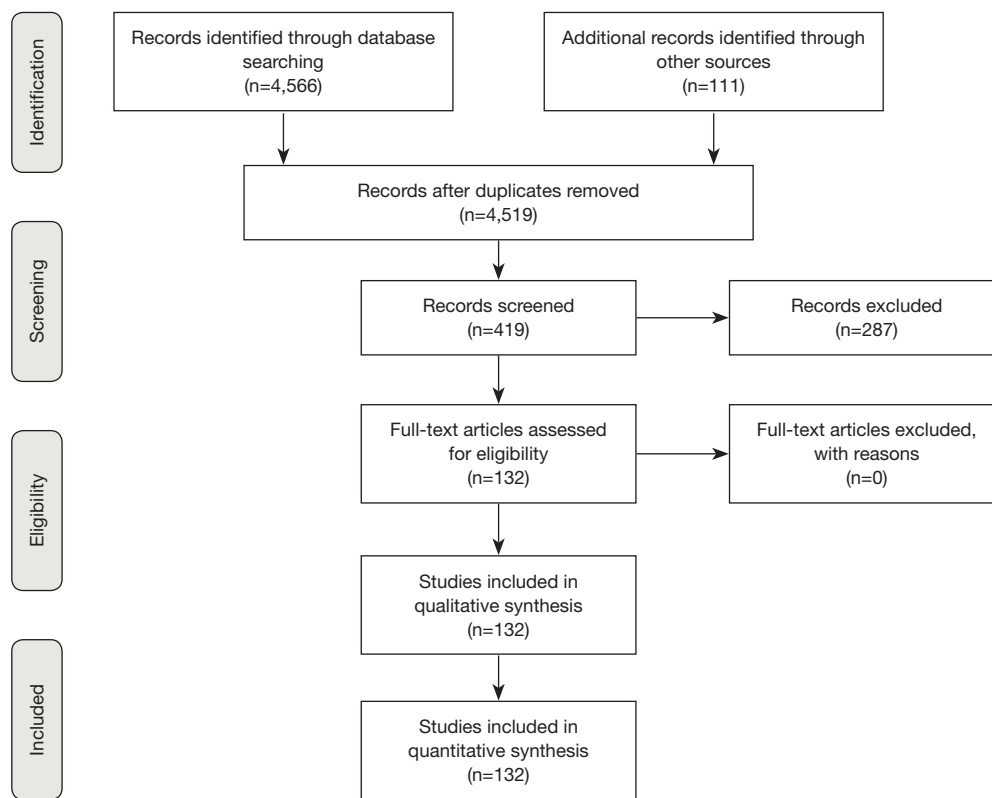


Figure 1 Schematic of Study Selection.

These data will provide an overview of the demographic characteristics of AAF, the pre-operative imaging techniques used to diagnose AAF, the anatomy and causes of AAF and finally give some information on the therapeutic options for AAF and the respective outcomes. These data should enable surgeons to prevent this condition occurring initially, as well as treating it optimally when it does occur.

Evidence acquisition

We systematically reviewed literature on AAF formation and closure. Separate Medline (PubMed), EMBASE, and Cochrane database queries were performed. The following MESH headings were used: atrium, ventricle, fistula, cardiac, shunts, aortic, aorto-atrial tunnels and coronary cameral fistula. All papers were considered for analysis irrespective of their quality, or the journal in which they were published. Strict criteria and screening of titles and abstracts were used to select relevant papers. All papers and reports on AAF formation and closure were included. Reports not written in English were excluded, as well as

reports without a clear description of AAF or AAF closure. No randomized controlled trials or clinical studies were identified. We evaluated the remaining case reports. We identified 132 case reports with a total of 136 patients for our analysis (*Figure 1*). In each of these reports we extracted the following information: year of publication, number of patients, age, sex, previous cardiac surgery, time between surgery and AAF formation, fistula tract, presumed AAF cause, surgical technique for AAF closure, follow-up and outcome (*Table 1*).

Evidence synthesis

Demographics

7% of the studied articles were published in the period from 1960 till 1980. Around 70% of the articles were published after 2000 whilst approximately 35% were published after 2010 (*Figure 2A*). Most case reports on AAF were from the United States of America (39 cases) followed by the United Kingdom (12 cases). Most Asian publications

Table 1 List of all analyzed articles

Reference	Year published	Sex/age (years)	Previous surgery	Time between surgery and AAF	Type of AAF	Cause of AAF	Closure technique	Follow-up/outcome
RB Hsu	2000	M/67	None	N/A	AscAo-RA	Endocarditis	Surgical	Lived
W Dewilde	2008	M/51	AVR + MVR	4 years	AscAo-LA	Prosthetic valve endocarditis	Conservative medical treatment	Lived
D Patsouras	2002	M/70	AVR 2x	7 years; 1 month	AscAo-LA	Aortic dissection	Conservative medical treatment	Died
CS Balestrini	2013	M/57	CABG	12 years	AscAo-RA	SVG aneurysm	Percutaneous	Lived
DA Chung	2000	M/52	Aortic root replacement + CABG	17 years	AscAo-RA	Aortic dissection	Surgical	Lived
F Haddad	2008	M/66	AVR + ascending aorta replacement	10 days	AscAo-RA	Aortic dissection (Giant cell arthritis)	Surgical	Lived
SS Dhawan	2008	M/65	AVR	10 weeks	AscAo-LA	Prosthetic valve endocarditis	Patient refused surgery	Not described
TP Archer	1997	M/61	None	N/A	AscAo-LA	Endocarditis	Patient died before surgery	Died
BN Shah	2012	F/54	AVR	8 years	AscAo-LA	Complication of cardiac surgery	Surgical	Not described
K Suzuki	2006	F/77	Aortic arch replacement	8 years	AscAo-RA	Complication of cardiac surgery	Surgical	Lived
S Cheng Siang	1967	M/55	None	N/A	AscAo-LA	Aneurysm	Conservative medical treatment	Died
O Candan	2012	F/55	MVR 2x, mitral valve repair	4 years; 3 years; 1 month	AscAo-RA	Prosthetic valve endocarditis	Surgical	Died
Y Sakano	2007	F/70	Ascending aorta replacement	16 years	AscAo-RA	Complication of cardiac surgery	Surgical	Lived
S Bouchez	2012	M/61	None	N/A	AscAo-LA	Accidental finding	No procedure performed	Lived
K Ananthasubramaniam	2005	M/66	AVR 2x	Not described; 4 years	AscAo-LA	Complication of cardiac surgery	Surgical	Lived
PR Menon	2011	F/73	Mitral valve repair + tricuspid valve repair	1 year	AscAo-RA	Complication of cardiac surgery	Surgical	Lived
S Pagni	2013	F/69	CABG	8 years	AscAo-RA	Aortic dissection	Surgical	Lived
R Estévez-Loureiro	2012	M/44	AVR	9 years	AscAo-LA	Prosthetic valve endocarditis	Percutaneous	Not described
J Swampillai	2012	F/16	None	N/A	AscAo-RA	Endocarditis	Surgical	Not described

Table 1 (continued)

Table 1 (continued)

Reference	Year published	Sex/age (years)	Previous surgery	Time between surgery and AAF	Type of AAF	Cause of AAF	Closure technique	Follow-up/outcome
R Dalla Pozza	2009	F/72	Aortic valve repair	<1 week	AscAo-LA + AscAo-RA	Complication of cardiac surgery	Percutaneous	Lived
MSL Sey	2010	M/20	Percutaneous closure of ASD	3 weeks	AscAo-RA	ASD device closure	Surgical	Lived
Y Cho	2005	F/61	None	N/A	AscAo-LA	Endocarditis	Surgical	Lived
M Sreedharan	2006	M/11	None	N/A	AscAo-RA	Congenital	Percutaneous	Lived
N Ozer	2007	F/41	AVR	13 years	AscAo-RA	Prosthetic valve endocarditis	Patient died before surgery	Died
MM Stechert	2007	M/65	AVR	6 months	AscAo-LA	Prosthetic valve endocarditis	Surgical	Lived
C Russo	2001	F/70	Ascending aorta replacement	6 years	AscAo-RA	Aortic dissection	Surgical	Lived
A Melua	1998	M/30	None	N/A	AscAo-RA	Behcet's disease	Surgical	Lived
WM Wilson	2010	M/17	Percutaneous closure of ASD	3 months	AscAo-LA	ASD device closure	Surgical	Lived
A Kalra	2013	F/61	Myectomy for hypertrophic cardiomyopathy + CABG	2 months	AscAo-RA	Aortic dissection	Surgical	Not described
H Matsuhisa	2004	M/85	None	N/A	AscAo-RA	Aortic dissection	Surgical	Lived
VR Aligeti	2012	M/61	RFA 2x	Not described	AscAo-RA	Complication of cardiac surgery	Surgical	Lived
AF Elwatidy	2003	F/3	None	N/A	DescAo-RA	Congenital	Surgical	Lived
A Alozie	2012	M/19	None	N/A	AscAo-RA	Aneurysm	Surgical	Lived
MS Topcuoğlu	1997	M/20	None	N/A	AscAo-LA	Congenital	Surgical	Lived
M Sehgal	2002	M/53	TIPS procedure, TIPS revision	4 years 5 months; 3 years 11 months	AscAo-RA	Stent protruding RA	Patient refused surgery	Died
AK Sarkar	2013	M/5 months	None	N/A	DescAo-LA	Congenital	Patient refused surgery	Not described
D Patsouras	2009	M/84	AVR	18 years	AscAo-LA	Prosthetic valve endocarditis	Conservative medical treatment	Lived
MT Barrio-López	2012	M/56	Multiple implantations of endovascular prostheses in IVC	1 day	AscAo-RA	Stent protruding RA	Surgical	Lived

Table 1 (continued)

Table 1 (continued)

Reference	Year published	Sex/age (years)	Previous surgery	Time between surgery and AAF	Type of AAF	Cause of AAF	Closure technique	Follow-up/outcome
M Chacko	2005	M/58	None	N/A	AscAo-LA	Aneurysm	Surgical	Not described
S Moral	2009	F/27	AVR + Aortic root replacement	3 months	AscAo-RA + AscAo-RV	Prosthetic valve endocarditis	Not described	Not described
S Bartus	2008	M/53	Percutaneous closure of congenital ASD	18 months	AscAo-RA	ASD device closure	Spontaneous closure	Lived
JM Hernández-García	2005	F/72	Resection left atrial myxoma 2x	18 years; 15 years	AscAo-LA	Complication of cardiac surgery	Percutaneous	Lived
S Maffè	2012	M/69	AVR	8 years	AscAo-RA	Prosthetic valve endocarditis	Surgical	Died
S Rubin	2006	M/30	None	N/A	AscAo-RA	Trauma	Surgical	Lived
DK Millward	1972	M/32	None	N/A	AscAo-RA	Aortic dissection	Patient died before surgery	Died
GY Jang	2005	F/54	Percutaneous closure of ASD	2 months	AscAo-RA	ASD device closure	Surgical	Lived
AD Berman	1987	F/60	AVR	10 years	AscAo-RA	Aortic dissection	Surgical	Lived
A Caruso	2000	M/41	AVR	8 years	AscAo-LA	Aortic dissection	Surgical	Lived
B Bell	2010	M/65	PCI + CABG	25 years; 19 years	AscAo-RA	SVG aneurysm	Percutaneous	Died
T Sugimoto	2006	M/65	CABG	20 years	AscAo-RA	SVG aneurysm	Surgical	Lived
R Benham	1992	M/21	None	N/A	AscAo-LA	Endocarditis	Surgical	Lived
AJ Page	1973	M/60	None	N/A	AscAo-RA	Aortic dissection	Surgical	Lived
JH Kay	1959	F/39	Exploration through left posterolateral thoracotomy due to cardiac mass	2 months	AscAo-LA	Aortic dissection	Surgical	Lived
A Ebringer	1969	F/21	None	N/A	AscAo-LA	Endocarditis	No procedure performed	Died
EJ Hickey	2008	M/72	CABG	8 years	AscAo-RA	SVG aneurysm	Surgical	Lived
U Filizcan	2011	M/62	None	N/A	AscAo-RA	RCA aneurysm	Surgical	Lived
AC Henze	1991	M/48	AVR	3 years	AscAo-RA	Aortic dissection	Surgical	Lived
JS Oliveira	1991	F/37	None	N/A	AscAo-LA	Aortic dissection	Patient died before surgery	Died

Table 1 (continued)

Table 1 (continued)

Reference	Year published	Sex/age (years)	Previous surgery	Time between surgery and AAF	Type of AAF	Cause of AAF	Closure technique	Follow-up/outcome
A Kalangos	2000	M/18	None	N/A	AscAo-RA	Congenital	Surgical	Not described
		M/7	None	N/A	AscAo-RA	Congenital	Surgical	Not described
C Türkay	2003	M/29	None	N/A	AscAo-RA	Congenital	Surgical	Not described
PR James	2002	M/34	AVR	1 week	AscAo-RA	Prosthetic valve endocarditis	Surgical	Lived
PA Crean	1983	F/65	None	N/A	AscAo-RA	Rheumatoid arthritis	Patient died before surgery	Died
W Beck	1964	M/42	None	N/A	AscAo-LA	Aneurysm	Surgical	Lived
JR Büchler	1983	M/53	CABG	2 years	AscAo-RA	Aortic dissection	Surgical	Died
W Knirsch	2005	M/3	Percutaneous closure of ASD	4 weeks	AscAo-LA	ASD device closure	Surgical	Lived
CS Krishna	2010	F/11	None	N/A	AscAo-RA	Congenital	Surgical	Lived
		M/24	None	N/A	AscAo-RA	Congenital	Surgical	Lived
YC Tsai	2002	F/2	None	N/A	AscAo-RA	Not described	Surgical	Lived
AM Esen	2003	M/44	None	N/A	AscAo-LA	Endocarditis	Surgical	Lived
H Nakano	2000	M/65	AVR	15 years	AscAo-RA	Aortic dissection	Surgical	Lived
M Dulake	1964	M/49	None	N/A	AscAo-RA	Aortic dissection	Conservative medical treatment	Died
AD Timmis	1985	M/72	None	N/A	AscAo-RA	Aortic dissection	Surgical	Died
D Vaidyanathan	1990	M/30	None	N/A	AscAo-RA	Aortic dissection	Conservative medical treatment	Lived
P Nicod	1984	F/52	CABG	9 years	AscAo-RA	Aortic dissection	Surgical	Not described
P Nihoyannopoulos	1987	M/4	None	N/A	DescAo-LA	Congenital	Surgical	Lived
S Chandra	2011	F/12	None	N/A	AscAo-RA	Congenital	Percutaneous	Lived
A Schwartzbard	1998	F/75	AVR	2 years	AscAo-LA	Prosthetic valve endocarditis	Surgical	Died
T Feldman	2006	F/76	MVR	10 years	AscAo-LA	Complication of cardiac surgery	Percutaneous	Lived
DS Chun	2003	M/10	Percutaneous closure of ASD	3 months	AscAo-RA	ASD device closure	Surgical	Lived

Table 1 (continued)

Table 1 (continued)

Reference	Year published	Sex/age (years)	Previous surgery	Time between surgery and AAF	Type of AAF	Cause of AAF	Closure technique	Follow-up/outcome
PA Grayburn	2005	F/41	Percutaneous closure of ASD	20 months	AscAo-RA	ASD device closure	Surgical	Lived
VS Mahadevan	2006	F/17	Percutaneous closure of ASD	25 months	AscAo-LA	ASD device closure	Percutaneous	Lived
DM Mello	2005	F/16	Percutaneous closure of ASD	6 months	AscAo-LA	ASD device closure	Surgical	Lived
D Danilowicz	1989	F/5 days	None	N/A	AscAo-RA	Congenital	Surgical	Lived
JW Jukema	1992	F/68	CABG	8 years	AscAo-RA	SVG aneurysm	Surgical	Lived
C Nathaniel	1996	M/59	CABG	16 years	AscAo-RA	SVG aneurysm	Surgical	Died
L Gruberg	1999	M/52	AVR + CABG	17 years	AscAo-RA	SVG aneurysm	Surgical	Lived
W Fares	2003	M/73	CABG, dual chamber pacemaker placement	21 years; 9 years	AscAo-RA	SVG aneurysm	Percutaneous	Lived
SA Photiou	1981	M/55	AVR	10 months	AscAo-RA	Aneurysm	Surgical	Lived
A DeSa'Neto	1979	M/17	None	N/A	AscAo-RA	Trauma	Surgical	Lived
F Moraes	2004	M/1	None	N/A	AscAo-RA	Congenital	Surgical	Lived
AE Weyman	1975	M/24	None	N/A	AscAo-RA	Aneurysm	Surgical	Lived
M Aiba	2013	M/71	CABG, Graft replacements of abdominal aorta, bilateral femoral + popliteal arteries, descending aorta	20 years; 16 years; 7 years; 3 years	AscAo-RA	SVG aneurysm	Surgical	Lived
M Yuce	2011	M/70	CABG + cardioverter-defibrillator implantation	22 years; 7 years	AscAo-RA	SVG aneurysm	Patient refused surgery	Not described
MP Richardson	1992	M/74	CABG	11 years	AscAo-RA	SVG aneurysm	Surgical	Died
H Le Breton	1998	M/62	CABG	21 years	AscAo-RA	SVG aneurysm	Surgical	Lived
ML Williams	2004	M/58	CABG	12 years	AscAo-LA	SVG aneurysm	Surgical	Lived
HD Danenberg	1995	F/49	Percutaneous transjugular stent placement to IVC and left hepatic vein	14 months	AscAo-RA	Complication of internal jugular vein catheterization	Surgical	Lived
SK Aggarwal	2007	F/12	None	N/A	AscAo-RA	Congenital	Surgical	Lived
		M/33	None	N/A	AscAo-RA	Aneurysm	Surgical	Lived

Table 1 (continued)

Table 1 (continued)

Reference	Year published	Sex/age (years)	Previous surgery	Time between surgery and AAF	Type of AAF	Cause of AAF	Closure technique	Follow-up/outcome
K Nandate	2016	M/19	None	N/A	AscAo-LA	Trauma	Surgical	Lived
E Valero	2016	F/60	Ascending aorta reconstruction without AVR	8 years	AscAo-LA	Endocarditis	Surgical	Lived
M Alkouli	2017	M/84	AVR	3 days	AscAo-RA	Complication of cardiac surgery	Percutaneous	Lived
T Ahmad	2014	M/71	None	N/A	AscAo-LA	Complication of cardiac surgery	Surgical	Lived
ES John	2014	F/21	None	N/A	AscAo-RA	Endocarditis	Surgical	Lived
S Chandra	2013	M/20	None	N/A	AscAo-LA	Endocarditis	Surgical	Lived
AM Noyes	2015	M/35	None	N/A	AscAo-LA	Endocarditis	Surgical	Lived
M Bashir	2014	M/27	Percutaneous closure of ASD	6 weeks	AscAo-RA	ASD device closure	Surgical	Lived
P Sytnik	2015	M/63	Ascending aorta reconstruction without AVR	9 days	AscAo-RA	Aortic dissection	Surgical	Lived
PA Villablanca	2014	F/51	None	N/A	AscAo-RA	Endocarditis	Patient refused surgery	Lived
M Yesin	2015	F/41	MVP + MVR	4 months	AscAo-LA	Complication of cardiac surgery	Surgical	Lived
N Raut	2016	M/48	MVR	4 years	AscAo-LA	Complication of cardiac surgery	Surgical	Lived
Y Agrawal	2016	M/57	None	N/A	AscAo-LA	Endocarditis	Patient died before surgery	Died
A Ikeda	2016	M/45	None	N/A	AscAo-RA	Endocarditis	Surgical	Lived
F Sabzi	2015	F/37	None	N/A	AscAo-LA + AscAo-RA	Endocarditis	Surgical	Lived
L Frey	2014	F/45	None	N/A	AscAo-RA	Endocarditis	Surgical	Lived
I Ece	2015	F/7	None	N/A	AscAo-RA	Congenital	Percutaneous	Lived
H Matsumoto	2014	F/72	AVR	3 years	AscAo-RA	Complication of cardiac surgery	Surgical	Lived
C Siebers	2014	M/62	AVR	5 years	AscAo-RA	Prosthetic valve endocarditis	Surgical	Lived
AC Aykan	2013	M/21	AVR + MVR	Not described	AscAo-LA	Prosthetic valve endocarditis	Surgical	Lived
MY Tsang	2014	F/43	Multiple catheter ablations	Not described	AscAo-RA	Complication of percutaneous catheterization	Surgical	Not described

Table 1 (continued)

Table 1 (continued)

Reference	Year published	Sex/age (years)	Previous surgery	Time between surgery and AAF	Type of AAF	Cause of AAF	Closure technique	Follow-up/outcome
A Gunarathne	2013	M/28	None	N/A	AscAo-RA + AscAo RV	Endocarditis	Surgical	Lived
E Sener	2014	F/19	None	N/A	AscAo-RA	Aneurysm	Surgical	Lived
R Pancas	2012	F/51	None	N/A	AscAo-RA	Not described	Surgical	Not described
V Patel	2010	F/72	2x AVR	10 years, several weeks	AscAo-RA + AscAo RV	Complication of cardiac surgery	Patient died before surgery	Died
T Takamura	2009	F/82	AVR	6 months	AscAo-RA	Prosthetic valve endocarditis	Surgical	Lived
MM El Yaman	2007	M/32	Coarctation repair, MVR, MVR, AVR+MVR	early childhood, 29 years, 25 years, 15 years	AscAo-LA	Complication of cardiac surgery	Percutaneous	Lived
O Badak	2003	F/49	AVR + MVR	10 months	AscAo-RA	Complication of cardiac surgery	Surgical	Lived
M Hachida	1994	F/57	AVR + MVR + Manouguian procedure	6 years	AscAo-LA	Complication of cardiac surgery	Surgical	Lived
		F/49	AVR + MVR + Manouguian procedure	3 years	AscAo-LA + AscAo-LV	Complication of cardiac surgery	Surgical	Lived
NE Liddell	1992	M/51	AVR + Aortic root replacement	8 weeks	AscAo-LA	Complication of cardiac surgery	Surgical	Lived
H Chang	1989	M/25	None	N/A	AscAo-RA	Trauma	Surgical	Lived
R Hayward	1988	F/72	Ascending aorta reconstruction without AVR	5 weeks	AscAo-RA	Complication of cardiac surgery	Percutaneous	Lived
JL Taylor	1982	M/61	None	N/A	AscAo-RA	Aortic dissection	Surgical	Lived
R Berkowitz	1973	M/24	Emergency thoracotomy and suturing of laceration RA appendage and RV	33 days	AscAo-RA	Trauma	Surgical	Lived
JS Ladowski	1984	F/56	Closed mitral commissurotomy	25 years	AscAo-RA	Complication of percutaneous catheterization	Surgical	Lived

AAF, aorto-atrial fistula; AscAo, ascending aorta; DescAo, descending aorta; RA, right atrium; LA, left atrium; RV, right ventricle; AVR, aortic valve replacement; MVR, mitral valve replacement; PCI, percutaneous coronary intervention; CABG, coronary artery bypass grafting; SVG, saphenous vein graft; IVC, inferior vena cava; ASD, atrial septal defect; RFA, radiofrequency ablation; TIPS, transjugular intrahepatic portosystemic shunt.

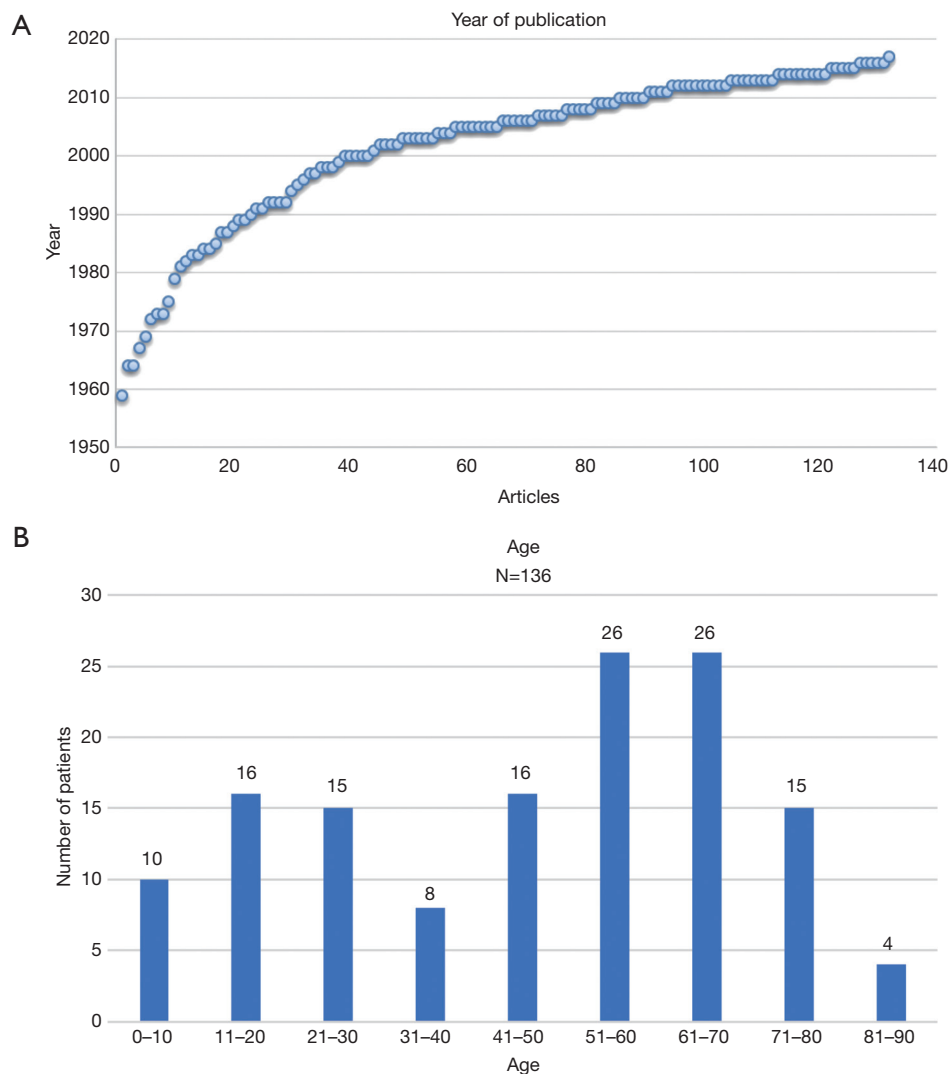


Figure 2 Demographics of Patient Population with AAF. (A) Number of articles published about AAF in time; (B) occurrence of AAF per age group. AAF, aorto-atrial fistula.

stemmed from India (11 cases), Japan (12 cases) and Turkey (12 cases). From the 136 cases analysed the occurrence of AAF had a male to female ratio of approximately 2:1. The age of the patients in the case reports described ranged between 5 days and 85 years old (median 51 years, average 46 years) (Figure 2B).

Imaging

In 130 out of the 136 cases information was provided regarding use of preoperative imaging techniques. In the majority of the cases where imaging was utilised,

echocardiography (83.1%) and angiography (59.6%) were favoured (Tables 2 and 3). Out of the 113 reported cases where echocardiography was used, the use of transthoracic (23.9%) as well as transesophageal (24.8%) or the combination of both (23.0%) seemed to be equally distributed, whilst in 28.3% of cases the technique the authors had used was not specified (Table 3).

Anatomy

Fistula formation from the ascending aorta to the atria occurred more often into the right atrium (86 of the 136

Table 2 Pre-operative diagnostic tests, number of cases, all cases (136)

Pre-operative diagnostic tests (N=136)	Number of cases	Percentage
Echocardiography only	47	34.6
Echocardiography + Angio	34	25.0
Echocardiography + Angio + CT scan	20	14.7
Echocardiography + Angio + CT-scan + MRI	1	0.7
Echocardiography + Angio + MRI	2	1.5
Echocardiography + CT-scan	8	5.9
Echocardiography + CT-scan + MRI	1	0.7
Angio only	11	8.1
Angio + CT-scan	3	2.2
Angio + MRI	1	0.7
CT-scan only	2	1.5
None described	6	4.4

Table 3 Preoperative diagnostic tests, percentages, all cases (136)

Preoperative diagnostic tests (N=136)	Number of cases	Percentage
Echocardiography	113	83.1
TTE	27	19.9 (23.9% of 113 cases)
TEE	28	20.6 (24.8% of 113 cases)
TTE + TEE	26	19.1 (23.0% of 113 cases)
Type of echocardiography not specified	32	23.5 (28.3% of 113 cases)
Angio	81	59.6
CT-scan	35	25.7
MRI	5	3.7
Not described	6	4.4

TTE, transthoracic echocardiography; TEE, transesophageal echocardiography.

cases) compared to the left atrium (41 of the 136 cases), at a LA to RA ratio of 1:2.1. In two patients, the fistula tract originated from the descending aorta into the left atrium (DescAo-LA) (1,2). Some very rare cases included fistula formation from the descending aorta into the right atrium (DescAo-RA) (3), fistula formation to both the left and right atrium (4,5) and fistula formation between the ascending aorta, right atrium as well as the right ventricle (6-8) and fistula formation between the ascending aorta, left atrium as well as the left ventricle (9) (*Figures 3,4 and Table 4*).

Causes

In the majority of cases (22.8%) endocarditis was the cause of AAF formation. In 71% of these cases, a paravalvular abscess was also present. Furthermore, 45.2% of these patients had prior surgery with a prosthetic valve. Aortic aneurysms (22.1%), mainly complicated with dissected aortic walls, were the 2nd most common cause. Congenital causes (11.8%) were also responsible for a number of AAFs. In this group 81.2% of the fistula tracts were from the

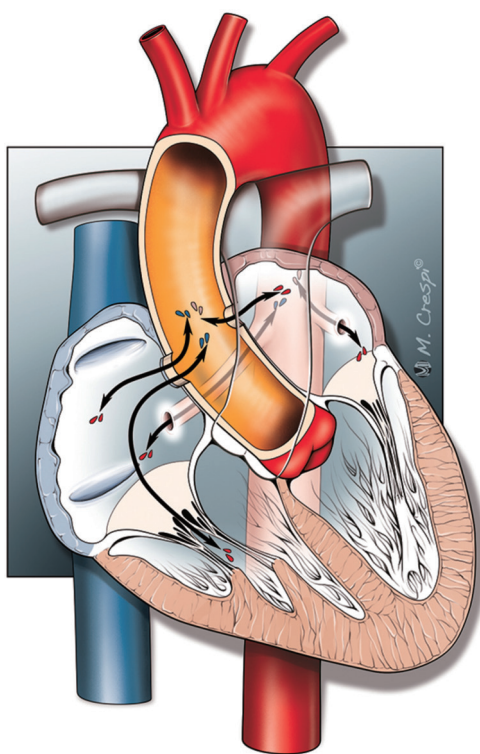


Figure 3 Types of AAF. AAF, aorto-atrial fistula.

aorta to the right atrium whilst only 18.8% led into the left atrium. Interestingly, chest traumas were a relatively rare cause of AAF, with this being the cause in just 3.7% of all cases reported.

In 15.4% of the cases fistula formation occurred secondary to cardiac surgery. Saphenous vein graft (SVG) aneurysms after coronary artery bypass surgery were responsible for 9.6% of the AAF formations in the reported cases. Furthermore, in 7.4% of the cases a previous atrial septal defect closure with a device was responsible for AAF (Table 5).

Therapy

As shown in Table 6, AAF was corrected via an open surgical approach in 73.5% of all cases. In 10.3% the fistula was closed via a percutaneous intervention, whilst in 4.4% of cases a conservative medical approach was advocated (e.g., diuretics and blood transfusions), due to the high surgical risk. In one case the patient was scheduled for surgical closure of the fistula, but echocardiography showed a spontaneous closure. In 3.6% of cases the patient refused

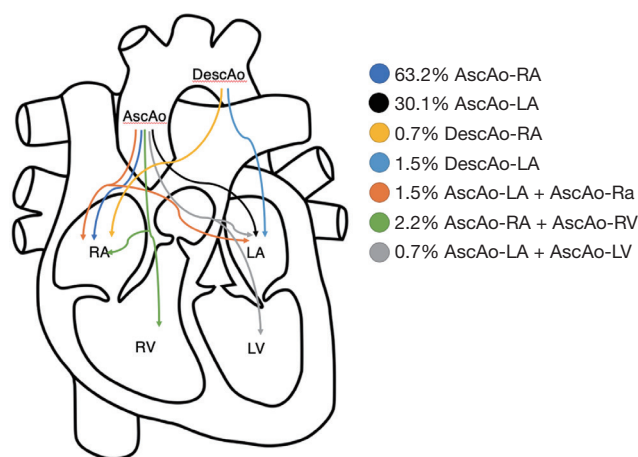


Figure 4 A Schematic outline illustrating the occurrence rates of different types of AAF. AAF, aorto-atrial fistula.

Table 4 Type of AAF, all cases (136)

Type of AAF (N=136)	Number of cases	Percentage
AscAo-RA	86	63.2
AscAo-LA	41	30.1
DescAo-RA	1	0.7
DescAo-LA	2	1.5
AscAo-LA + AscAo-RA	2	1.5
AscAo-RA + AscAo-RV	3	2.2
AscAo LA + AscAo LV	1	0.7

AAF, aorto-atrial fistula; AscAo, ascending aorta; DescAo, descending aorta; RA, right atrium; LA, left atrium; RV, right ventricle; LV, left ventricle.

corrective surgery and in 5.1% of all cases the patient died before surgery could go ahead. In 1.5% of all cases with AAF there was no procedure or medical intervention performed, either due to a very high operational risk or due to the fact that the fistula had no hemodynamic effects. In 0.7% of the cases the treatment of the AAF was not described. In 42% of the cases where a surgical approach was utilized, the fistula was closed with sutures. In 20% of the cases it was opted to close the fistula with a patch, whilst in 4% the tract was ligated. A combined approach of suturing and the use of patches occurred in 5% of cases. The closing technique during corrective surgery was not described in 29% of cases (Table 6). When percutaneous closure of the fistula tract was employed, closure with an

Table 5 Causes of AAF, all cases (136)

Cause of AAF (N=136)	Number of cases	Percentage	Sub-analysis individual groups
Aneurysm	30	22.1	N=30
With dissection	22	16.2	73%
Without dissection	8	5.9	27%
Endocarditis (total)	31	22.8	N=31
With abscess formation	22	16.2	71%
Without abscess formation	9	6.6	29%
Endocarditis no artificial valves	17	12.5	54.8%
With abscess formation	11	8.1	64.7%
Without abscess formation	6	4.4	35.3%
Prosthetic valve endocarditis	14	10.3	45.2%
With abscess formation	11	8.1	78.6%
Without abscess formation	3	2.2	21.4%
Congenital	16	11.8	N=16
Congenital ARAF	13	9.6	81.2%
Congenital ALAF	3	2.2	18.8%
SVG aneurysm	13	9.6	–
Complication of cardiac surgery	21	15.4	–
ASD device closure	10	7.4	–
Chest trauma	5	3.7	–
Stent protruding RA	2	1.5	–
Complication of percutaneous catheterization	3	2.2	–
RCA aneurysm	1	0.7	–
Behcet's disease	1	0.7	–
Rheumatoid arthritis	1	0.7	–
Accidental finding	1	0.7	–

AAF, aorto-atrial fistula; ARAF, aorto-right atrial fistula; ALAF, aorto-left atrial fistula; SVG, saphenous vein graft; ASD, atrial septal defect; RA, right atrium.

Amplatzer device was the treatment of choice (71.4%), followed by coil embolization (14.3%), covered stents (7.15%) and finally balloon closures (7.15%) (Table 6).

Outcomes

In 74.3% of all studied cases the fistula repair was successful and patients survived the procedures. In 14.7% of the cases patients did not survive, whilst in 11.0% of the reported cases patient's outcome was not mentioned. In 83% of all

surgical cases the fistula repair was successful and patients survived the procedures. In 85.7% of all the percutaneous fistula corrections, the repair was successful and patients survived the procedures (Table 7).

Discussion

We systematically reviewed the literature for reports on AAF. We did not identify any reports on systematic registries or clinical trials investigating AAF. All our knowledge on

Table 6 Treatment of AAF, all cases (136)

Type of treatment (N=136)	Number of cases	Percentage	Sub-analysis individual groups
Surgical closure	100	73.5	N=100
Suture closure of fistula	42	30.9	42%
Patch closure of fistula	20	14.7	20%
Combination of suture and patch	5	3.7	5%
Ligation of fistula	4	2.9	4%
Closing technique not described	29	21.3	29%
Percutaneous closure	14	10.3	N=14
Amplatzer device	10	7.4	71.4%
Coil embolisation	2	1.5	14.3%
Covered stents	1	0.7	7.15%
Balloon closure	1	0.7	7.15%
Conservative medical treatment	6	4.4	–
Patient died before surgery	7	5.1	–
Patient refused surgery	5	3.7	–
No procedure performed	2	1.5	–
Procedure not described	1	0.7	–
Spontaneous closure	1	0.7	–

AAF, aorto-atrial fistula.

AAF is therefore currently based on case-reports. Based on the reported case reports, we conclude that:

- (I) Small AAFs can be asymptomatic and may be conservatively approached with the reduction of cardiac afterload and the use of diuretics. In these cases, it is highly recommended to closely observe the patient over time and if clinical conditions deteriorate, active closure of the fistula should be considered.
- (II) Large AAFs require immediate closure either percutaneously or via a surgical approach. Spontaneous closure of an AAF is very rare and conservative treatment must be strongly discouraged in cases with large fistulas or clinical symptoms ensue.
- (III) Although the case volume is low, compared to surgery, percutaneous closure has shown comparable outcome.

The surgical approach to close the fistula often entails

suturing or the use of a patch. Percutaneous closure of AAF has been employed more often in the last few years. There are no specific devices for transcatheter closure of fistulas, but devices like the Amplatzer Septal Occluder, used for closing atrial septal defects, have proven their applicability for this purpose. Overall treatment success rates are at least 70% with a mortality rate of around 15%.

There are a number of limitations to our study, with the major limitation being that reported data came from case reports or case series. For these reasons, it is likely that there is some publication bias as it is highly likely that not all cases have been published. Furthermore, cases of patients who were unsuccessfully treated are less likely to be reported. Data from larger populations is lacking, meaning that specific data regarding incidence and prevalence does currently not exist. This review provides us with a number of insights into the occurrence and pathophysiology of AAF, as well as the current treatment options for this rare, but potentially life threatening, condition.

Table 7 Outcome of AAF, all cases (136)

Type of treatment (N=136)	Survived	Died	Not described	Number of cases
Intervention				
Surgical closure	83 (83%)	7 (7%)	10 (10%)	100
Suture closure	37 (88.1%)	1 (2.4%)	4 (9.5%)	42
Patch closure	16 (80%)	2 (10%)	2 (10%)	20
Suture and patch closure	5 (100%)	–	–	5
Ligation	4 (100%)	–	–	4
Closing technique not described	21 (72.4%)	4 (13.8%)	4 (13.8%)	29
Percutaneous closure	12 (85.7%)	1 (7.1%)	1 (7.1%)	14
Amplatzer device	9 (90%)	–	1 (10%)	10
Coil embolization	2 (100%)	–	–	2
Covered stents	–	1 (100%)	–	1
Balloon closure	1 (100%)	–	–	1
Procedure not described	–	–	1 (100%)	1
Overall treatment success	95 (82.6%)	8 (7.0%)	12 (10.4%)	115
No intervention				
Conservative medical treatment	3 (50%)	3 (50%)	–	6
No procedure performed	1 (50%)	1 (50%)	–	2
Patient refused surgery	1 (20%)	1 (20%)	3 (60%)	5
Spontaneous closure	1 (100%)	–	–	1
Patient died before surgery	–	7 (100%)	–	7
Overall	101 (74.3%)	20 (14.7%)	15 (11.0%)	136

AAF, aorto-atrial fistula.

Acknowledgements

None.

Footnote

Conflicts of Interest: The authors have no conflicts of interest to declare.

References

1. Nihoyannopoulos P, Sapsford R, Oakley CM. Congenital fistula between the aorta and left atrium. *Br Heart J* 1987;57:387-90.
2. Sarkar AK, Sanjeeva NG, Waghmare NS. Association of congenital descending aorto-left atrial fistula with the aortopulmonary window and atrial septal defect. *Cardiol Young* 2014;24:143-4.
3. Elwatidy AF, Galal AN, Rhydderch D, et al. Aorto-right atrial fistula. *Ann Thorac Surg* 2003;76:929-31.
4. Dalla Pozza R, Kozlik-Feldmann R, Le TP, et al. Interventional closure of two fistulas after aortic valve surgery. *Clin Res Cardiol* 2009;98:451-4.
5. Sabzi F, Heidari A, Faraji R. A rare case of aortic sinuses of valsalva fistula to multiple cardiac chambers secondary to periannular aortic abscess formation from underlying *Brucella* endocarditis. *GMS Hyg Infect Control* 2015;10:Doc14.
6. Moral S, Aboal J, Morales M. Multiple aorto-right cavitory fistula: a rare complication of prosthetic valvular endocarditis in intravenous drug users. *Eur J Echocardiogr*

- 2009;10:374-5.
7. Gunarathne A, Hunt J, Gershlick A. Aorto-right atrial and right ventricular fistulae: a very rare complication of native bicuspid aortic valve endocarditis. *Heart* 2013;99:1708.
 8. Patel V, Fountain A, Guglin M, et al. Three-dimensional transthoracic echocardiography in identification of aorto-right atrial fistula and aorto-right ventricular fistulas. *Echocardiography* 2010;27:E105-8.
 9. Hachida M, Koyanagi H, Hanayama N, et al. Successful reconstruction of aorto-left atrial fistula following aortic valve replacement and root enlargement by the Manouguian procedure. *J Card Surg* 1994;9:392-8.

Cite this article as: Jainandunsing JS, Linnemann R, Bouma W, Natour N, Bidar E, Lorusso R, Gelsomino S, Johnson DM, Natour E. Aorto-atrial fistula formation and closure: a systematic review. *J Thorac Dis* 2019;11(3):1031-1046. doi: 10.21037/jtd.2019.01.77