

Case report

Open antero-lateral dislocation of the elbow. A case report

Juan A Alonso*, Bibas R Roy and David L Shaw

Address: Department of Orthopaedics and Trauma Surgery, Bradford Royal Infirmary, Bradford, UK

E-mail: Juan A Alonso* - antonio@alonso.co.uk; Bibas R Roy - bibrroy@bigfoot.com; David L Shaw - dlshaw@orthonet.org.uk

*Corresponding author

Published: 4 January 2002

Received: 18 October 2001

BMC Musculoskeletal Disorders 2002, **3**:1

Accepted: 4 January 2002

This article is available from: <http://www.biomedcentral.com/1471-2474/3/1>

© 2002 Alonso et al; licensee BioMed Central Ltd. Verbatim copying and redistribution of this article are permitted in any medium for any non-commercial purpose, provided this notice is preserved along with the article's original URL. For commercial use, contact info@biomedcentral.com

Abstract

Background: Open dislocations are infrequent, often associated with damage to the neurovascular structures. We present an unusual case of an open antero-lateral dislocation of the elbow, which was not associated with any vascular or neural injury.

Case presentation: A 34 year female dance instructor sustained an open dislocation of her elbow. Surgical exploration was undertaken. No major neurovascular injury was present. There was almost complete disruption of all the muscular and ligamentous attachments to the distal humerus and the proximal radius and ulna, which were not formally repaired during surgery. The elbow was found to be very unstable, and was placed in a back slab. The functional recovery was complete in about six months, the patient regaining full range of elbow movement. Elbow dislocations without associate fractures are adequately treated by manipulation and reduction, in spite of the almost complete disruption of the soft tissues around the joint.

Background

Elbow dislocation is a common injury, postero-lateral dislocation being the commonest pattern of injury. Open dislocations are infrequent, often associated with damage to the neurovascular structures. These injuries and various ways of dealing with them have been widely described in the literature [1–3]. We present an unusual case of an open antero-lateral dislocation of the elbow, which was not associated with any vascular or neural injury.

Case presentation

A 34 year female dance instructor presented to the Accident and Emergency department having fallen on to her right elbow sustaining an open dislocation of her elbow (Figure 1).

On admission there was a palpable radial pulse and full sensation in her forearm and hand. Radiographs revealed

this to be an anterolateral elbow dislocation (Figures 2 and 3). Surgical exploration was undertaken. The uninjured brachial artery, and ulnar and median nerves were all visualised. There was almost complete disruption of all the muscular and ligamentous attachments to the distal humerus and the proximal radius and ulna. The joint was relocated, the wound cleaned with saline lavage and primarily closed without formal repair of muscular and ligamentous structures. The elbow was found to be very unstable, and was placed in a back slab. The post operative period was uneventful.

The elbow was maintained in a splint for a four week period after which gentle physiotherapy was started. The functional recovery was complete in about six months, the patient regaining full range of elbow movement (Figure 4).

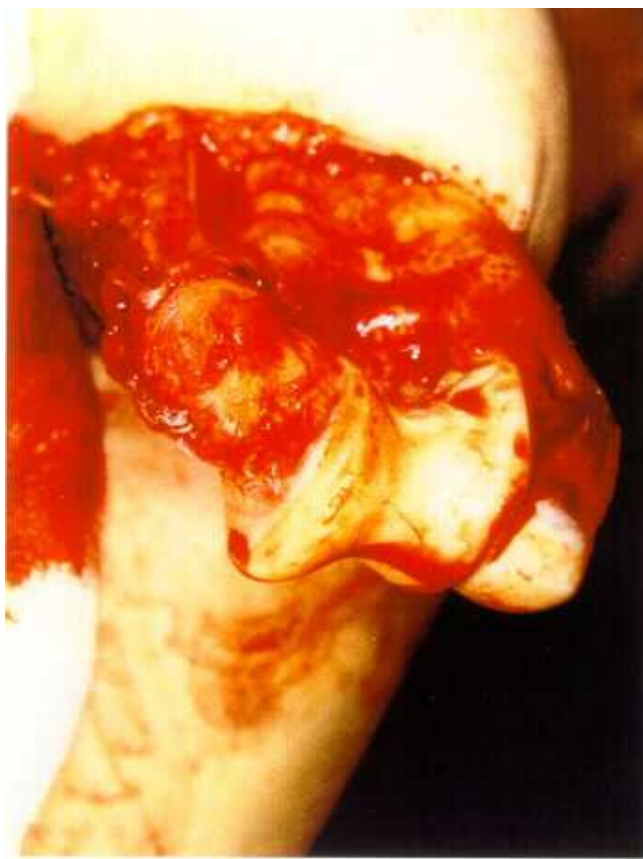


Figure 1
Clinical photograph of open elbow dislocation following a simple fall

Conclusions

Elbow dislocations without associate fractures are termed 'simple'. They are adequately treated by closed reduction, in spite of the almost complete disruption of the soft tissues around the joint. Cases of open dislocation of the elbow are uncommon. They are usually associated with severe trauma, contact sports, road traffic accidents etc. Posterior elbow dislocation is due to a combined valgus and external rotatory stress to the semiflexed elbow, resulting in a bilateral ligamentous injury [4]. Anterior elbow dislocations occur most often as a fracture-dislocation in which the distal humerus is driven through the olecranon [5]. Simple anterior dislocation does not seem to be a well described injury

The stabilising structures of the elbow can be thought of as a ring [6]. The trochlear notch surrounds almost 180 degrees of the trochlea, accounting for a large part of the stability of the elbow joint. The ulno-humeral articulation has been shown to be the most important stabiliser of the elbow joint. The posterior column, the disruption of

which would be a prerequisite for anterior dislocation, is formed by the olecranon, the triceps, and the posterior aspect of the capsule [6]. This would explain the rarity of this injury.

In our patient the medial collateral ligament was found to be disrupted at operation. Thus, the injury had also involved the medial column, dislocating the joint in an antero-lateral direction. Most authors recommend accelerated functional treatment for simple elbow dislocations [7], as long periods of immobilisation have not been found to be of any benefit [8]. Surgical repair of the ligaments has been advocated, but there is little evidence that the results of surgical repair of the ligaments are any better than those of non-surgical treatment [9]. This case highlights the possibility of sustaining an extensive soft tissue damage after a minor injury and illustrates how excellent functional outcome can be achieved with a conservative approach in this situation.

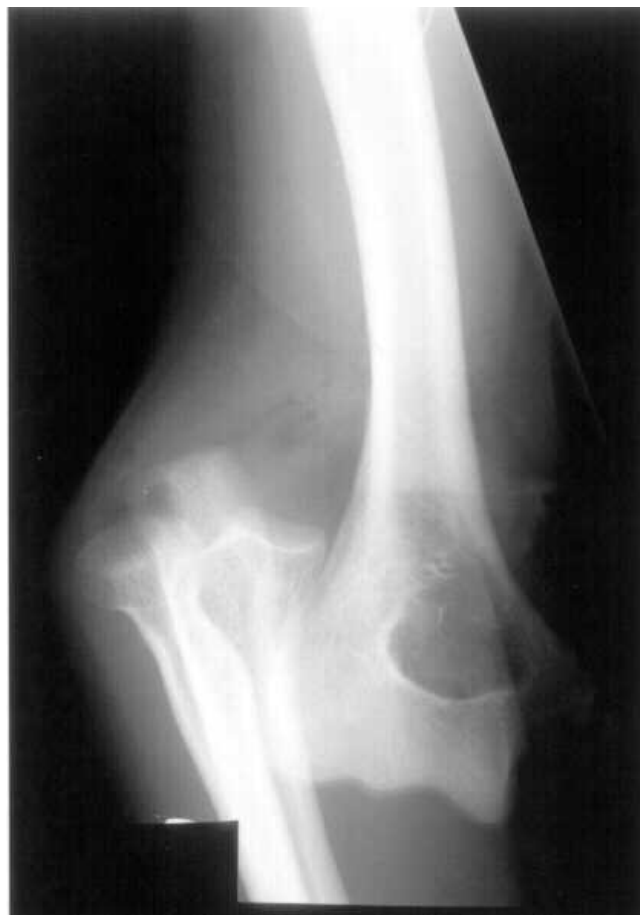

Figure 2
Postero-anterior radiograph of right elbow showing an antero-lateral dislocation

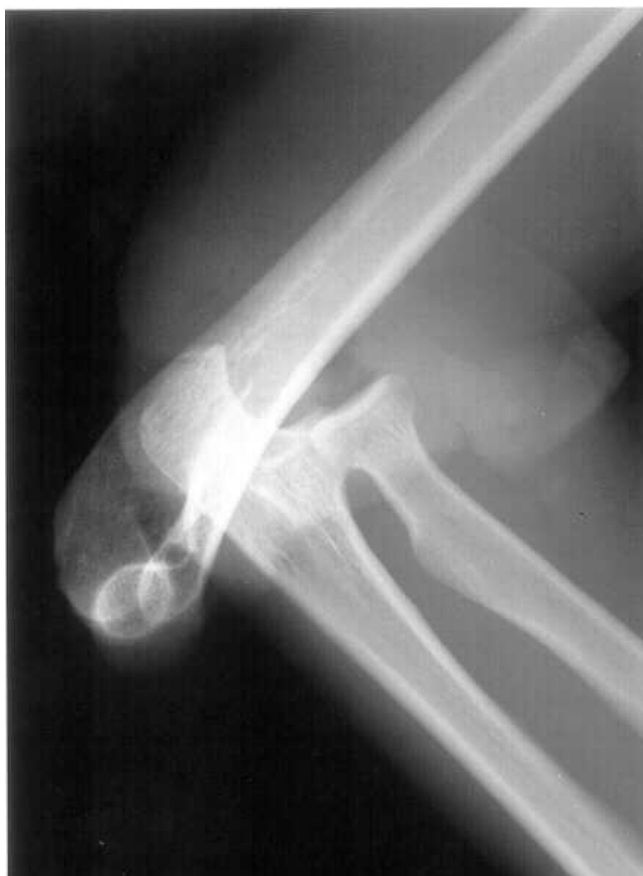

Figure 3
Lateral radiograph of right elbow showing an antero-lateral dislocation



Figure 4
Clinical photograph showing the range of movements achieved on the injured elbow six months after injury

Competing interests
None declared.

References

1. al-Qattan MM, Zuker RM, Weinberg MJ, McKee N, McCall J: **The use of a shunting catheter for a ruptured brachial artery following open elbow dislocation.** *J Hand Surg [Br]* 1994, **19**:788-90
2. Kharrazi FD, Rodgers WB, Waters PM, Koris MJ: **Dislocation of the elbow complicated by arterial injury. Reconstructive strategy and functional outcome.** *Am J Orthop* 1995, **Suppl**:11-5
3. Mains DB, Freeark RJ: **Report on compound dislocation of the elbow with entrapment of the brachial artery.** *Clin Orthop* 1975, **106**:180-5
4. Sojbjerg JO, Helmig P, Kjaersgaard-Andersen P: **Dislocation of the elbow: an experimental study of the ligamentous injuries.** *Orthopedics* 1989, **12**:461-3
5. Ring D, Jupiter JB, Sanders RW, Mast J, Simpson NS: **Transolecranon fracture-dislocation of the elbow.** *J Orthop Trauma* 1997, **11**:545-50
6. Ring D, Jupiter JB: **Fracture-dislocation of the elbow.** *J Bone Joint Surg Am* 1998, **80**:566-80
7. Lansinger O, Karlsson J, Korner L, Mare K: **Dislocation of the elbow joint.** *Arch Orthop Trauma Surg* 1984, **102**:183-6
8. Riel KA, Bernett P: **Simple elbow dislocation. Comparison of long-term results after immobilization and functional treatment.** *Unfallchirurg* 1993, **96**:529-33
9. Josefsson P, Gentz C, Johnell O, Wendeberg B: **Surgical versus non-surgical treatment of ligamentous injuries following dislocation of the elbow joint. A prospective randomized study.** *J Bone Joint Surg [Am]* 1987, **69**:605-8

Publish with **BioMed Central** and every scientist can read your work free of charge

"BioMedcentral will be the most significant development for disseminating the results of biomedical research in our lifetime."
Paul Nurse, Director-General, Imperial Cancer Research Fund

Publish with **BMC** and your research papers will be:

- available free of charge to the entire biomedical community
- peer reviewed and published immediately upon acceptance
- cited in PubMed and archived on PubMed Central
- yours - you keep the copyright

Submit your manuscript here:
<http://www.biomedcentral.com/manuscript/>



BioMedcentral.com
editorial@biomedcentral.com